

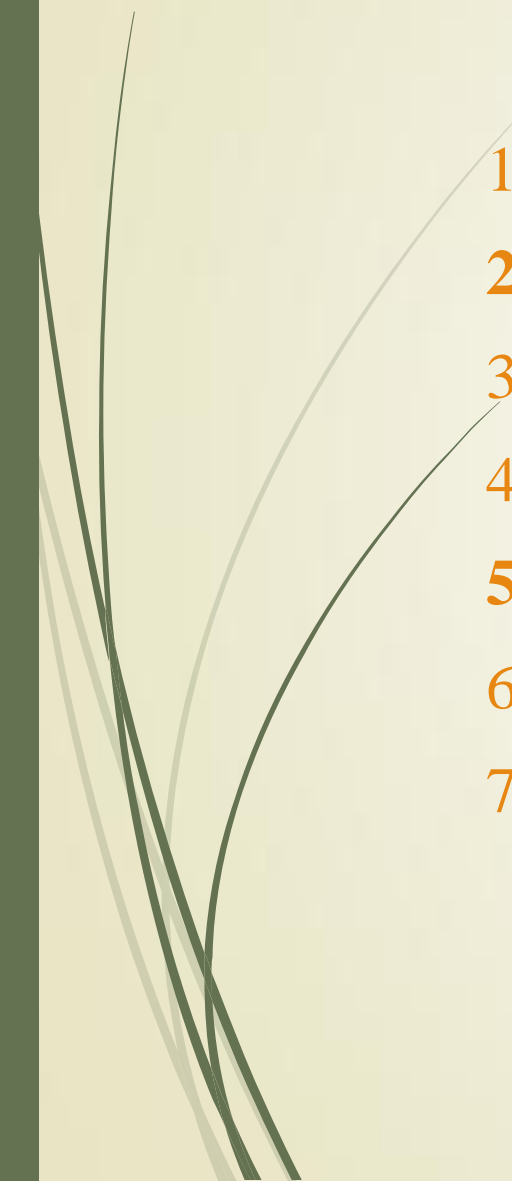



Functional anatomy and variability of the blood vessels of the upper and lower limbs

Anastasia Bendelic
Human Anatomy Department




Plan:

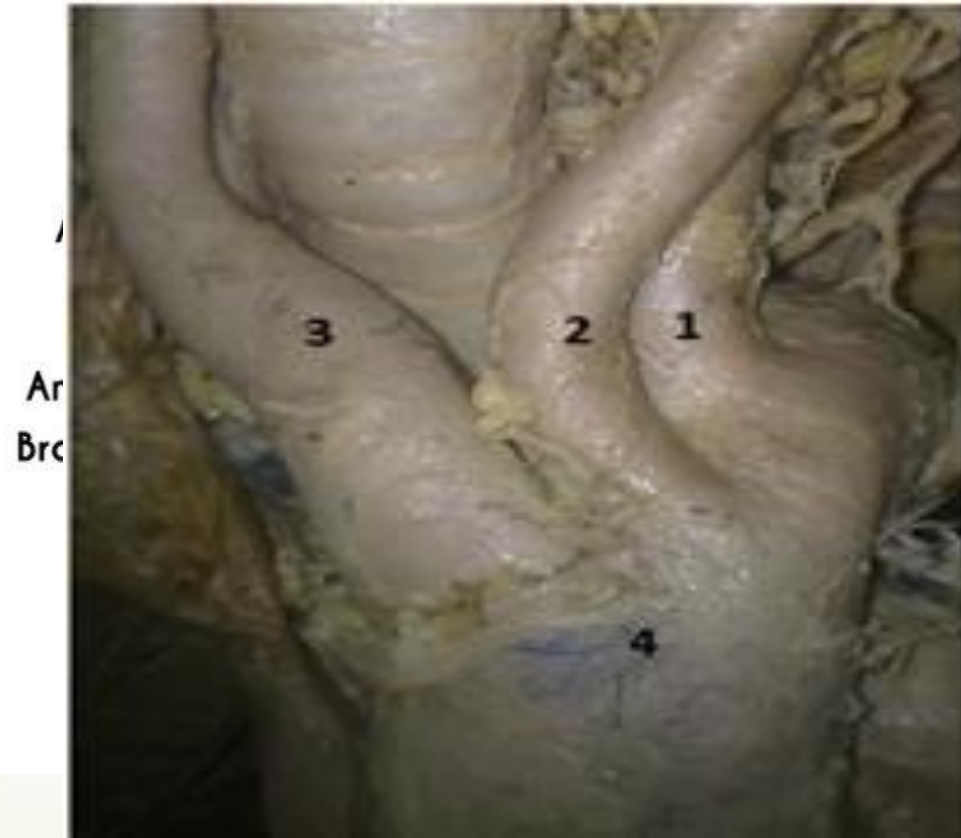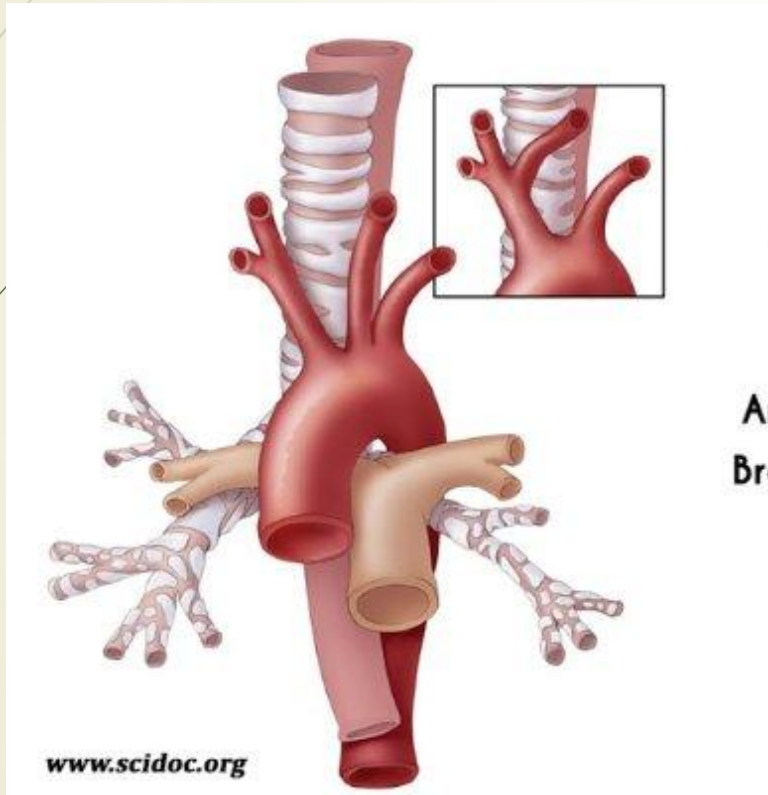
1. Variations of the branching pattern of the aortic arch
 2. **Arterial anastomoses** of the upper extremity
 3. Determining the **arterial pulse** on the upper limbs
 4. Variations of the arterial patterns in the upper limb
 5. **Arterial anastomoses** of the lower extremity
 6. Determining the **arterial pulse** on the lower limbs
 7. Variations of the arterial patterns in the lower limb
- 




Variations of the branching pattern of the aortic arch

- ▶ Variations of the branching pattern of the aortic arch are not rare.
 - ▶ Most of them are asymptomatic and mostly found as incidental finding during routine diagnostic procedures.
 - ▶ However, head and neck surgeons and interventional radiologists should be aware of aortic arch variation.
 - ▶ The normal three-branch pattern of the aortic arch is found with an incidence of 64,9-94,3% according to the literature.
- 

The normal three-branch pattern of the aortic arch (64,9-94,3%)

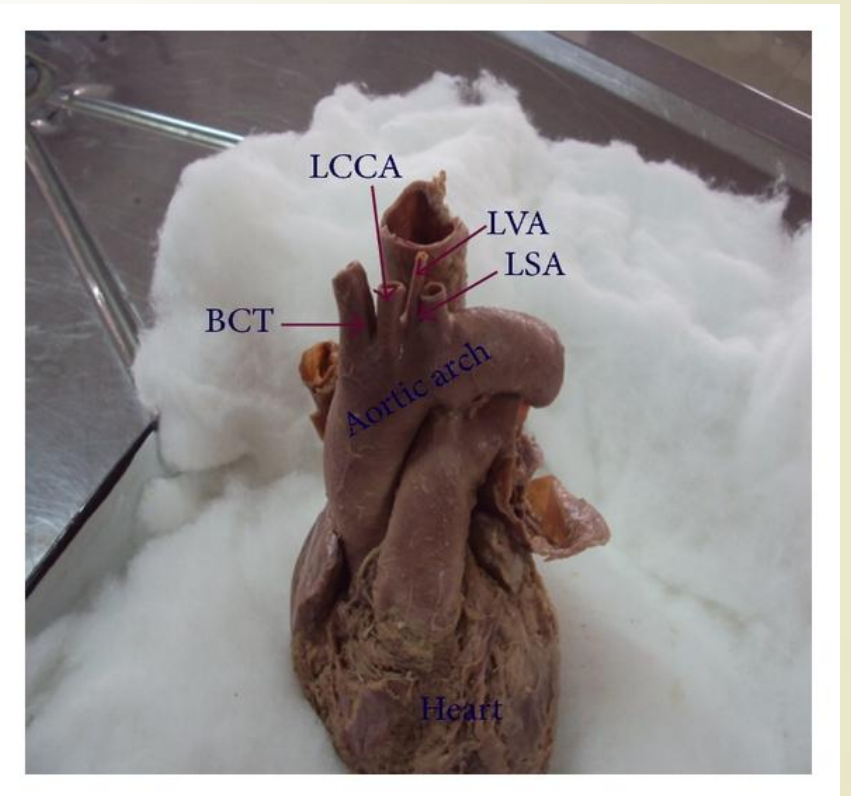
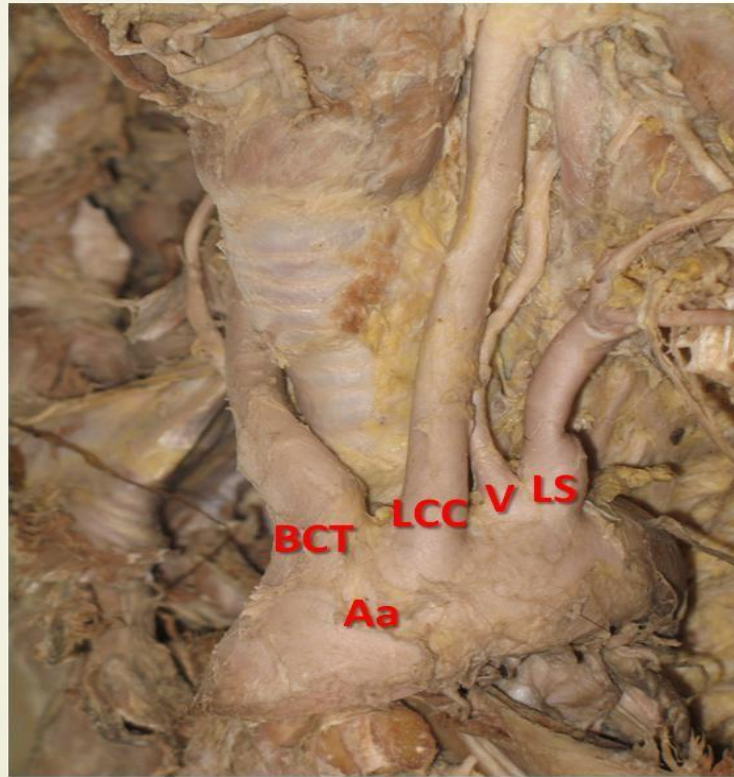





Variations of the branching pattern of the aortic arch


- ▶ The most common variation of the aortic arch with two branches (**common brachiocephalic trunk with left common carotid artery and left subclavian artery**) is found with an incidence of 10-22% in literature.
- ▶ Origination of the **left vertebral artery** from the aortic arch is not uncommon and the reported prevalence is between 2,4 and 8%.

Origination of the left vertebral artery from the aortic arch (2,4-8%)

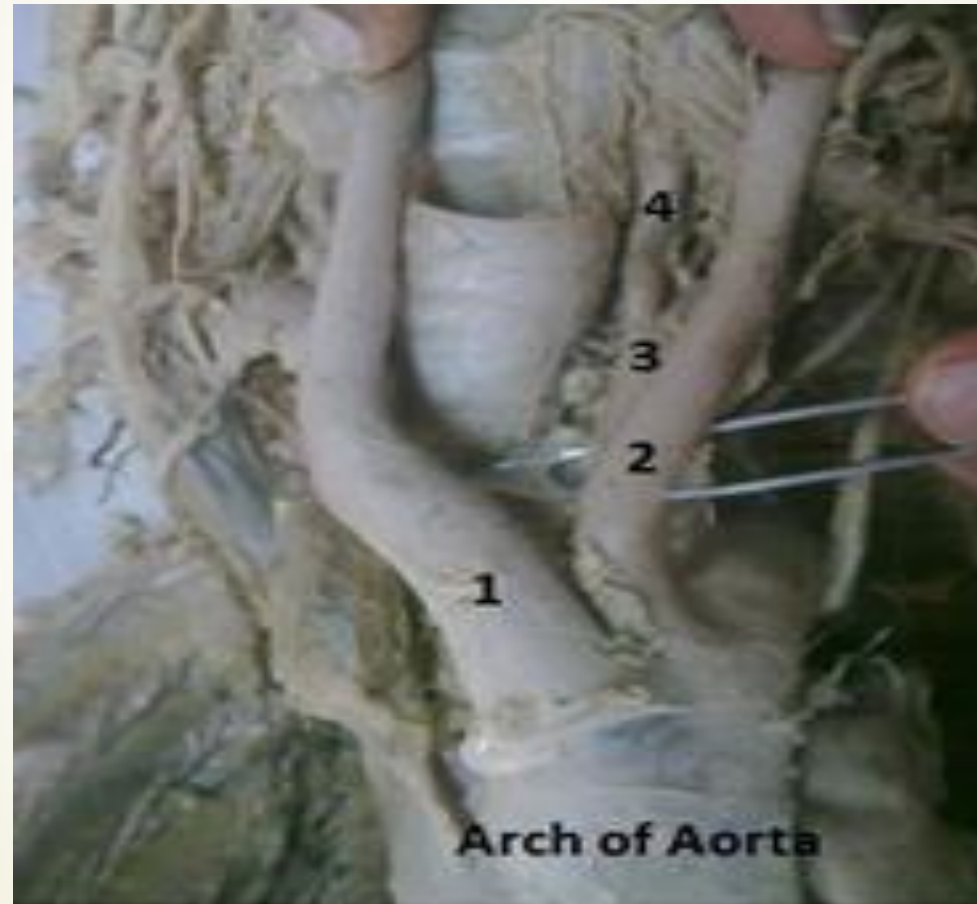




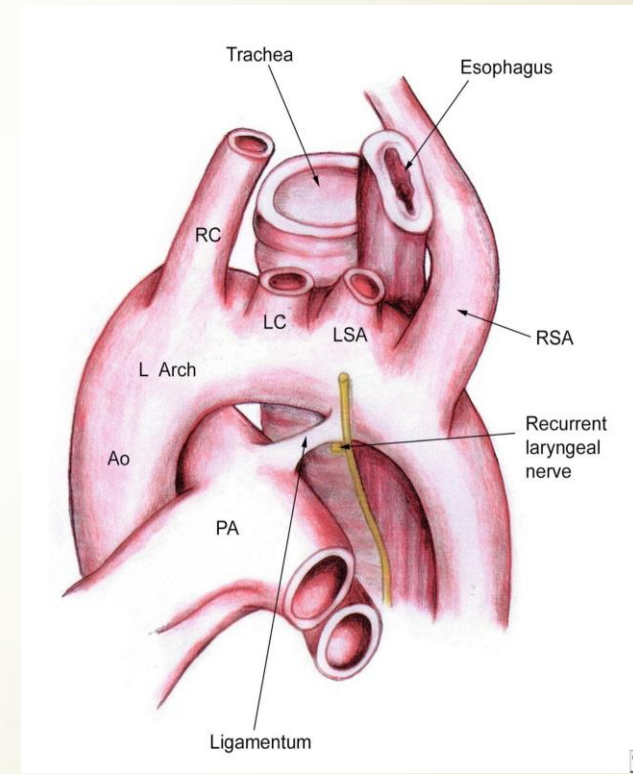
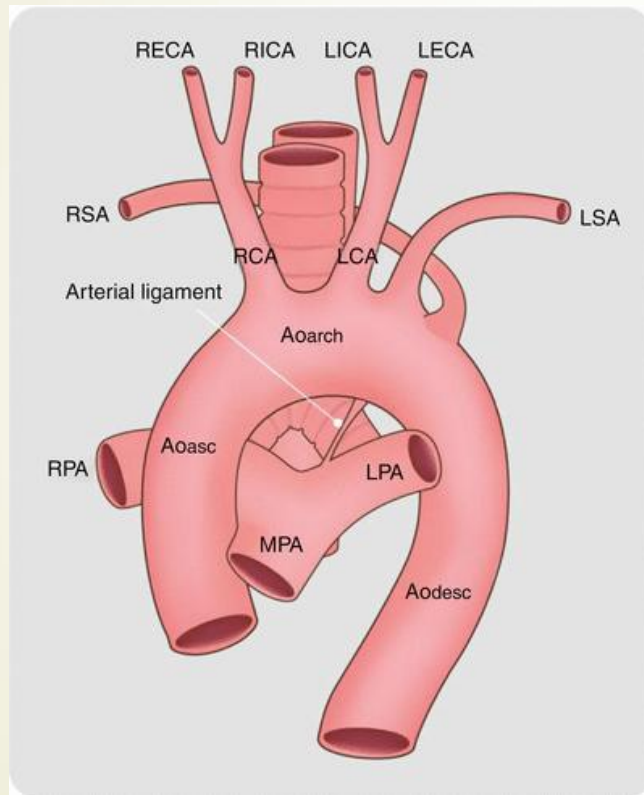
Variations of the branching pattern of the aortic arch

- ▶ Two common brachiocephalic trunks.
 - ▶ The brachiocephalic trunk is absent and right subclavian artery, right common carotid artery, left common carotid artery and left subclavian artery leave the aortic arch separately.
 - ▶ The right subclavian artery is the last branch of the aortic arch in ~1% of individuals. It courses to the right behind of the esophagus. A retroesophageal course may be the cause of dysphagia.
- 

Two brachiocephalic trunks

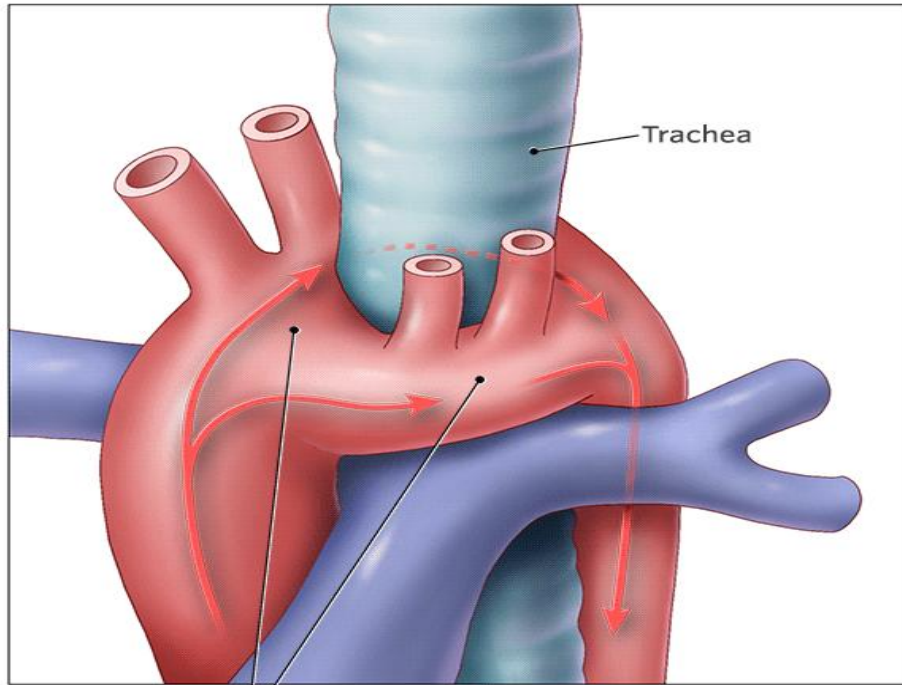


The brachiocephalic trunk is absent (retroesophageal course of the right subclavian artery)



Double aortic arch

Vascular Ring

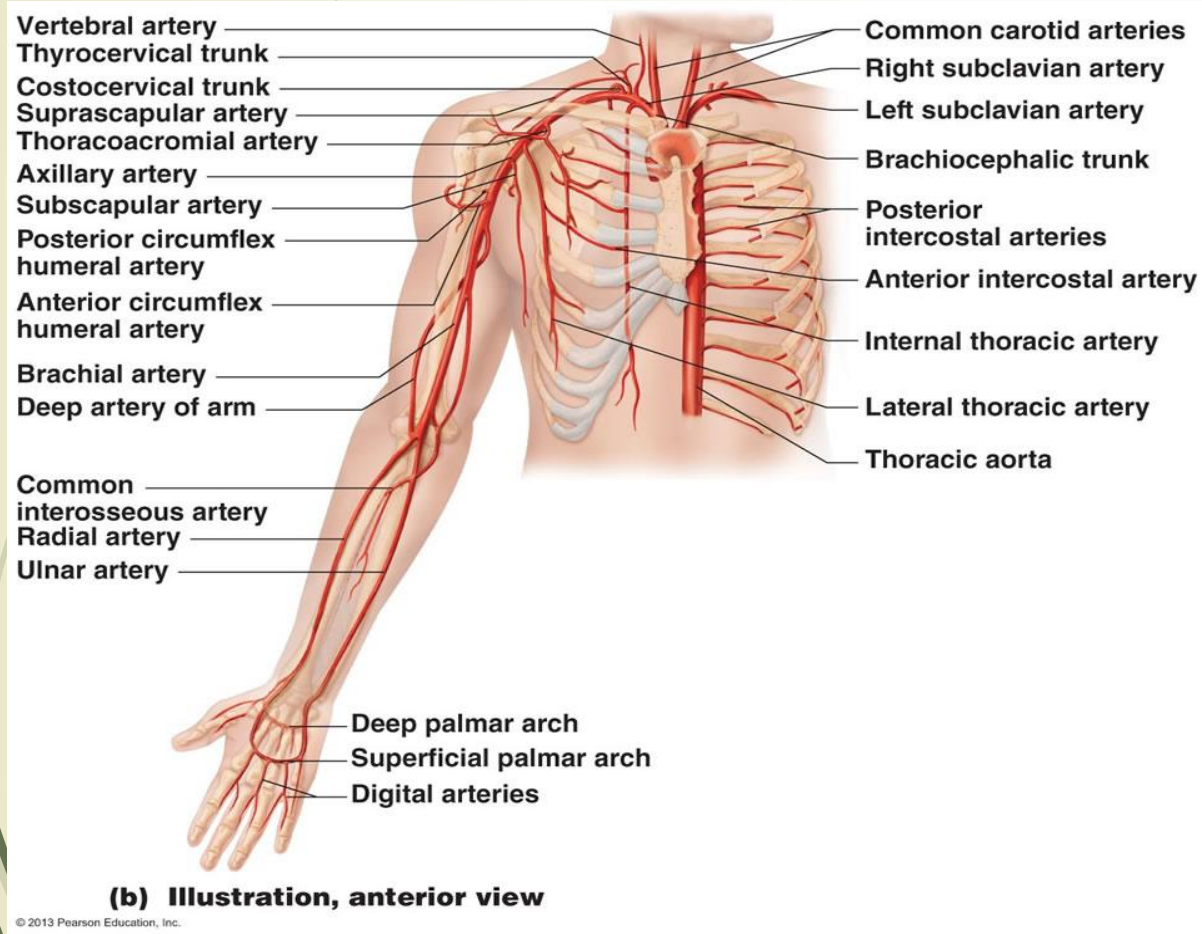


Double Aortic Arch Type
(surrounds the trachea and esophagus)

● Oxygen-rich blood ● Oxygen-poor blood

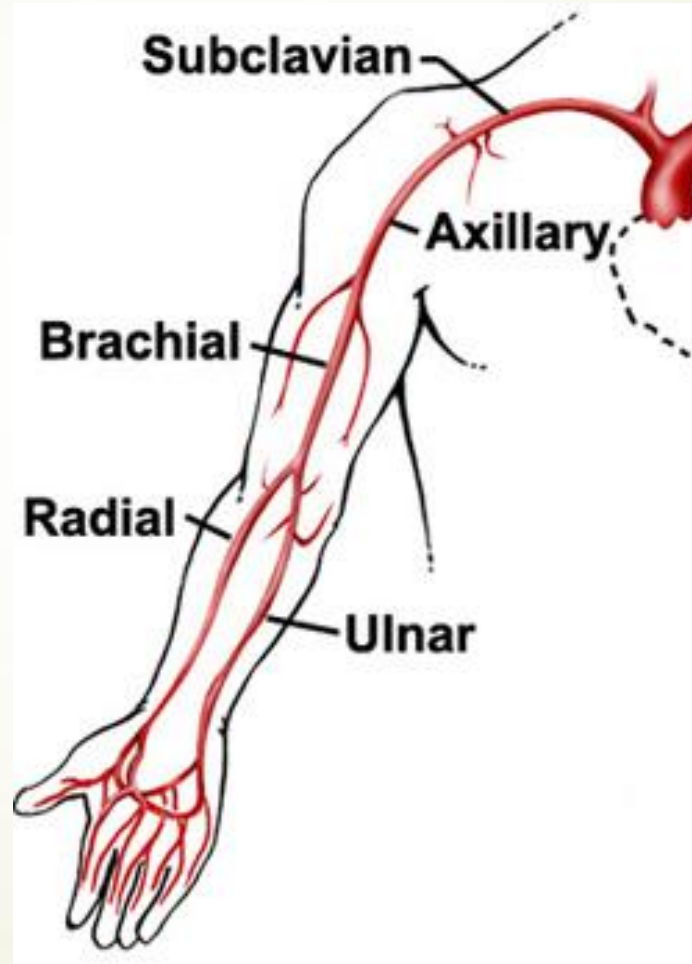
Double aortic arch is a rare anomaly caused by the persistence of the fetal double aortic system. It is a form of complete vascular ring that may compress the trachea and esophagus.


The arteries of the upper limb




The **brachial artery** usually begins as a continuation of the **axillary artery** at the inferior border of the teres major muscle. It ends at about a centimeter distal to the elbow joint at the level of the neck of radius by dividing into **radial** and **ulnar arteries**.

The arteries of the upper limb





Arterial anastomoses of the upper extremity

- 1. Scapular and shoulder anastomoses**
 - 2. Elbow anastomosis**
 - 3. Wrist and hand anastomoses**
- 

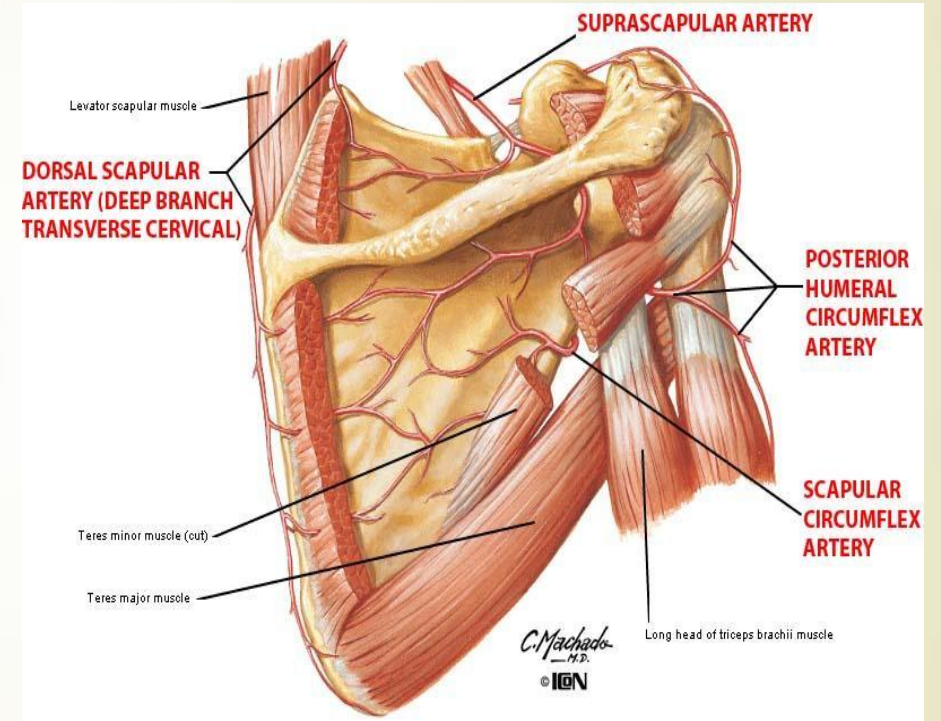
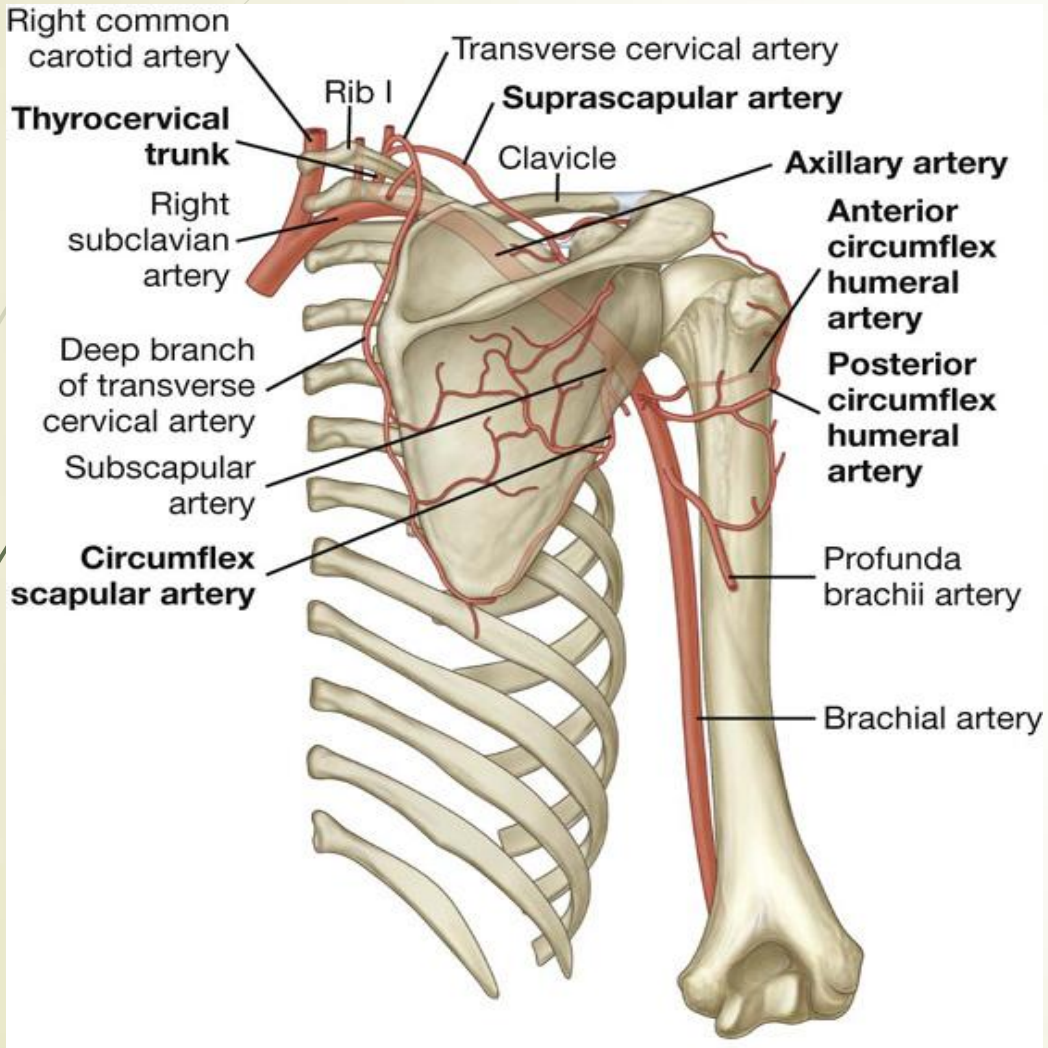
Scapular and shoulder anastomoses

- **Around the scapula** (scapular anastomosis):
 - a) Suprascapular artery (from the thyrocervical trunk);
 - b) Dorsal scapular artery (from the transverse cervical artery);
 - c) Circumflex scapular artery (from the subscapular artery).

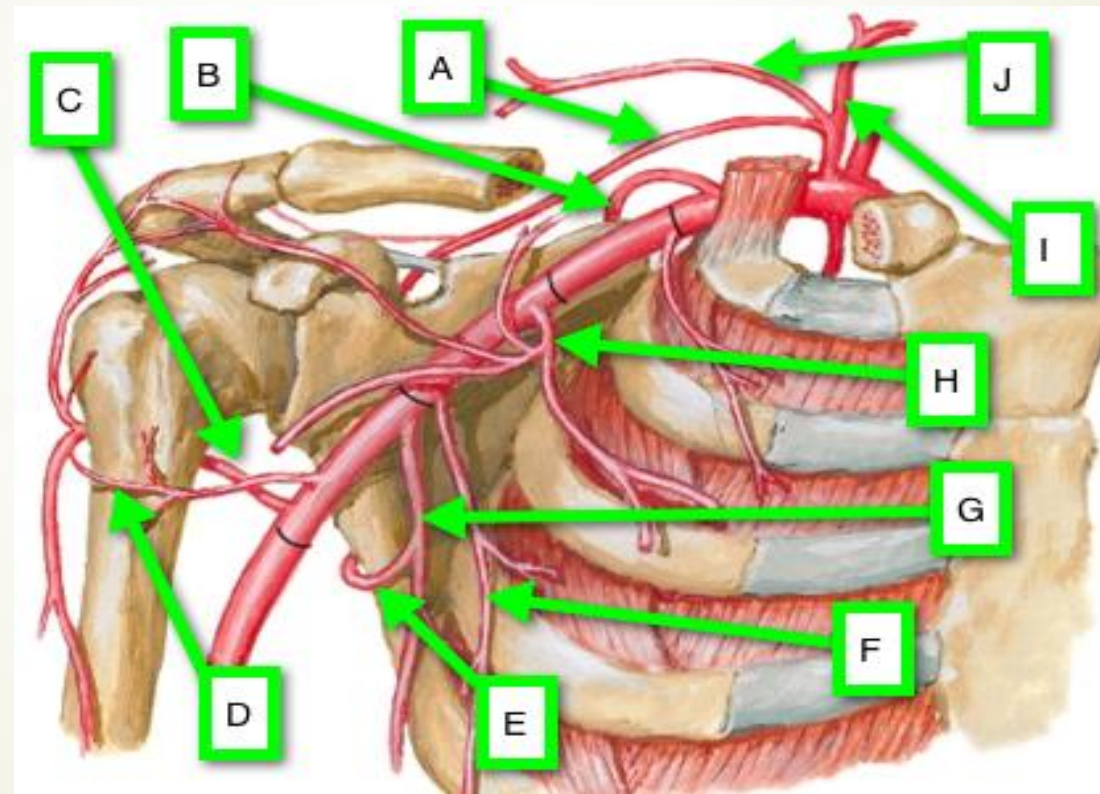
- **Around the surgical neck of the humerus:**
 - a) Anterior humeral circumflex artery (from the axillary artery);
 - b) Posterior humeral circumflex artery (from the artery).


- **Around the acromioclavicular joint** (acromial anastomosis):
 - a) Acromial branch of the thoracoacromial artery;
 - b) Acromial branches of the circumflex humeral arteries;
 - c) Suprascapular artery (from the thyrocervical trunk).

Scapular and shoulder anastomoses



Scapular and shoulder anastomoses





Elbow anastomosis (*rete articulare cubiti*)

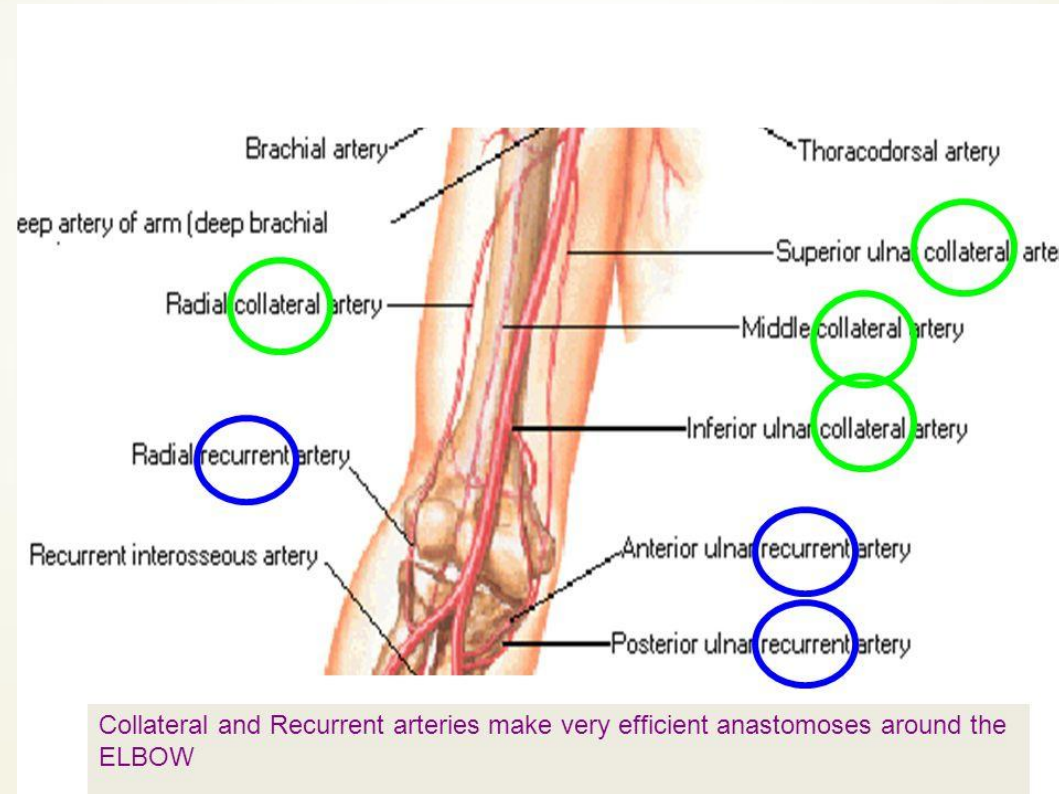
► **Four collateral arteries:**

- a) Radial collateral artery (from the profunda brachii artery);
- b) Medial collateral artery (from the profunda brachii artery);
- c) Superior ulnar collateral artery (from the brachial artery);
- d) Inferior ulnar collateral artery (from the brachial artery).

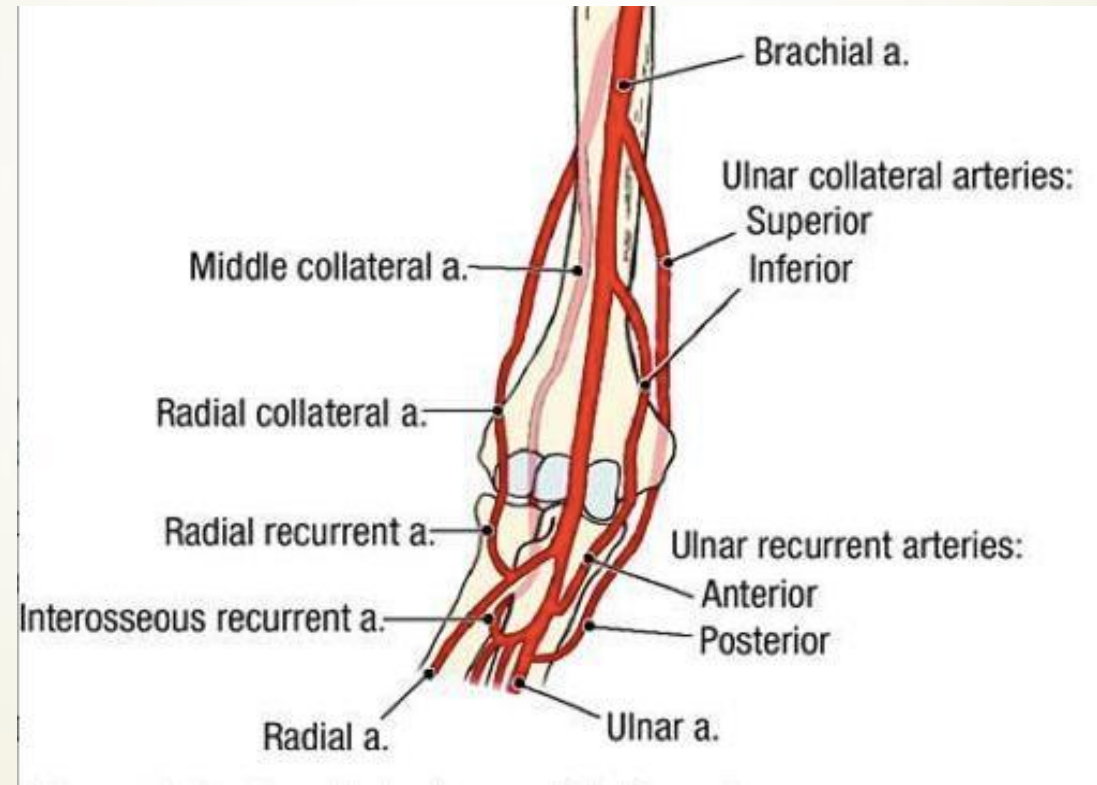
► **Four recurrent arteries:**

- a) Radial recurrent artery (from the radial artery);
- b) Interosseous recurrent artery (from the common interosseous artery);
- c) *Posterior branch* of the ulnar recurrent artery (from the ulnar artery);
- d) *Anterior branch* of the ulnar recurrent artery (from the ulnar artery).

Elbow anastomosis (*rete articulare cubiti*)



Elbow anastomosis (*rete articulare cubiti*)



Wrist anastomoses

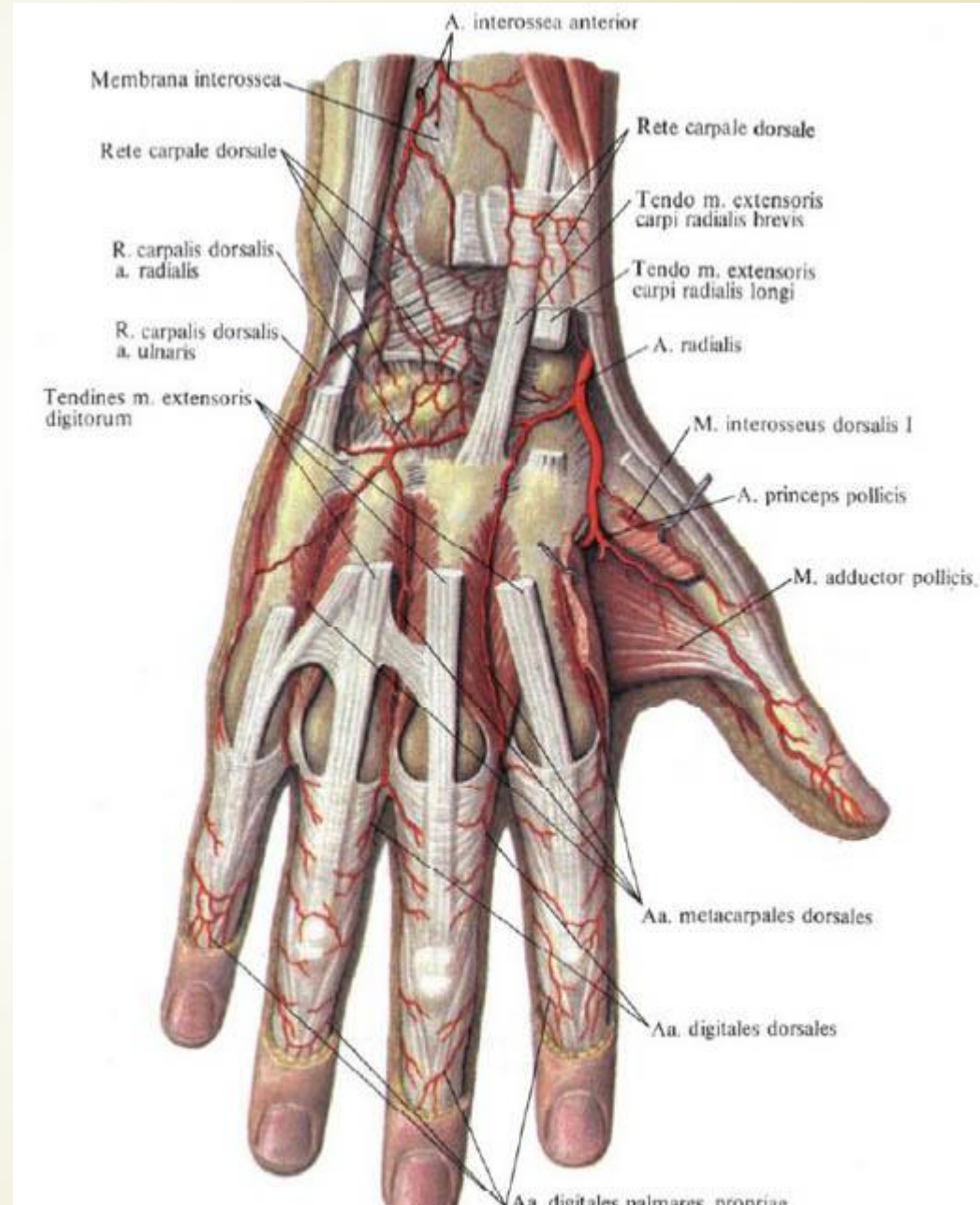
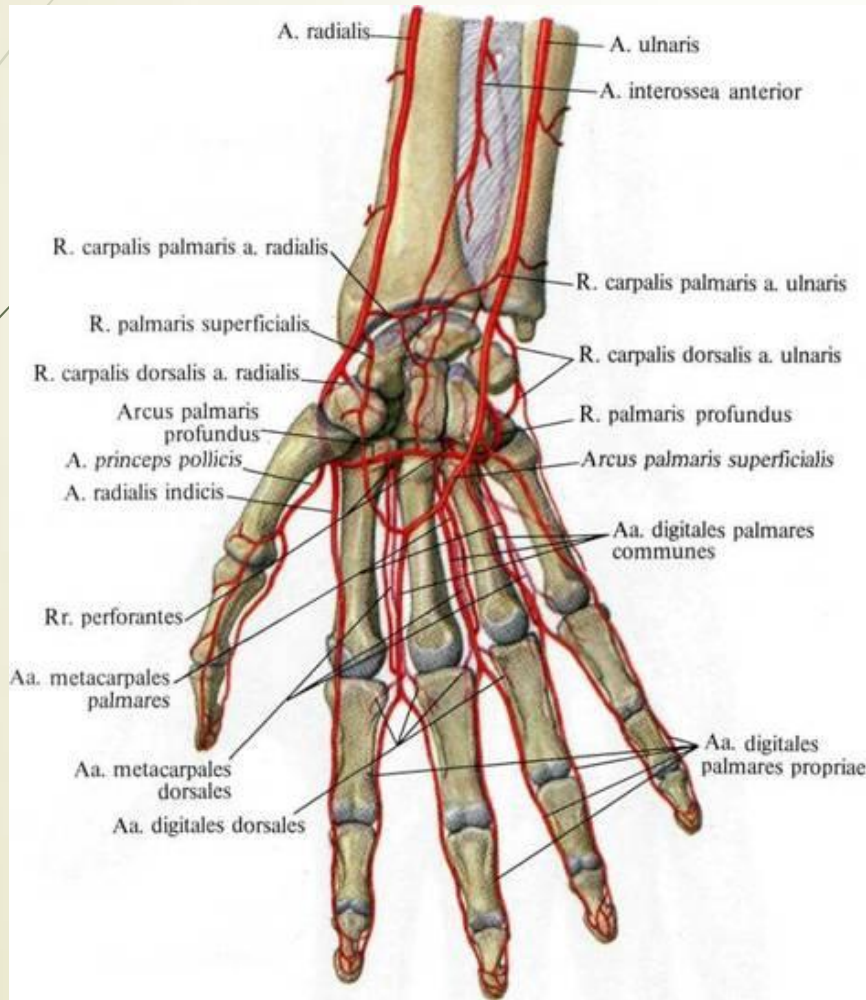
► *Rete carpal dorsale:*

- a) Dorsal carpal branch, *ramus carpalis dorsalis*, (from the ulnar artery);
- b) Dorsal carpal branch, *ramus carpalis dorsalis*, (from the radial artery);
- c) Anterior and posterior interosseous arteries (from the common interosseous artery).

► *Rete carpal palmare:*

- a) Palmar carpal branch, *ramus carpalis palmaris*, (from the ulnar artery);
- b) Palmar carpal branch, *ramus carpalis palmaris*, (from the radial artery);
- c) Anterior interosseous artery (from the common interosseous artery).

Wrist anastomoses



Hand anastomoses (palmar arches)

➤ **Superficial palmar arch** (*arcus palmaris superficialis*) is formed by:

- a) Ulnar artery (its terminal part);
- b) Superficial palmar branch, *ramus palmaris superficialis*, (from the radial artery).

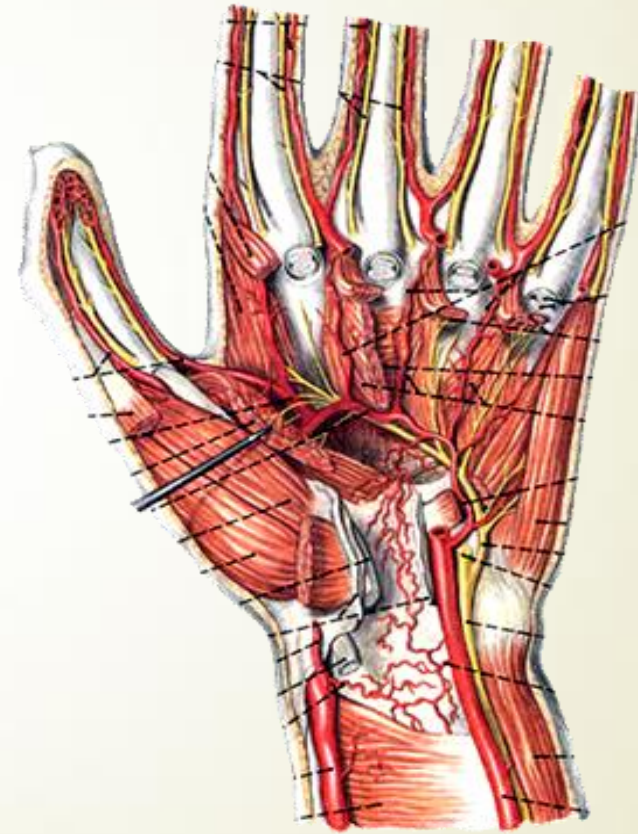
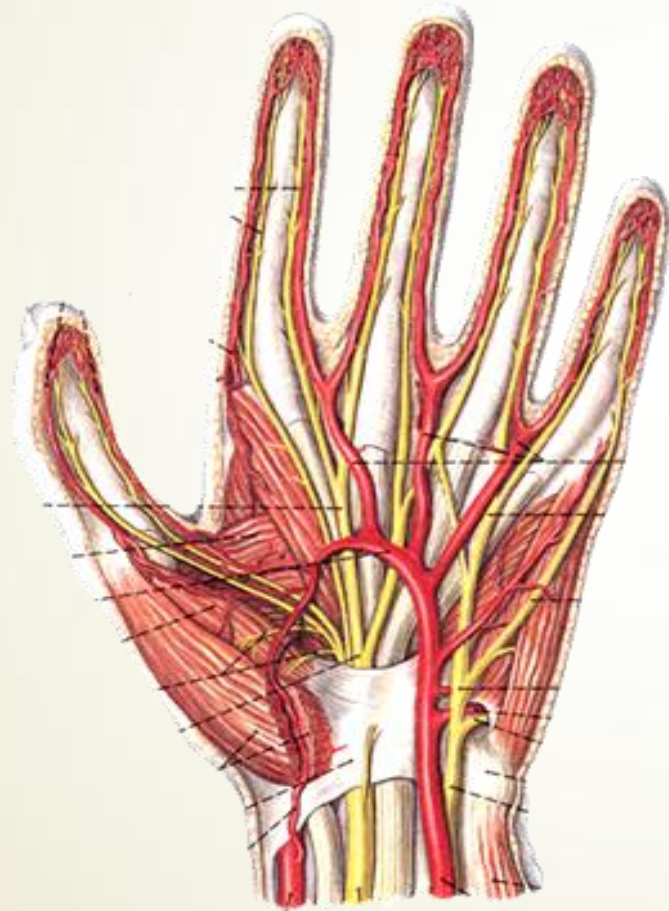
The superficial palmar arch gives rise to **three common palmar digital arteries**, each then divides into two **proper palmar digital arteries**.


➤ **Deep palmar arch** (*arcus palmaris profundus*) is formed by:

- a) Radial artery (its terminal part);
- b) Deep palmar branch, *ramus palmaris profundus*, (from the ulnar artery).


The deep palmar arch gives rise to **three palmar metacarpal arteries**.

Hand anastomoses (palmar arches)

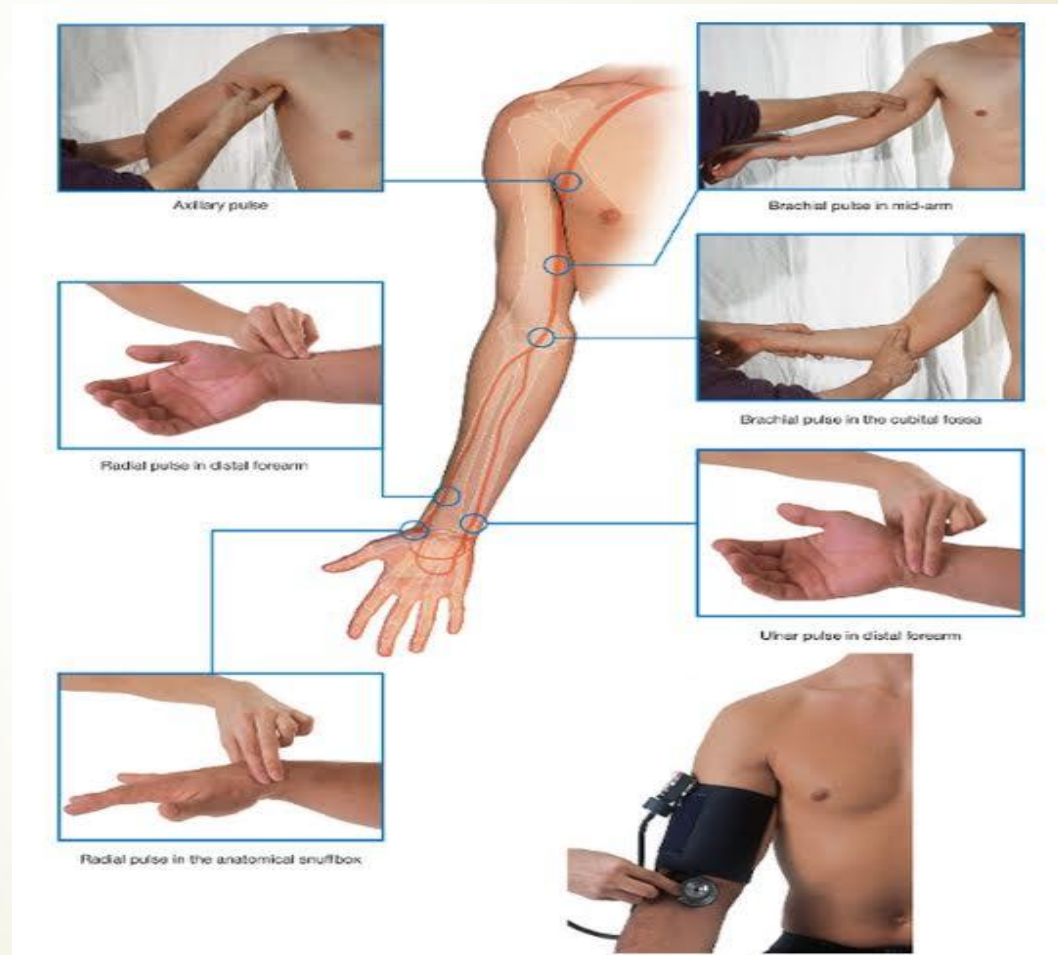



Determining the arterial pulse on the upper limbs


- ▶ **Axillary pulse** is palpated on the lateral wall of the axillary cavity (axillary artery).
 - ▶ **Brachial pulse** is determined from the brachial artery in the distal third of the medial bicipital sulcus or near the elbow joint.
 - ▶ **Radial pulse** is palpated on the lateral side of the wrist and in the anatomical snuffbox (radial artery).
 - ▶ **Ulnar pulse** is defined on the medial side of the wrist (ulnar artery).
- 

Determining the arterial pulse on the upper limbs





Variability of the blood vessels

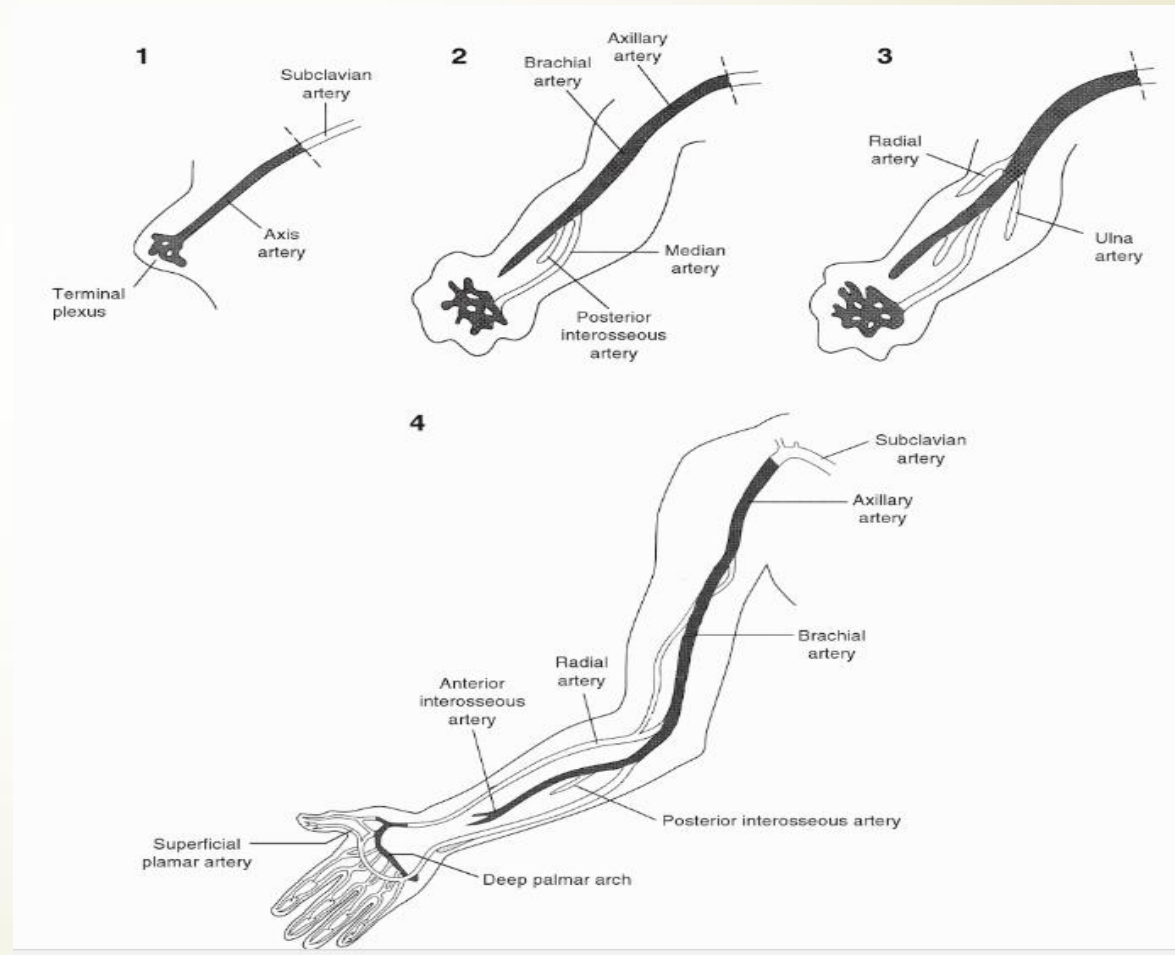
- ▶ The variations of the branching patterns of the arteries of the limbs have clinical and surgical significance.
 - ▶ The knowledge of variations of the arteries of the limbs is important in procedures like the cardiac catheterization, arterial grafting and other angiographic procedures.
 - ▶ The variations may cause a misinterpretation of the angiographic images.
 - ▶ Accidental punctures of the superficially placed arteries may occur while venipunctures are attempted.
 - ▶ The superficially located artery brings an elevated risk of bleeding complications in unexpected situations.
- 



Development of the arteries of the upper limb

- ▶ The anomalies of various blood vessels of upper extremity can be explained on the basis of the embryological development of the vascular plexus of limb buds.
- ▶ The lateral branch of the 7th cervical intersegmental artery gets enlarged to form the **axial artery** of the upper limb, which ends in the **terminal plexus** (*axial arterial plexus*).
- ▶ The axial artery of the upper limb persist as **axillary, brachial and anterior interosseous arteries**.
- ▶ The terminal plexus takes part in the formation of the **deep palmar arch**.

Development of the arteries of the upper limb





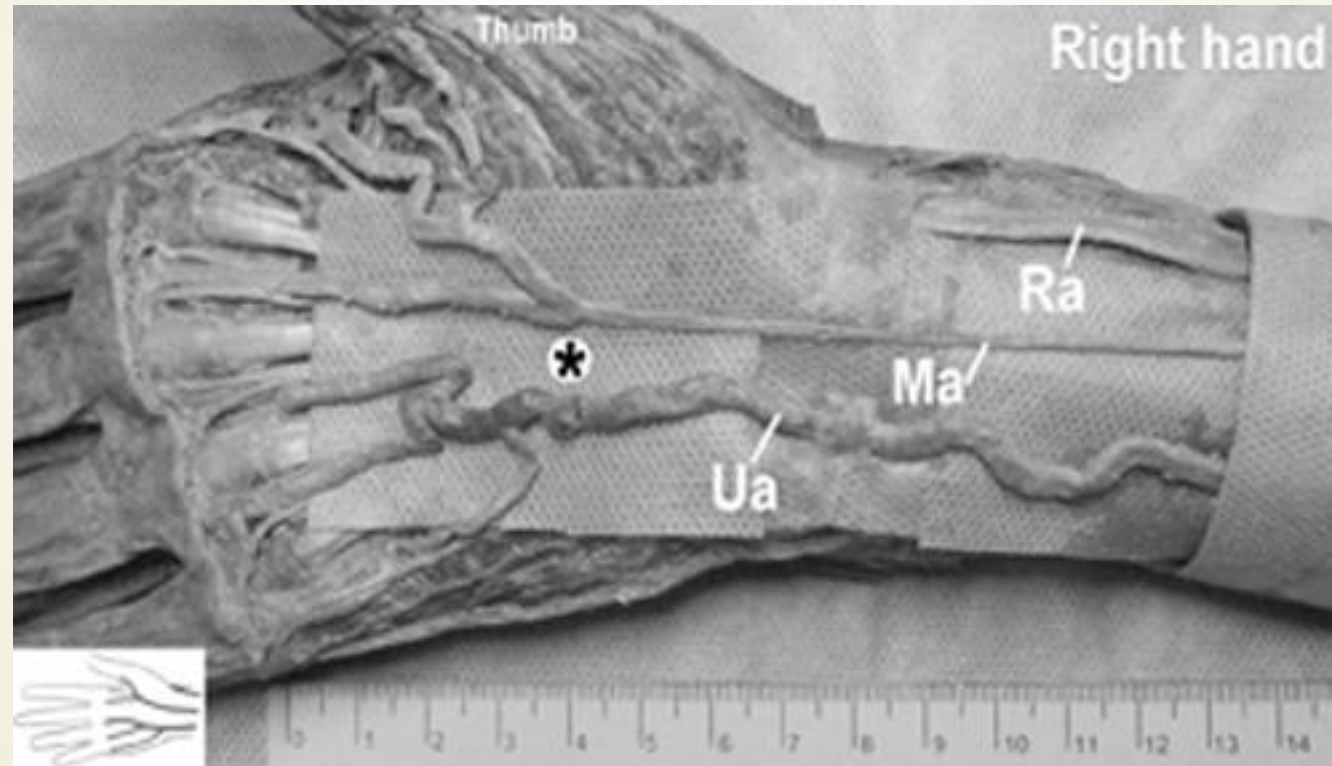
Development of the arteries of the upper limb

- ▶ The axial artery initially splits into the **posterior interosseous artery** and the **median artery** (which is reduced to an unnamed vessel in adult).
- ▶ The axial artery later splits into the **radial** and **ulnar arteries**.
- ▶ Embryologically, the **median artery** is the dominant blood supply to the hand. It normally regresses in the second month of the intrauterine life.
- ▶ The **persistent median artery** has a range of incidence from 17-20%.

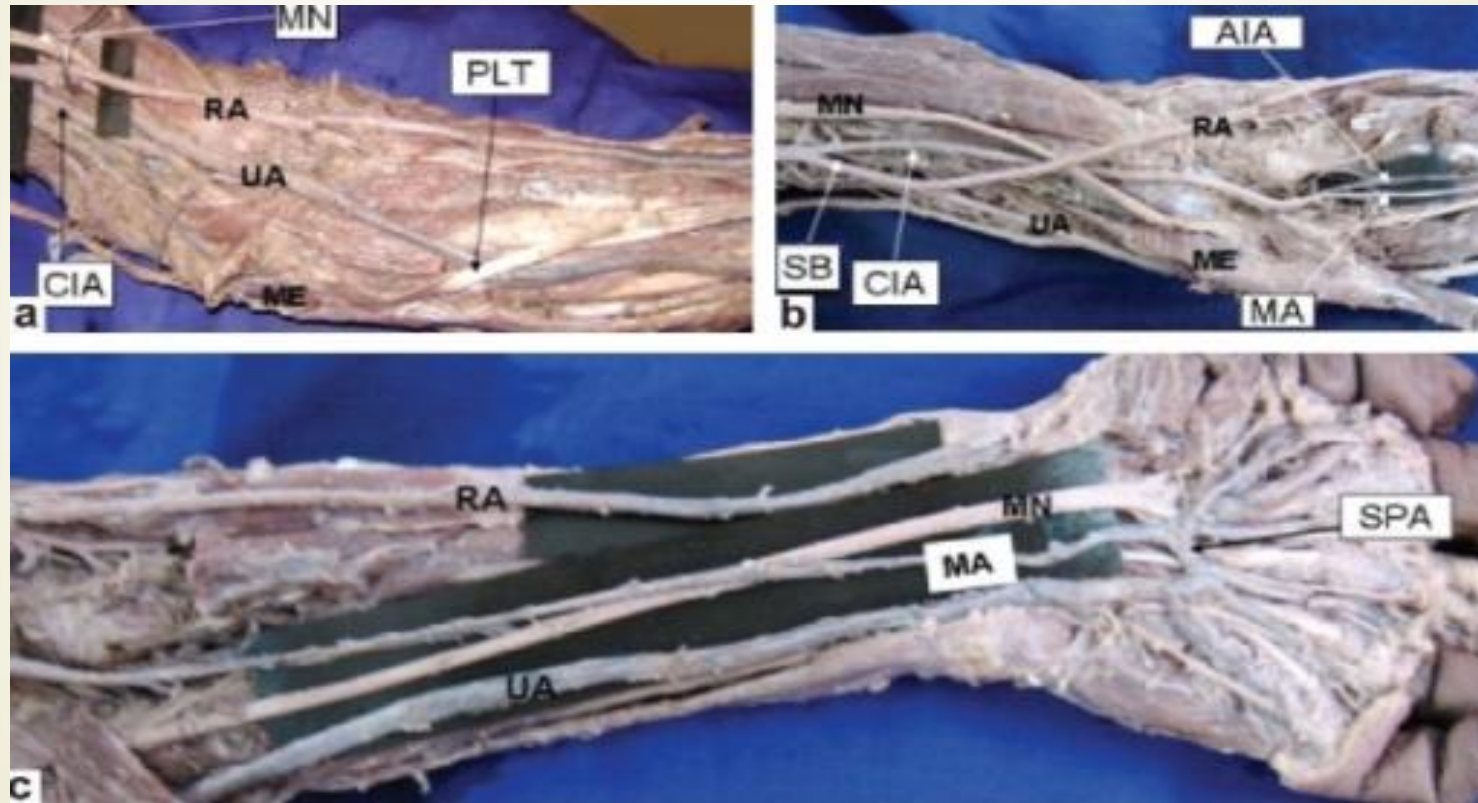
The persistent median artery

- ▶ The **median artery** (a. comitans nervi mediani) is an artery that occasionally found in humans.
 - a) When present, it is found in the forearm, between the radial and ulnar arteries.
 - b) It is a persistent embryological remnant that usually regresses by the 8th week of gestation.
 - c) It runs with the median nerve and supplies the same structures as that nerve.
 - d) It passes deep to the flexor retinaculum and may terminate at one or more of the palmar arches.

The persistent median artery



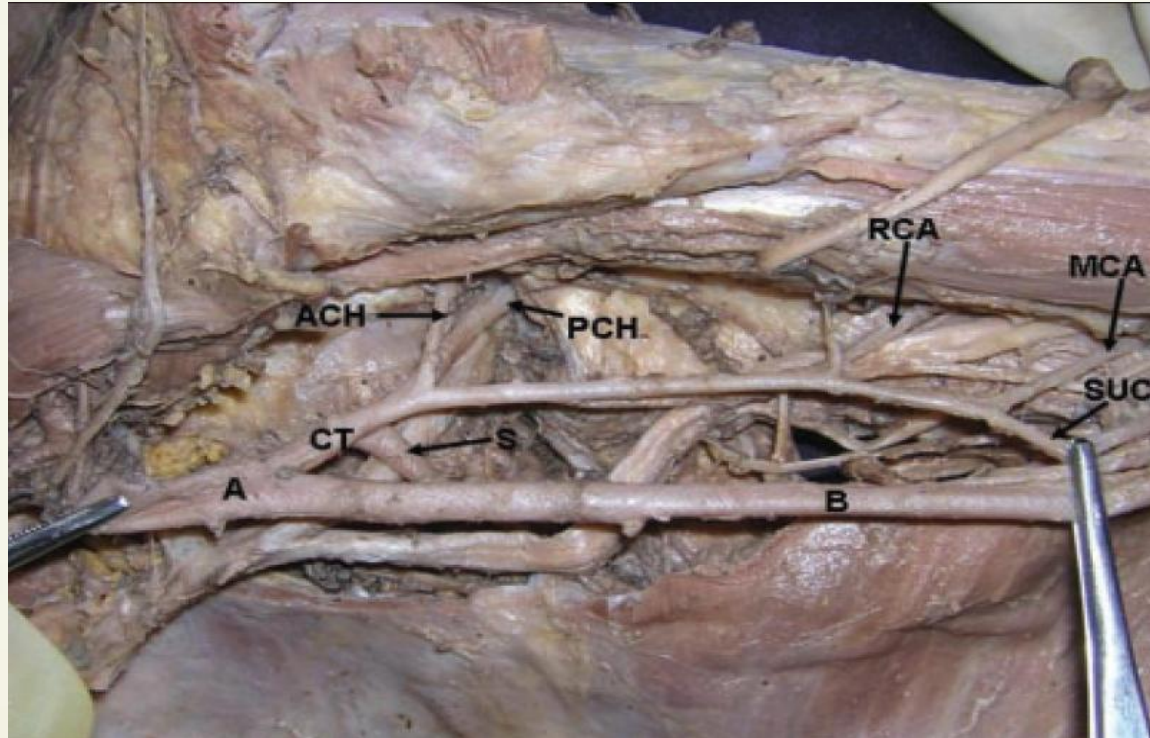
The persistent median artery



Common trunk from the axillary artery

- ▶ Anomalous branching of the third part of the axillary artery:
 - a) **Common trunk**, which gives rise to:
 - *Subscapular artery*,
 - *Anterior circumflex humeral artery*,
 - *Posterior circumflex humeral artery*,
 - *Radial collateral artery*,
 - *Middle collateral artery*,
 - *Superior ulnar collateral artery*.

A common trunk from axillary artery





Variations of the arterial patterns in the upper limb

- ▶ The **profunda brachii artery** is the largest branch of the brachial artery and it shows considerable variations in its origin.
 - a) It may arise from the axillary artery (22% cases); as a **common trunk with superior ulnar collateral artery** (22% cases), as a branch of circumflex humeral artery (in 7% cases).

Common trunk of the profunda brachii artery with superior ulnar collateral artery



Variations of the arterial patterns in the upper limb

- ▶ **Superficial brachial artery** – a brachial artery coursing in front of rather than behind the median nerve.
- ▶ **Accessory brachial artery** – originates from upper third of the brachial artery and rejoins proximal to the elbow with the brachial artery.
- ▶ **Brachioradial artery** – is define as a radial artery with a *high origin* coexisting with brachial artery that branches into ulnar and common interosseous trunk.
- ▶ **Superficial brachioradial artery** – is define as a high origin of the radial artery coursing over the brachioradialis muscle or tendons, which define the snuffbox and coexisting with a brachial artery that usually branches into ulnar and interosseous arteries.

Accessory brachial artery

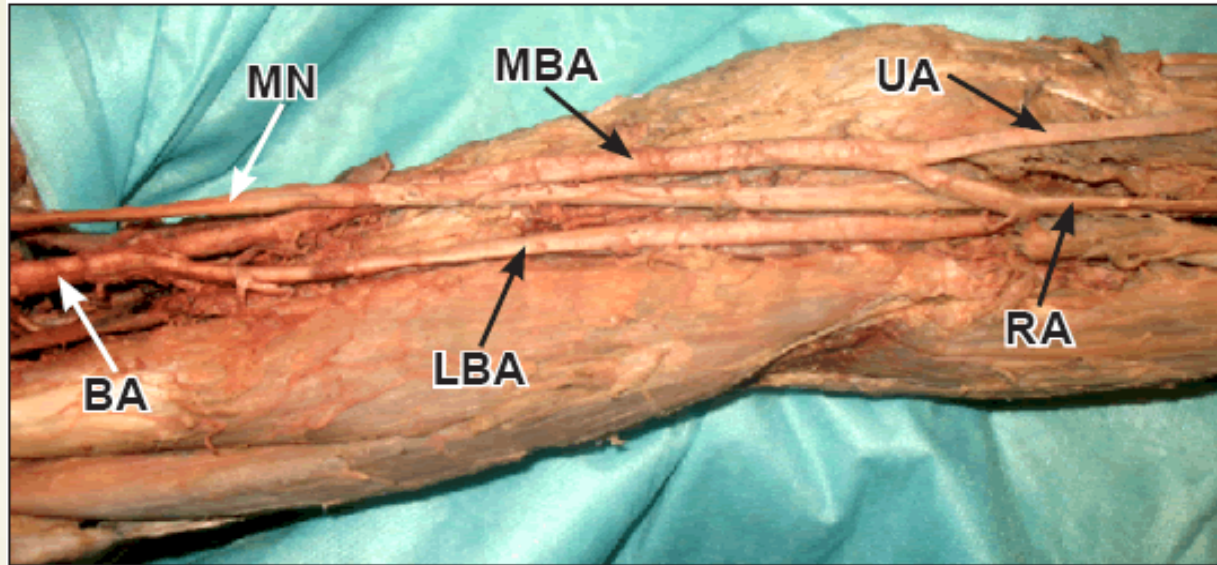
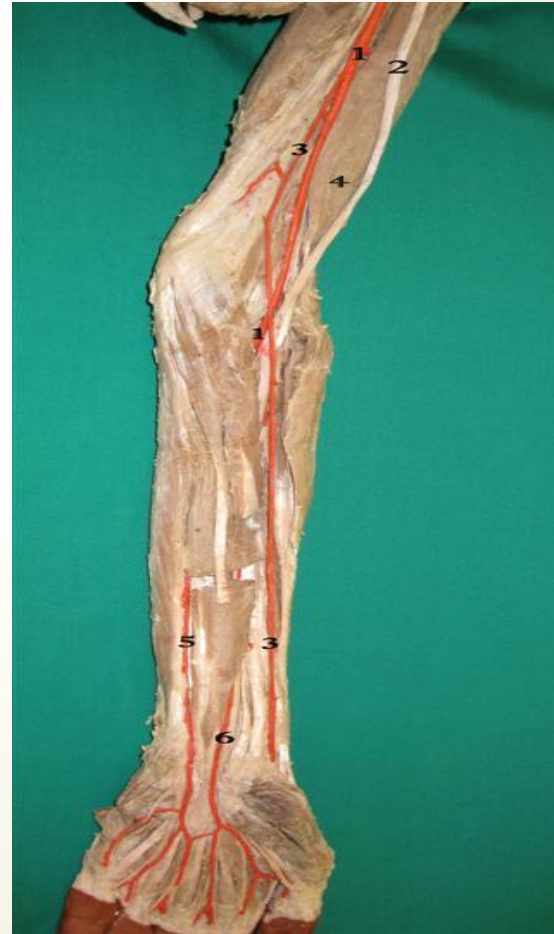
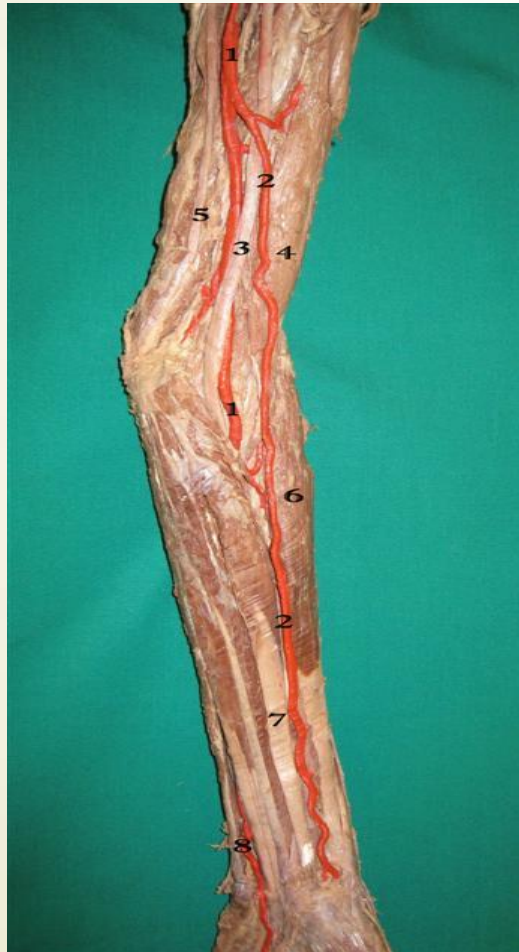
Figure 2. Photograph of the right *main brachial artery (BA)* bifurcating in the upper arm into the *medial (MBA)* and *lateral brachial arteries (LBA)*. The medial brachial artery represented a normal brachial artery dividing in the cubital fossa into superficial *ulnar (UA)* and *radial arteries (RA)*. The lateral brachial artery, in the cubital fossa, disappeared deep to pronator teres as the common interosseous artery. (*MN: median nerve*)

Brachioradial artery (a high origin of the radial artery)






Variations of the arterial patterns in the upper limb

- ▶ **Brachioulnar artery** – is define as an ulnar artery with a *high origin* and a normal course along the forearm and hand and coexisting with a brachial artery which branches into the radial and common interosseous trunk.
- ▶ **Superficial brachioulnar artery** – is define as an ulnar artery with a high origin and which courses over the superficial forearm flexor muscles and coexisting with a brachial artery which branches into the radial and common interosseous trunk.



Variations of the arterial patterns in the upper limb

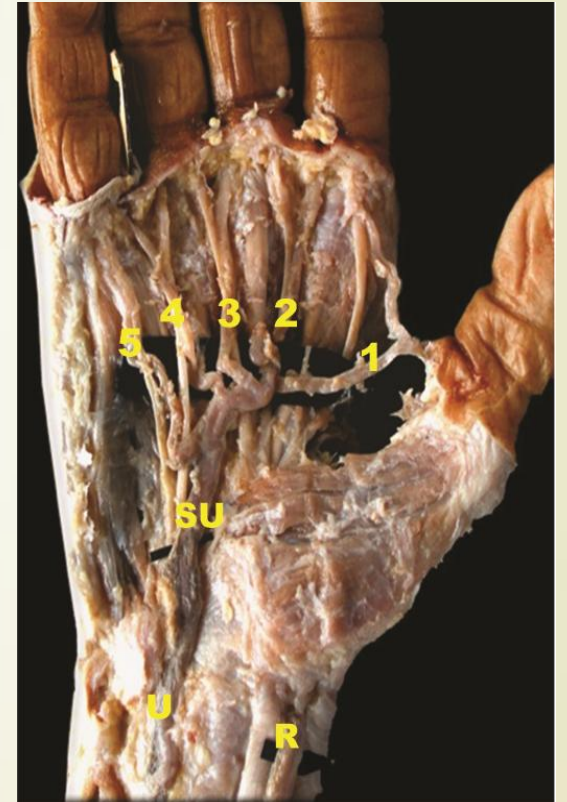
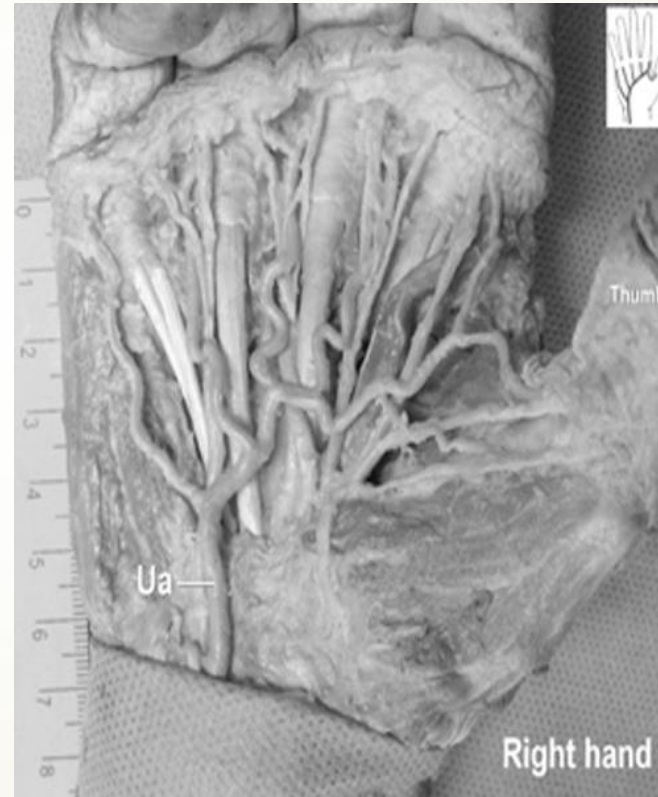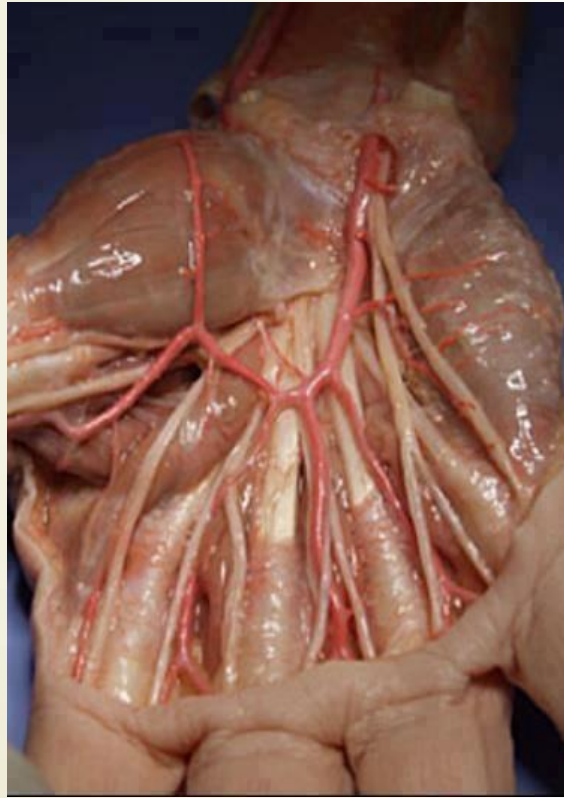
- ▶ **Superficial radial artery** – is a radial artery coursing over the tendons defining the snuffbox.
 - ▶ **Duplication of the radial artery.**
 - ▶ **Absence of the radial artery.** In this case, the radial blood supply territory is provided by the anterior interosseous or the median artery.
 - ▶ **Duplication of the ulnar artery.**
 - ▶ **Absence of the ulnar artery.** This absence is compensated by the radial and interosseous rather than by the median artery.
- 



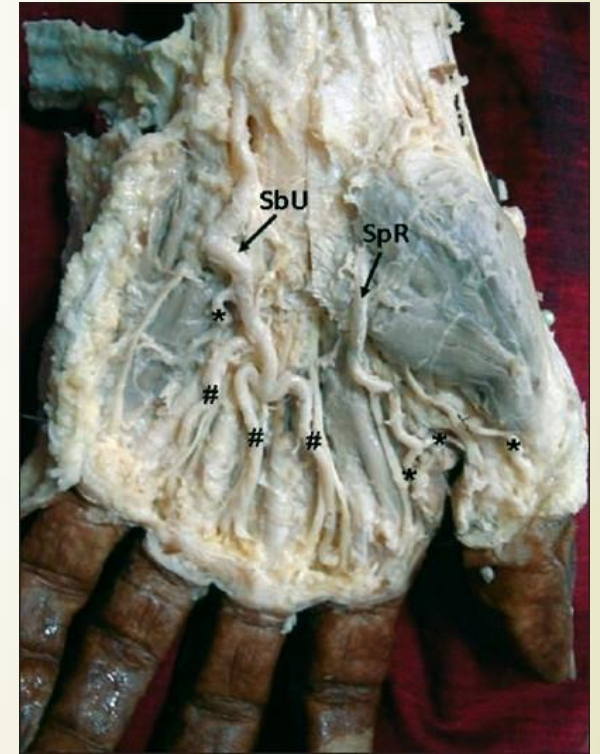
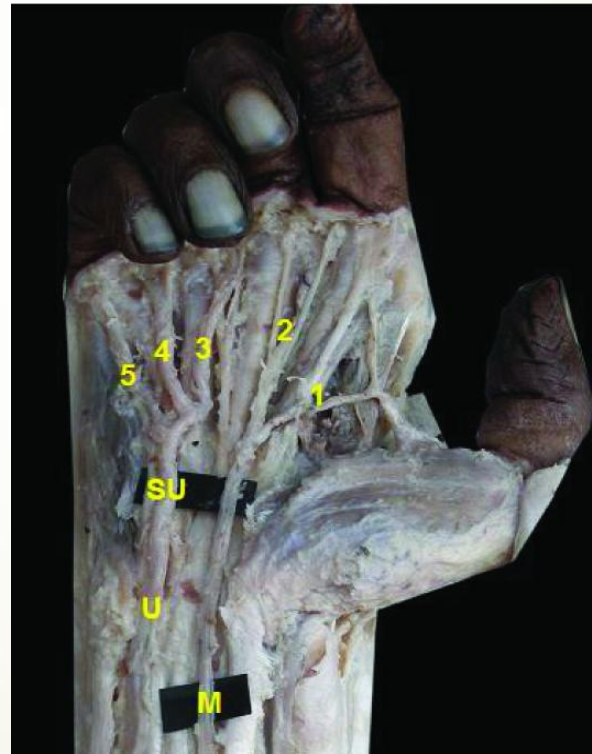
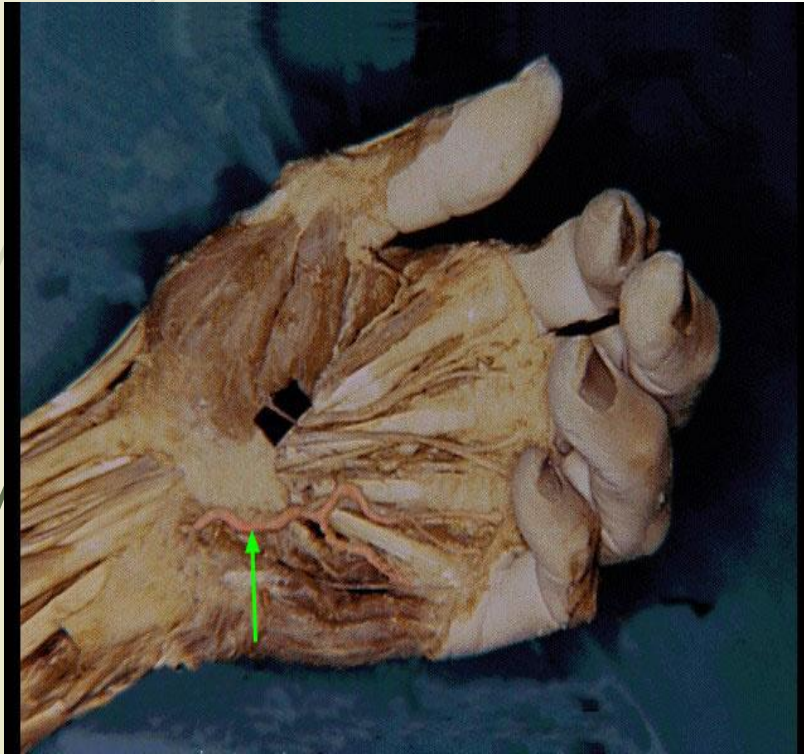The superficial palmar arch

- The **superficial palmar arch** mainly is fed by the ulnar artery passing superficial to the flexor retinaculum, then curving laterally to form an arch, lying just deep to the palmar aponeurosis.
- a) About one *third* of the superficial palmar arch is formed by *ulnar artery* alone.
- b) A further *third* is completed by the superficial palmar branch of the radial artery.
- c) A *third* is completed by the *a. radialis indicis*, or a branch of the *a. princeps pollicis*, or by the median artery.

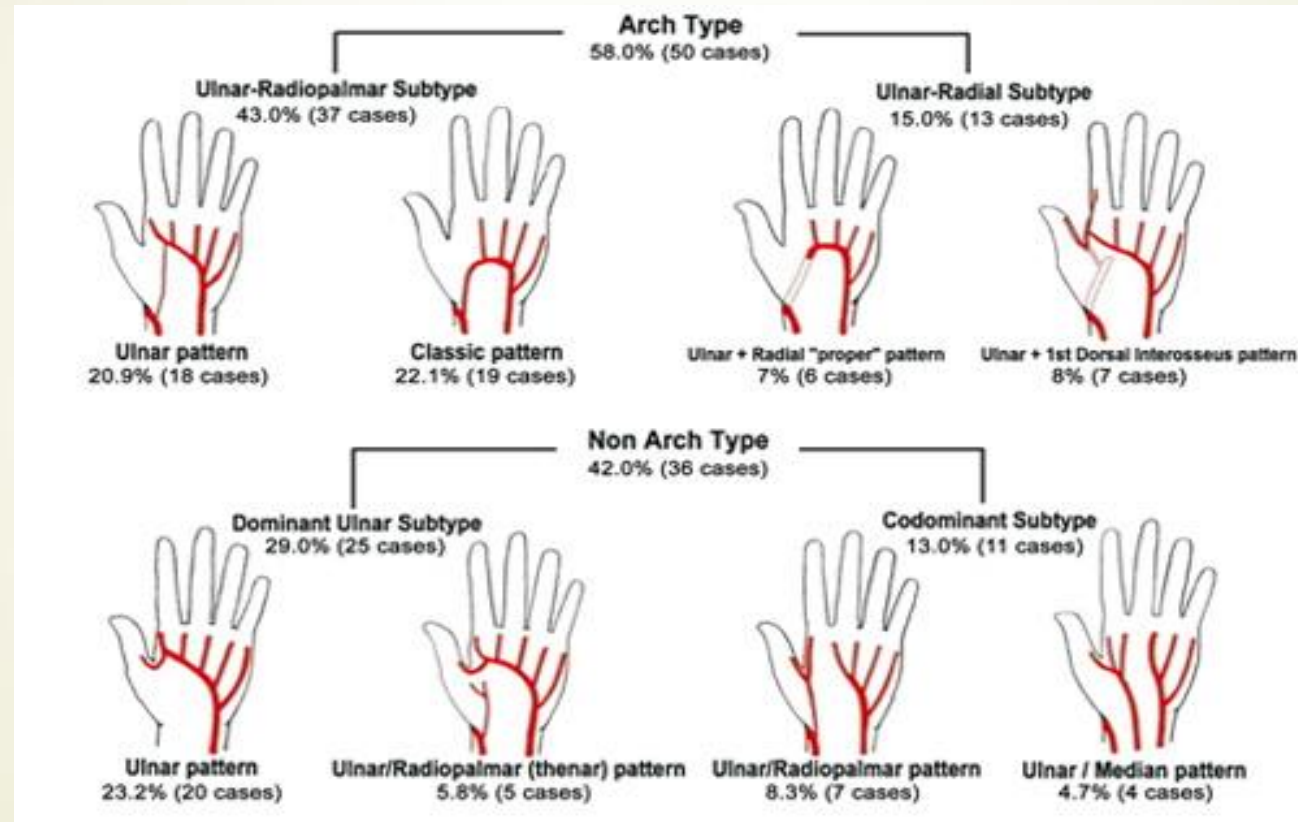
Superficial palmar arch (arch type)



Superficial palmar arch (non-arch type)

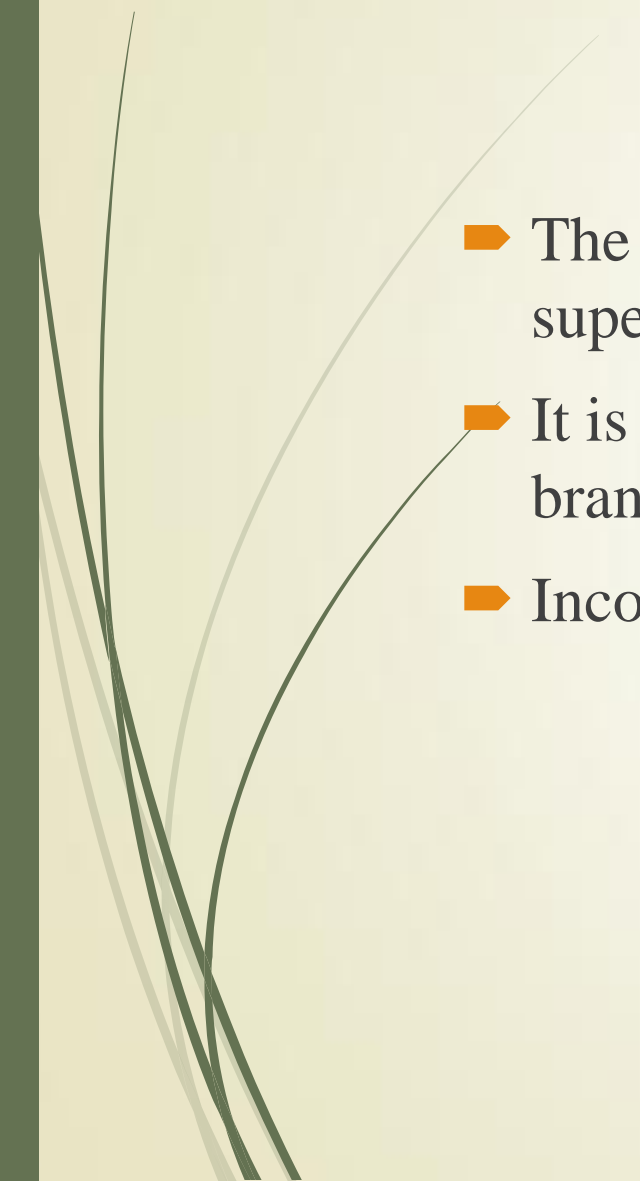


Superficial palmar arch

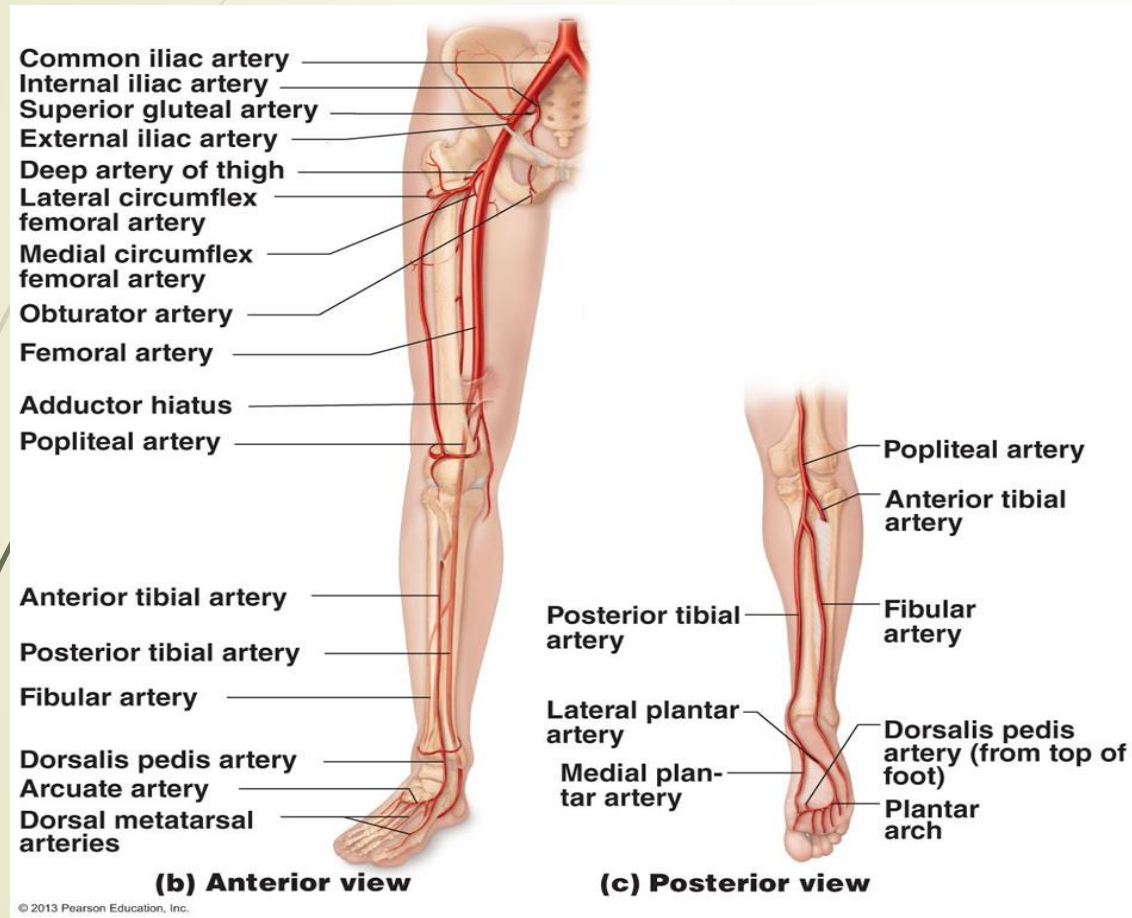




The deep palmar arch

- ▶ The **deep palmar arch** is found to be less variable as compared to superficial palmar arch.
 - ▶ It is formed by the radial artery which anastomoses with the deep palmar branch of the ulnar artery.
 - ▶ Incomplete arch is found in 3% of cases.
- 

The arteries of the lower limb



The main artery of the lower limb is **femoral artery**. It is a continuation of the **external iliac artery**. In the popliteal fossa it is known as **popliteal artery** which terminates by dividing into **anterior** and **posterior tibial arteries**.



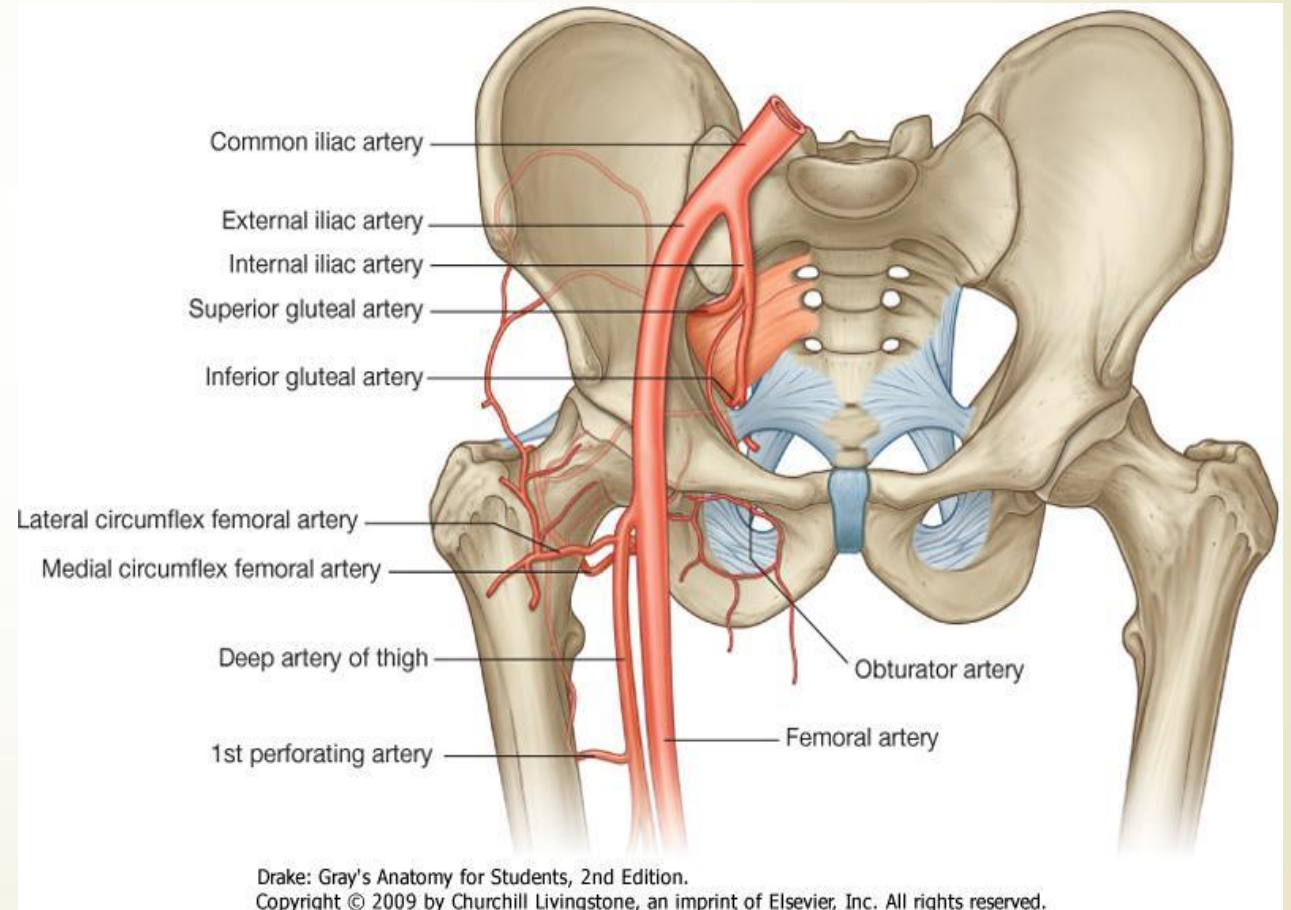
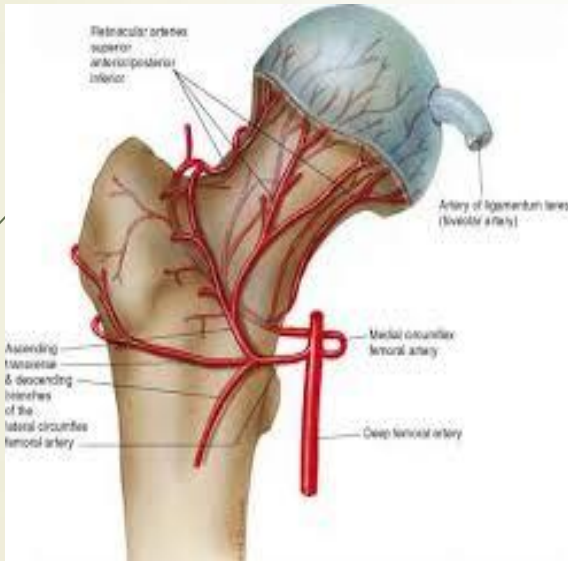
Arterial anastomoses of the lower extremity

- ▶ **Hip arterial anastomoses** (trochanteric and cruciate anastomoses);
- ▶ **Anastomosis around the knee joint** (genicular anastomosis);
- ▶ **Ankle and foot anastomoses.**

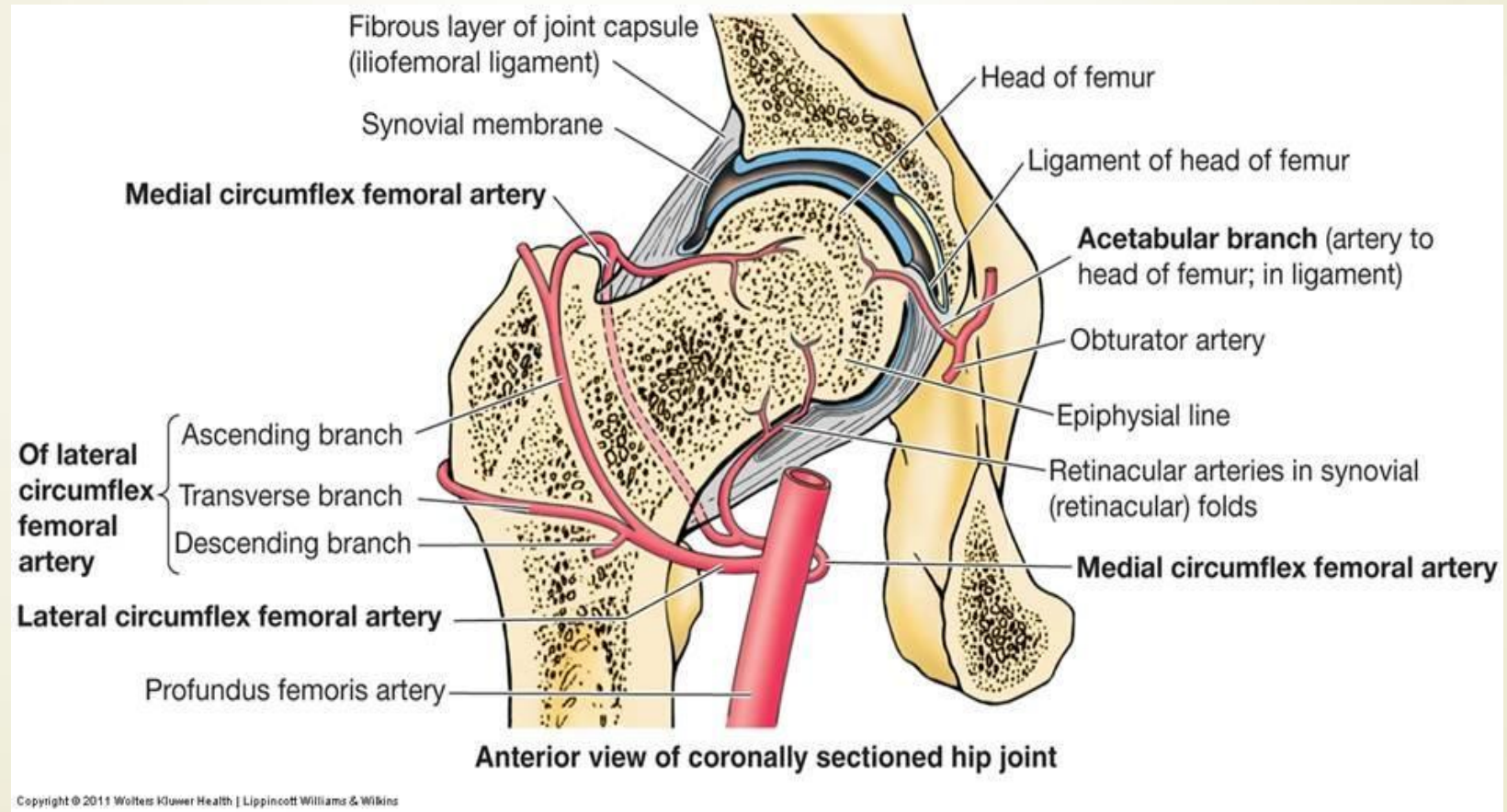
The hip arterial anastomoses

- The **trochanteric anastomosis** provides the main source of blood supply of the head of femur. It lies near the trochanteric fossa (at the greater trochanter) hence its name. It is formed by:
 - a) Descending branch of the superior gluteal artery (from the internal iliac artery);
 - b) Inferior gluteal artery (from the internal iliac artery);
 - c) Ascending branch of the lateral circumflex femoral artery (from the profunda femoris artery);
 - d) Ascending branch of the medial circumflex femoral artery (from the profunda femoris artery).

The trochanteric anastomosis



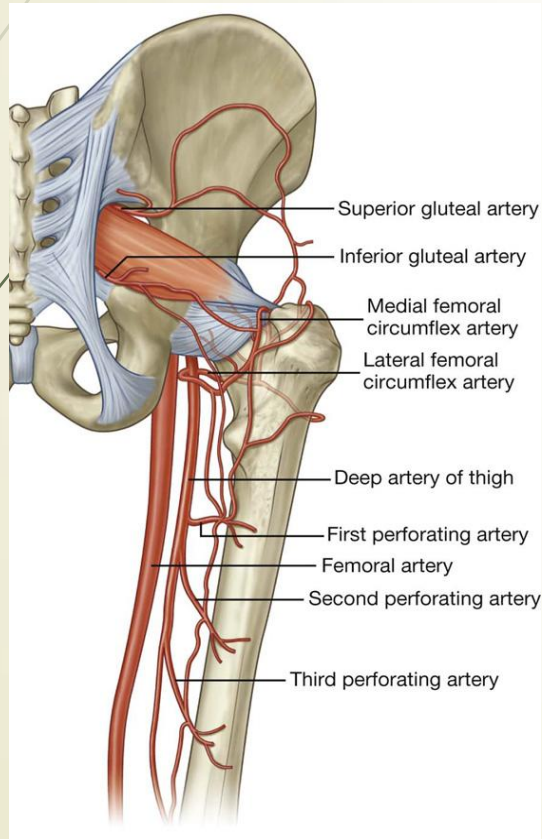
The trochanteric anastomosis



The cruciate anastomosis

- The **cruciate anastomosis** is located at the level of the lesser trochanter (cruciform in shape hence its name). It is formed by:
 - a) Transverse branch of the medial circumflex femoral artery (from the profunda femoris artery);
 - b) Transverse branch of the lateral circumflex femoral artery (from the profunda femoris artery);
 - c) Descending branch of the inferior gluteal artery (from the internal iliac artery);
 - d) Ascending branch of the first perforating artery (from the profunda femoris artery).

The hip arterial anastomoses



HIP JOINT 3

CAPSULE

Strong ++
 Anterior: Covers whole neck to intertrochanteric line
 Posterior: Covers neck half way to intertrochanteric crest
 Reflects: Back as retinaculum which carries the blood supply

1. Superior gluteal to trochanteric anastomosis only

2. Inferior gluteal

3,4. Lateral & medial circumflex femoral off profunda femoris supplying both anastomoses

5. Ascending branch of 1st perforator to cruciate anastomosis only

6. Art to head of femur

Trochanteric anastomosis

Cruciate anastomosis

Int iliac
 Obturator
 Ext iliac
 Femoral
 Profunda femoris

HIP ARTERIAL ANASTOMOSES

2 ANASTOMOSES

Trochanteric (at greater trochanter):
 Descending superior gluteal
 Inferior gluteal
 Ascending branches of medial & lateral circumflex femoral

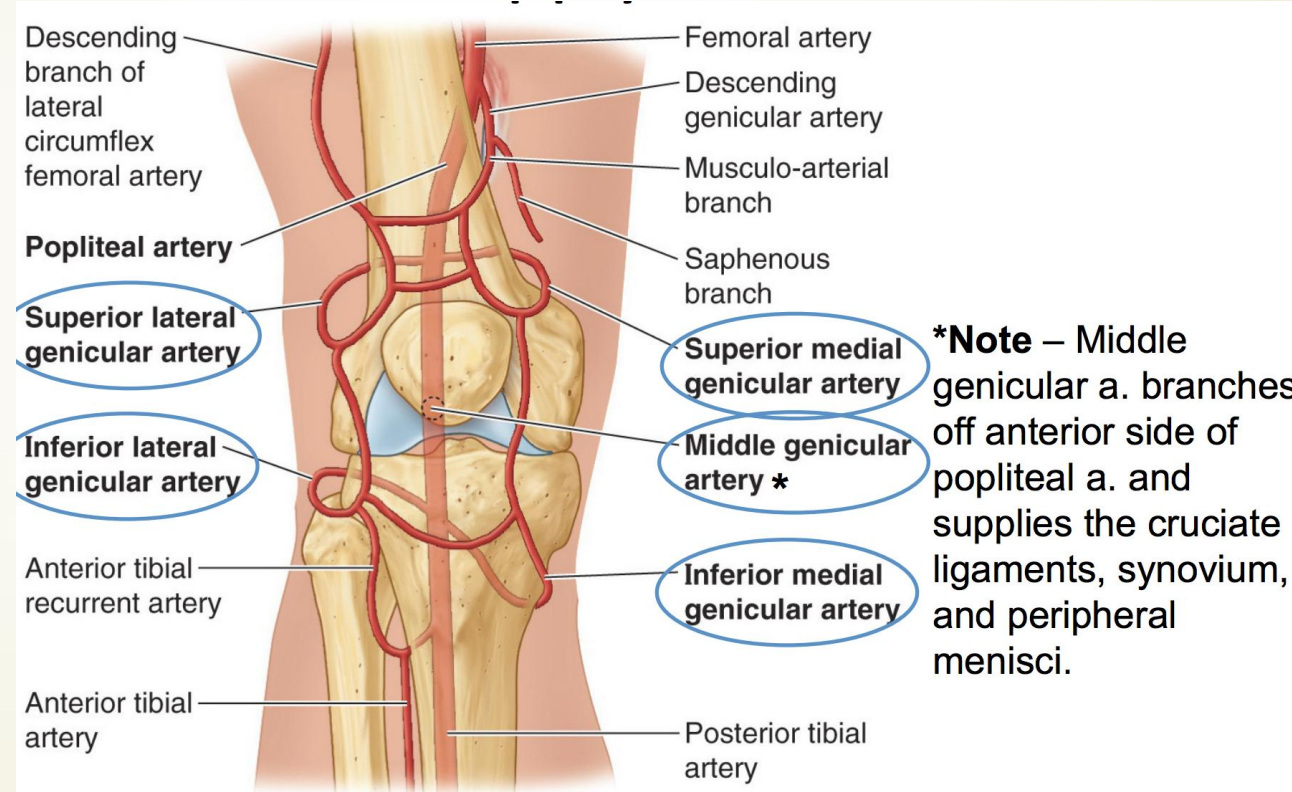
Cruciate (at lesser trochanter):
 Transverse branches of medial & lateral circumflex femoral
 Descending branch of inferior gluteal
 Ascending branch of 1st perforating artery

Mnemonic:
 Upper anastomosis does not receive branch from lowest artery,
 lower anastomosis does not receive branch from highest artery.

Anastomosis around the knee joint (genicular anastomosis)

- ▶ The genicular arteries participate in the formation of the important **genicular anastomosis** around the knee. (It compensates for the narrowing of the popliteal artery during the flexion of the knee.) It is formed by:
 - a) Descending genicular branch (from the femoral artery);
 - b) Descending branch of the lateral circumflex femoral artery (from the deep femoral artery);
 - c) Genicular arteries (from the popliteal artery);
 - d) Anterior and posterior recurrent tibial arteries (from the anterior tibial artery);
 - e) Circumflex fibular branch (from the posterior tibial artery).

Genicular anastomosis (*rete articulare genus*)



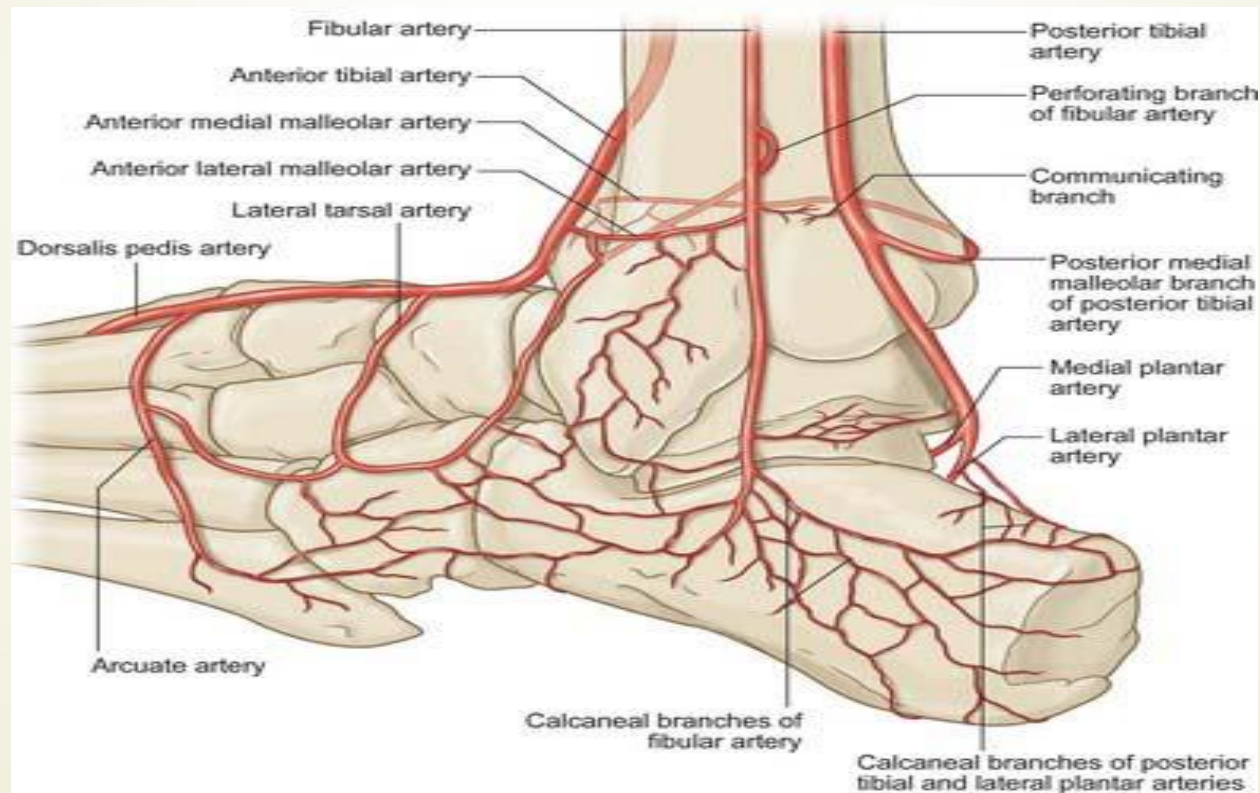
Anastomoses around the ankle joint

- ▶ **Rete malleolare mediale** (medial malleolar network):
 - a) Anterior medial malleolar artery (from the anterior tibial artery);
 - b) Medial malleolar branches (from the posterior tibial artery).

- ▶ **Rete malleolare laterale** (lateral malleolar network):
 - a) Anterior lateral malleolar artery (from the anterior tibial artery);
 - b) Lateral malleolar branches (from the peroneal artery);
 - c) Perforating branch of the peroneal artery;
 - d) Lateral tarsal artery (from the dorsalis pedis artery).

- e) **Rete calcaneum:**
 - f) Calcaneal branches of the peroneal artery;
 - g) Calcaneal branches of the posterior tibial artery.

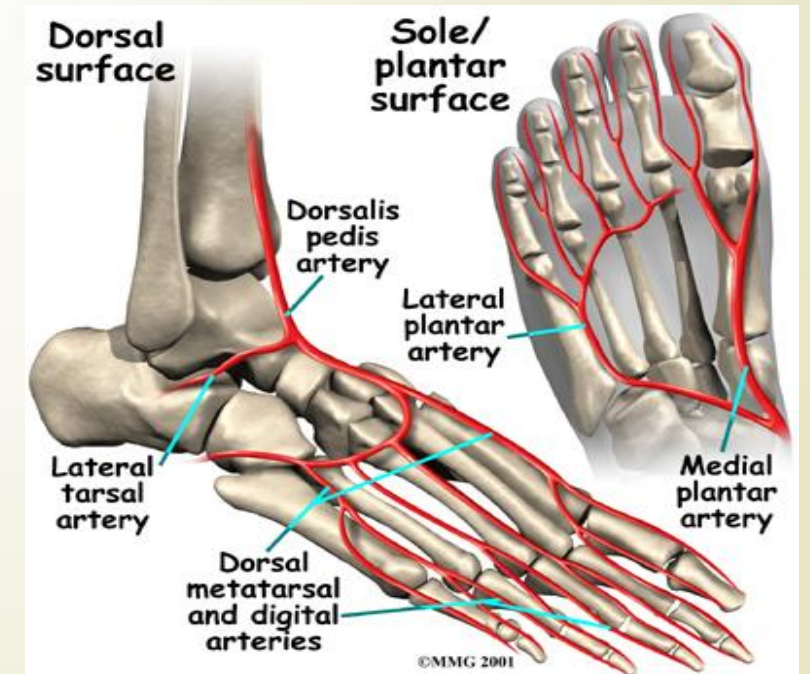
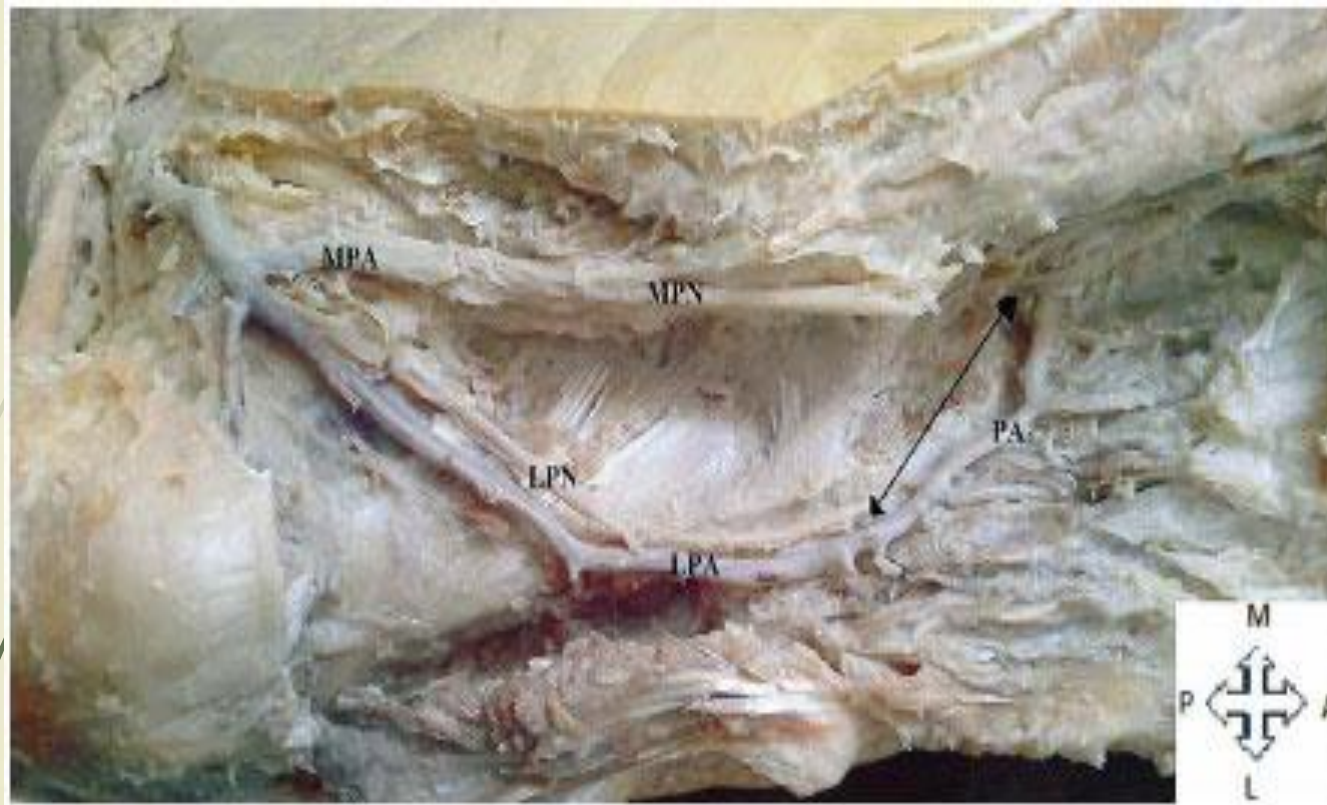
Anastomoses around the ankle joint



Plantar arches

- ▶ The **posterior tibial artery** is the larger of the terminal branches of the popliteal artery that terminates by bifurcating into medial and lateral plantar arteries.
- ▶ The **lateral plantar artery** is the larger terminal branch of the posterior tibial artery. At the base of the 5th metatarsal bone it curves medially to form the (deep) **plantar arch**.
- ▶ The plantar arch is completed by the **deep plantar branch** from the **dorsalis pedis artery**.
- ▶ The plantar arch gives rise to the plantar metatarsal arteries, plantar digital arteries and three perforating arteries (which anastomoses with the dorsalis pedis artery).

Plantar arch

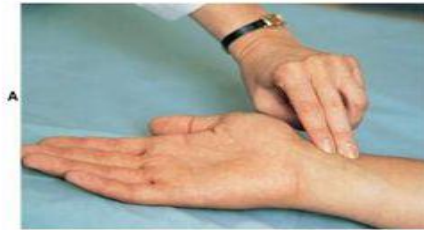

Determining the arterial pulse on the lower limbs

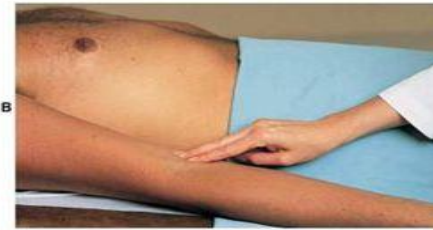- ▶ **Femoral pulse** can be palpated just inferior to the inguinal ligament and midway between the anterior superior iliac spine and pubic tubercle.
- ▶ **Popliteal pulse** is best felt in the inferior part of the popliteal fossa, where the artery is related to the tibia. (Weakening or loss of the popliteal pulse is a sign of femoral artery obstruction.)
- ▶ **Posterior tibial pulse** is taken postero-inferior to the medial malleolus. (Palpation of the posterior tibial pulse is essential for examining patients with occlusive peripheral arterial diseases.)
- ▶ **Dorsalis pedis pulse** is easy to be felt (being subcutaneous) over the tarsal bones between the tendons of the extensor hallucis longus and the extensor digitorum longus. (A diminished or absent dorsalis pedis pulse usually suggests vascular insufficiency resulting from arterial disease.)

Determining the arterial pulse on the lower limbs

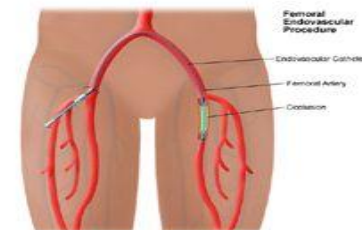
Palpation of arterial pulses



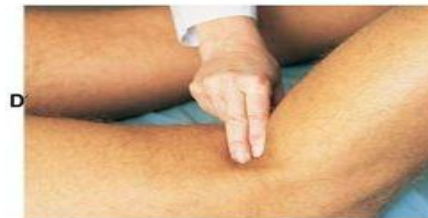Radial



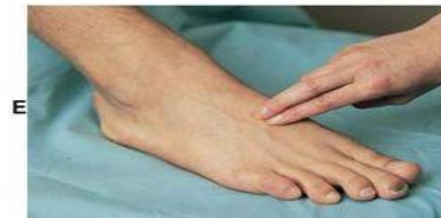Brachial



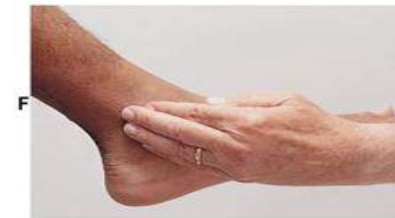Femoral



Popliteal



Dorsalis pedis



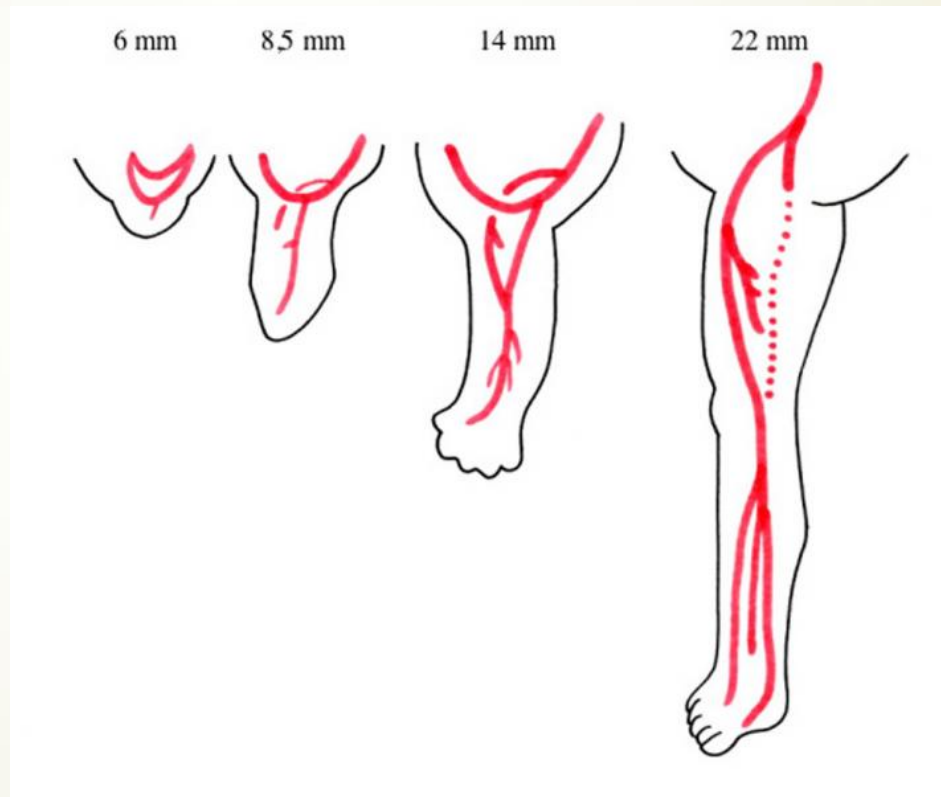
Posterior tibial



Development of the arteries of the lower limbs


- ▶ During the embryological development, the lateral branch of the 5th lumbar intersegmental artery forms the **axial artery** of the lower limbs, named **sciatic artery**.
- ▶ The most proximal segment of the **sciatic artery** usually disappear; however the medium and distal segments persist and form the definitive **popliteal** and **peroneal arteries**.
- ▶ By the 14-mm embryonic stage (7th week), the **external iliac artery** and its continuation the **femoral artery** grows towards the thigh and joins the part of the sciatic artery, which lies in the popliteal fossa.
- ▶ The **anterior and posterior tibial arteries** originate from the popliteal artery.

Development of the arteries of the lower limbs





Variations of the arterial patterns in the lower limb

- ▶ The primary artery of the thigh, in mammals, was the **ischiodic (sciatic) artery** accompanying the ischiadic (sciatic) nerve and that the **femoral artery** later took on that function.
 - ▶ In case of **persistence** of the embryonal axial artery (**ischiodic or sciatic artery**) its representative, the *inferior gluteal artery* continuous downward to supply the leg and foot, and the *femoral artery* ends at the knee.
- 

Persistent sciatic artery

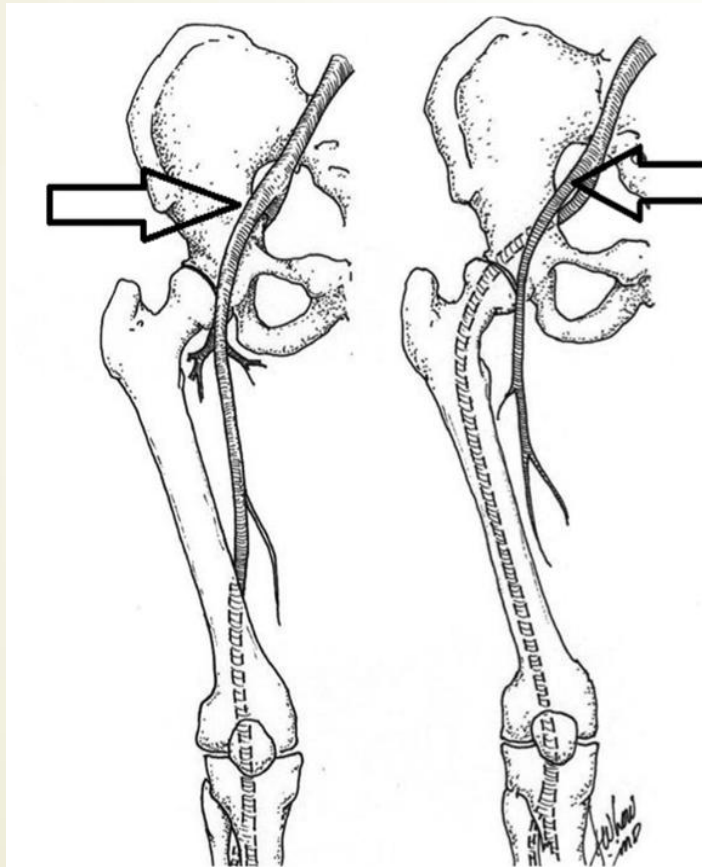
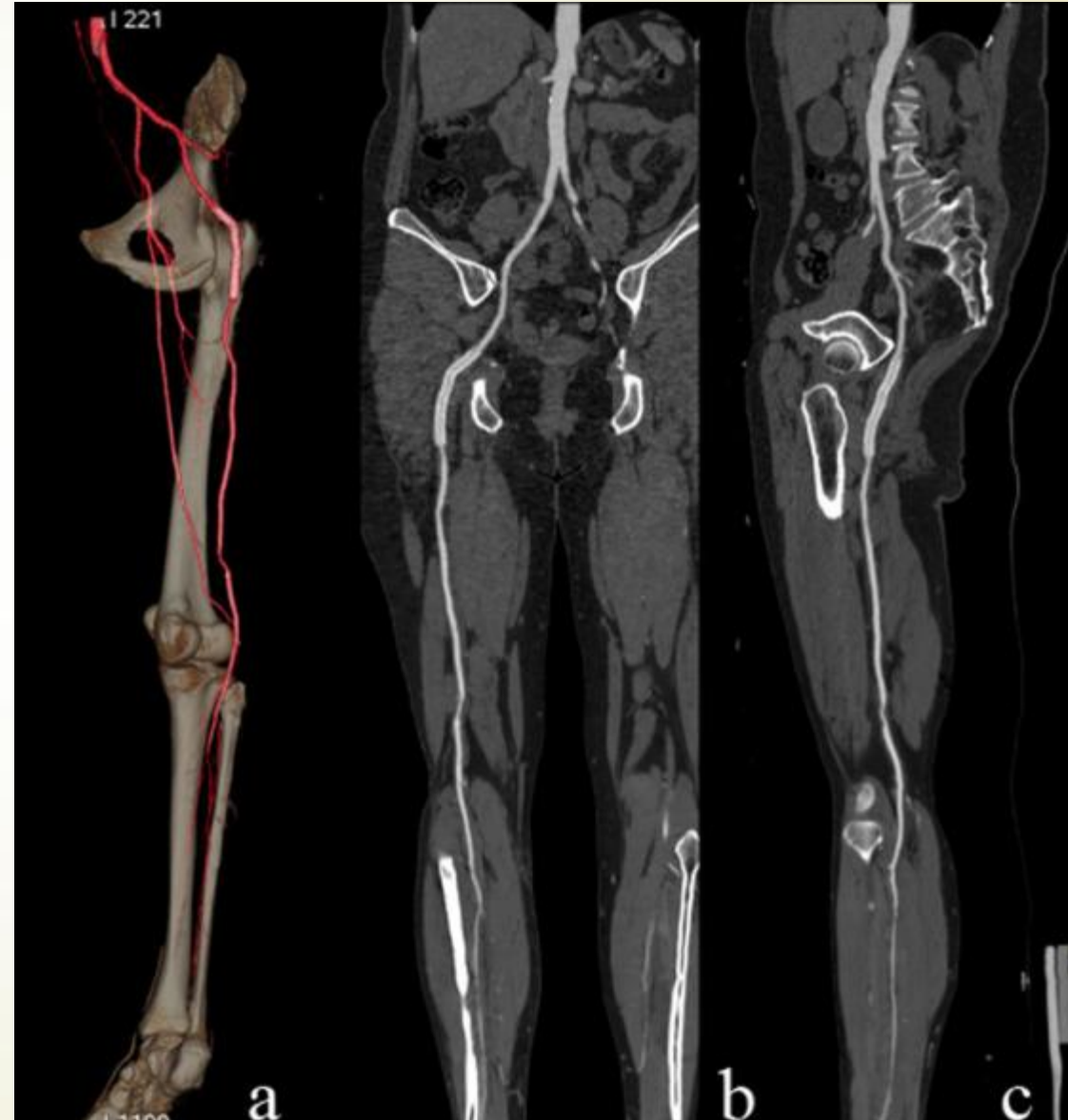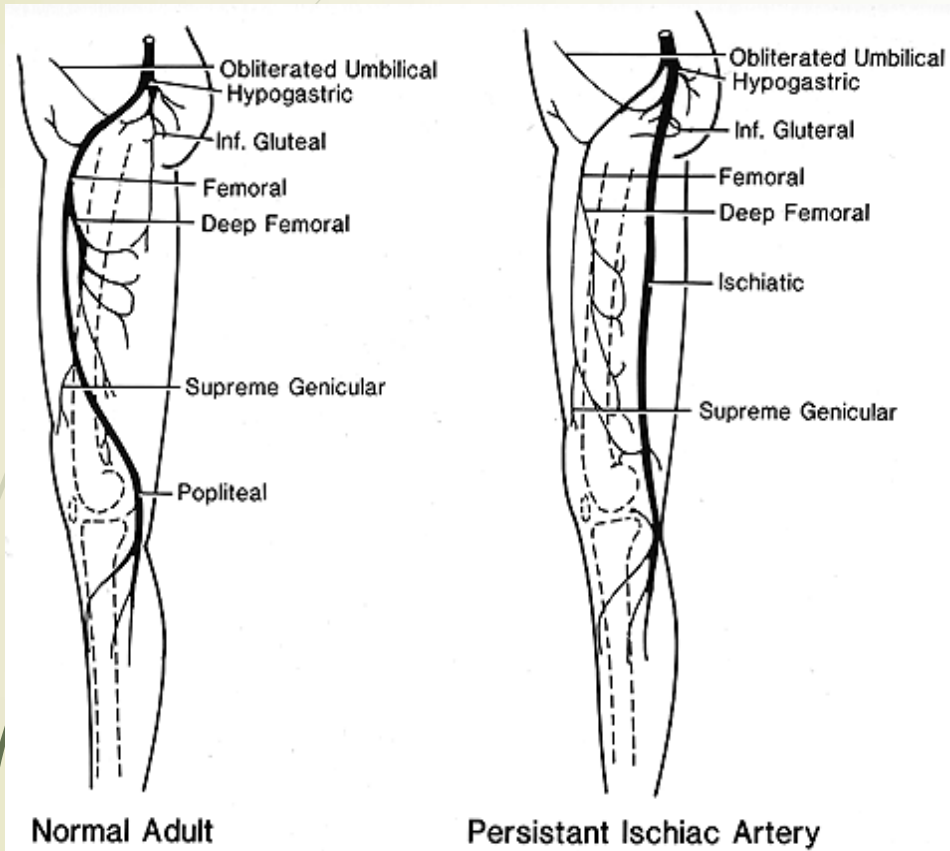


Figure 4. Left panel demonstrating the "usual" anatomy of the external iliac artery; superficial femoral artery and the profunda femoral artery. The right panel demonstrates the persistent sciatic artery and the absence of the external iliac artery.


A **persistent sciatic artery** is a rare vascular anomaly where there is a continuation of the *internal iliac artery* into the thigh through the greater sciatic foramen. It may be the dominant artery supplying the leg, in which case the superficial femoral artery may be small.

Persistent sciatic artery





Variations of the arterial patterns in the lower limb

- ▶ A **doubling** of the **femoral artery** may occur below the origin of the deep femoral artery; the doublet vessels may reunite in the distal thigh.
 - ▶ The **great saphenous artery** courses between adductor magnus and vastus medialis, pierces the crural fascia below the knee, and runs with the saphenous vein to the medial malleolus or end at the knee.
 - ▶ The **fourth perforating artery** sometimes splits distally into an **anterior** and **posterior tibial arteries**.
- 

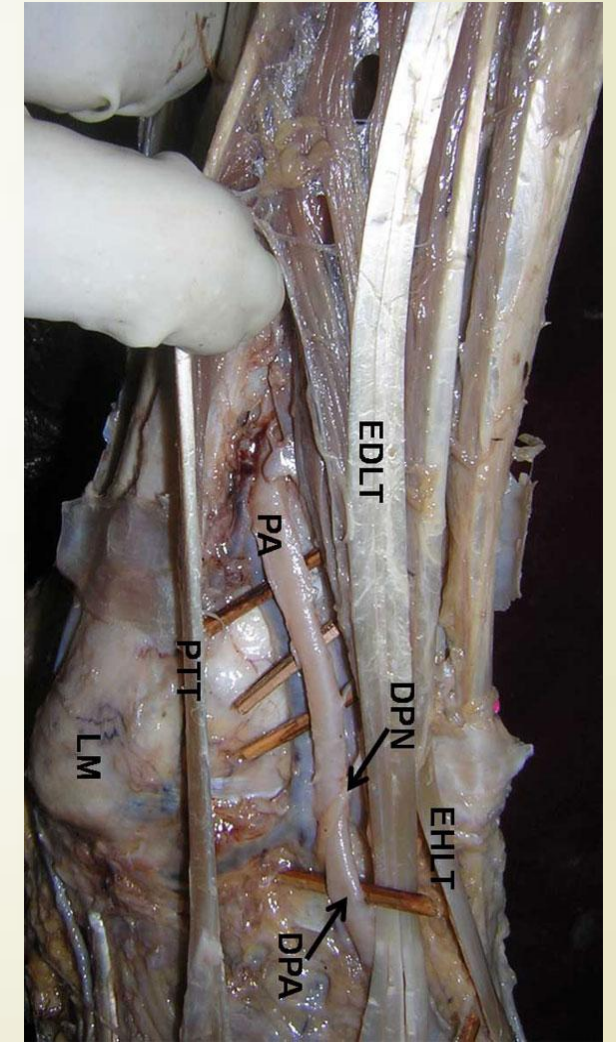
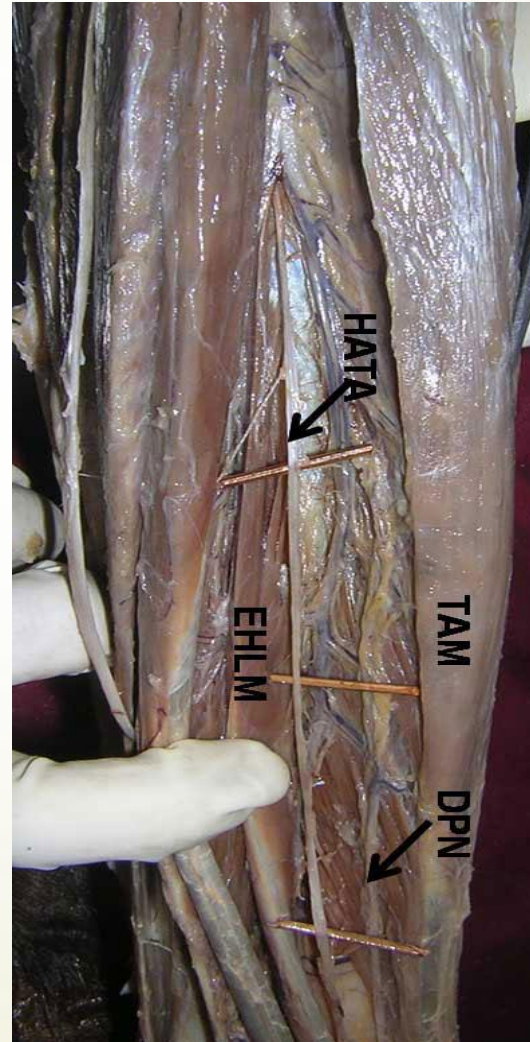


Variations of the arterial patterns in the lower limb

- ▶ **Tibial artery anomalies** are present in about 3% to 10% of the population.
- ▶ The most frequent are **`high` bifurcation** or true **trifurcation** of the **popliteal artery**; common origin of the anterior tibial and peroneal arteries; and **hypoplasia** or **absence** of the anterior or posterior tibial arteries.
- ▶ The continuation of the **peroneal (fibular) artery** as **dorsalis pedis artery** is a rare finding. However, the anterior tibial artery is hypoplastic in this case.


Variations of the arterial patterns in the lower limb

- ▶ The hypoplastic anterior tibial artery.
- ▶ The peroneal (fibular) artery continuous as **dorsalis pedis** artery.



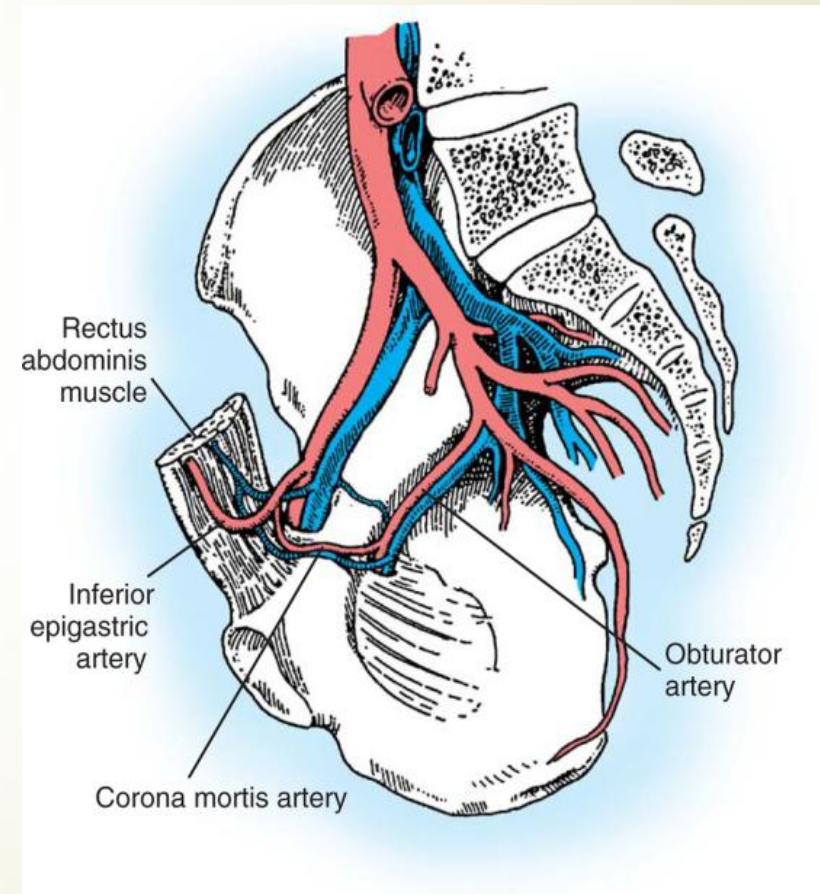


Variations of the arterial patterns in the lower limb

- ▶ The **posterior tibial artery** may be absent, rudimentary or replaced by the peroneal (fibular) artery.
 - ▶ The **plantar arch** may be double or absent in which case the plantar tissues of the foot are supplied by a single artery, **posterior tibial artery**.
 - ▶ Rarely, in the absence of the posterior tibial artery, the **peroneal artery** develops into the medial and lateral plantar arteries.
- 

`Corona mortis` or `crown of death`

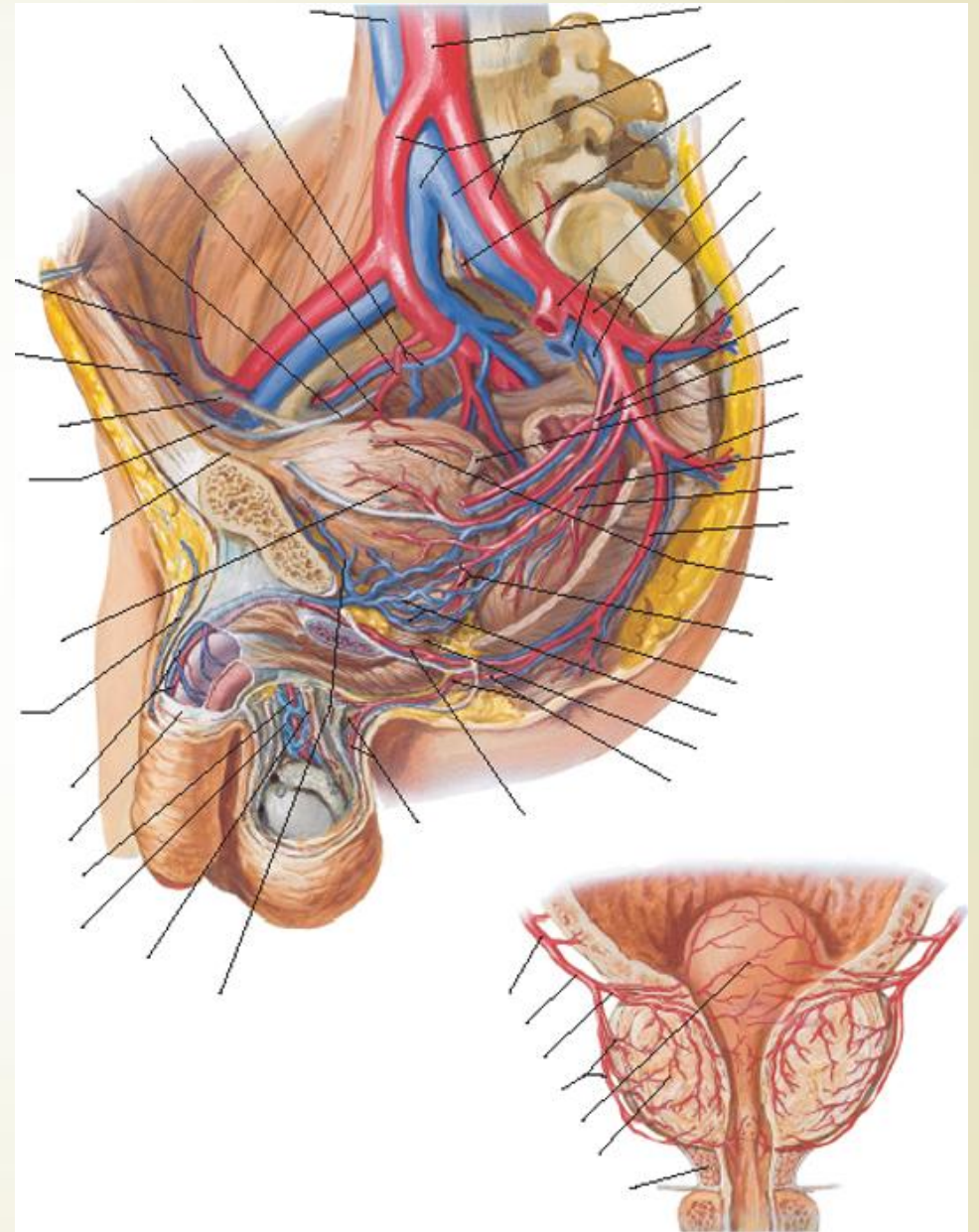
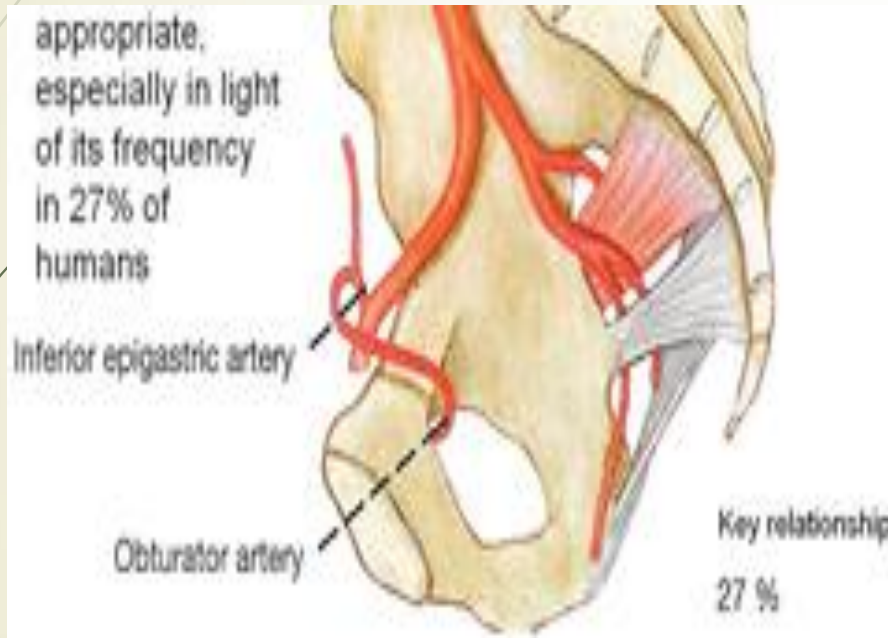
- ▶ *Corona mortis*, Latin for *crown of death* is a common variant vascular anastomosis between the external iliac artery or **inferior epigastric artery** with the **obturator artery**.
- ▶ It is important for femoral hernia anatomy and surgery.



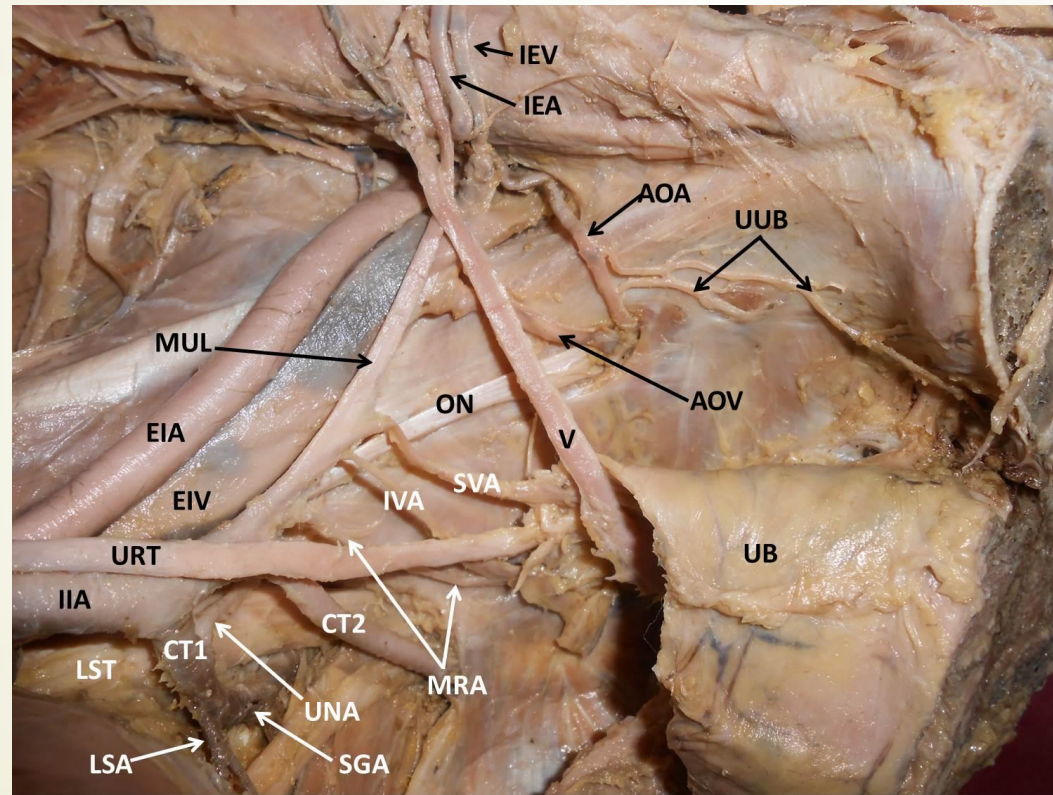
`Corona mortis`

- ▶ In some cases, the `**corona mortis`** is the actual obturator artery that arises from the inferior epigastric artery instead of the internal iliac artery.
- ▶ It can also arise from the external iliac artery. In both cases it has been called an `**aberrant obturator artery`**.
- ▶ This anatomical variation can be present in up to 25% of cases.
- ▶ When present it can be injured when a surgeon looks to enlarge the femoral ring by opening the lacunar ligament.

Aberrant obturator artery



Aberrant obturator artery



Thank you!

