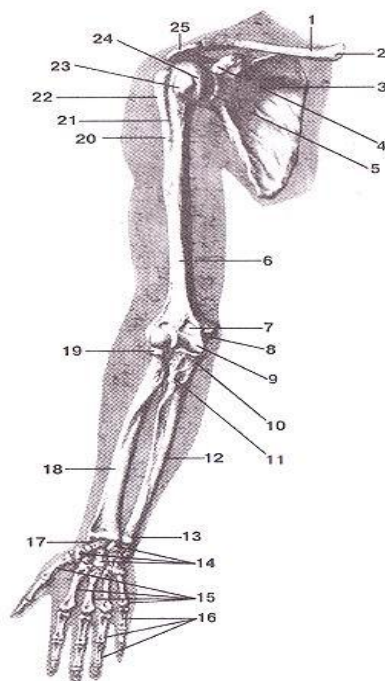


Государственное бюджетное образовательное учреждение высшего
профессионального образования
«Иркутский государственный медицинский университет»
Министерства здравоохранения Российской Федерации

Department of Operative Surgery and Topographic Anatomy

G.I. Songolov, O.P. Galeeva, S.N. Redkov

Clinical anatomy of the upper extremity



Teaching aid

Иркутск

ИГМУ
2016

УДК [616-089.87(075.8)

ББК 54.54я73.

C 60

Recommended by faculty methodological council of medical department of SBEI HE ISMU The Ministry of Health of The Russian Federation as a teaching aid for independent work of foreign students from medical faculty, faculty of pediatrics, faculty of dentistry, protocol № 01.02.2016.

Authors:

- G.I. Songolov** - associate professor, Head of Department of Operative Surgery and Topographic Anatomy, PhD, MD SBEI HE ISMU The Ministry of Health of The Russian Federation
- O. P.Galeeva** - associate professor of Department of Operative Surgery and Topographic Anatomy, MD, PhD SBEI HE ISMU The Ministry of Health of The Russian Federation
- S. N. Redkov** – assistant of department of Operative Surgery and Topographic Anatomy SBEI HE ISMU The Ministry of Health of The Russian Federation.

Reviewers:

- E.V. Gvildis** - head of department of foreign languages with the course of the Latin and Russian as foreign languages of SBEI HE ISMU The Ministry of Health of The Russian Federation, PhD,
- L.V. Sorokina** - associate Professor of Department of Anesthesiology and Reanimation at ISMU, PhD, MD

Songolov G.I

C 60 Clinical anatomy of upper extremity: teaching aid / Songolov G.I, Galeeva O.P, Redkov S.N; State budget educational institution of higher education of the Ministry of Health and Social Development of the Russian Federation; "Irkutsk State Medical University" of the Ministry of Health and Social Development of the Russian Federation Irkutsk ISMU, 2016, 37 p.

Clinical anatomy of upper extremity is one of the important sections in topographic anatomy. The teaching manual is intended for foreign students of medical faculty, faculty of pediatrics, faculty of dentistry of USMU.

УДК [616-089 (075.8)

ББК 54.54я73

© Сонголов Г.И., Галеева О.П, Редков С.Н, Юдин А.А,
© ГОУ ВПО ИГМУ Минздрава России, 2016

Contents

INTRODUCTION	4
GENERAL CHARACTERISTICS	5
TOPOGRAPHY OF THE SCAPULAR REGION.....	5
TOPOGRAPHY OF THE AXILLARY REGION.....	7
TOPOGRAPHY OF THE DELTOID REGION.....	10
TOPOGRAPHY OF THE SUBCLAVIAN REGION.....	11
TOPOGRAPHY OF THE ANTERIOR REGION OF THE ARM.....	12
TOPOGRAPHY OF THE POSTERIOR REGION OF THE ARM.....	14
TOPOGRAPHY OF THE ELBOW REGION.....	16
TOPOGRAPHY OF THE ANTERIOR CUBITAL REGION.....	17
TOPOGRAPHY OF THE POSTERIOR CUBITAL REGION.....	19
TOPOGRAPHY OF THE ANTERIOR REGION OF THE FOREARM.....	20
TOPOGRAPHY OF THE POSTERIOR REGION OF THE FOREARM.....	25
TOPOGRAPHY OF THE DORSAL REGION OF THE HAND.....	28
TOPOGRAPHY OF THE WRIST.....	28
TOPOGRAPHY OF THE FINGERS.....	30
TEST.....	34
TEST ANSWERS.....	38

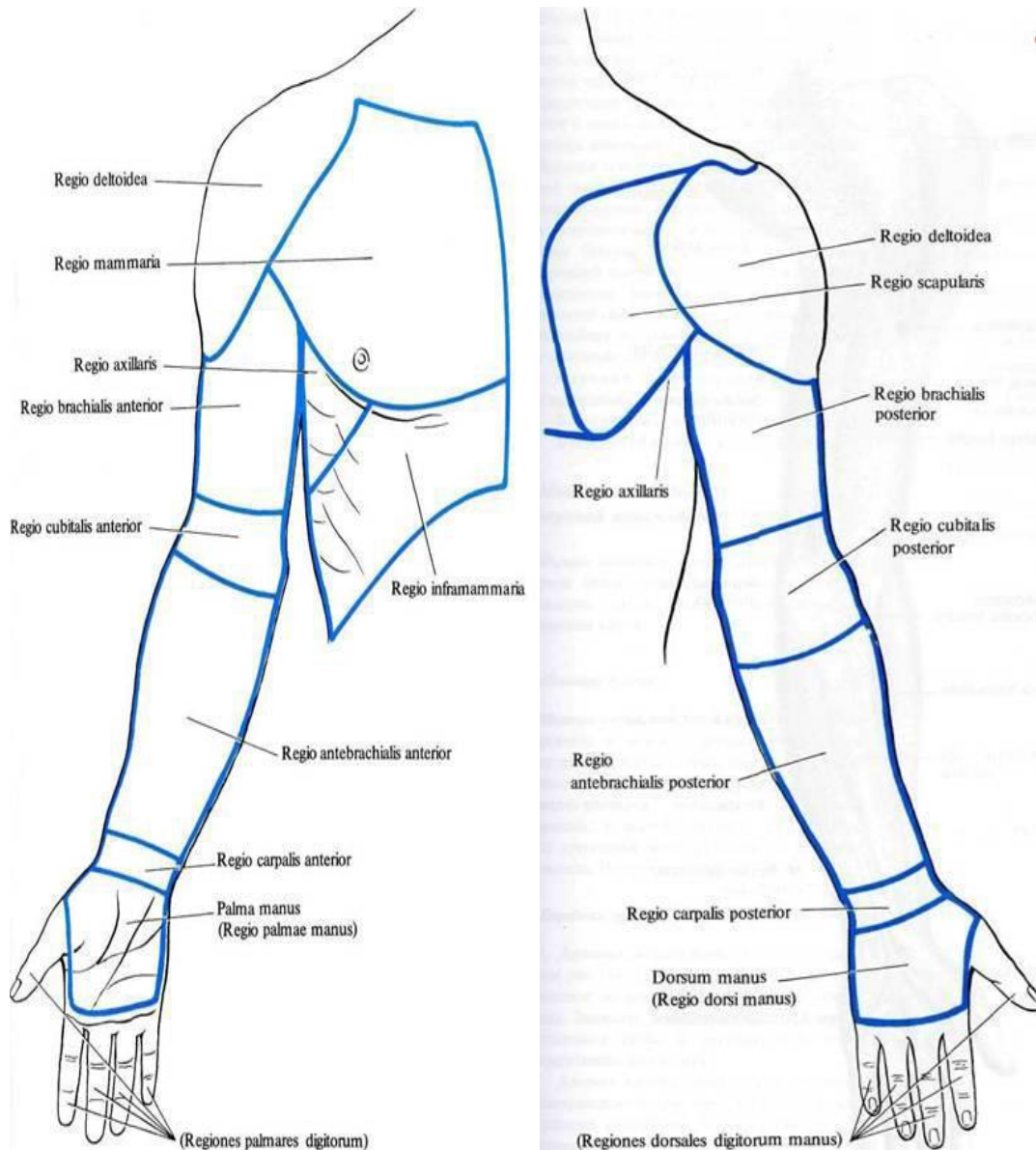
INTRODUCTION

In this manual you can find the materials, used in learning the theme: “Topography of the upper extremity”. The objective of this is the formation of the holistic picture of the targeting and projection anatomy of the upper extremity. This manual is a useful source of knowledge of the lower extremity’s regional clinical anatomy. The student, who read attentively will find for himself the necessary anatomoco-clinical connections, that in the future will help in his independent work.

The formation of holistic view of morphofunctional relations in the organism is tightly connected with anatomico-clinical characteristic of the concrete region of the human’s body. The importance of this cannot be overemphasized because it is necessary for a doctor to have the knowledge and the skill to be professionally oriented in the spatial and structural organization of the biological object discredited by the disease or trauma.

GENERAL CHARACTERISTICS

The upper extremity is divided into the following regions: scapular region, deltoid region, infraclavicular region, axillary region, anterior and posterior regions of the arm, anterior and posterior elbow regions, anterior and posterior regions of the forearm, wrist region, palmar and dorsal regions of the hand.



TOPOGRAPHY OF THE SCAPULAR REGION

Landmarks: acromion, superior angle of the scapula, inferior angle of the scapula.

Borders:

Superior – horizontal line drawn through the acromion . Inferior – horizontal line

drawn through the inferior angle of the scapula. Lateral – vertical line drawn through the acromion. Medial – medial margin of the scapula.

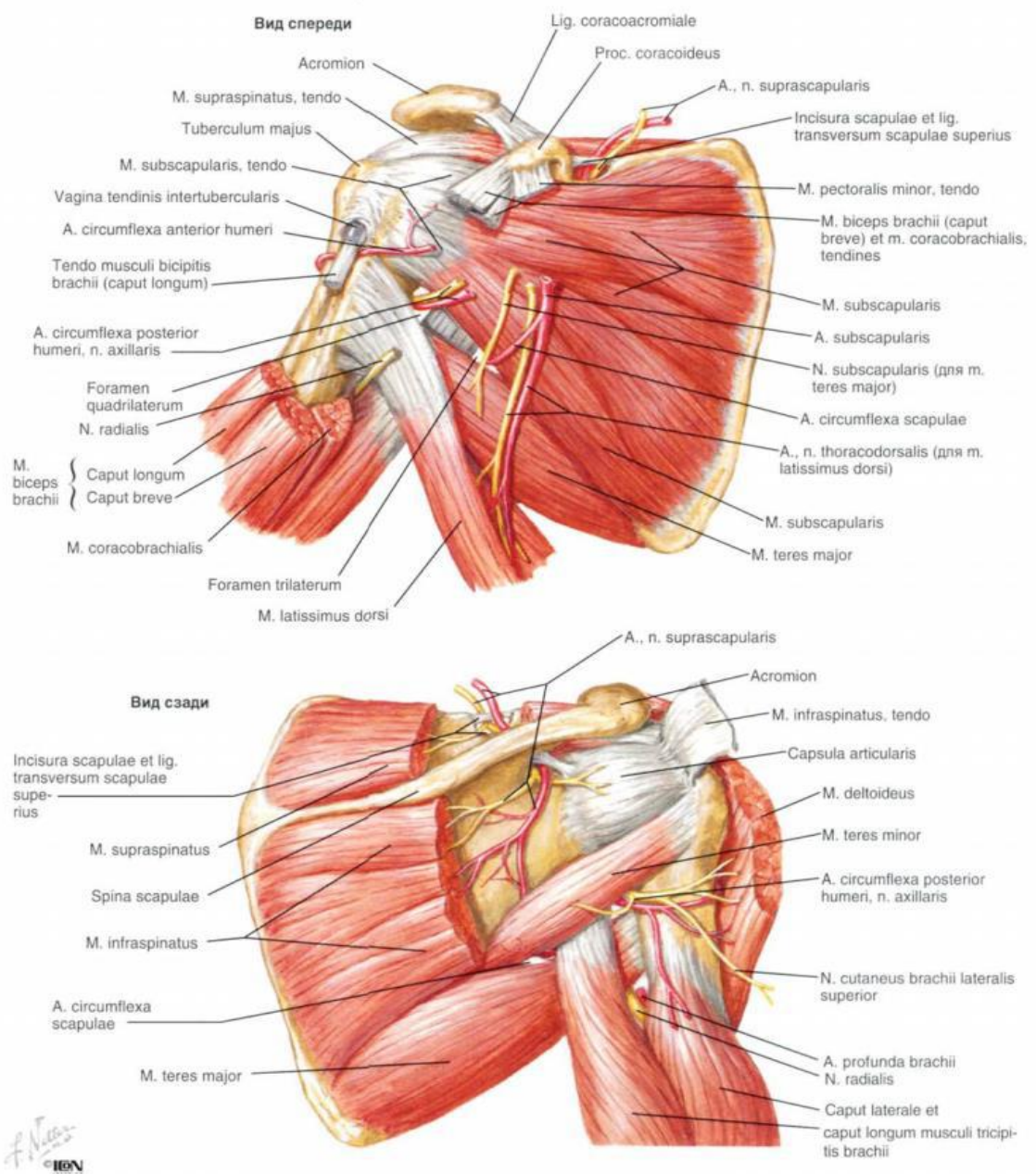
Layers:

Skin: it is thick with limited movement. It is innervated by the superior lateral cutaneous nerve of the arm.

Subcutaneous tissue.

Superficial fascia: it is dense and consists of many layers. It contains the fibrous tissues which connect the subcutaneous tissue and are fixed to the skin. That is why the skin has limited movement. It contains fat and cutaneous nerve.

Deep fascia: it consists of 2 layers: superficial layer covers the latissimus dorsi and trapezius muscles. Deep layer covers the supraspinatus, infraspinatus, teres major and teres minor muscles.



SCAPULAR ARTERIAL NETWORK

Anastomosis around the scapula occurs in 3 fossae:

1. Supraspinous fossa. 2. Infraspinous fossa. 3. Subscapular fossa.

It is formed by: *suprascapular artery* (branch of the thyrocervical artery of the subclavian artery), *dorsal scapular artery*/ deep branch of the transverse cervical artery; *circumflex scapular artery*.

To provide collateral circulation when the subclavian artery or axillary artery is blocked/ damaged. To help preserve the upper limb during injury. Anastomosis over the acromion : acromial branch of the thoracoacromial artery; acromial branch of the suprascapular artery; acromial branch of the posterior circumflex humeral artery.

TOPOGRAPHY OF THE AXILLARY REGION

Landmarks:

Outlines of the pectoralis major, latissimus dorsi and coracobrachialis muscles; axillary fossa is shown by lifting up the upper extremity.

Borders: anterior- lower margin of the pectoralis major muscle; posterior – lower margin of the latissimus dorsi muscle; medial – line connecting the margin of the pectoralis major and latissimus dorsi muscles along the sagittal section of the lateral surface of the thorax at the level of the 3rd rib; lateral – line connecting the margin of the pectoralis major and latissimus dorsi muscles on the medial surface of the arm.

Layers:

Skin: it is thin and easily movable. It contains the suspensory ligament of the axilla. It separates and forms the pectoral fascia anteriorly, thoracolumbar fascia posteriorly and brachial fascia laterally.

Axillary cavity:

Borders:

Anterior – pectoralis major muscle and clavipectoral fascia. Posterior – subscapularis, latissimus dorsi, teres major muscles. Medial – thoracic wall, serratus anterior muscle and 1st until 4th intercostal muscles. Lateral – surgical neck of the humerus, short head of the biceps brachii muscle and coracobrachialis muscle.

Contents: axillary is divided into 3 parts and gives branches according to:

clavipectoral triangle (thoracoacromial artery, arteria thoracica suprema, lateral and medial pectoral nerves); pectoral triangle (lateral thoracic artery and long

thoracic nerve); subpectoral triangle(subscapular artery, anterior and posterior circumflex humeral arteries).

The axillary artery is in relation first with the posterior and then with the outer wall of the axillary cavity. The pulsations of the vessel may be distinctly felt to the inner side of the prominence caused by the coracobrachialis muscle; this is the situation in which the artery may be most safely ligated by elevating the arm and keeping close to the border of the muscle. The vessel is comparatively close to the shoulder-joint and is sometimes torn across in dislocations or in attempts at their forcible reduction. The branches of the axillary artery are:

1. The acromiothoracic

2. The subscapular, which arises from about the middle of the axillary and consequently at the mid-point between the clavicle and the lower border of the pectoralis major muscle, in which latter situation the axillary becomes the brachial. *The subscapular artery* divides into two chief branches, the *dorsalis scapula* and the *thoracodorsalis* .

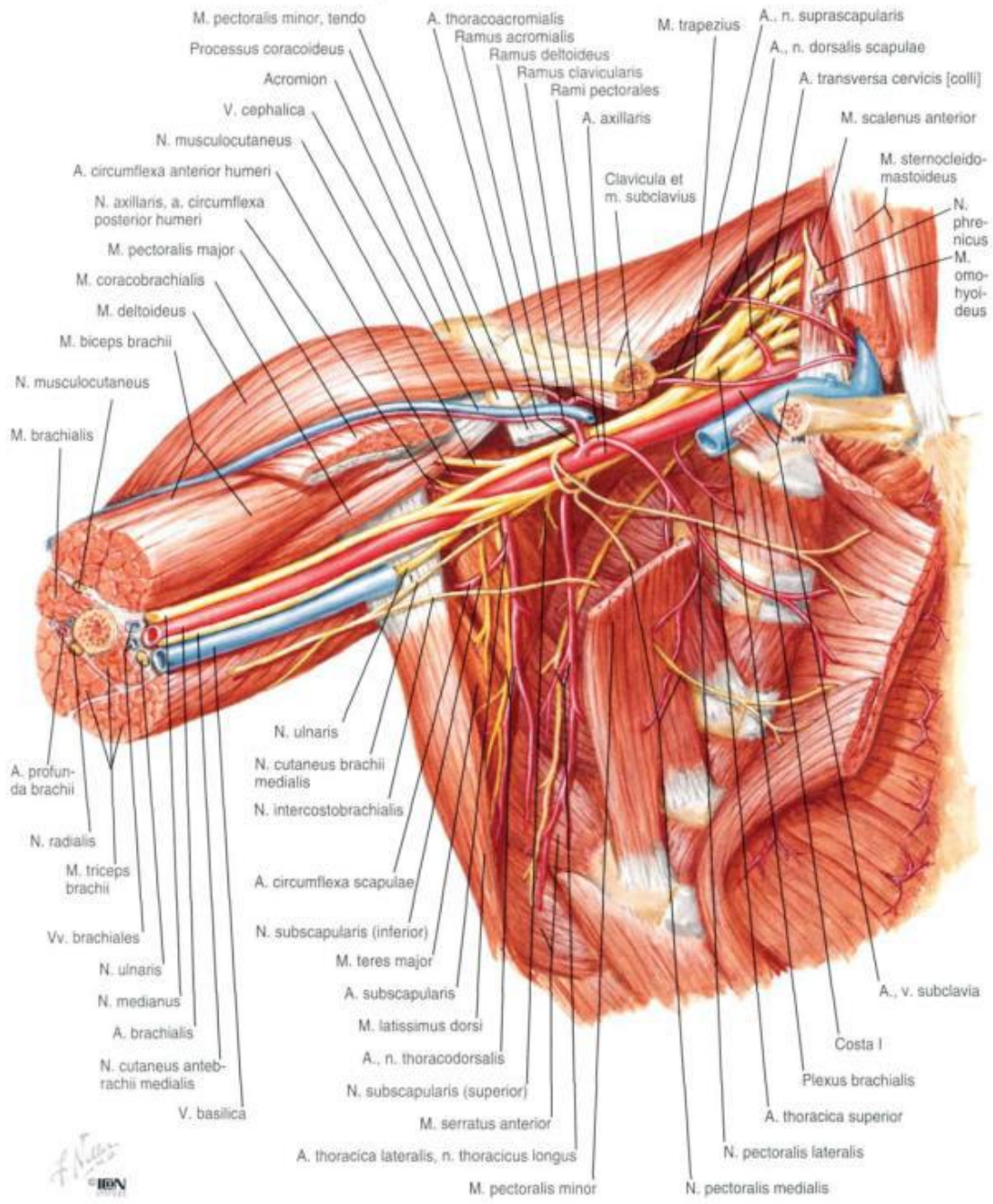
The dorsalis scapula runs over the external border of the scapula to the dorsal surface of this bone, supplies the surrounding muscles, and anastomoses freely with the suprascapular branch of the subclavian. This is the main path for the collateral circulation when the blood-current in the axillary artery is interfered with or when this vessel is ligated. *The thoracodorsalis* is the largest vessel of the lateral thoracic wall. It runs down the axillary border of the scapula, under cover of the edge of the latissimus dorsi, and particularly supplies the teres major, the latissimus dorsi, and the serratus magnus muscles .

3. The long thoracic, an inconstant branch, which arises above the subscapular and is situated in front of the thoracic dorsalis.

4. The anterior circumflex, a small branch which runs outward over the anterior surface of the neck of the humerus.

5. The posterior circumflex, a large branch which arises beside the preceding one, passes through the quadrangular space close to the bone to run posteriorly with the circumflex nerve and, like it, to particularly supply the deltoid muscle.

The axillary vein, like the subclavian, is situated in front and to the inner side of the artery; it consequently covers the artery to a varying extent, dependent upon the degree of its distention. It is only in exceptional cases that the axillary vein is double.



Brachial plexus: lateral cord, posterior cord, medial cord.

Just beneath the clavicle the trunks of the brachial plexus, with the exception of a few small branches, are situated to the outer side of the vessel. Beneath the *pectoralis minor muscle* these trunks form three cords which are so arranged about this portion of the artery that we may differentiate an outer, an inner, and a posterior cord. The outer and inner cords supply chiefly the skin and muscles of the flexor surface, while the posterior cord supplies the extensors surface. A more detailed study of the axilla shows that the outer cord gives off the *musculocutaneous nerve* and the outer head of the median. From the inner cord

arises the inner head of the median which, together with the outer head, surrounds the axillary artery like the prongs of a fork; the inner cord also gives off the ulnar, the internal cutaneous, and the lesser internal cutaneous nerves. From the posterior cord arise the circumflex, the musculus spiral, and the subscapular nerves. Of the other branches of the brachial plexus there is one which is of particular importance from a surgical stand point; this is the long thoracic, the motor nerve of the serratus magnus muscle. It lies directly upon the serratus magnus, in association with *the thoracodorsalis artery*, and is covered by the edge of the latissimus dorsi; it is not particularly exposed to injury in operations in the axillary cavity. The comparatively superficial long or middle subscapular nerve running to the latissimus dorsi is more easily injured, and its division is followed by paralysis of this muscle. The other two subscapular nerves supply *the teres major and the subscapularis muscles* and are more deeply situated. The suprascapularis nerve, which runs through the subscapularis notch to the dorsal surface of the scapula and supplies the supraspinatus and infraspinatus muscles, is more rarely divided by the knife of the surgeon; the nerve filaments supplying the levator anguli scapulae and the rhomboid muscles are also rarely injured.

Axillary lymph nodes (5 groups): lateral axillary lymph nodes, central axillary lymph nodes, medial axillary lymph nodes, posterior axillary lymph nodes, apical axillary lymph nodes.

TOPAGRAPHY OF THE DELTOID REGION

Landmarks: anterior and posterior margins of the deltoid muscle, clavicle, acromioclavicular joint, acromion, spine of the scapula.

Borders:

Superior – line drawn on the deltoid muscle from lateral 1/3 of the clavicle, acromion and lateral 1/3 of the spine of the scapula. Inferior – horizontal line drawn on the lower margin of the pectoralis major muscle and latissimus dorsi muscle. Anterior – anterior margin of the deltoid muscle. Posterior – posterior margin of the deltoid muscle.

Layers:

Skin: it is thick with limited movement. Upper half of the deltoid muscle: lateral supraclavicular nerve. Lower half of the deltoid muscle: superior lateral brachial cutaneous nerve.

Subcutaneous tissue with superficial fascia: it contains moderate amount of fat. It is divided by septa.

Deep fascia.

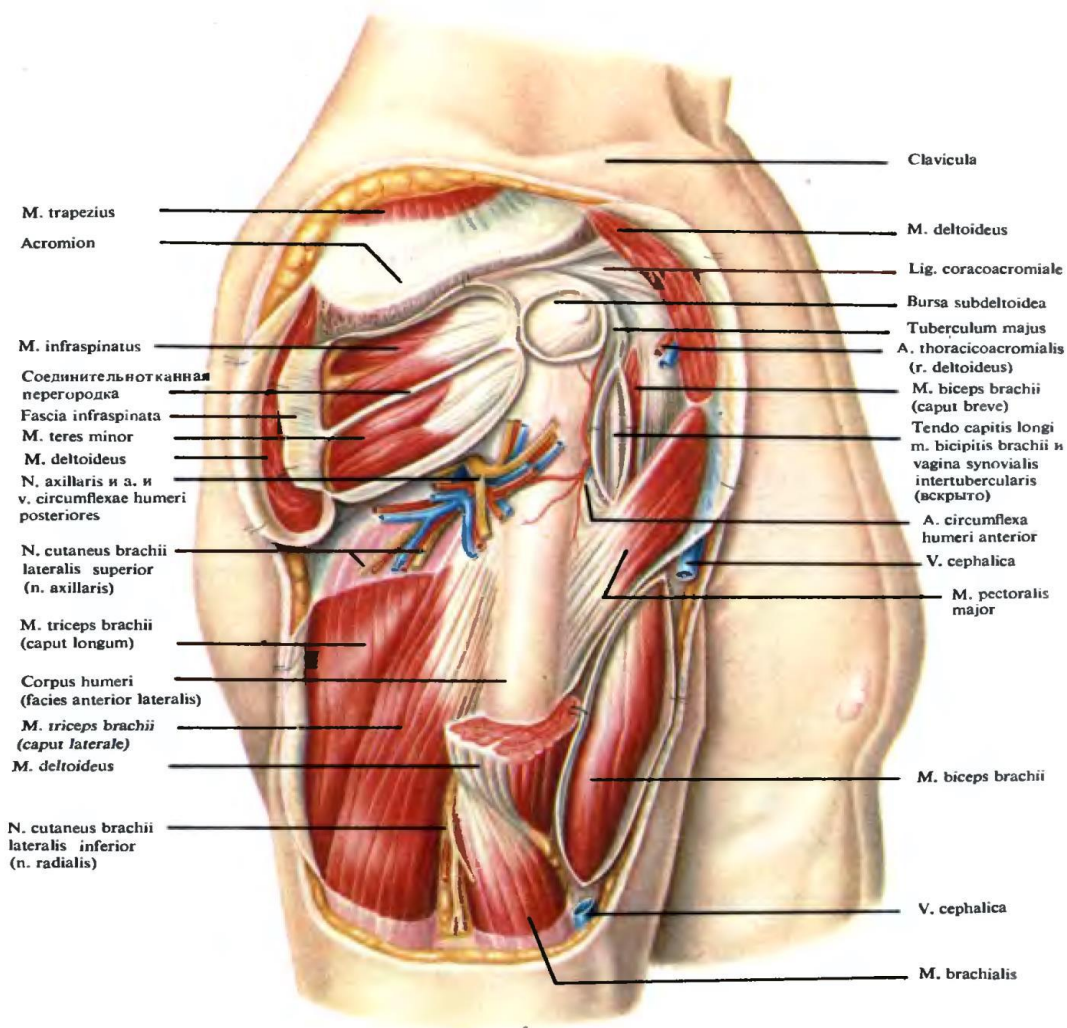
Superficial layer: it covers the outer surface of the deltoid muscle; it is continuous

with the pectoral fascia; it divides the deltoid muscle into 3 parts, which are the clavicular, acromial.

Deep layer: it invests the deltoid nerve; it is continuous with the fascia covering the triceps brachii muscle; it sends numerous septa and fasciculi.

Muscles:

Unipennate: clavicular and spine of the scapula parts; Multipennate: acromial part; all fibres converge and are attached to the deltoid tuberosity. Actions: abduction, pulling the arm forwards and pronating is slightly, pulling the arm backwards and supinating it slightly, anterior part helps the pectoralis major muscle in arm flexion and medial rotation of the arm; posterior part helps latissimus dorsi muscle in arm extension and lateral rotation of the arm.



Сосуды, нервы и мышцы, лежащие под дельтовидной мышцей; вид справа (1/2).

TOPOGRAPHY OF THE SUBCLAVIAN REGION

Landmarks: sternum, clavicle, coracoid process, 3rd rib, cephalic vein, pectoralis

major muscle, deltoid muscle, border between pectoralis major and deltoid muscles.

Borders:

Superior – clavicle. Inferior – horizontal line drawn through the 3rd rib; upper margin of the mammary gland (in women). Medial – lateral margin of the sternum. Lateral – anterior margin of the deltoid muscle.

Layers:

Skin: it is thin, easily movable; it contains sebaceous glands; it is innervated by the supraclavicular nerve.

Subcutaneous tissue: it is well-developed, especially in women. It contains the cutaneous nerve. It contains the thoracoacromial and thoracoepigastric veins form the cephalic and axillary veins.

Superficial fascia: it is thin and firm. It is attached to the inferior margin of the clavicle and upper margin of the mammary gland, which forms the Cooper's suspensory ligaments of the mammary gland.

Deep fascia: it covers the pectoralis major muscle, it divides the pectoralis major muscle into 3 parts (clavicular, sternocostal, abdominal).

Borders: superior – clavicle; inferior – fascia of the serratus anterior and rectus abdominis muscles; medial – sternum; lateral – deltoid and axillary fasciae.

Proper fascia: it is attached to the lower margin of the clavicle, coracoid process and 1st rib. It covers the subclavius and pectoralis minor muscles. Lower part of proper fascia forms the suspensory ligaments of the mammary gland.

TOPAGRAPHY OF THE ANTERIOR REGION OF THE ARM

Landmarks: deltoid muscle, pectoralis major muscle, latissimus dorsi muscle, biceps brachii muscle, triceps brachii muscle, medial and lateral epicondyles of the humerus, greater tubercle of the humerus; sulci bicipitales lateralis et mediales.

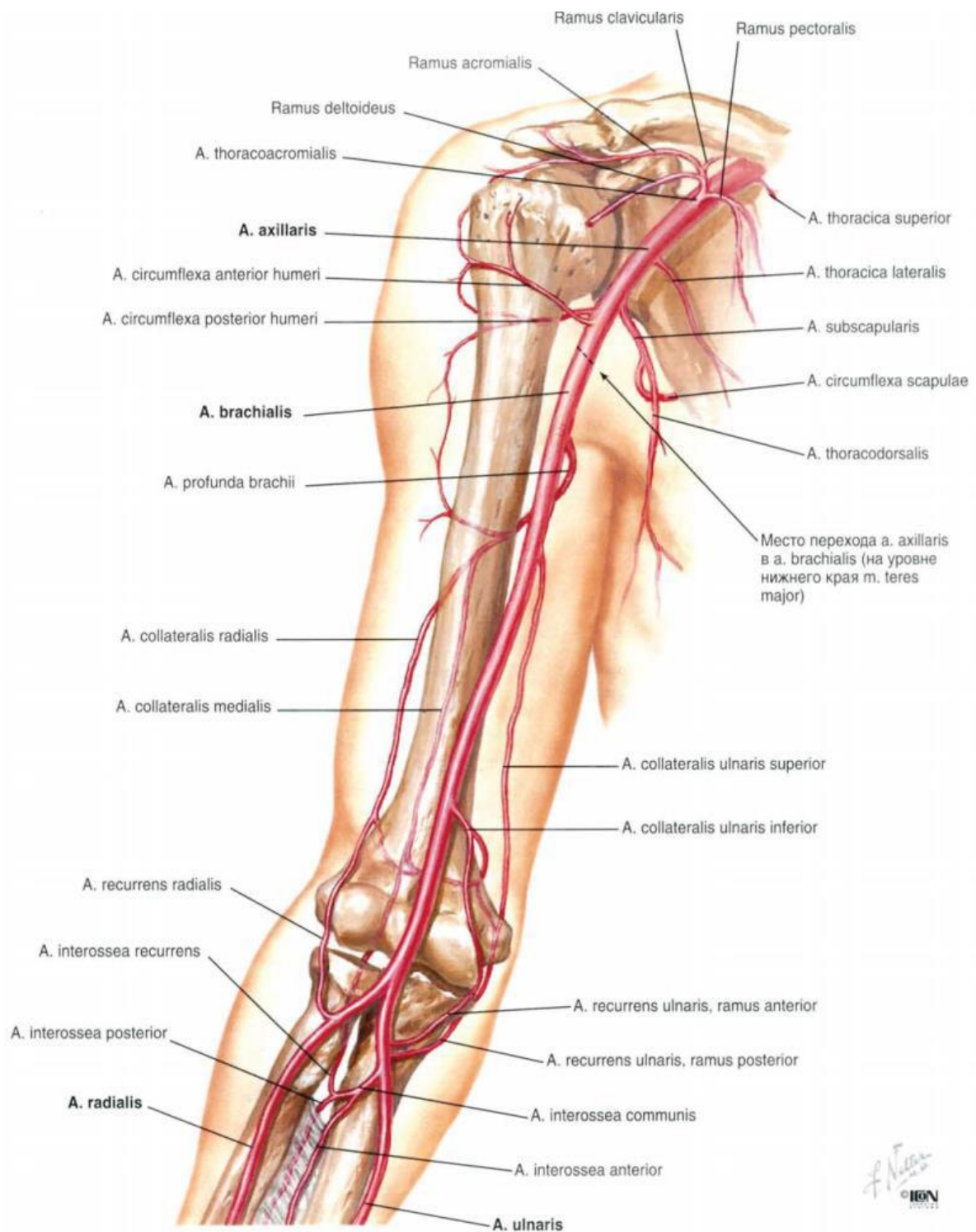
Borders:

Superior – horizontal line drawn from the pectoralis major and latissimus dorsi muscles. Inferior – imaginary line drawn with 2 fingers above the lateral and medial epicondyles of the humerus; medial and lateral: vertical lines drawn on medial and lateral epicondyles of the humerus respectively.

Layers:

Skin: lateral is thicker than the medial one. It is slightly movable. It is innervated by the medial cutaneous nerve of the arm, lateral cutaneous nerve of the arm, superior lateral cutaneous nerve of the arm and inferior lateral cutaneous nerve of the arm.

Subcutaneous tissue: it contains the cephalic and basilica veins. It contains the cubital lymph nodes.



Superficial fascia: it forms a covering for the superficial veins and cutaneous nerves.

Deep fascia: it forms 2 septa which are connected to the humerus, namely the lateral and medial intermuscular septa. These 2 septa divide the brachial region into anterior and posterior parts. Transverse septum is pierced by the ulnar nerve

and anterior descending branch of profunda brachii artery to the anterior surface of the lateral epicondyle. Anteroposterior septum separates the brachialis muscle from the muscles attached to the lateral supracondylar ridge. This septum also encloses the radial nerve and anterior descending branch of the deep artery of arm.

Muscles: *coracobrachialis muscle* (from the coracoid process in common with the short head of the biceps, and its insertion is at about the middle of the internal border of the humerus), *biceps brachii muscle* (arises by long head from the apex of the coracoid process; it inserts into the tuberosity of the radius), brachialis muscle (situated beneath the biceps, arises from the anterior aspect of the humerus, below the insertion of the deltoid muscle, and from the intermuscular septa, and is inserted into the coronoid process of the ulna).

TOPOGRAPHY OF THE POSTERIOR REGION OF THE ARM

Landmarks: deltoid muscle, pectoralis major muscle, latissimus dorsi muscle, biceps brachii muscle, triceps brachii muscle, medial and lateral epicondyles of the humerus, greater tubercle of humerus, sulcus deltoideopectoralis, sulci bicipitales lateralis et mediales.

Borders:

Superior – horizontal line drawn from the pectoralis major latissimus dorsi muscles. Inferior – imaginary line drawn with 2 fingers above the lateral and medial epicondyles of the humerus. Medial and lateral – vertical lines drawn on the medial and lateral epicondyles of the humerus respectively.

Layers:

Skin: it is thick and well-connected with the subcutaneous tissue.

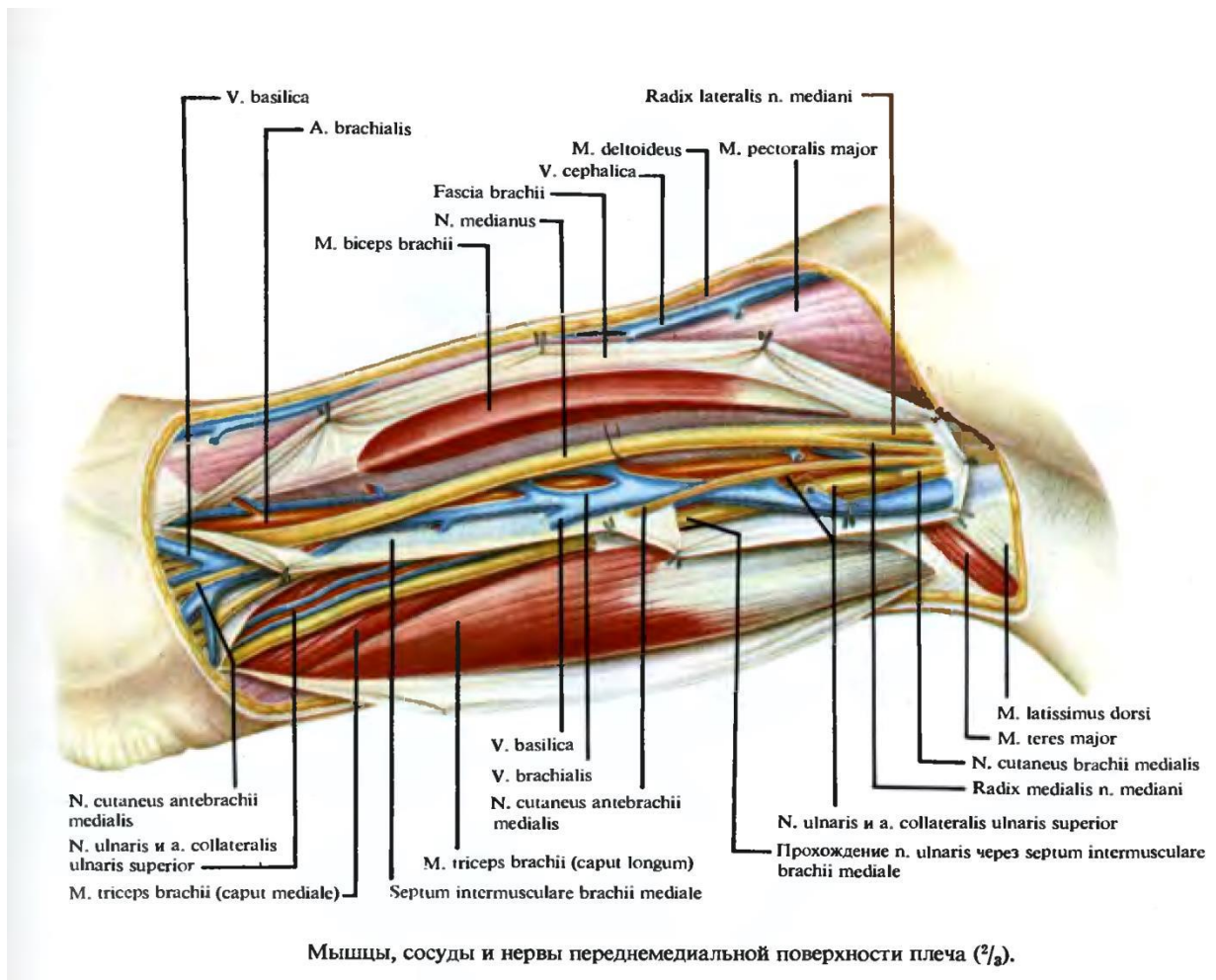
Subcutaneous tissue: it contains the superior lateral cutaneous nerve of the arm, inferior lateral cutaneous nerve of the arm and posterior cutaneous nerve of the forearm.

Superficial fascia.

Deep fascia: it forms a covering for the triceps brachii muscle and its tendon.

Muscle: *triceps brachii muscle* (the long head arises from the infraglenoid tubercle of the scapula; the inner head arises from the posterior surface of the humerus below the musculospiral groove; the outer head commences above the musculospiral groove, which it bridges over, and arises from the outer surface of the bone and from the external intermuscular septum. These 3 heads are inserted into a common tendon which is attached to the olecranon).

Humeromuscular canal: it is also known as canalis spiralis. Radial nerve, deep artery of arm and its vein pass through this canal.



Superior trilateral foramen

Borders:

Medial – teres minor muscle. Lateral – medial margin of the long head of the triceps muscle. Inferior – teres major muscle.

Contents: circumflex scapular artery.

Inferior trilateral foramen

Borders:

Medial – long head of the triceps brachii muscle; lateral – medial margin of the humerus. Superior – teres major muscle.

Contents: radial nerve, deep artery of the arm.

Quadrilateral foramen

Borders:

Medial – lateral margin of the long head of the triceps brachii muscle; Lateral – surgical neck of the humerus. Superior – teres minor muscle, subscapularis muscle.

Inferior – teres circumflex humeral artery

Canal of the radial nerve

Topography: it is bounded by the humerus and triceps brachii muscle. It contains the radial nerve, deep artery of the arm and its veins.

The ulnar, the second great nerve of the arm, lies internal to the artery, but gradually becomes more distant from the vessel. It pierces the internal intermuscular septum at the lower third of the arm and reaches the space between the internal condyle and the olecranon. The ulnar nerve also gives off no branches in the upper arm as the median one.

Shoulder-joint -This joint has the widest range of motion of any joint in the body. The articulation is formed by the head of the humerus and the glenoid cavity of the scapula. The humeral head is covered by cartilage and the articular surface of the glenoid cavity is enlarged (deepened) by the glenoid ligament. As a consequence of the incongruity between the two articular surfaces, the head of the humerus projects far beyond the edge of the glenoid cavity. The lax capsular ligament passes down from the circumference of the glenoid cavity and is attached, anteriorly, to the anatomic neck of the humerus.

TOPAGRAPHY OF THE ELBOW REGION

Landmarks:

Olecranon of the ulna, brachioradialis muscle, tendon of the biceps brachii muscle, medial and lateral epicondyles of the humerus, sulci cubitales posteriores lateralis et medialis, sulci cubitales anteriores lateralis et medialis.

Borders:

A horizontal line is drawn 4 cm from the level which connects the medial and lateral epicondyles of the humerus; 2 vertical lines are drawn through the medial and lateral epicondyles of the humerus and divide the elbow region into the anterior region and posterior region.

The elbow-joint is composed of three articulations:

1. The trochlear surface of the humerus with the greater sigmoid cavity of the ulna.
2. The capitulum of the humerus with the cup-shaped depression on the head of the radius.
3. The lesser sigmoid cavity of the ulna with the circumference of the head of the radius. The first articulation is for flexion and extension, the third is for rotation (pronation and supination), and the second permits not only of flexion and extension, but also of rotation. All three articulations are surrounded by a common lax capsular ligament, which is attached anteriorly above the coronoid and radial

depressions, excluding the epicondyles, and posteriorly above the olecranon fossa, which is also situated within the joint. To either side of the olecranon the capsular ligament forms small diverticula which arch situated beneath the cutaneous depressions visible in this situation in the living subject. The capsular ligament is attached to the edges of the greater and lesser sigmoid cavities of the ulna in such a way that the apex of the coronoid process and the olecranon arc within the articular cavity; this ligament is also inserted into the neck of the radius so that the head of this bone is entirely within the joint. The capsular ligament is reinforced by three other ligaments:

1. *The internal lateral ligament*, which radiates from the internal epicondyle to the edge of the greater sigmoid cavity of the ulna.

2. *The external lateral ligament*, which runs downward from the external epicondyle, some of the fibers surrounding the neck of the radius and being inserted into the anterior and posterior margins of the lesser sigmoid cavity of the ulna.

3. *The orbicular ligament*, which enforces the capsule in a circular manner about the neck of the radius and is inserted into the anterior and posterior margins of the lesser sigmoid cavity of the ulna. The external lateral and orbicular ligaments form practically one continuous band of connective tissue.

As the large superficial and deep vessels of this region are situated in front of the elbow-joint, it follows that marked subcutaneous or deep extravasations of blood may result from a backward dislocation of both bones, and particularly from that form which is due to hyperextension. In this dislocation the median nerve is necessarily lacerated, as it is also in front of the articulation. The importance of the relation of the ulnar nerve to the joint has been already emphasized.

TOPAGRAPHY OF THE ANTERIOR CUBITAL REGION

Layers:

Skin: it is thin, movable and non-pigmented. It contains sweat glands, sebaceous glands and hair. It is innervated by the lateral and medial cutaneous nerves of the forearm.

Subcutaneous tissue: it contains lymphatic vessels with superficial lymphatic nodes and superficial venous network. It contains the cephalic, basilica and median cubital veins. Superficial cubital nodes are situated at the basilica vein. The connection of the cephalic, basilic and median cubital veins forms an alphabet "N".

Superficial fascia: it is connected with the superficial fascia of the arm and forearm, aponeurosis of biceps brachii muscle, it is connected with the deep fascia.

Deep fascia: fascia of the biceps brachii and brachialis muscles forms the lateral

and medial intramuscular septa. These septa are fixed to the medial and lateral epicondyles of the humerus. It forms a covering for the muscles of the arm and forearm. Inferior to the radial tuberosity, the fixation for the tendon of the biceps brachii muscle takes place. Intermuscular septa continue to form the anterior radial intermuscular septa of the forearm.

Muscles:

Lateral: brachioradialis muscle and supinator muscle.

Median: biceps brachii muscle and brachialis muscle.

Medial: (1st layer) pronator teres, flexor carpi radialis, palmaris longus and flexor carpi ulnaris muscles

Medial: (2nd layer) flexor digitorum superficialis muscle.

Neurovascular bundles:

2 neurovascular bundles are found between groups of muscles and septa, which are lateral bundle (radial nerve and radial collateral artery) and medial bundle (brachial artery and median nerve).

The brachial artery runs beneath the deep fascia in the internal bicipital groove; it is accompanied by two veins, the inner of which receives the basilica vein. Higher up, the veins unite to form a single vein, either before reaching the axilla or, more rarely, after entering into this region. Disregarding the muscular branches, of which the bicipital is particularly large, the main branches of the brachial are:

1. ***The superior profunda artery***, which accompanies the musculospiral nerve about the posterior surface of the humerus, in the musculospiral groove, between the outer and inner heads of the triceps muscle. It ends at the outer side of the humerus, where it is accompanied by a cutaneous branch of the musculospiral nerve, and descends behind the external intermuscular septum to reach an anastomotic arch above the olecranon.

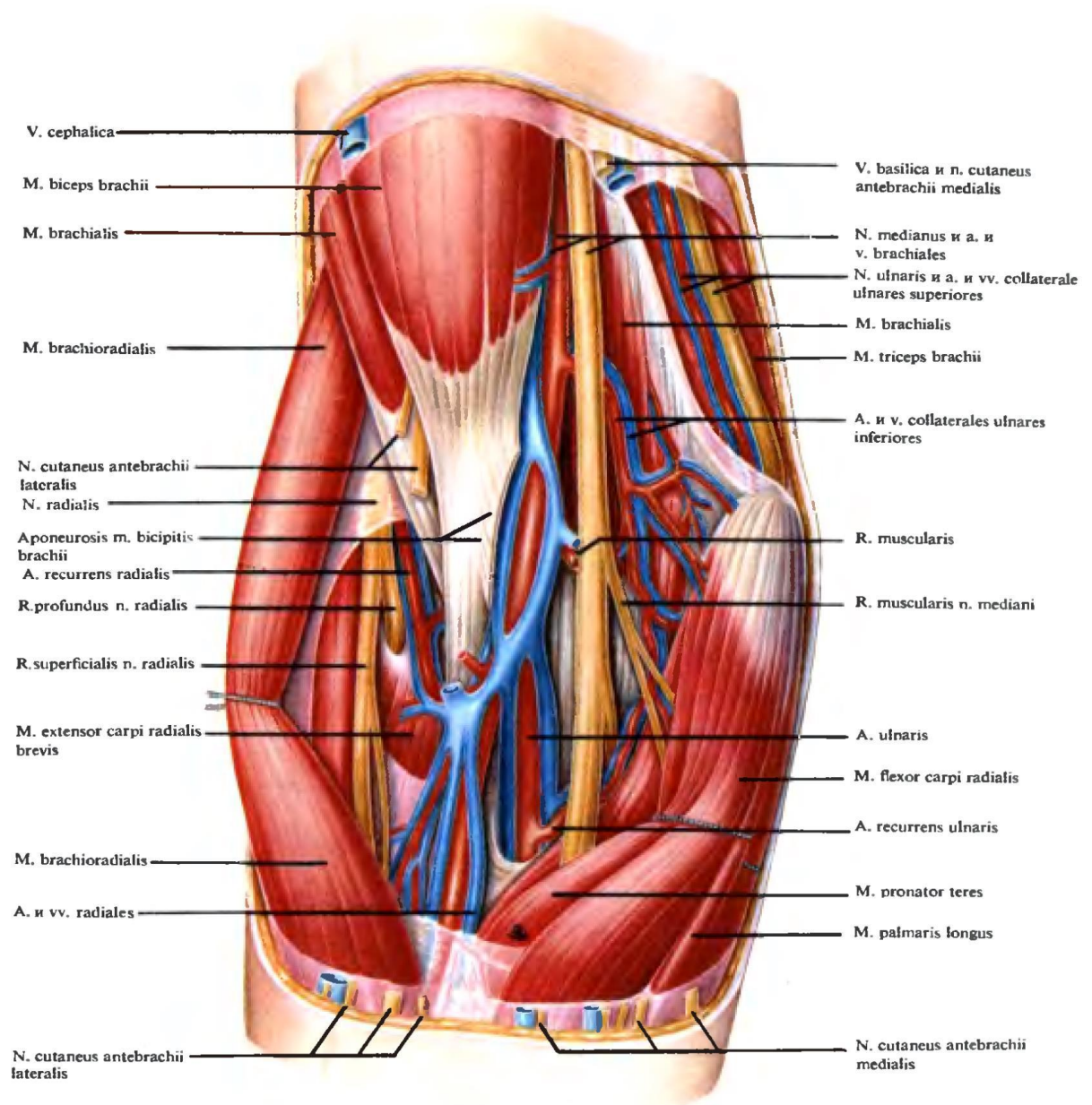
2. ***The inferior profunda artery***, usually a ling vessel, which accompanies the ulnar nerve to the olecranon, where it empties into the rete cubiti.

3. ***The anastomotic magna artery***, which arises near the division of the brachial in the region of the elbow. It runs transversely inward across the brachialis anticus muscle and passes posteriorly to the rete cubiti.

The radial artery: It passes through the tendon of the biceps brachii muscle. It is lodged between the pronator teres and brachioradialis muscles.

The radial nerve: it is situated between the brachioradialis and brachialis muscles in the upper level. It goes downward and is divided into 2 branches, which are the superficial and deep branches of the radial nerve at the level of the lateral epicondyle of the humerus. Superficial branch innervates the brachioradialis and

pronator teres muscles. Deep branch lies laterally and passes through the supinator canal between the superficial and deep layers of supinator muscle.



Сосудисто-нервные пучки передней области локтя (1/1).

TOPOGRAPHY OF THE POSTERIOR CUBITAL REGION

Landmarks:

Olecranon of ulna, sulci cubitales posteriores lateralis et mediales, ulnar nerve passing along the sulcus cubitales posterior medialis, head of the radius is palpated in the middle part of sulcus cubitalis posterior lateralis.

Layers:

Skin: it is thick and movable, it forms skin folds.

Subcutaneous tissue: it contains the superficial arteries(medial collateral artery, radial collateral artery and recurrent interosseous artery); it contains the posterior cutaneous nerve of the arm, medial cutaneous nerve of the forearm. Bursa of the elbow joint is located in the superior part of the olecranon of the ulna.

Superficial fascia: it is thin layer without fixation.

Deep fascia: it is formed by the aponeurosis; it is fixed to the tendon of the triceps brachii muscle, medial and lateral epicondyles of the humerus and olecranon of the ulna.

Muscles:

Superior – *triceps brachii* and *anconeus muscles*; lateral – *extensor muscle* of the wrist(*extensor carpi radialis longus* , runs to the dorsal surface of the base of the second metacarpal bone, *extensor carpi radialis brevis*, goes to the dorsal surface of the third metacarpal bone, and *extensor carpi ulnaris muscles*, arises from the external condyle, from the deep fascia of the forearm, and from the posterior border of the ulna, and is inserted into the base of the fifth metacarpal bone) and extensor muscle of the digits(*extensor digitorum*, arises from the external condyle and from from the deep fascia of the forearm and is inserted by means of four tendons into the dorsal aponeurosis of the fingers, and *extensor digiti minimi muscles*, arises from the external condyle and furnishes a second tendon to the little finger); deep - *supinator muscle*; medial – *flexor digitorum profundus*, arises from the upper two-thirds of the anterior surface of the ulna and from the interosseous membrane, and by a small muscular slip from the internal condyle and is inserted into the terminal phalanx of the thumb and *flexor carpi ulnaris muscles*, the ulnar origin extends downward to the lower third of the bone, is inserted into the pisiform bone, the inciform process of the unciform mone, and the base of the fifth metacarpal bone.

TOPOGRAPHY OF THE ANTERIOR REGION OF THE FOREARM

Landmarks: brachioradialis muscle, sulci radialis et ulnaris, tendons of the flexor carpi radialis and palmaris longus muscles, styloid process of the ulna and radius.

Borders:

Upper – horizontal line drawn 4 cm distal to the level of the wrist joint. Lower – transverse line drawn 2 cm proximal to the styloid process of the radius; 2 vertical lines are drawn through the epicondyles and styloid processes, which divide the

forearm region into the anterior and posterior regions.

Layers:

Skin: it is thin, it contains sweat and sebaceous glands, it is innervated by the medial and lateral cutaneous nerves of the forearm.

Subcutaneous tissue: it contains the cephalic vein and basilica vein; it contains the lateral cutaneous nerve of the forearm and medial cutaneous nerve of the forearm; intermediate anterbrachial vein passes through the middle line of this region.

Superficial fascia: it is not attached to the bone, it covers all structures in the subcutaneous tissue.

Deep fascia: it forms a covering for muscles, vessels, nerves and bones; it is thicker in the proximal part and thinner in the distal part; it sends two septa to the radius one and divides the forearm into 3 seats for muscles (anterior, posterior and lateral) in the upper half of forearm.

Lateral: brachioradialis, extensor carpi radialis longus and extensor carpi radialis brevis muscles. Anterior: pronator teres, flexor carpi radialis, flexor digitorum superficialis, palmaris longus and flexor carpi ulnaris muscles, flexor digitorum profundus and flexor pollicis longus muscles.

Borders of the fascia: anterior – strictly fixed to the deep fascia; posterior – interosseous membrane, ulna and radius; medial – posterior margin of ulna; lateral – sulcus radialis.

Pirogov's space is situated in the lower half of the deep fascia. Anterior: fascia of the flexor digitorum and flexor pollicis longus muscles. Posterior: fascia of the pronator quadratus muscle.

Muscles:

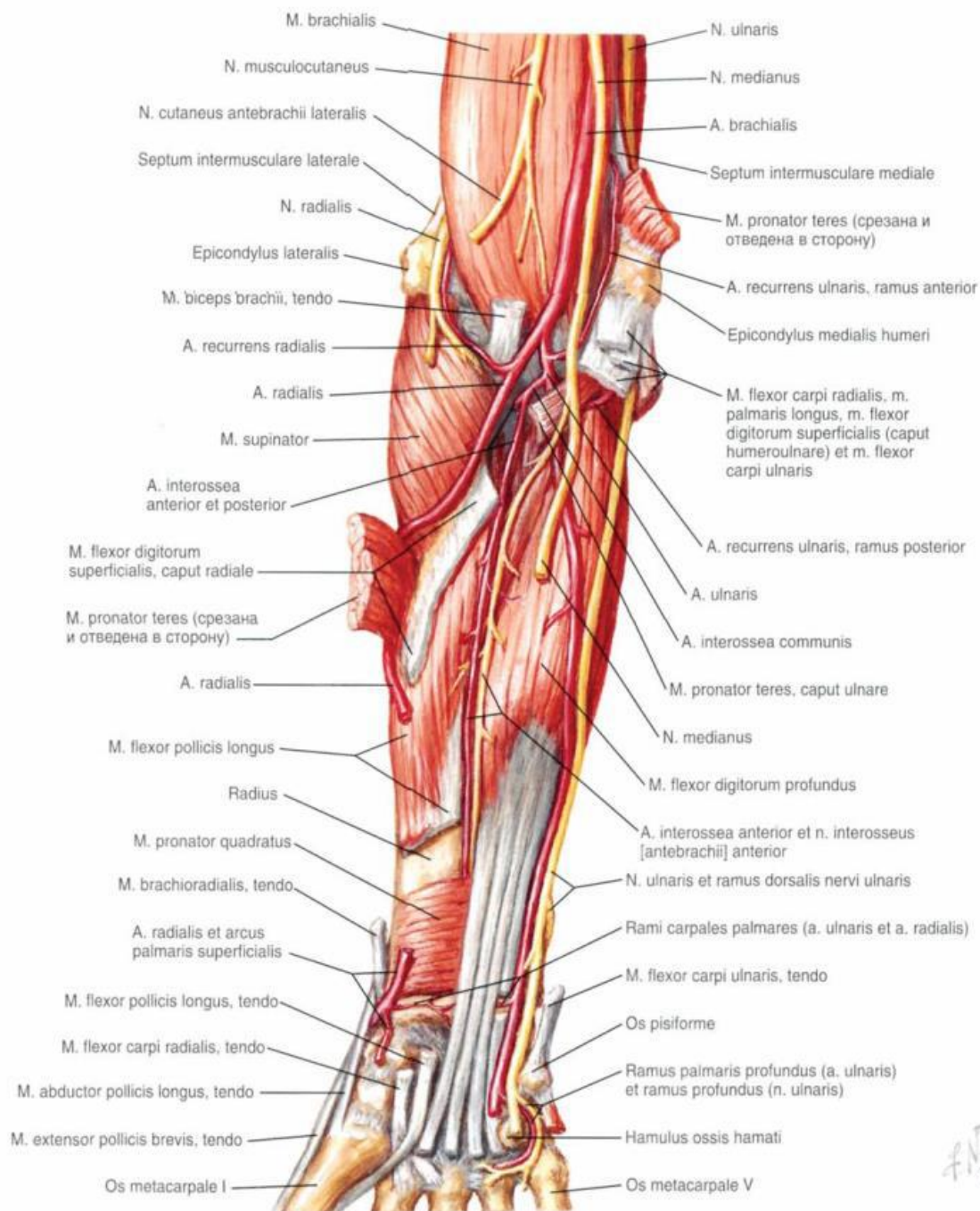
Medial margin of the deep fascia is bounded to the posterior margin of the ulna and divides the muscles into 4 layers:

- 1) 1st layer: pronator teres, flexor carpi radialis, palmaris longus, flexor carpi ulnaris and brachioradialis muscles.
- 2) 2nd layer: flexor digitorum superficialis muscle.
- 3) 3rd layer: flexor digitorum profundus and flexor pollicis longus muscles.
- 4) 4th layer: pronator quadratus muscle.

The muscles of the forearm should be reviewed in detail from a systematic anatomy. The flexor group may be subdivided into a superficial and a deep layer, each consisting of four muscles. All of the superficial flexors originate from the internal condyle. **The pronator radii teres** is inserted into the outer surface of the middle of the radius. **The flexor carpi radialis** is attached to the base of the second metacarpal bone. **The palmaris longus radiates** into the palmar fascia. **The flexor carpi ulnaris**, the ulnar origin of which extends downward to the lower third of the

bone, is inserted into the pisiform bone, the unciform process of the unciform bone, and the base of the fifth metacarpal bone. There are four deep muscles upon the flexor surface. *The flexor sublimis digitorum* arises by two heads from the internal condyle of the humerus and from the anterior surface of the radius and is inserted by means of four tendons into the second phalanges of the fingers. *The flexor profundus digitorum* arises from the upper two-third of the anterior surface of the ulna and from the interosseous membrane and is inserted by means of four tendons into the terminal phalanges of the fingers. *The flexor longus pollicis* arises from the anterior surface of the radius, from the interosseous membrane, and by a small muscular slip from the internal condyle and inserted

into the terminal phalanx of the thumb.



Neurovascular bundles:

Lateral:

Radial artery and vein; superficial branch of the radial nerve: it is located on the sulcus radialis, in the upper 1/3 of the forearm, it is bounded by the brachioradialis muscle laterally and pronator teres muscle medially, in the middle and lower 1/3 of the forearm, it follows the brachioradialis and flexor carpi radialis muscles and passes downward along with radial artery, then it passes through the tendon of the

brachioradialis muscle.

The radial artery: it passes along the middle part of the elbow joint to the styloid process of the radius and enters the anatomical snuffbox.

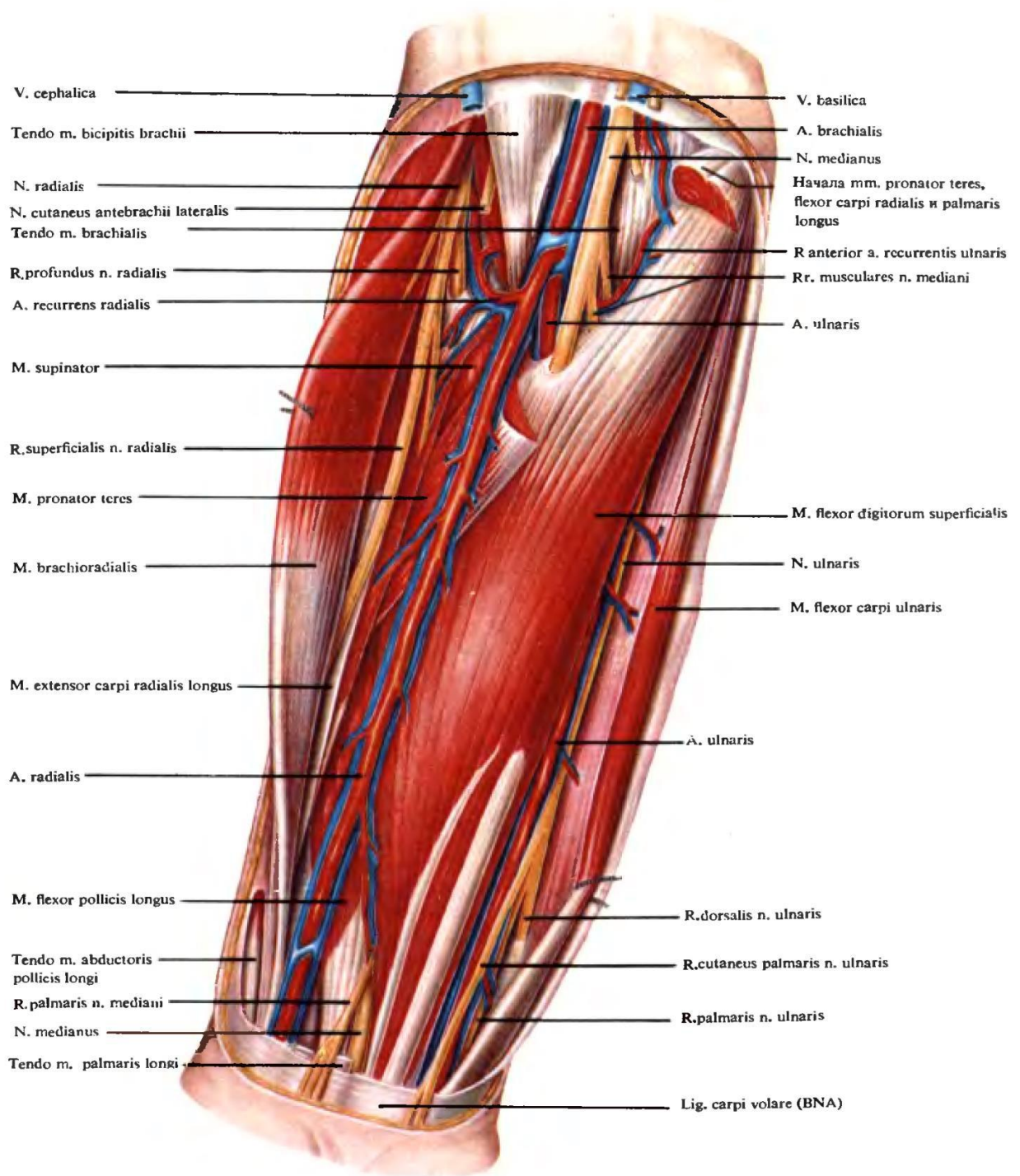
Medial:

The ulnar artery: it exists inferior to the pronator muscle in the upper part. It is later located between the superficial and deep flexors of the fingers. It passes from the tendon of the biceps brachii muscle, in the middle 1/3 of the forearm, it passes under the pronator teres muscle, flexor digitorum superficialis muscle and sulcus ulnaris, in the lower 1/3 of the forearm, it passes to the medial margin of the styloid process of the ulna and reaches the pisiform bone.

The ulnar nerve: it passes on the sulcus ulnaris and is bounded medially by the flexor carpi ulnaris muscle and laterally by the flexor digitorum superficialis in the upper 1/3 of the forearm; then it passes from the medial epicondyle of the humerus to the medial margin of the pisiform bone; dorsal branch of the ulnar nerve starts from the middle and lower 1/3 of the forearm and passes under the tendon of the flexor carpi ulnaris muscle, it passes downward and medially to the ulnar artery. Posterior interosseous artery is a branch of the upper part of the ulnar artery and is divided into the anterior and posterior interosseous arteries. Posterior interosseous artery passes through the orifice of the interosseous membrane to the posterior region of the forearm.

Anterior:

The median nerve is the most superficial of the three chief nerves in the upper arm. At first the nerve lies to the outer side of the brachial artery, it then passes in front of the vessel, and, while still above the elbow, takes a position to the inner side of the artery. The nerve consequently crosses the artery, and is to be felt lying upon the vessel, if the panniculus adiposus is not too well marked. The nerve gives off no branches in the upper arm as the median one.



Локтевой и лучевой сосудисто-нервные пучки; вид спереди ($\frac{2}{2}$).

TOPOGRAPHY OF THE POSTERIOR REGION OF THE FOREARM

Layers:

Skin: it is thick with limited movement; it is innervated by the medial and lateral

cutaneous nerves of the forearm and posterior cutaneous nerve of the forearm.

Subcutaneous tissue: it contains less fatty tissue; superficial veins from the main trunk of the vein.

Superficial fascia: it is weak layer.

Deep fascia: it is distinguished by its thickness and strictly fixed to the ulna and radius, it is an aponeurosis in the upper half of the forearm, it tends downward and forms the extensor retinaculum and dorsal carpal canal, it forms cellular space which contains deep branch of the radial nerve, posterior interosseous artery, posterior interosseous veins and nerve; deep branch of the radial nerve passes through the canalis supinatorius; posterior interosseous artery passes medial to the posterior interosseous nerve.

Muscles:

Superficial muscles: extensor carpi radialis longus muscle, extensor carpi radialis brevis muscle, extensor digitorum muscle, extensor digiti minimi muscle, extensor carpi ulnaris muscle.

Deep muscles: supinator muscle, abductor pollicis longus muscle, extensor pollicis longus muscle, extensor pollicis brevis muscle, extensor indicis muscle.

TOPOGRAPHY OF THE PALMAR REGION OF THE HAND

Landmarks: styloid processes of the ulna and radius, skin fold of the wrist joint, metacarpal bones, phalanges of fingers.

Borders: 2 cm above the styloid process of the ulna, 2 vertical lines are drawn along the ulna and radius and divide the hand region into the palmar and dorsal regions.

Layer:

Skin: it is thick with limited movement, stratum corneum is well developed in this region, it contains sweat glands and sebaceous glands, it is innervated by the radial nerve, ulnar nerve and median nerve.

Subcutaneous tissue: it contains vessels, nerves and lymphatic vessels with lymphatic nodes, it contains the superficial palmar branch of the radial artery.

Superficial fascia: it is a continuation of the superficial fascia of the forearm, it is slightly movable and fixed to the bones.

Deep fascia: it stretches from the palmar longus tendon to the ligamentum carpi volare, it forms the palmar aponeurosis, flexor retinaculum, synovial sheaths of the hand and fingers.

Flexor retinaculum: it is the strongest and thickest fascia which is fixed to the bone. Between the eminentia carpi ulnaris and eminentia carpi radialis, flexor retinaculum converts the sulcus carpi into the canalis carpi. Then the flexor

retinaculum forms the canalis carpi radialis and canalis carpi ulnaris. *Synovial sheath of the thumb*: it is situated laterally, this long and narrow canal encloses the tendon of the flexor pollicis longus, superiorly this sheath protrudes 1-2 cm proximal to the flexor retinaculum, inferiorly it extends on the tendon to the base of the distal phalanx the thumb.

Synovial sheath of the index, middle and ring fingers: these 3 fingers have common sheaths on the palmar surface; they have separate sheaths in the segment of the distal halves of the metacarpal bones; these sheaths stretch from the line of the metacarpophalangeal joints to the base of the distal phalanges.

Synovial sheath of the little finger: it covers the flexor digitorum superficiales and profundus muscles; superiorly this sheath protrudes 1-2 cm proximal to the flexor retinaculum; inferiorly it extends on the flexors until the base of the distal phalanx of the little finger.

For all fingers: on the phalangeal shafts, synovial sheaths of the fingers are covered by the dense annular fibrous sheaths; on the phalangeal joints, synovial sheaths of the fingers are covered by the thin cruciform fibrous sheaths; the tendons are connected with the thin mesotendineum, which transmit blood vessels and nerves.

Canals of the anterior region of the hand:

Canalis carpi ulnaris: it is formed by a fascia around the pisiform bone; this canal contains ulnar artery and nerve; then it passes under the palmaris brevis muscle.

Canalis carpalis: it is formed by a fascia between the flexor retinaculum and bones (scaphoid bone, trapezium bone, pisiform bone and hamate bone). This canal contains median nerve, 4 flexor digitorum superficialis tendons and 4 flexor digitorum profundus tendons; there are 2 separate synovial sheaths: 1 for the tendons of the flexor pollicis longus muscle; it forms common synovial sheaths of the flexor tendons medially and a sheath for the tendon of the flexor pollicis longus muscle laterally.

Canalis carpi radialis contains tendon of the flexor carpi radialis muscle.

Muscles:

Thenar muscles: abductor pollicis brevis muscle, opponens pollicis muscle, flexor pollicis brevis muscle, adductor pollicis muscle.

Hypothenar muscles: abductor digiti minimi muscle, opponens digiti minimi muscle, flexor digiti minimi brevis muscle, palmaris brevis muscle.

Median muscle group: lumbrical muscles, palmar interosseous muscles, dorsal interosseous muscles.

TOPOGRAPHY OF THE DORSAL REGION OF THE HAND

Layers:

Skin: it is thin and movable, it contains hair follicles, sweat glands and sebaceous glands, furuncles tend to occur in this region, it is innervated by the ulnar, median and radial nerves.

Subcutaneous tissue: it contains loose connective tissue, the cephalic (radial margin) and basilic vena which then form a vascular network between them, it also contains the radial nerve and ulnar nerve.

Superficial fascia:

It is fixed to the styloid process and bones of the wrist.

Deep fascia: It forms the extensor retinaculum, it has 6 canals which are formed by the extensor retinaculum with the carpal bones.

The 6 canals contain: tendon of the extensor carpi ulnaris muscle, tendon of the extensor digiti minimi muscle, tendons of the extensor digitorum and extensor indicis muscles, tendon of the extensor pollicis longus muscle, tendons of the extensor carpi radialis brevis and extensor carpi radialis longus muscles, tendons of the extensor pollicis brevis and abductor pollicis longus muscles, tendons of the extensor pollicis brevis and abductor pollicis longus muscles. On dorsal part of the fingers, tendons of the extensors consist of 3 parts. Tendons from the median part are fixed to the middle phalanges, while tendons from the medial and lateral parts are fixed to the distal phalanges. Aponeurotic tension is located above the proximal phalanges. Distal suffering from the ulnar nerve palsy may show this pose: extension of the proximal phalanges, flexion of the distal and middle phalanges.

TOPOGRAPHY OF THE WRIST

ANTERIOR COMPARTMENT OF THE WRIST

Landmarks:

Structures passing superficial to the flexor retinaculum: flexor carpi ulnaris tendon, ulnar nerve, ulnar artery, palmar cutaneous branch of the ulnar nerve, palmaris longus tendon, palmar cutaneous branch of the median nerve.

Structures passing deep to the flexor retinaculum: flexor digitorum superficialis tendon, median nerve, flexor pollicis longus tendon, flexor carpi radialis tendon.

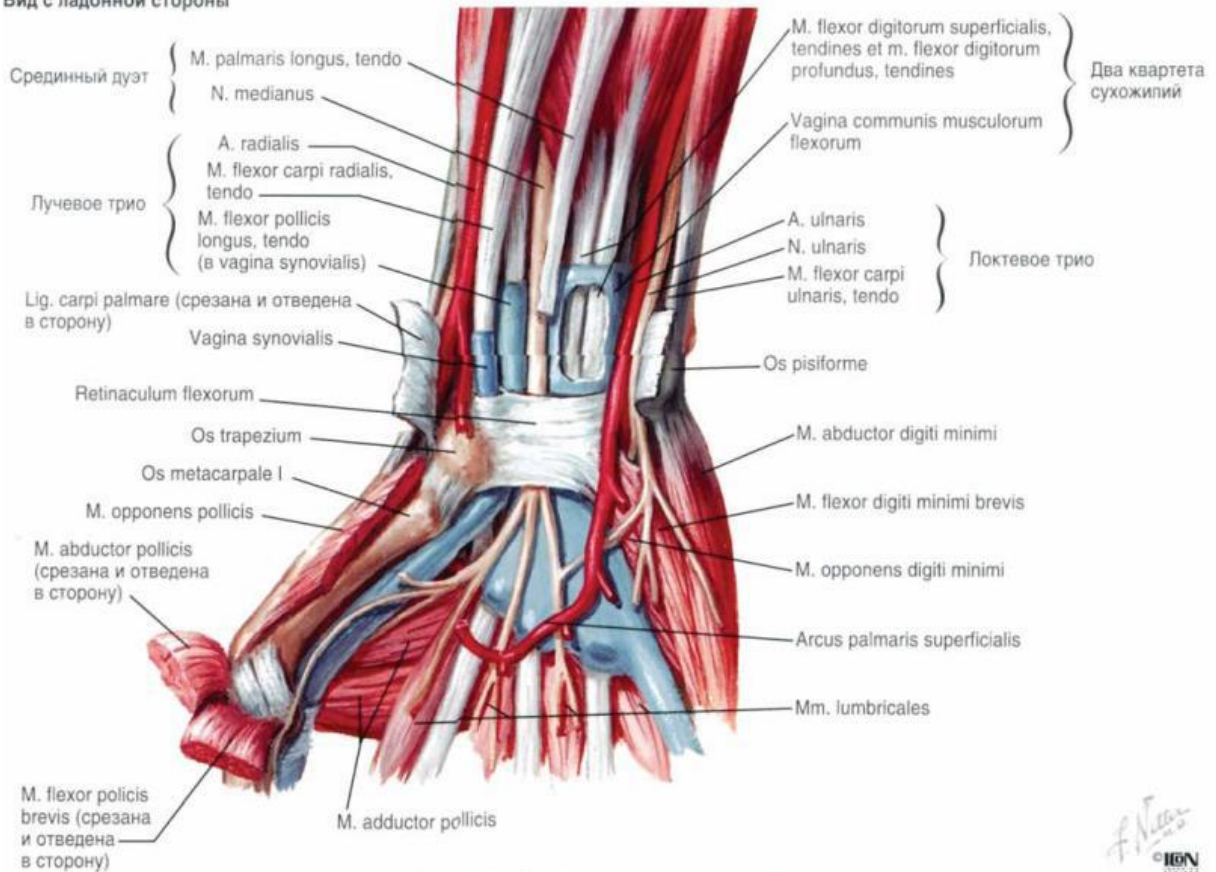
POSTERIOR COMPARTMENT OF THE WRIST

Structures passing superficial to the extensor retinaculum: ulnar nerve, basilica vein, cephalic vein, radial nerve.

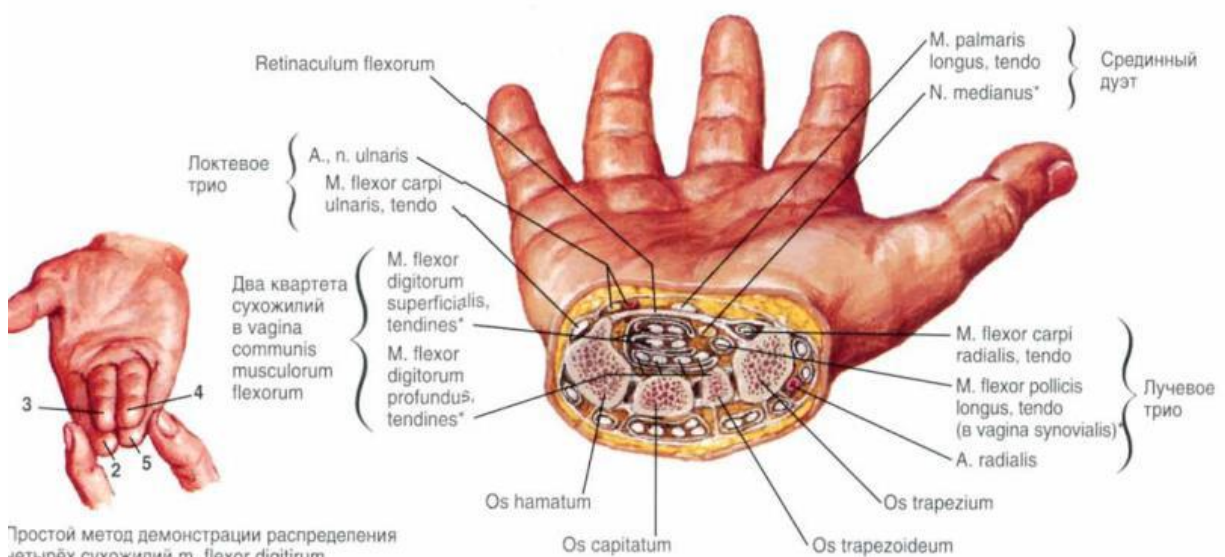
Structures passing beneath the extensor retinaculum: tendon of the extensor carpi

ulnaris muscle, tendon of the extensor digiti minimi muscle, tendon of the extensor digitorum and extensor indicis muscles, tendon of the extensor pollicis longus tendon muscle, tendon of the extensor carpi radialis longus and extensor carpi radialis brevis muscles, tendon of the extensor pollicis brevis and abductor pollicis longus muscles.

Вид с ладонной стороны



Поперечный срез через канал запястья



Тростной метод демонстрации распределения четырёх сухожилий m. flexor digitorum superficialis в канале запястья.

* Структуры, лежащие в канале запястья

The following articulations may be differentiated at the wrist:

1. ***The radiocarpal articulation*** or wrist-joint, between the radius and the distal surface of the interarticular fibrocartilage on one side, and the scaphoid, semilunar, and cuneiform bones upon the other.
2. **The inferior radio-ulnar articulation** between the sigmoid cavity of the radius and the head of the ulna. This joint is completely separated from the preceding one.
3. ***The intercarpal articulations***, between the carpal bones; ***the carpometacarpal articulations***, between the second row of the carpal bones and the metacarpal bones; ***the intermetacarpal articulations***, between the lateral articular surfaces of the bases of the metacarpal bones. These three sets of articulations usually possess a common synovial membrane; the carpal bones are joined together by the tense interosseous ligaments. The synovial cavity of the joint between the unciform and the fourth and fifth metacarpal bones is occasionally separated from the large synovial cavity of the carpus.
4. The articulation between the pisiform and the cuneiform bones.
5. The articulation of the metacarpal bone of the thumb with the trapezium (saddle-joint). In disarticulating at this joint care must be taken to avoid injuring the articulation between the trapezium and the second metacarpal bone, as such an injury would open up the common synovial cavity of the carpus.

TOPOGRAPHY OF THE FINGERS

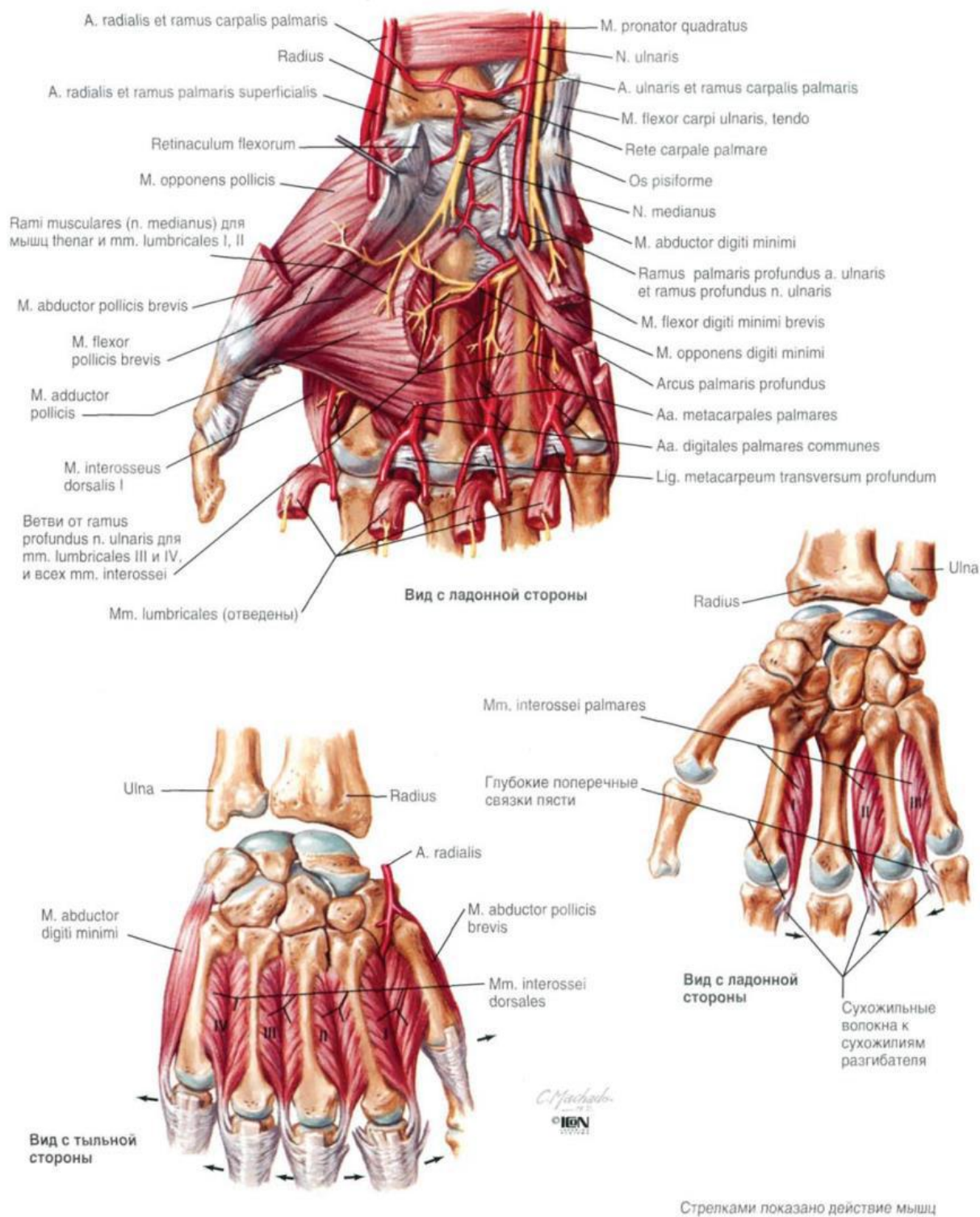
Layers:

Skin: it is thicker in the palmar surface and thinner in the dorsal surface, on the palmar surface, hair follicles and sebaceous glands are absent but sweat glands are present, on the dorsal surface, hair follicles, sebaceous glands and sweat glands are present.

Subcutaneous tissue: it is thin and surrounds the tendinous sheath of the flexor digitorum profundus and flexor digitorum superficialis muscles; the sheath of the index, middle and ring fingers terminates at the level of the metacarpal bones; for the thumb and little finger, it continues to the palm and forms the ulnar and radial bursae connecting with Pirogov's space; on the dorsal surface, tendon of the extensor digitorum muscle does not have any sheath and is connected deep with phalanges.

Superficial fascia: it is almost absent and transformed into the fibrous bundles from the skin to tissue.

Deep fascia: on the phalangeal shafts, synovial sheath of the finger are covered by the dense annular fibrous sheaths; on the phalangeal joints, synovial sheaths of the fingers are covered by the thin cruciform fibrous sheaths.



GROOVES, CANALS AND FATTY TISSUE OF THESE REGIONS

Forearm:

Sulcus radialis: it lies between the brachioradialis and flexor carpi radialis muscles; it contains the superficial branch of the radial nerve, radial artery and vein.

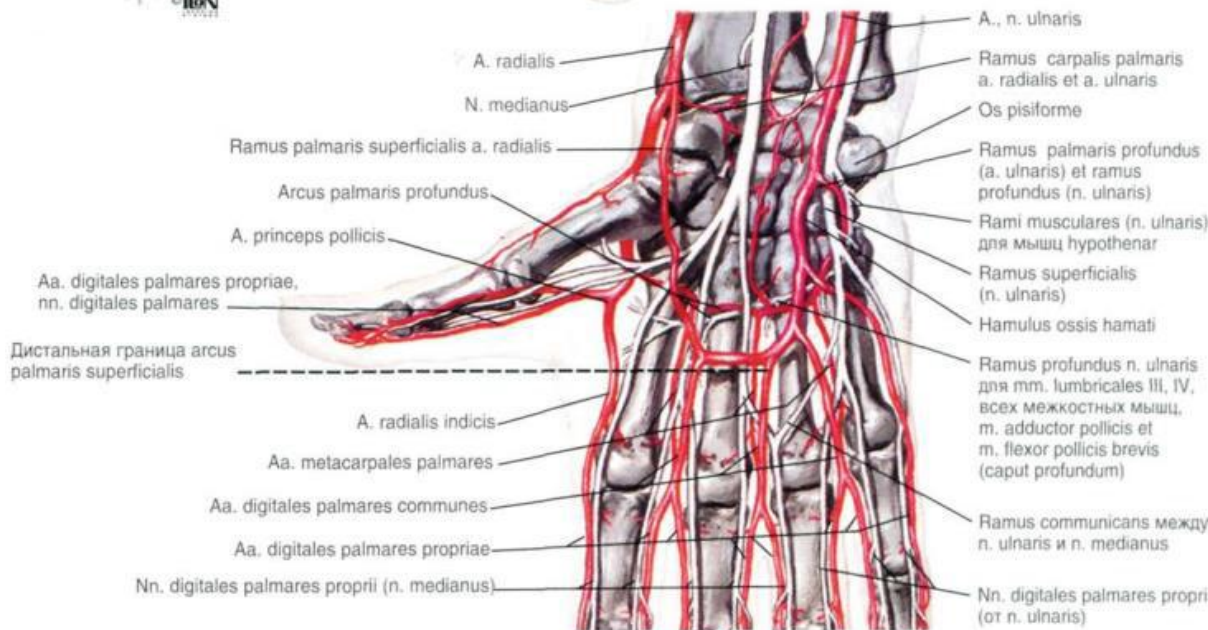
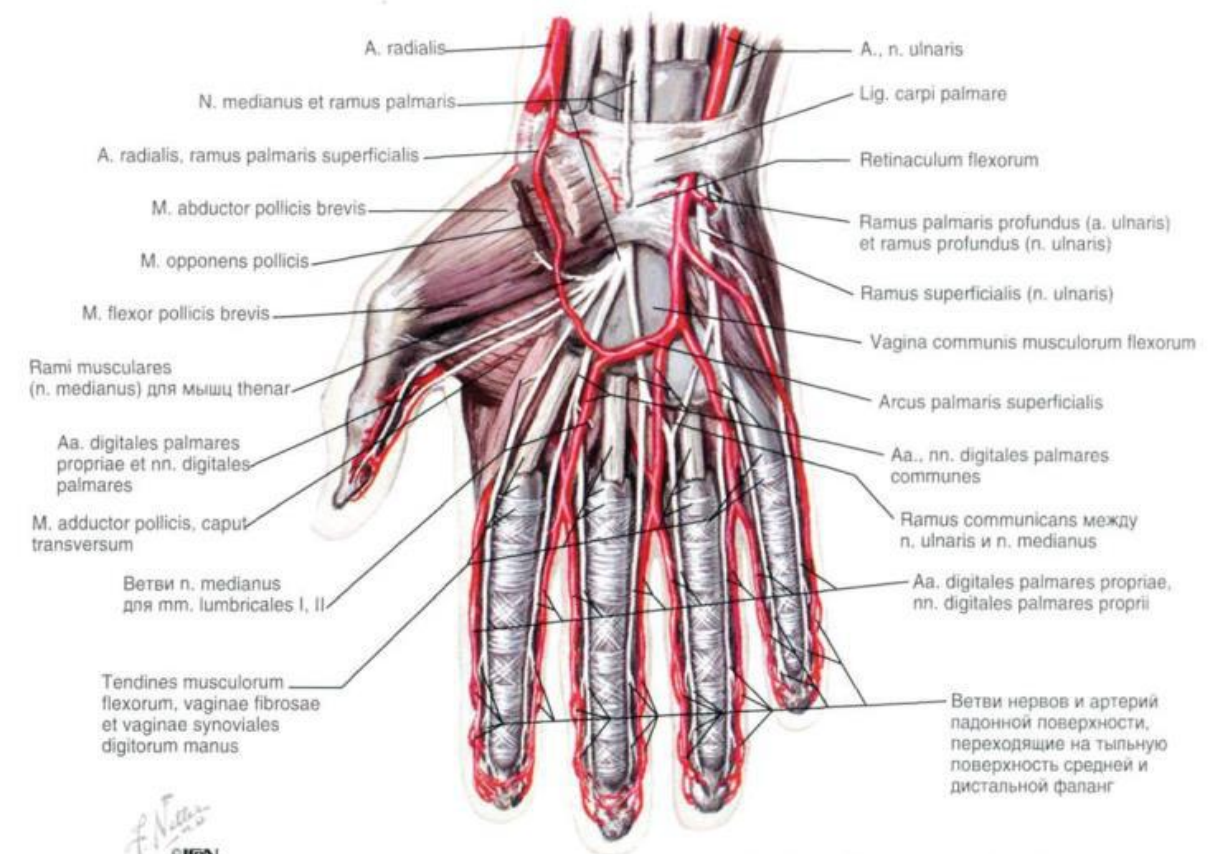
Sulcus ulnaris: it is lodged between the flexor carpi ulnaris and flexor digitorum superficialis muscles; it contains the ulnar artery, vein and nerve.

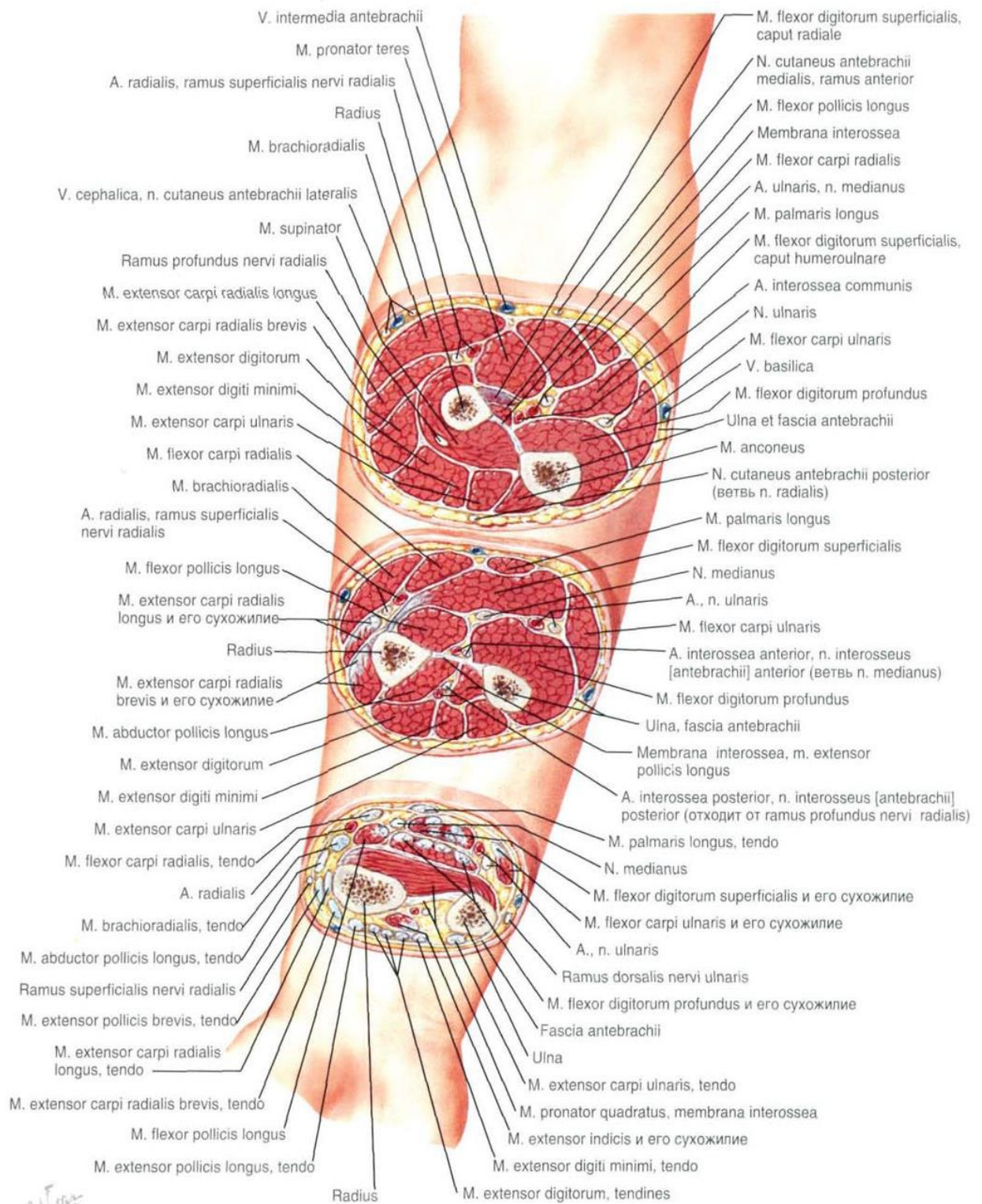
Sulcus medianus: it lies between the flexor carpi radialis and flexor digitorum superficialis muscles; it contains the medial nerve.

Wrist and hand:

Canalis carpi ulnaris: it contains the ulnar artery, vein and nerve

Canalis carpi radialis: it contains the tendon of the flexor carpi radialis, it contains the superficial branch of the radial nerve and palmar branch of the radial artery.





TEST

1. LANDMARKS OF THE SCAPULAR REGION

- a) Acromion, superior angle of the scapula, inferior angle of the scapula
- b) Acromion, superior angle of the scapula
- c) Acromion

2. BORDERS OF THE SCAPULA REGION

- a) Superior – horizontal line drawn through the acromion
- b) Inferior – horizontal line drawn through the inferior angle of the scapula
- c) Lateral – vertical line drawn through the acromion
- d) Medial – medial margin of the scapula.

3. SKIN OF THE SCAPULAR REGION

- a) It is thick with limited movement
- b) It is thin
- c) It is innervated by the superior lateral cutaneous nerve of the arm

4. LANDMARKS OF THE AXILLARY REGION

- a) Outlines of the pectoralis major
- b) Latissimus dorsi
- c) Coracobrachialis muscles
- d) Axillary fossa
- e) Brachialis muscles

5. BORDERS OF THE AXILLARY CAVITY

- a) Anterior – pectoralis major muscle and clavipectoral fascia; posterior – subscapularis, latissimus dorsi, teres major muscles
- b) Medial – line connecting the margin of the pectoralis major and latissimus dorsi muscles along the sagittal section of the lateral surface of the thorax at the level of the 3rd rib
- c) Medial – thoracic wall, serratus anterior muscle and 1st until 4th intercostal muscles
- d) Lateral – surgical neck of the humerus, short head of the biceps brachii muscle and coracobrachialis muscle.

6. CLAVIPECTORAL TRIANGLE CONTAINS

- a) Thoracoacromial artery, arteria thoracica suprema, lateral and medial pectoral nerves
- b) Thoracoacromial artery, arteria thoracica suprema
- c) Lateral and medial pectoral nerves

7. PECTORAL TRIANGLE CONTAINS

- a) Lateral and medial pectoral nerves
- b) Thoracoacromial artery, arteria thoracica suprema, lateral and medial pectoral nerves
- c) Lateral thoracic artery and long thoracic nerve

8. LANDMARKS OF THE DELTOID REGION

- a) Anterior and posterior margins of the deltoid muscle
- b) Clavicle
- c) Acromioclavicular joint
- d) Acromion, spine of the scapula

9. SKIN OF THE SUBCLAVIAN REGION

- a) It is thin, easily movable
- b) It contains sebaceous glands
- c) It is innervated by the supraclavicular nerve

10. BORDERS OF THE ANTERIOR REGION OF THE ARM

- a) Superior – horizontal line drawn from the pectoralis major and latissimus dorsi muscles; inferior – imaginary line drawn with 2 fingers above the lateral and medial epicondyles of the humerus
- b) Medial and lateral: vertical lines drawn on medial and lateral epicondyles of the humerus respectively.
- c) Superior – clavicle; inferior – horizontal line drawn through the 3rd rib; upper margin of the mammary gland
- d) Medial – lateral margin of the sternum; lateral – anterior margin of the deltoid muscle.

11. LANDMARKS OF THE POSTERIOR REGION OF THE ARM

- a) Deltoid muscle, pectoralis major muscle, latissimus dorsi muscle, biceps brachii muscle
- b) Triceps brachii muscle, medial and lateral epicondyles of the humerus, greater tubercle of humerus
- c) Sulcus deltoideopectoralis, sulci bicipitales lateralis et mediales

12. FORMATIONS THAT PASSÉ THROUGH THE HUMEROMUSCULAR CANAL

- a) Radial nerve
- b) Arteria ulnaris
- c) Arteria brachialis
- d) Deep artery of arm and its vein

13. INFERIOR TRILATERAL FORAMEN CONTAINS

- a) Radial nerve
- b) Arteria ulnaris

- c) Arteria brachialis
- d) Deep artery of arm

14. SUPERIOR TRILATERAL FORAMEN CONTAINS

- a) Radial nerve
- b) Circumflex scapular artery
- c) Coracobrachialis muscle

15. BORDERS OF THE QUADRILATERAL FORAMEN

- a) Medial – lateral margin of the long head of the triceps brachii muscle; lateral – surgical neck of the humerus ; superior – teres minor muscle, subscapularis muscle; inferior – teres circumflex humeral artery
- b) Medial – long head of the triceps brachii muscle; lateral – medial margin of the humerus; superior – teres major muscle.

16. LANDMARKS OF THE ELBOW REGION

- a) Triceps brachii muscle, medial and lateral epicondyles of the humerus, greater tubercle of humerus
- b) Sulcus deltoideopectoralis, sulci bicipitales lateralis et mediales
- c) olecranon of the ulna, brachioradialis muscle, tendon of the biceps brachii muscle, medial and lateralepicondyles of the humerus, sulci cubitales posteriores lateralis et medialis, sulci cubitales anteriores lateralis et medialis.

17. MUSCLES OF THE ANTERIORCUBITAL REGION

- a) Lateral: brachioradialis muscle and supinator muscle.
- b) Median: biceps brachii muscle and brachialis muscle.
- c) Medial: (1st layer) pronator teres, flexor carpi radialis, palmaris longus and flexor carpu ulnaris musles
- d) Medial: (2nd layer) flexor digitorum superficialis muscle

18. SKIN OF THE ANTERIOR REGION OF THE FOREARM

- a) It is thin
- b) It contains sweat and sebaceous glands
- c) It is innervated by the medial and lateral cutaneous nerves of the forearm

19. PIROGOV'S SPACE IS SITUATED

- a) In the upper half of the deep fascia
- b) In the lower half of the deep fascia
- c) In the superficial fascia

20. CANALIS CARPI ULNARIS

- a) Contains tendon of the flexor carpi radialis muscle

- b) It is formed by a fascia between the flexor retinaculum and bones (scaphoid bone, trapezium bone, pisiform bone and hamate bone)
- c) It is formed by a fascia around the pisiform bone; this canal contains ulnar artery and nerve; then it passes under the palmaris brevis muscle

21. SULCUS RADIALIS

- a) It is lodged between the flexor carpi ulnaris and flexor digitorum superficialis muscles; it contains the ulnar artery, vein and nerve
- b) It lies between the brachioradialis and flexor carpi radialis muscles; it contains the superficial branch of the radial nerve, radial artery and vein
- c) It lies between the flexor carpi radialis and flexor digitorum superficialis muscles; it contains the medial nerve.

22. SULCUS ULNARIS

- a) It is lodged between the flexor carpi ulnaris and flexor digitorum superficialis muscles; it contains the ulnar artery, vein and nerve
- b) It lies between the brachioradialis and flexor carpi radialis muscles; it contains the superficial branch of the radial nerve, radial artery and vein
- c) It lies between the flexor carpi radialis and flexor digitorum superficialis muscles; it contains the medial nerve.

23. SULCUS MEDIANUS

- a) It is lodged between the flexor carpi ulnaris and flexor digitorum superficialis muscles; it contains the ulnar artery, vein and nerve
- b) It lies between the brachioradialis and flexor carpi radialis muscles; it contains the superficial branch of the radial nerve, radial artery and vein
- c) It lies between the flexor carpi radialis and flexor digitorum superficialis muscles; it contains the medial nerve.

24. CANALIS CARPI ULNARIS

- a) It contains the tendon of the flexor carpi radialis
- b) It contains the ulnar artery, vein and nerve
- c) It contains the superficial branch of the radial nerve and palmar branch of the radial artery

25. CANALIS CARPI RADIALIS

- a) It contains the tendon of the flexor carpi radialis
- b) It contains the ulnar artery, vein and nerve
- c) It contains the superficial branch of the radial nerve and palmar branch of the radial artery

TEST ANSWERS

1-a	6 -a	11 -a,b,c	16 - c	21 - b
2-a,b,c,d	7 -c	12 - a,d	17 - a,b,c,d	22 - a
3 - a,c	8 - a,b,c,d	13 -a,d	18 - a,b,c	23 - c
4 - a,b,c,d	9 - a,b,c	14 - b	19 - b	24 - b
5 -a,c,d	10 - a,b	15 - a	20 - c	25 - a,c

REFERENCES

Basic literature

1. Oskar Schultze, George D. Stewart. *Atlas and Textbook of Topographic and Applied: - Forensics* 2012. – 382p.
2. Tsyhykalo O.V. *Topographical anatomy and operative surgery: Textbook for english-speaking foreign students: - Nova Knyha Publishers*, 2011. — 528 p.
3. Fominykh T.A., Verchenko I.A. *Topographic anatomy and operative surgery: -* 2011. – 316p.

Additional literature

1. Frank. H. Netter. V.L. *Atlas of Human Anatomy*. M .: GEOTAR Media, 2011. – 600p.
2. Kagan I.I.T *Topographic Anatomy and Operative Surgery: textbook.-* M:GZOATAR-Media, 2012 – 512 p

Учебное пособие

Clinical anatomy of the upper extremity

Составители:

Геннадий Игнатьевич Сонголов,

Ольга Павловна Галеева,

Редков Сергей Николаевич,

Подпись в печать 11.12.15. Формат 60x84.1/16.

Тираж 10 экз. Заказ №1160. Гарнитура TimesNewRoman.

Бумага офсетная. Печать ризография. Усл. печ. л. 14,54

Отпечатано в типографии «Вектор»

г. Иркутск, ул. Гагарина, 74