



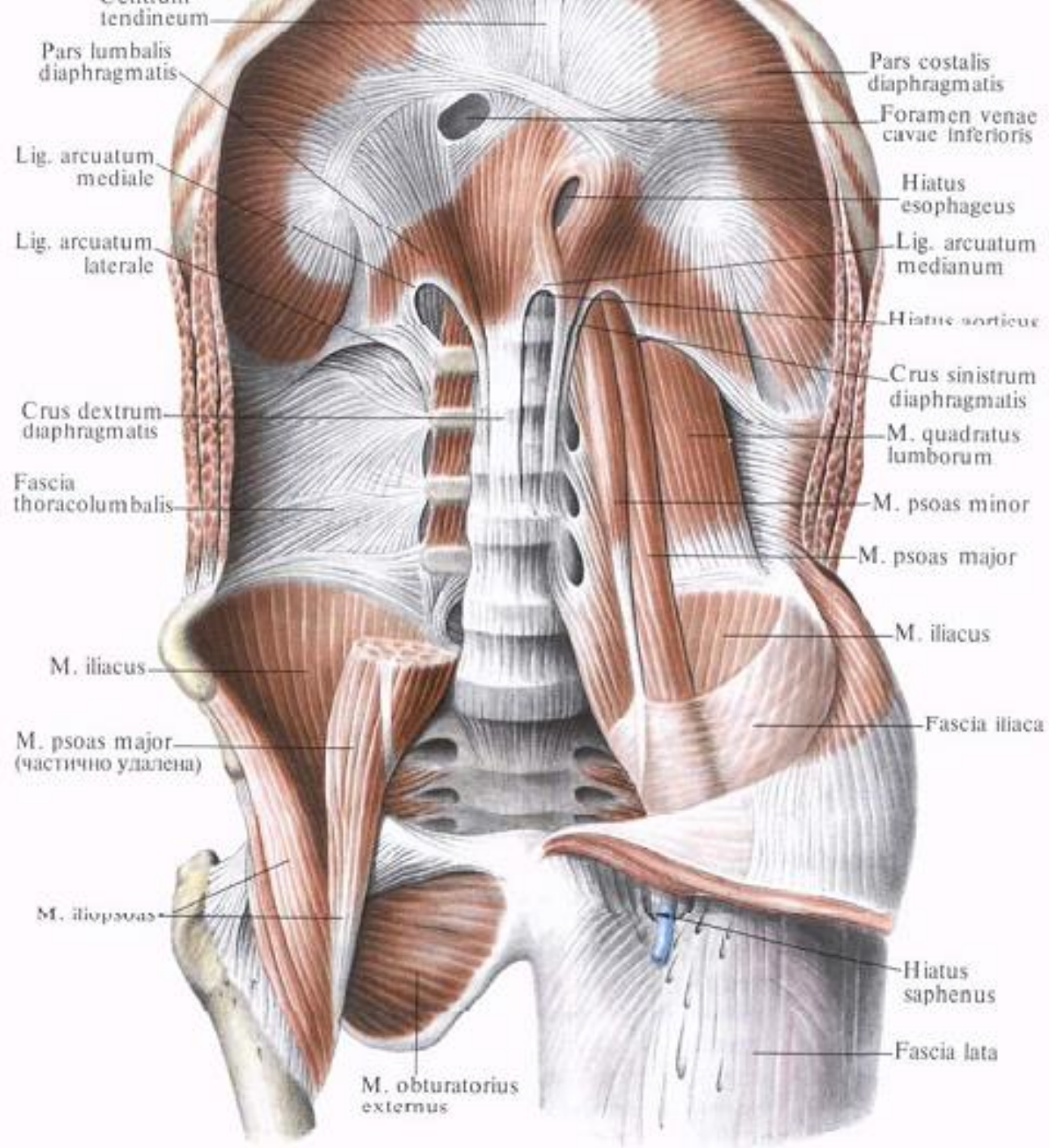
State Medical and Pharmaceutical University

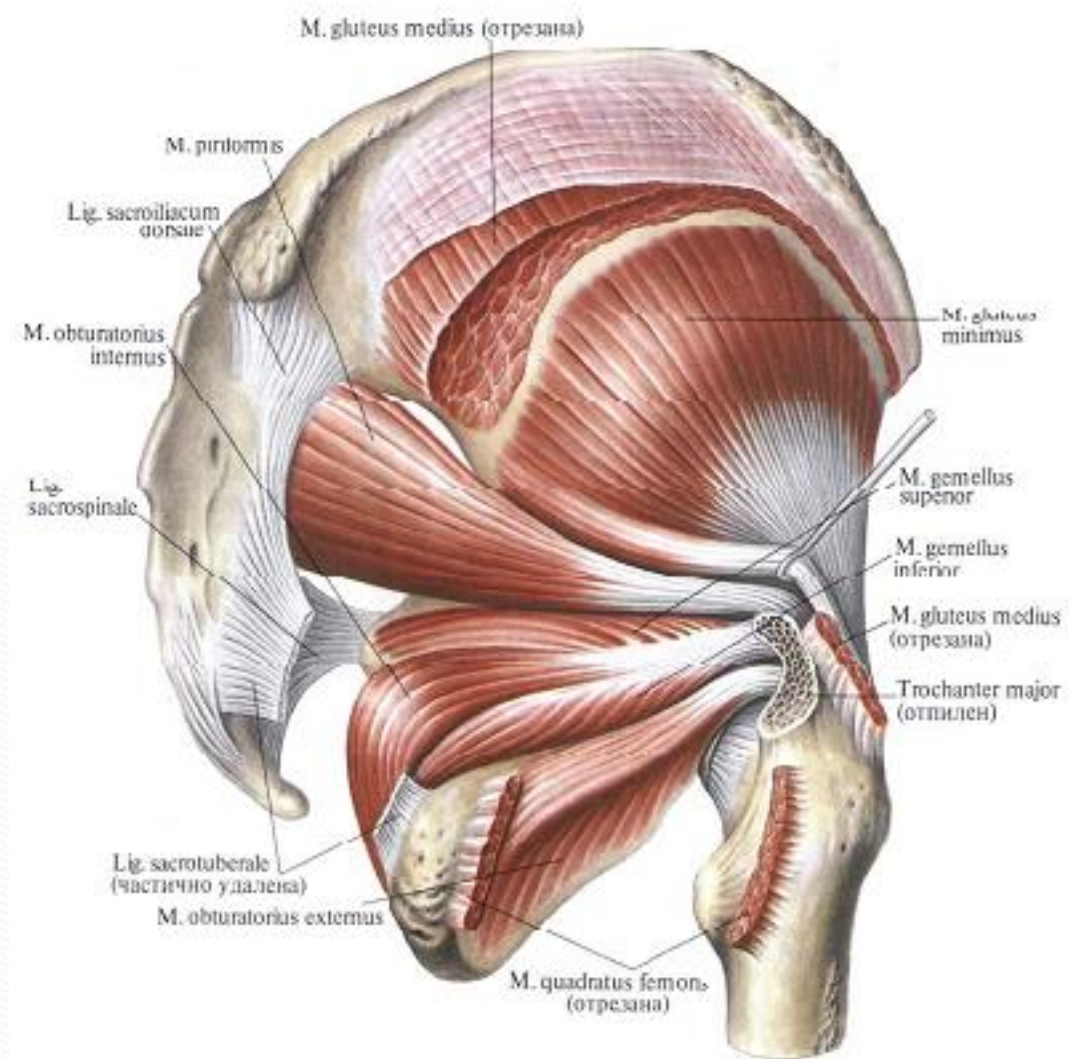

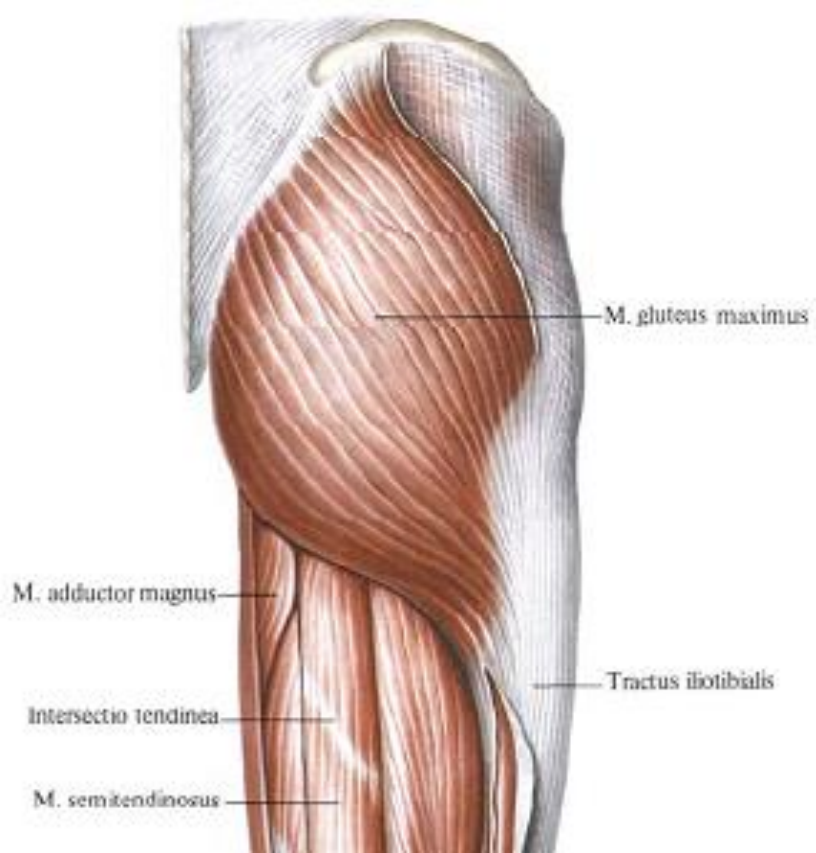
“Nicolae Testemitanu”

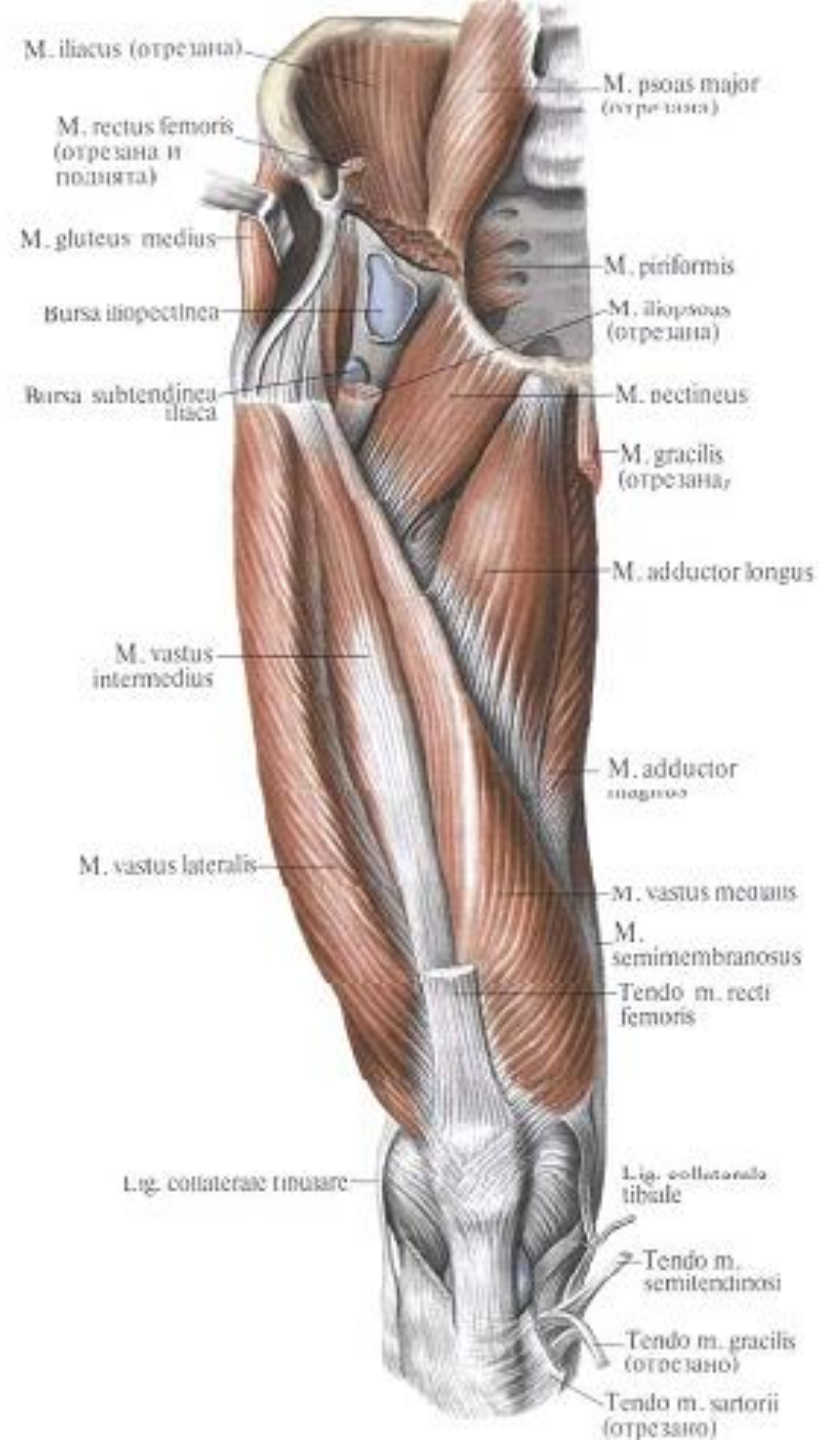
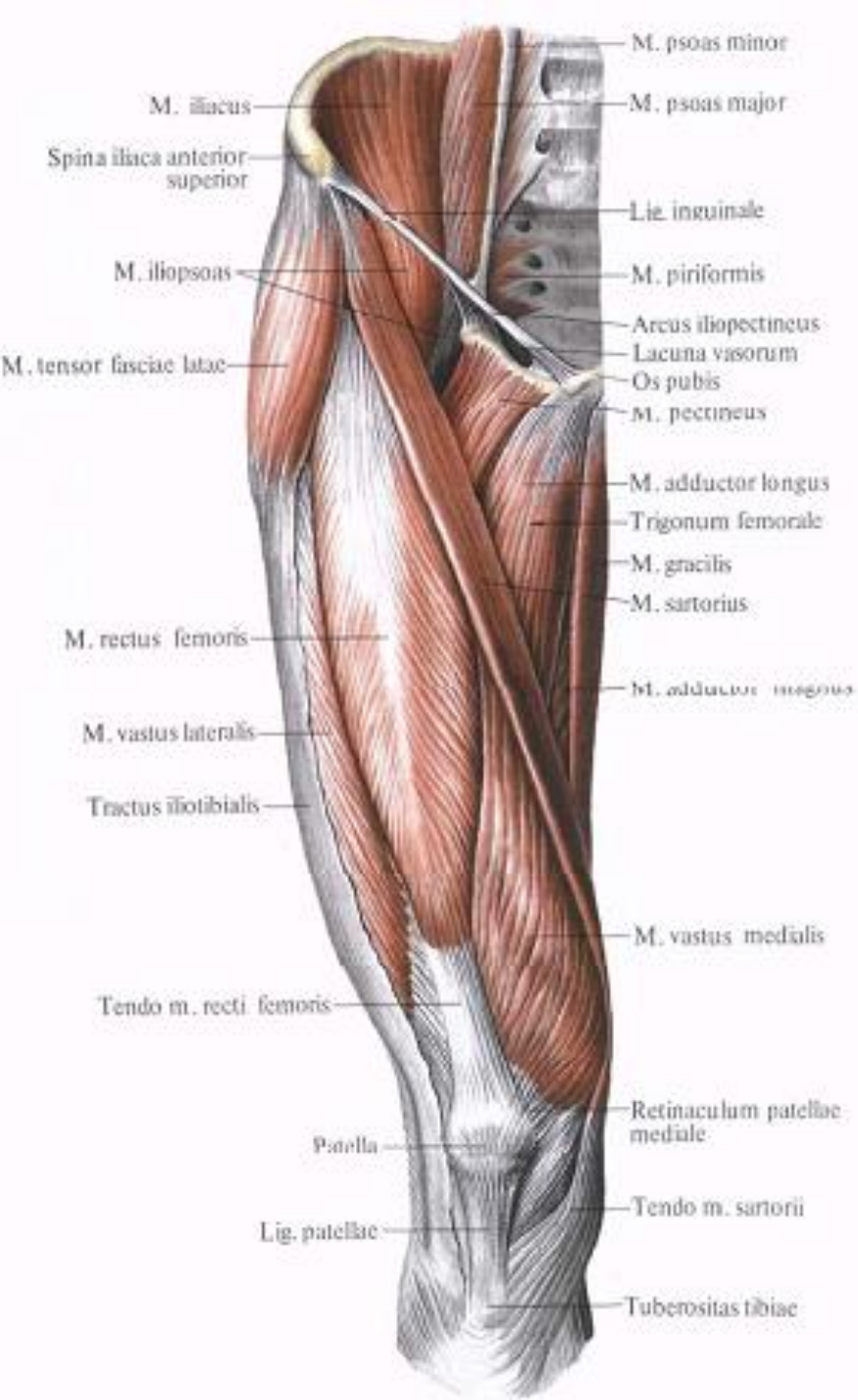Anatomy Department

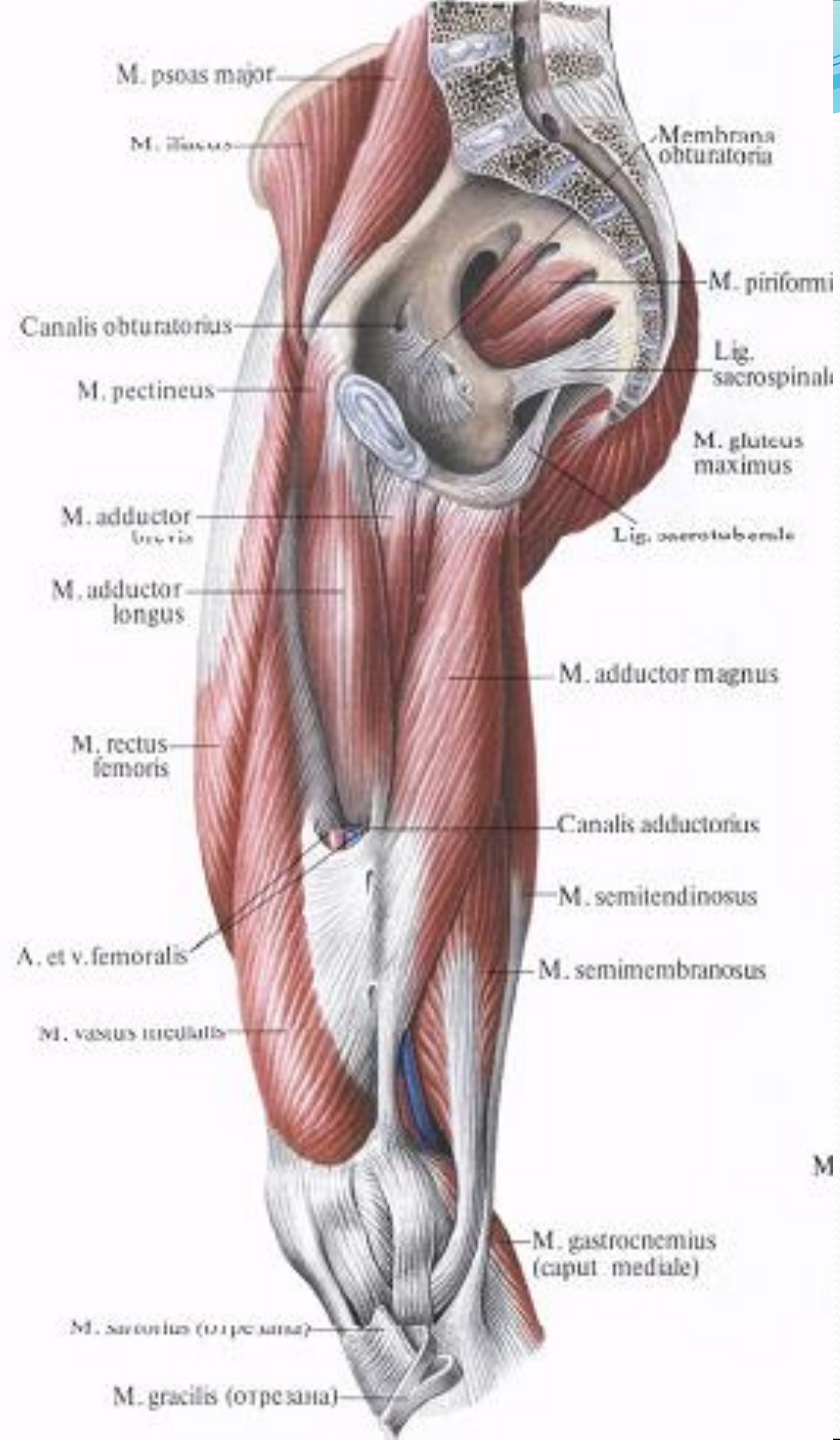
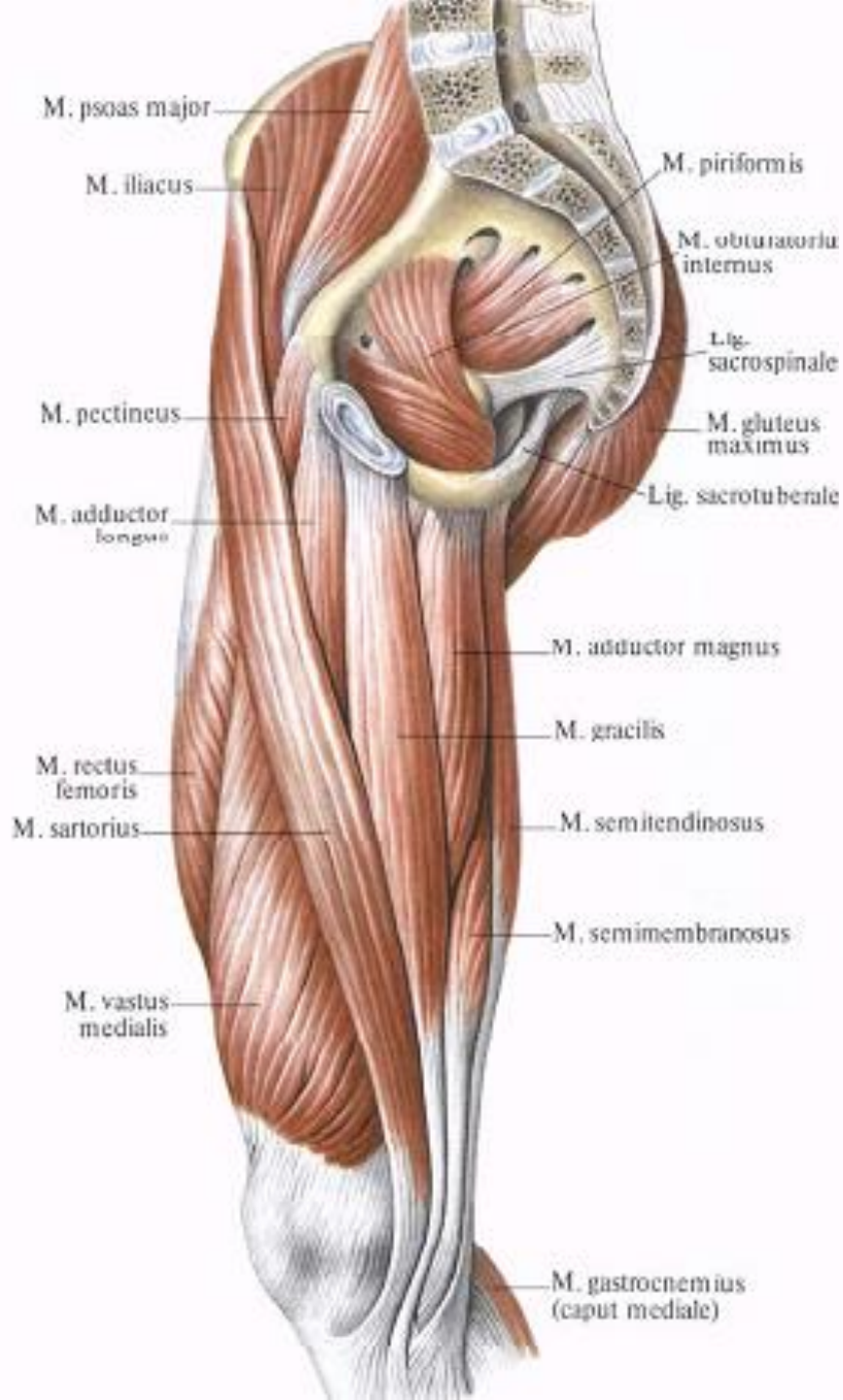
Functional Anatomy of Muscles of the Lower Limb

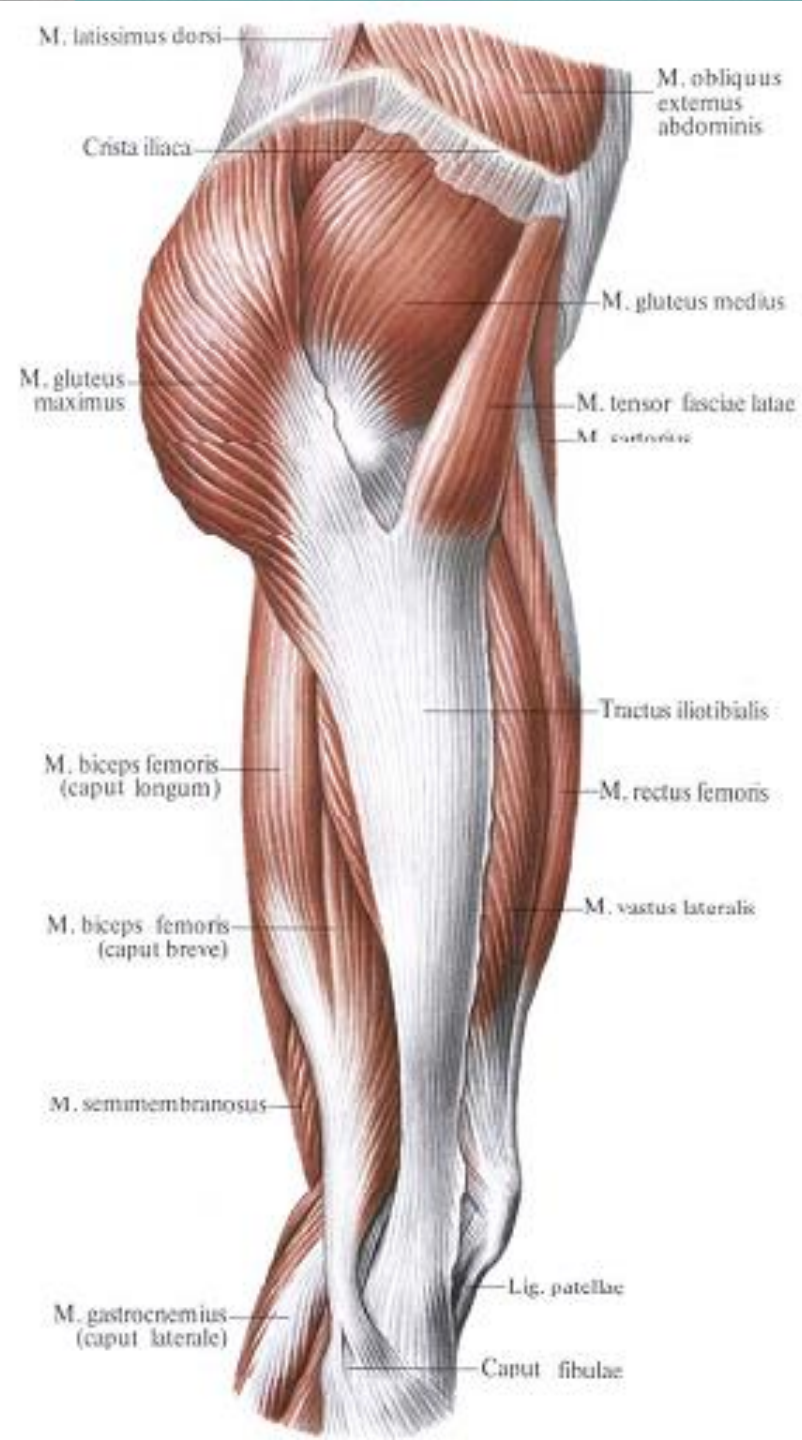
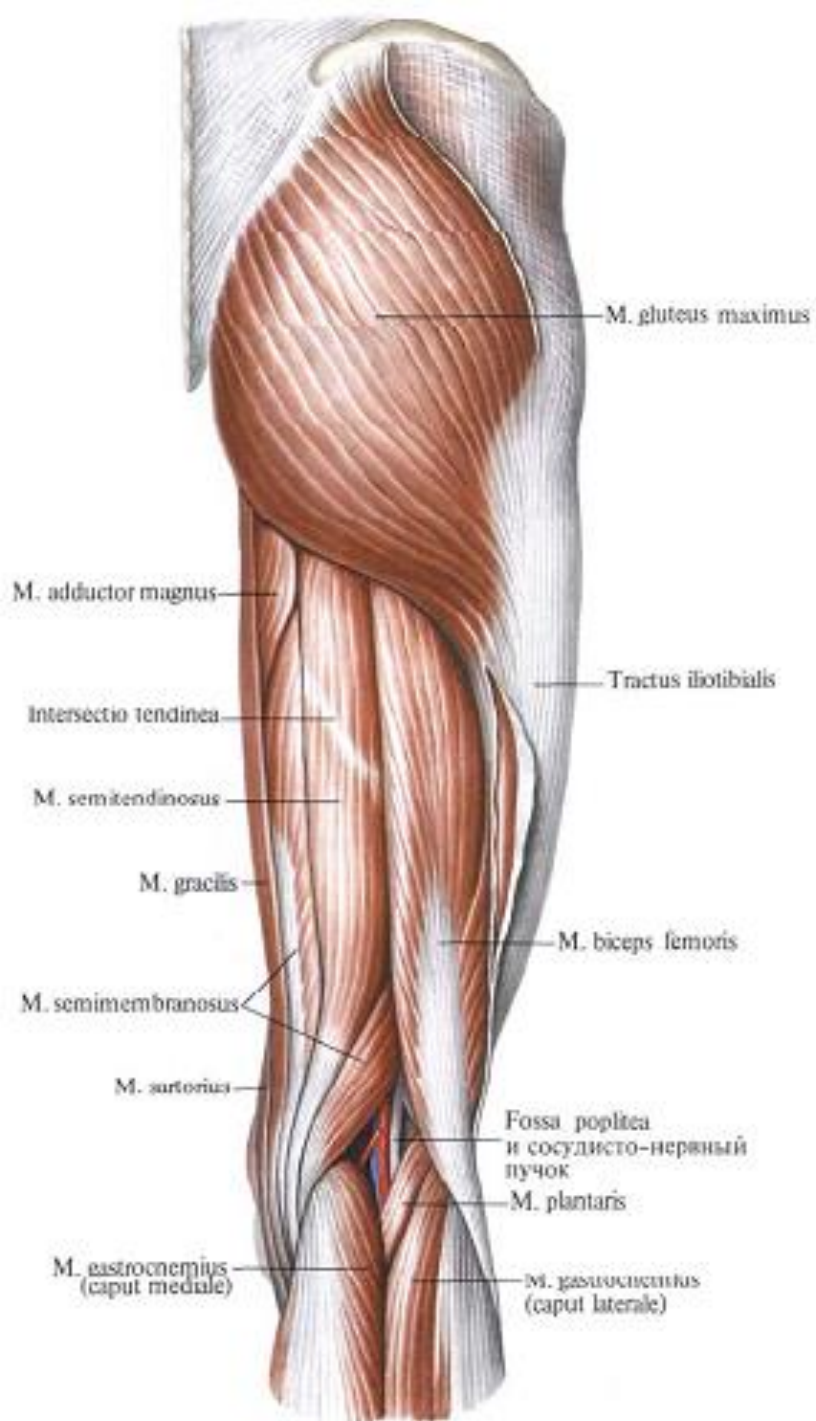
Lecturer **Globa Lilian**

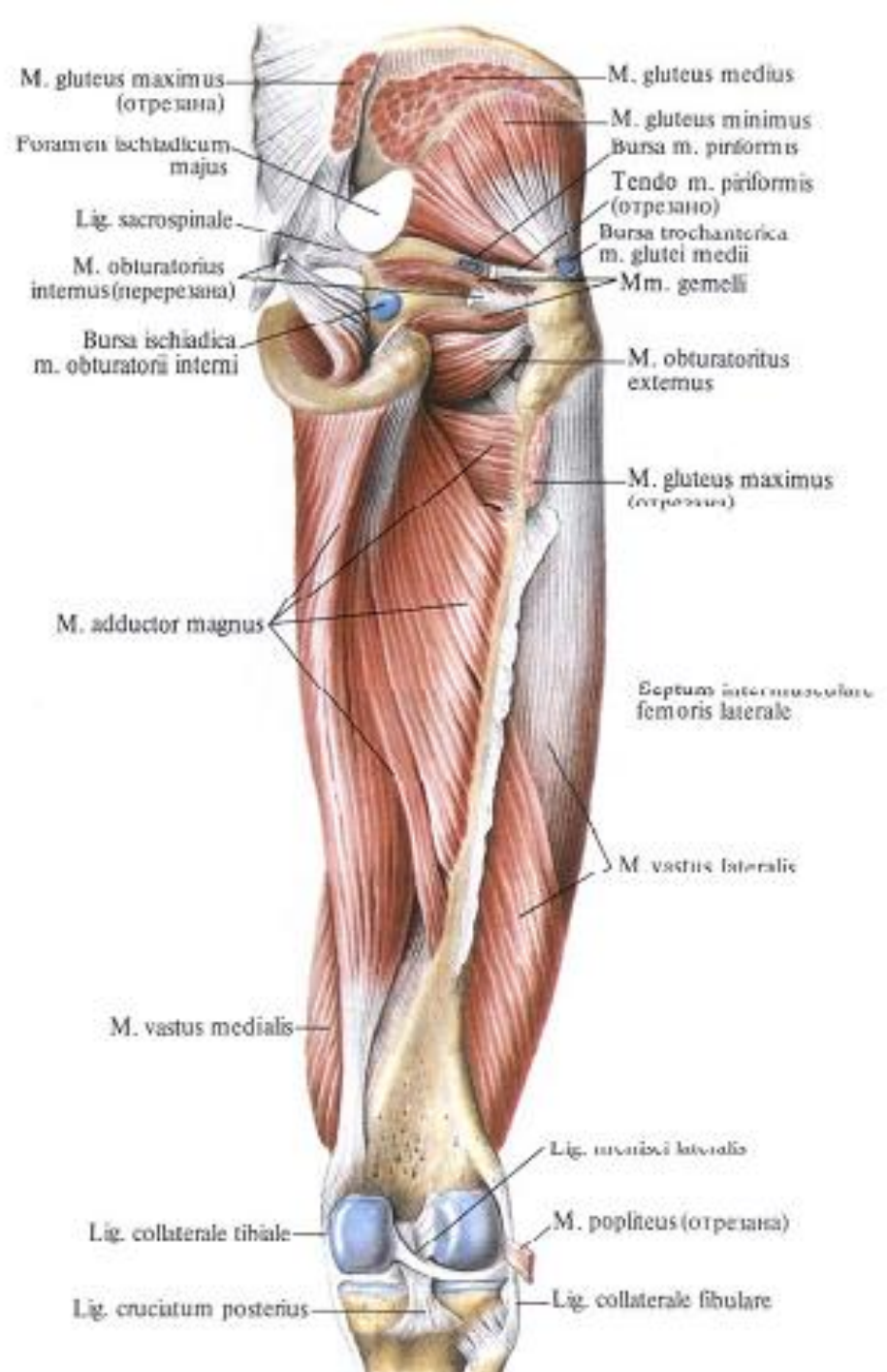
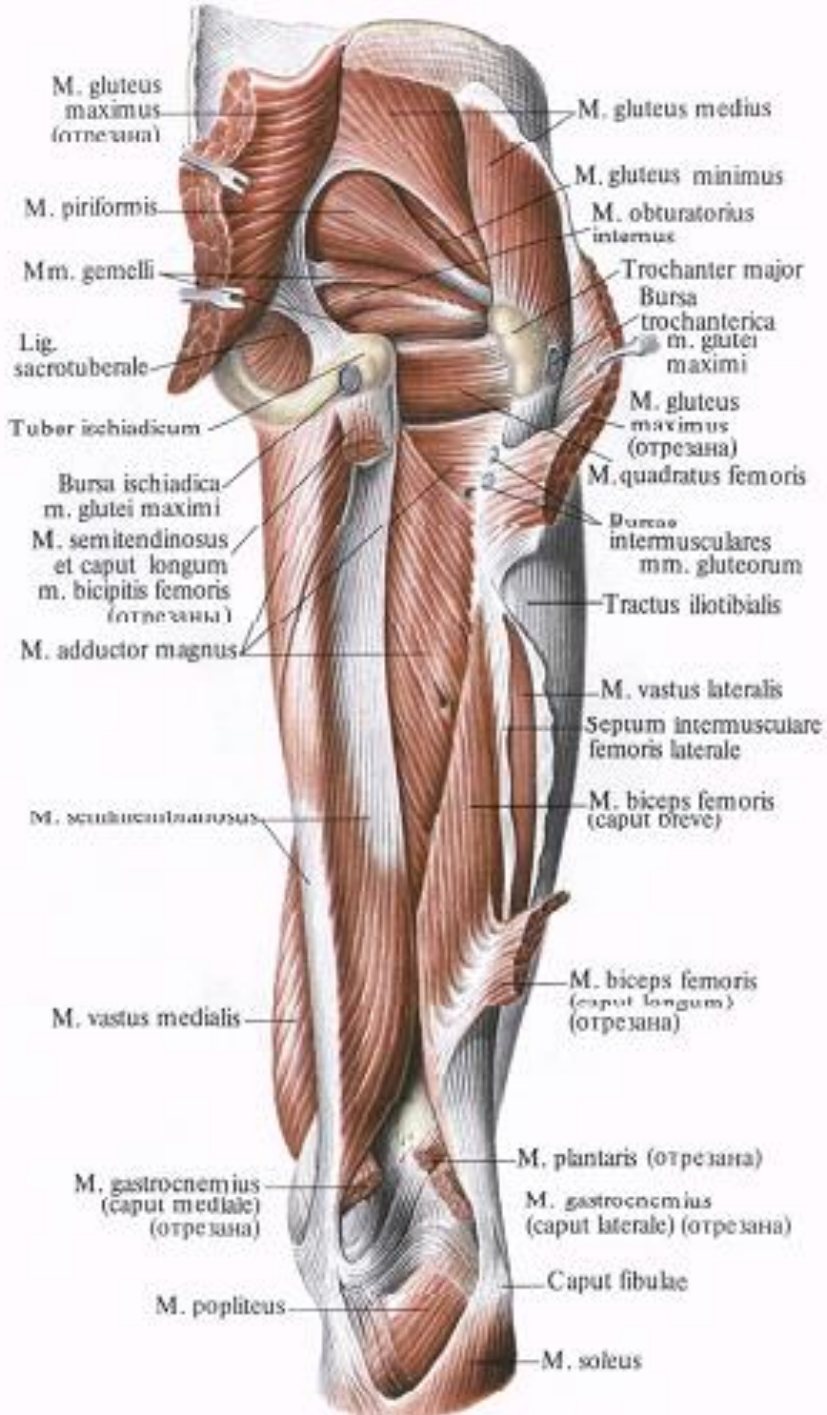


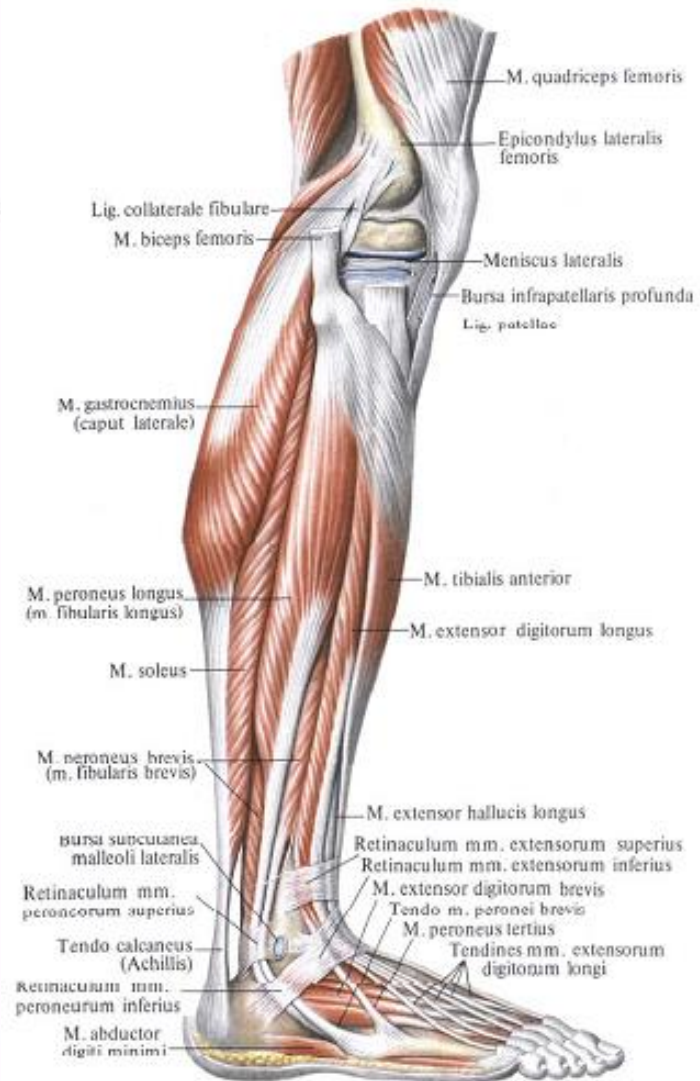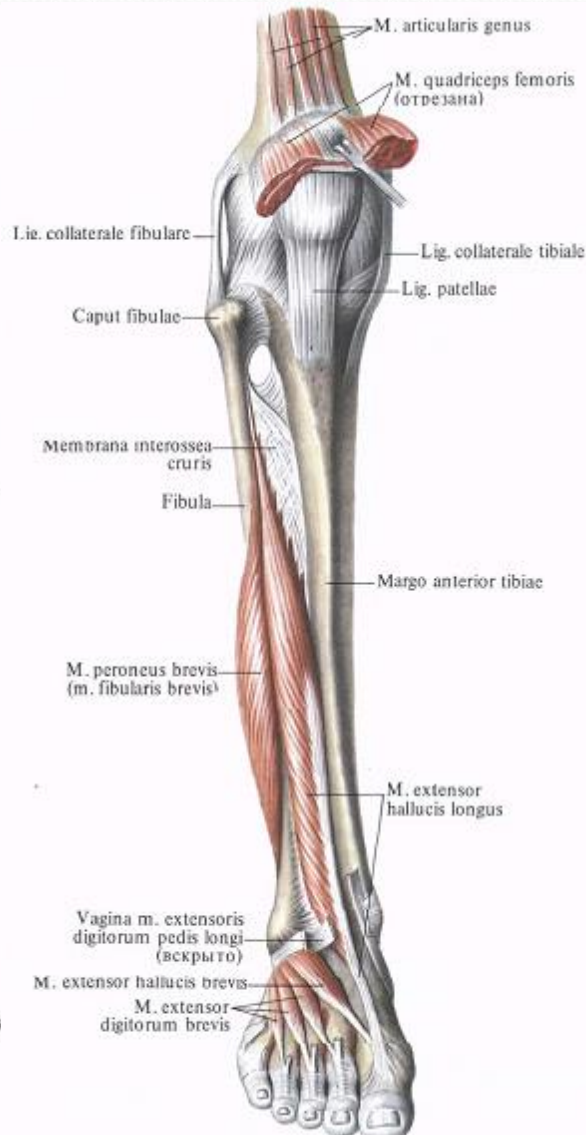

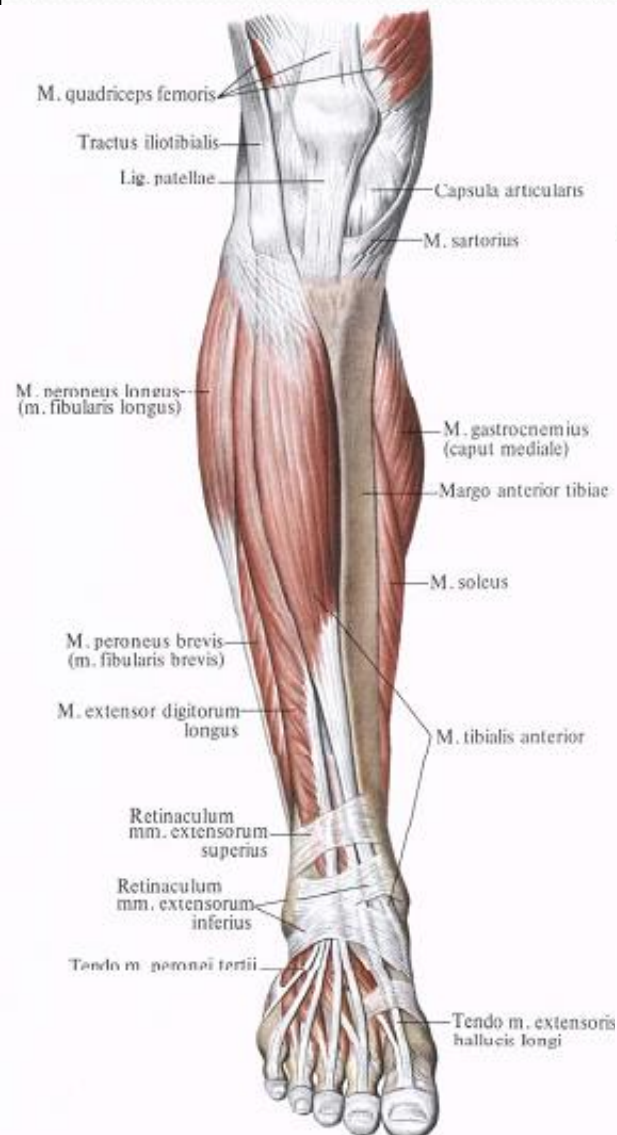
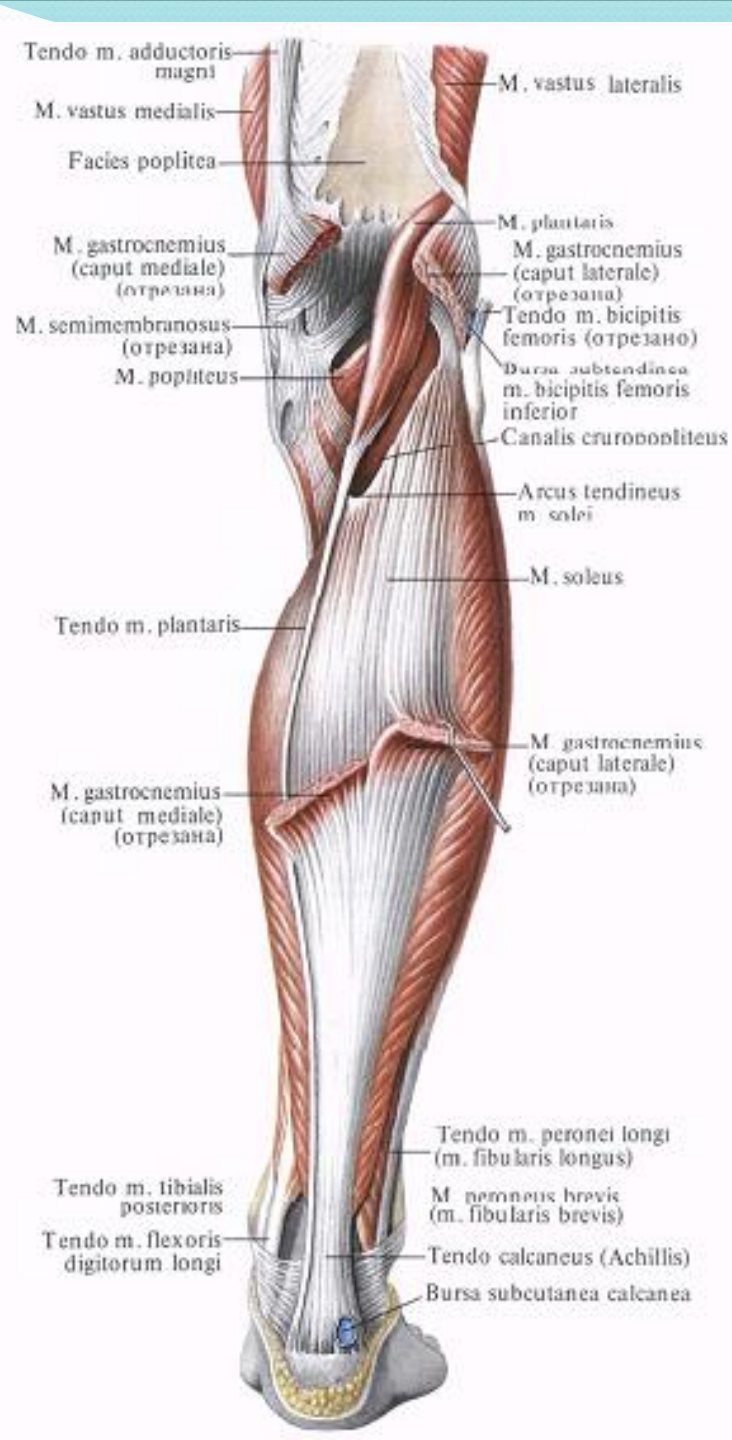
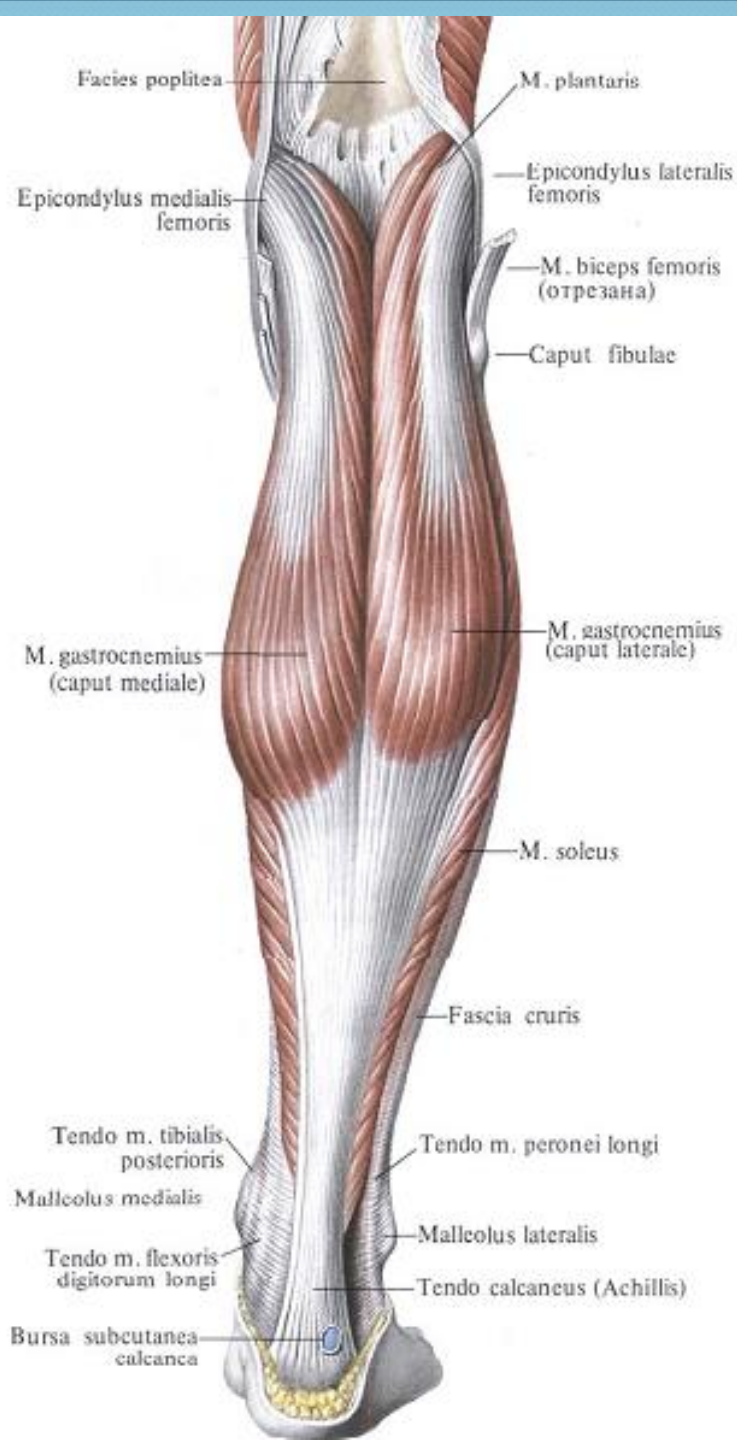


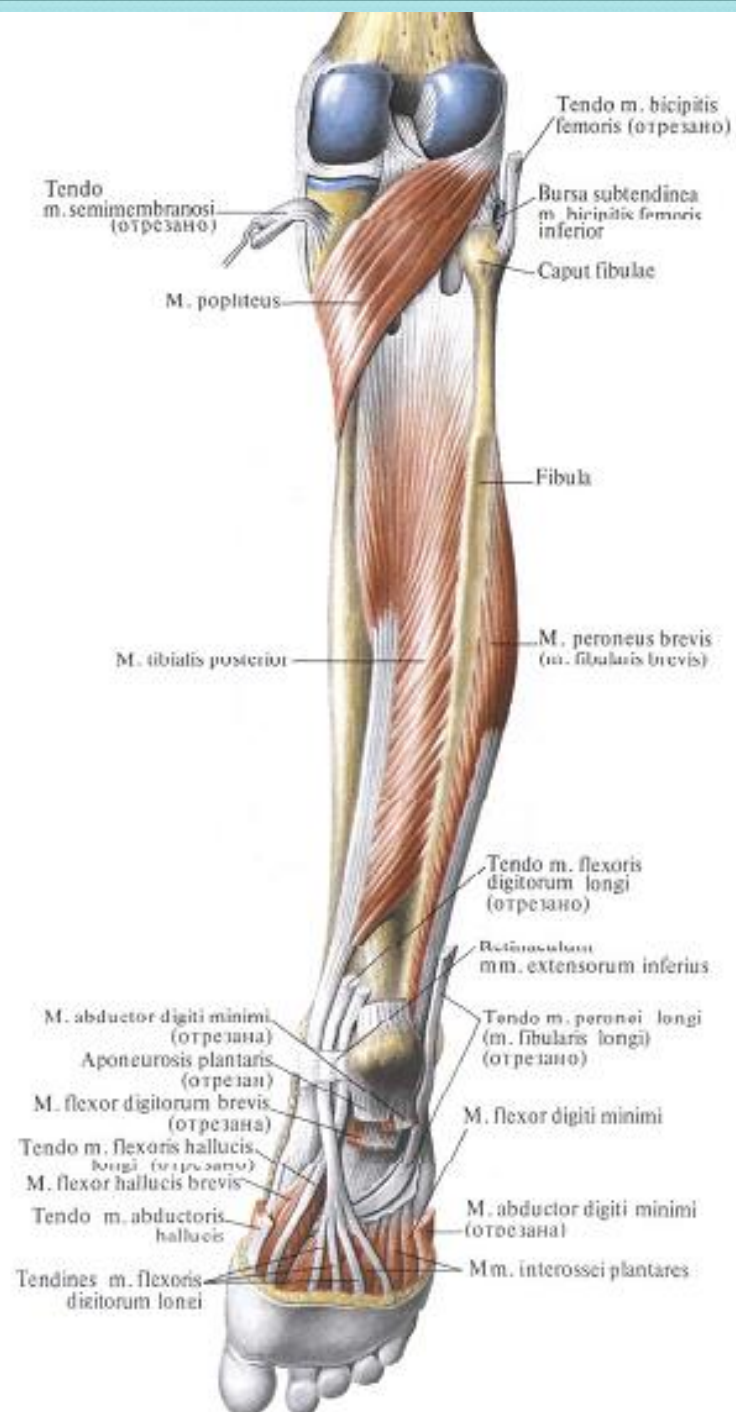
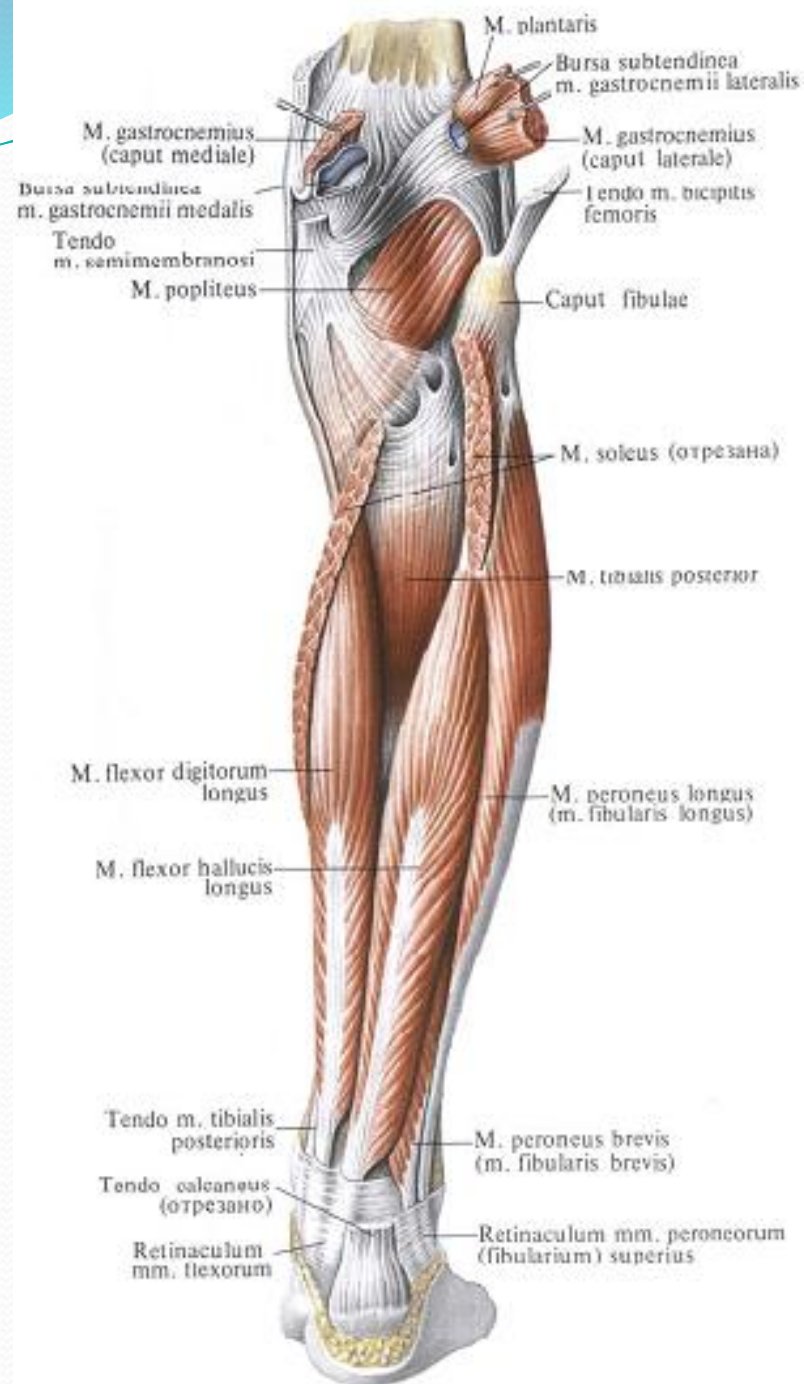


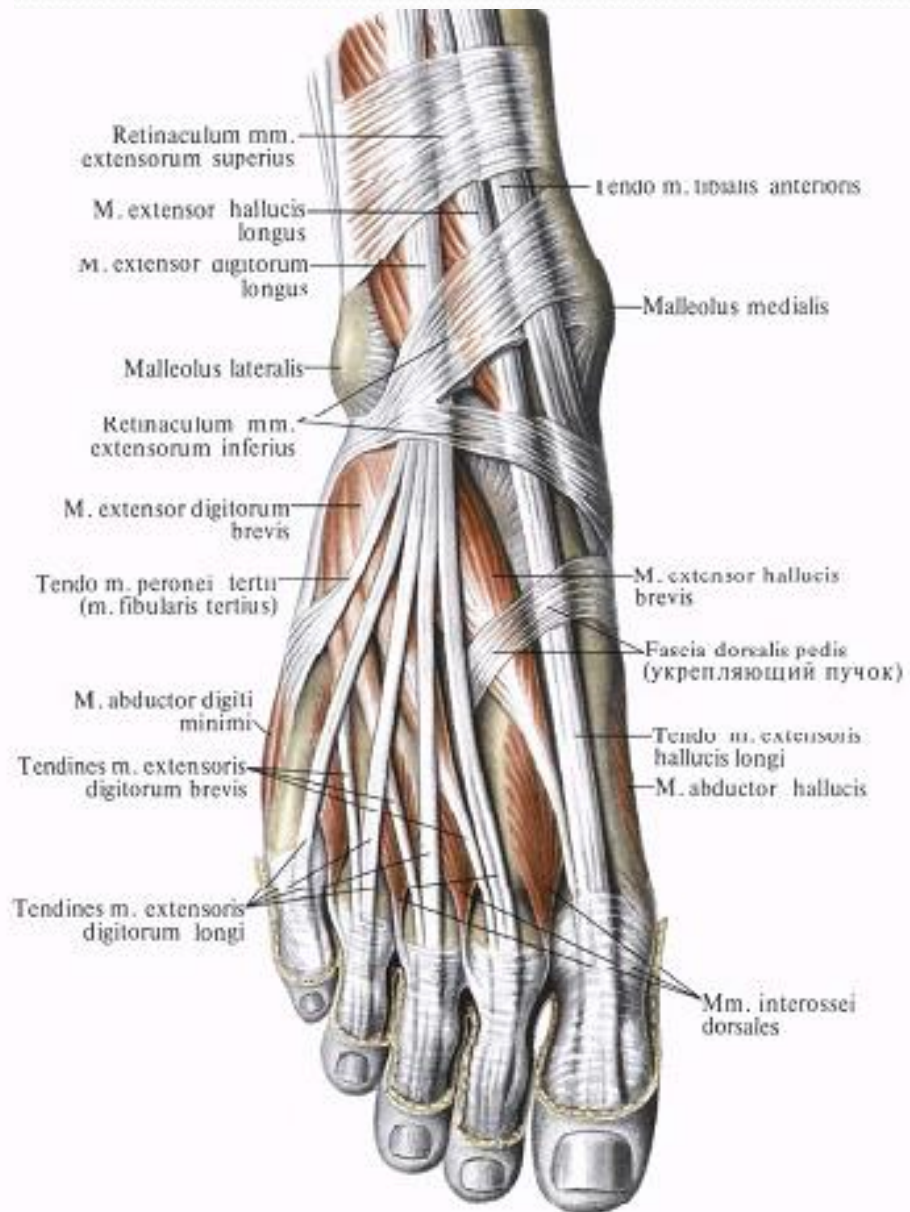
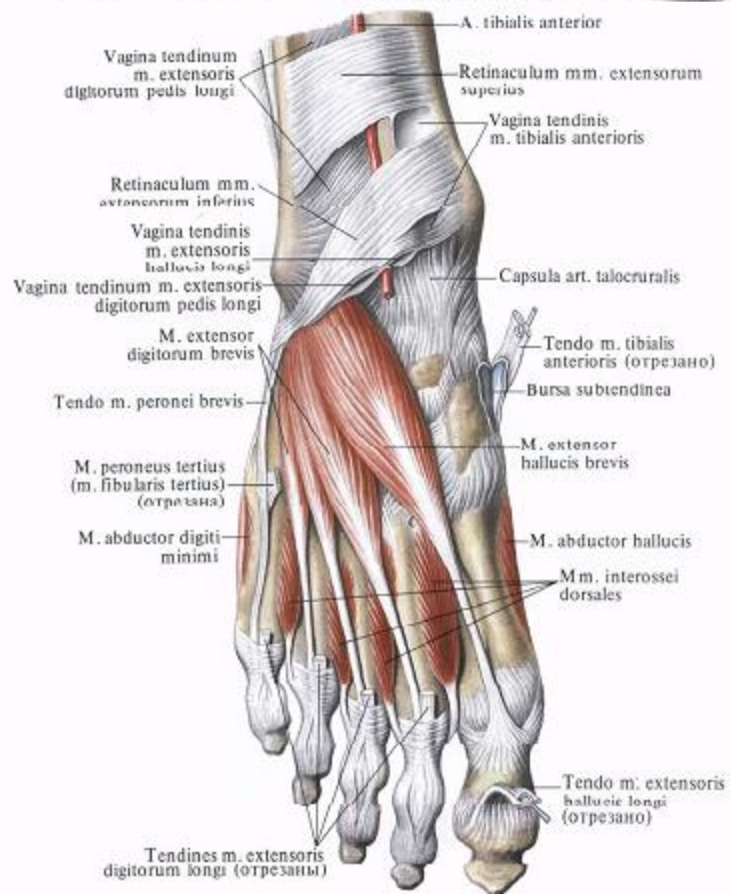
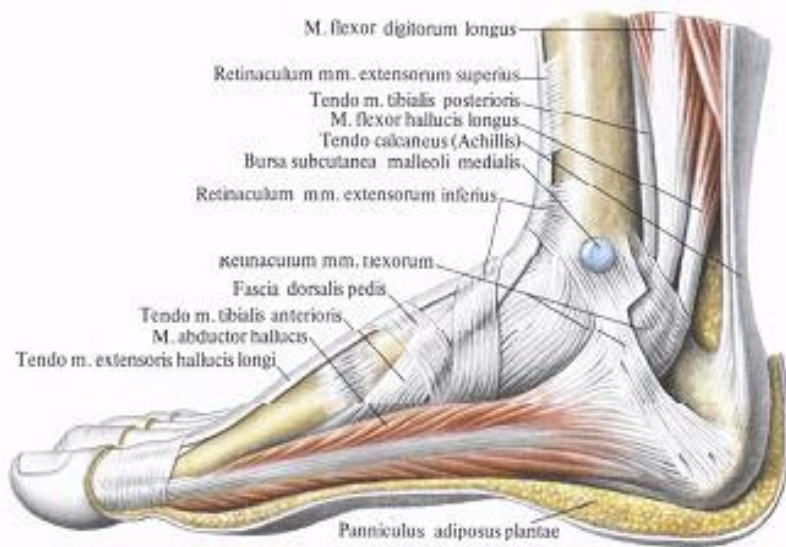


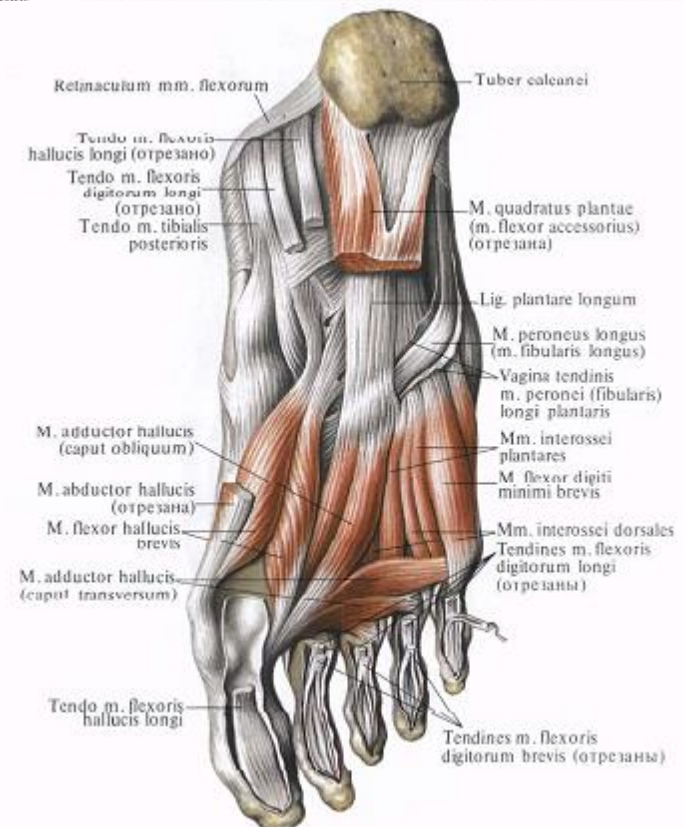
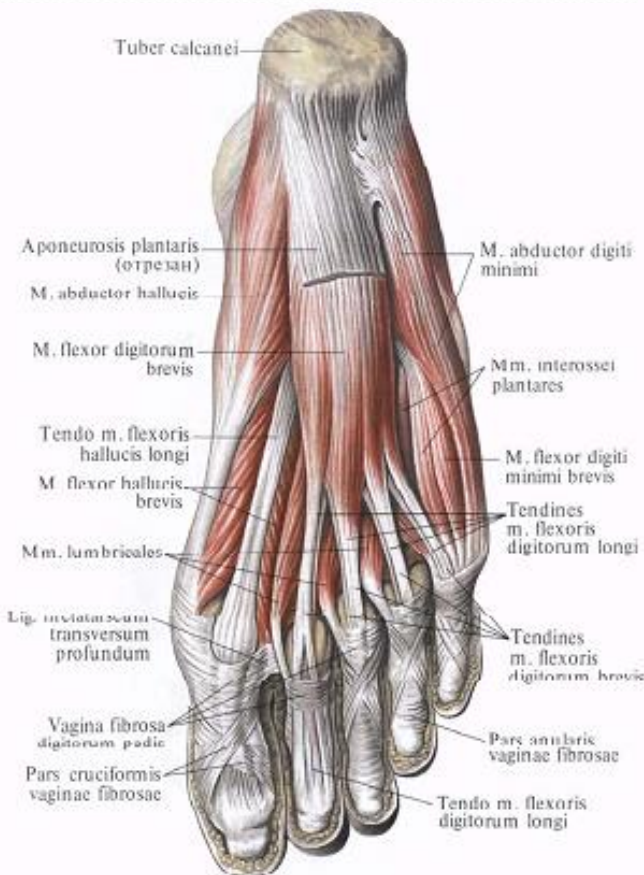
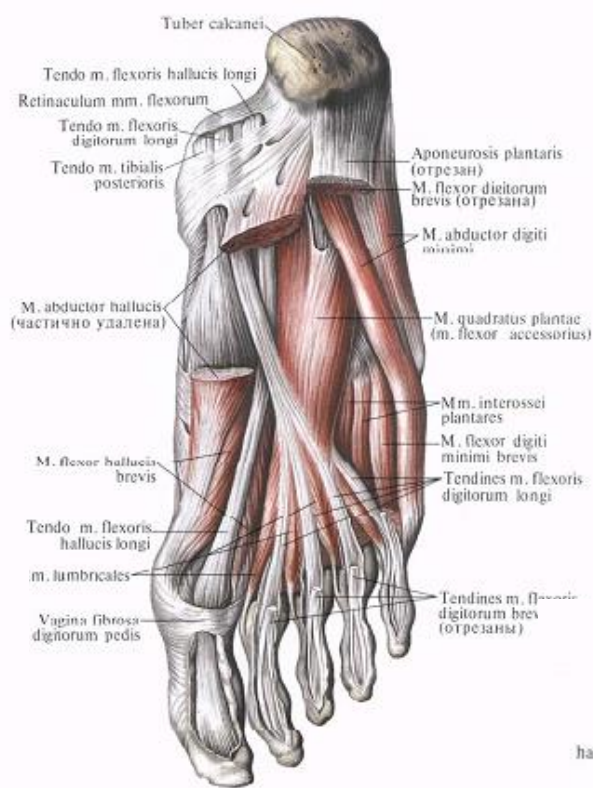


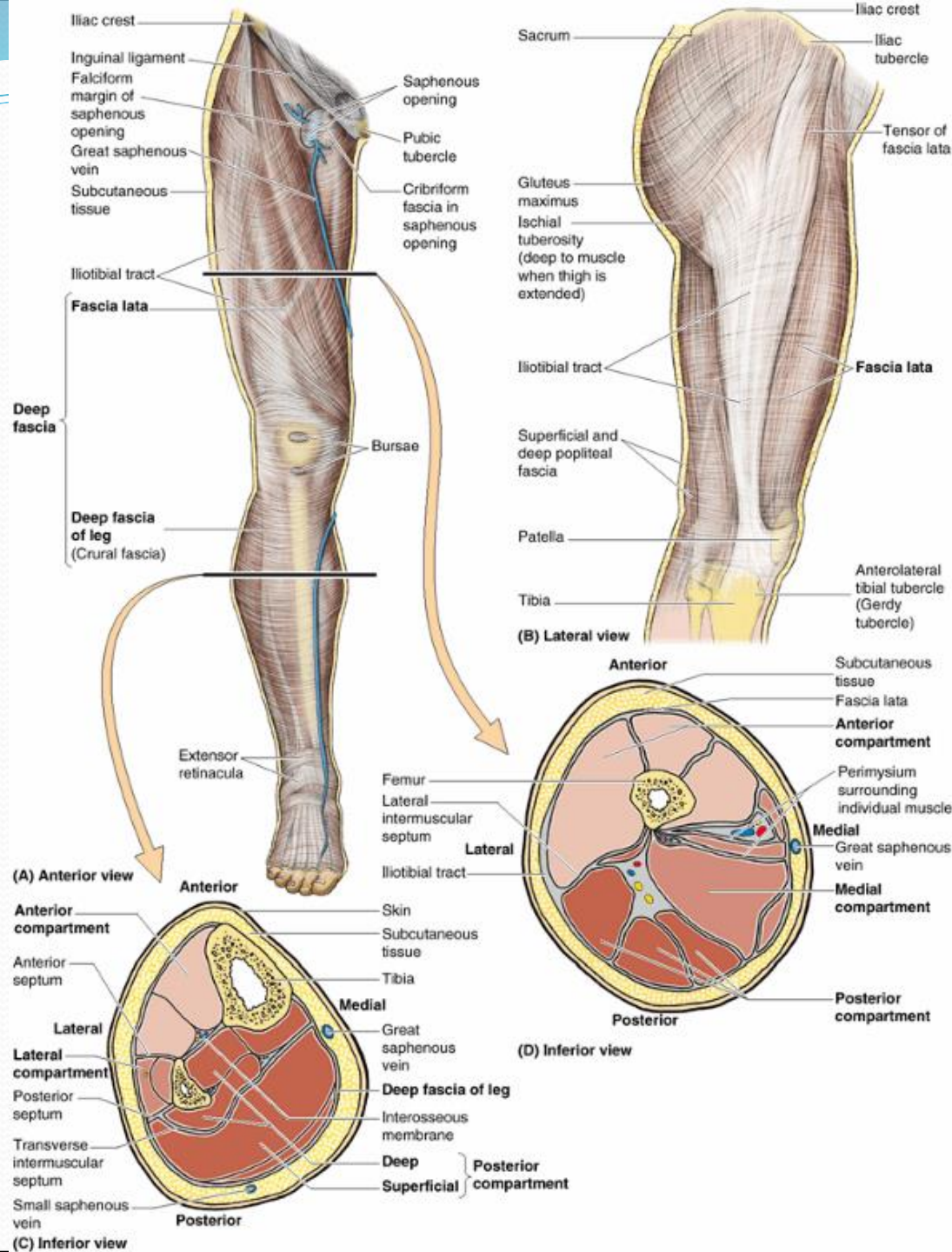


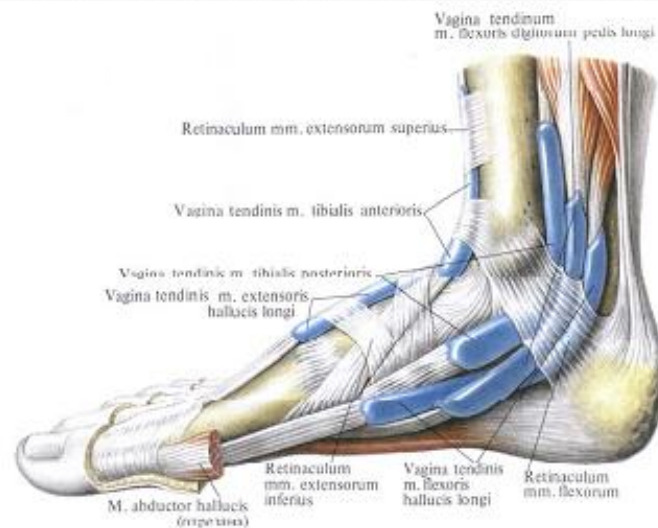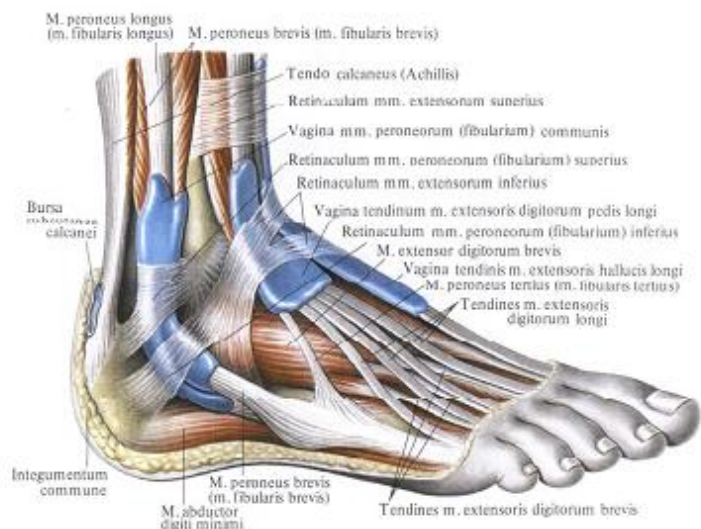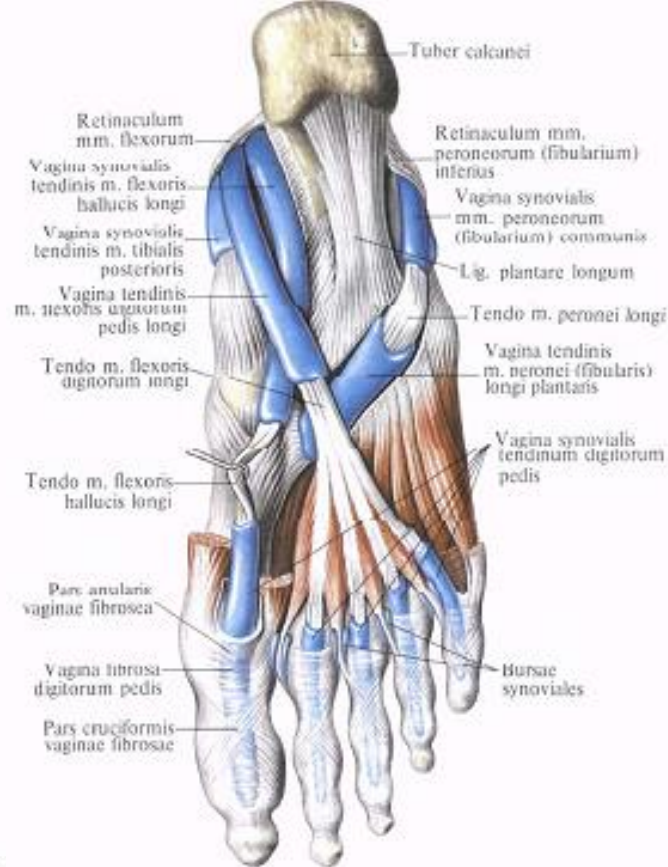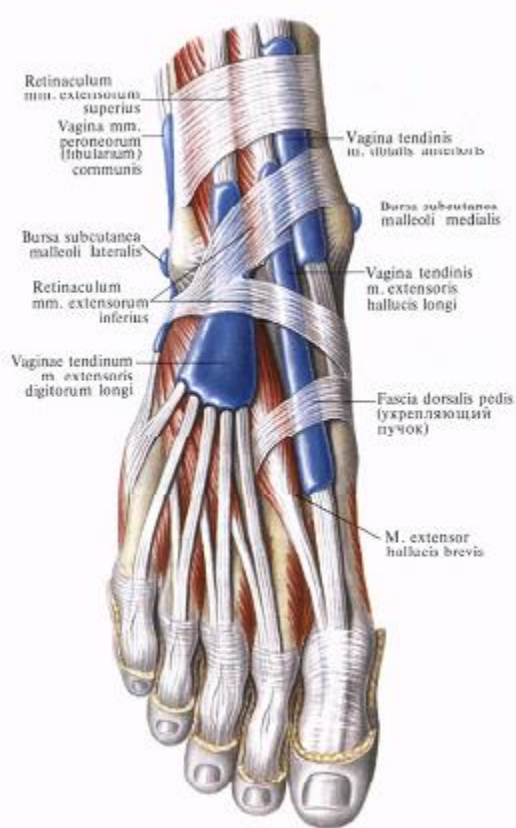


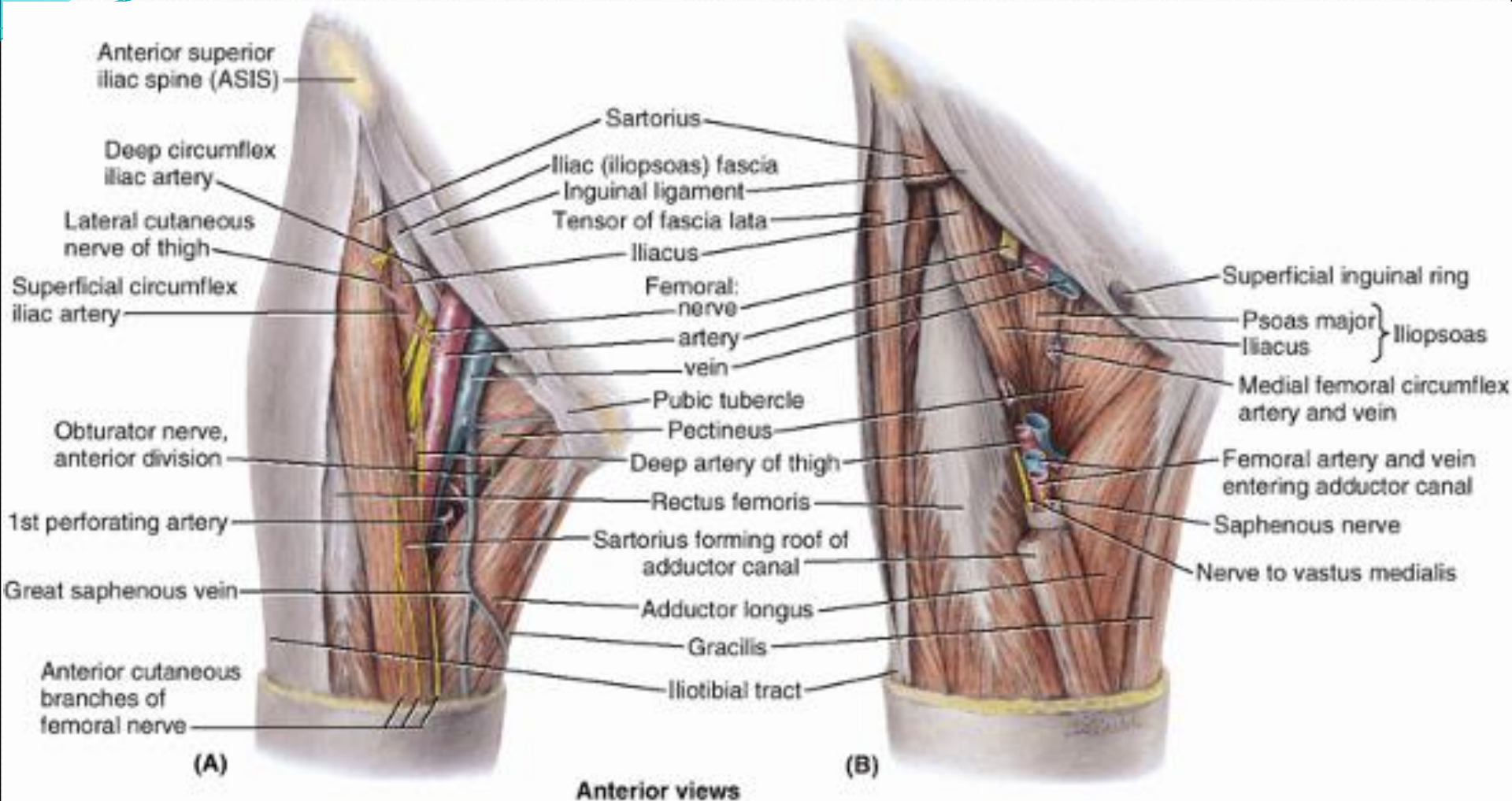


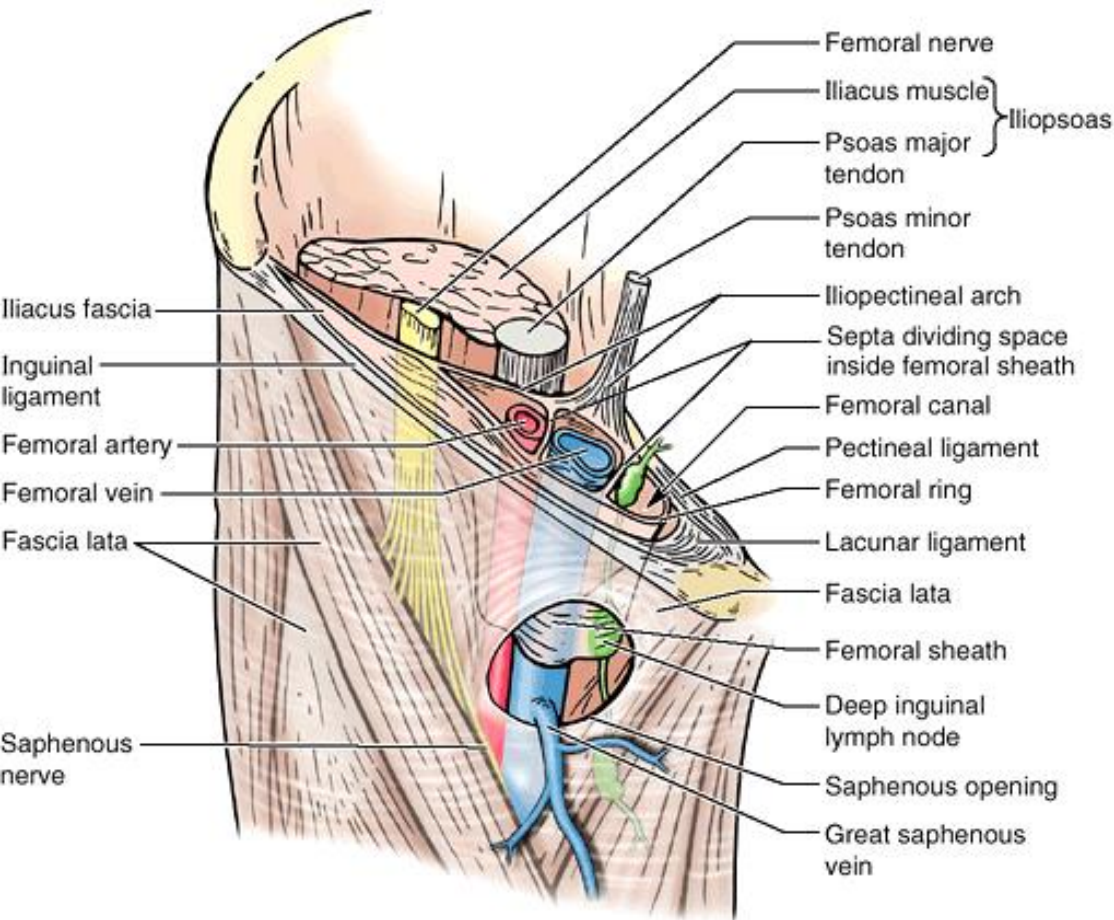









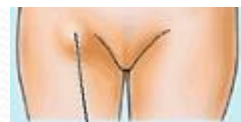
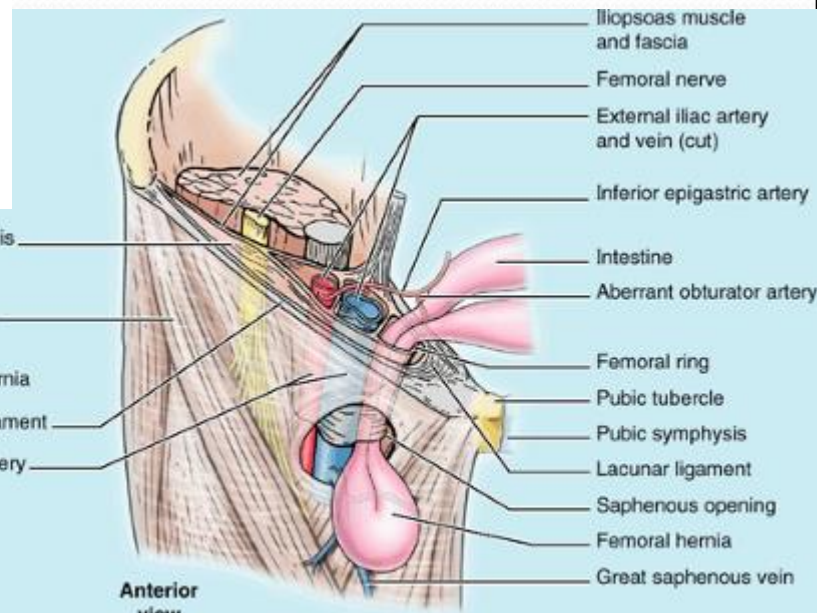


Anterior view



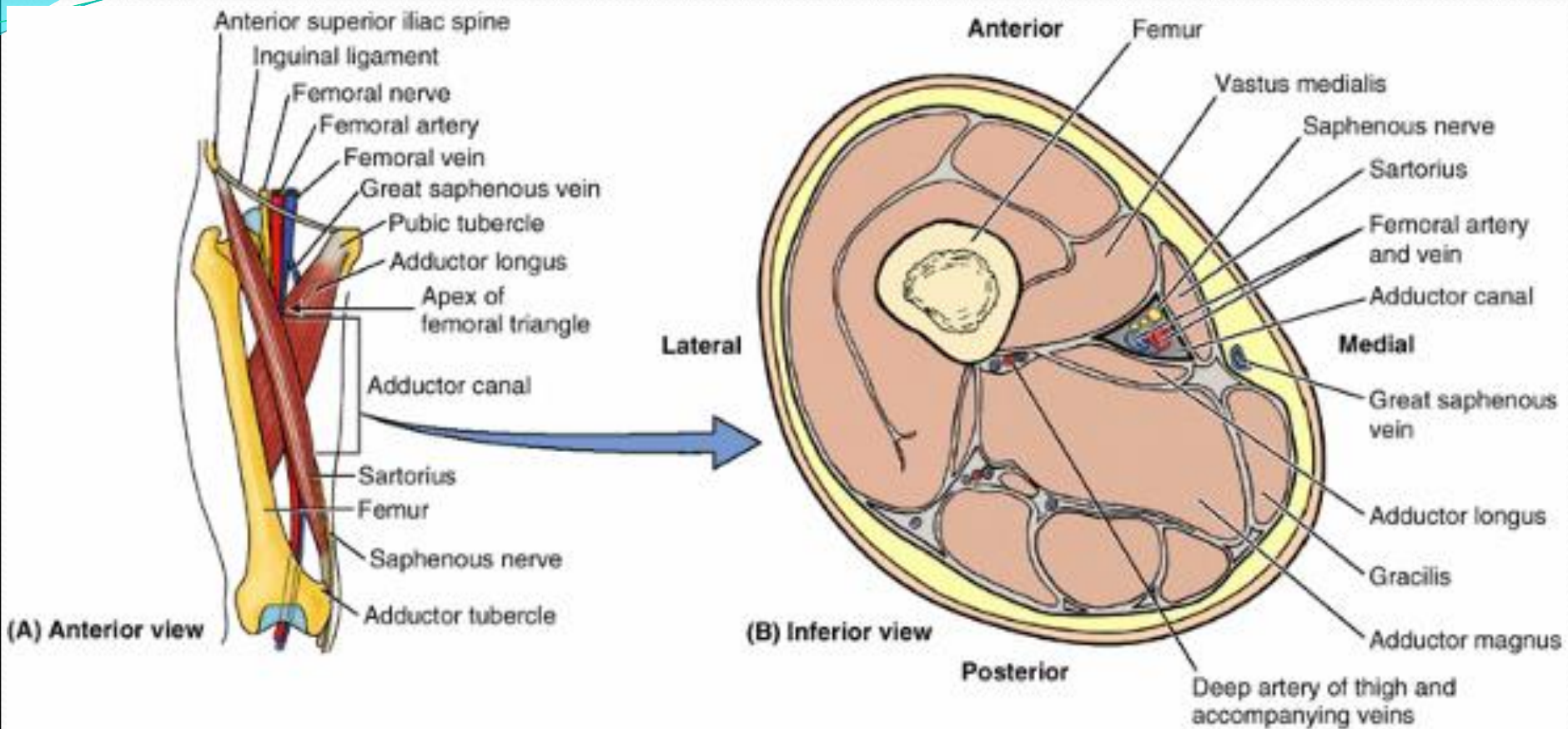
Transversalis fascia
Fascia lata
Femoral hernia
Inguinal ligament
Femoral artery and vein

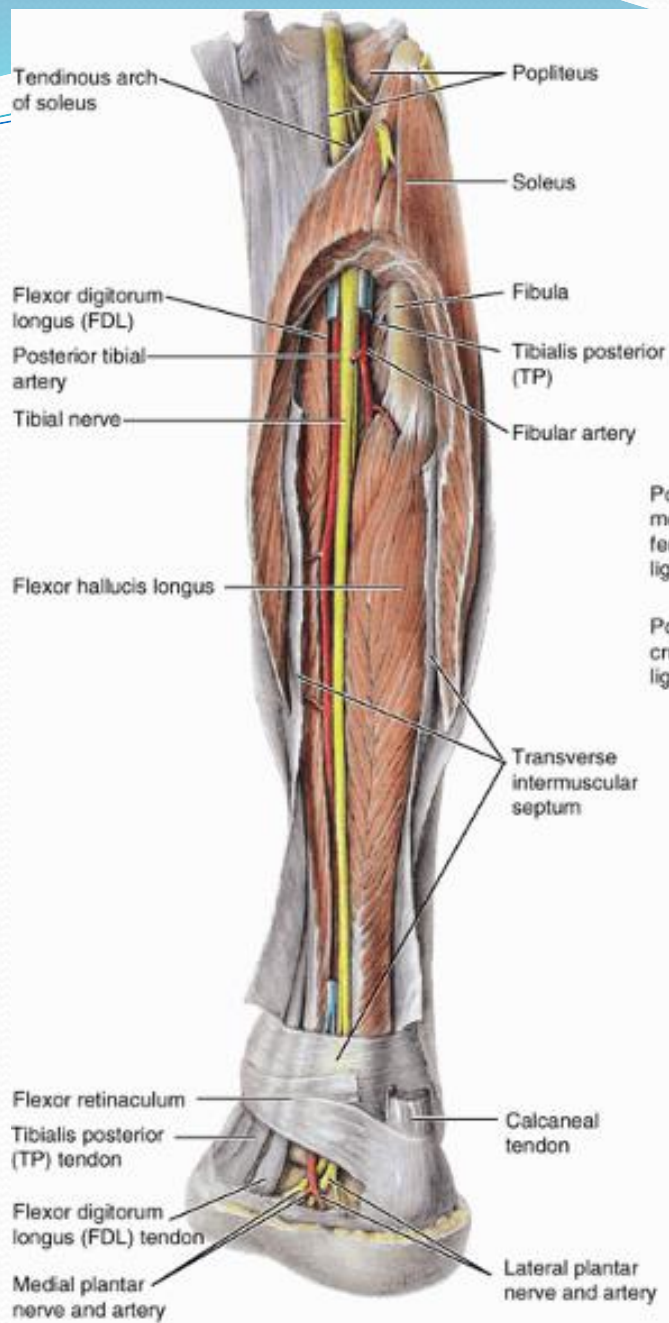
Early stage



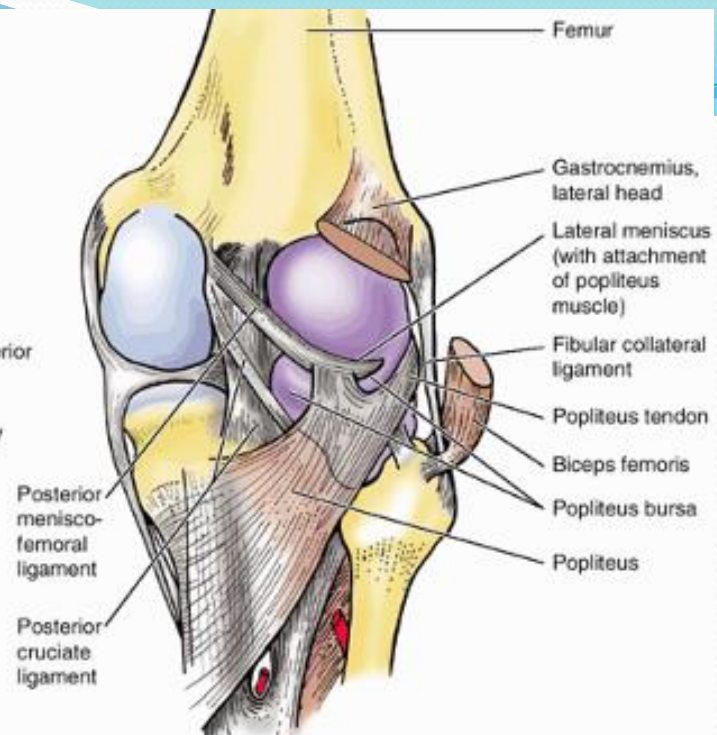
Anterior view

Late stage

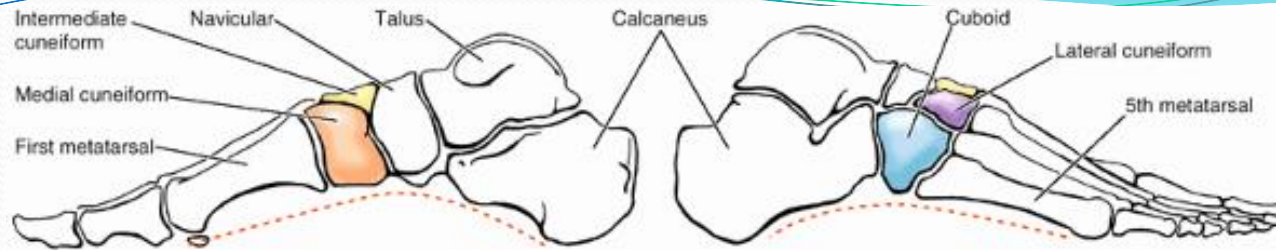




(A) Posteromedial view

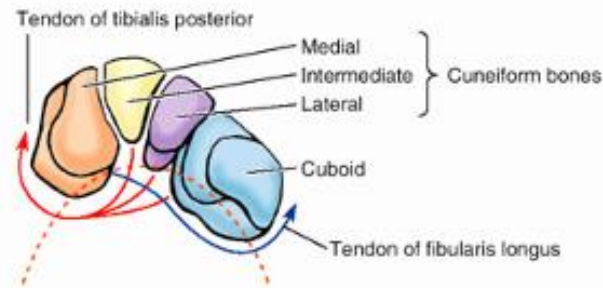


(B) Posterior aspect of the knee joint

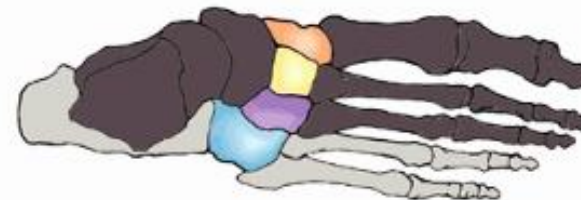

(A) Medial longitudinal arch (medial view)

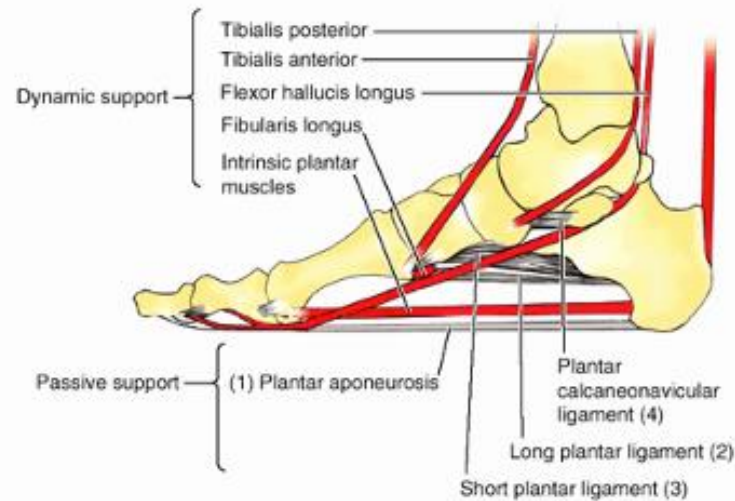
(B) Lateral longitudinal arch (lateral view)



(C) Transverse arch (anterior view)



(D) Superior view



(E) Medial longitudinal arch (medial view)