

**Universitatea de Stat de Medicină și Farmacie „Nicolae Testemițanu”**

**Catedra de anatomie și anatomie clinică**

**Test set  
for Clinical Anatomy**

Chișinău – 2021

## UPPER LIMB

### INFRACLAVICULAR REGION

- Boundaries of the infraclavicular region are:
  - inferior border of the major pectoral muscle
  - edge of the sternum**
  - anterior border of the deltoid muscle**
  - clavicle**
  - 3<sup>rd</sup> rib**
- Which fascia forms the capsule of the mammary gland?
  - pectoral fascia
  - clavipectoral fascia
  - superficial fascia**
  - transversal fascia
  - endothoracic fascia
- Determine which of the following statements are true:
  - the sheath of pectoralis major muscle represents superficial fascia
  - the sheath of pectoralis major muscle is formed by pectoral fascia**
  - retromammar space is limited by pectoral fascia end sheath of mammary gland**
  - pectoralis major muscle forms the anterior wall of the superficial subpectoral space**
  - pectoralis major muscle is surrounded by clavipectoral fascia
- The deep lamina of pectoral fascia is called:
  - coracoclavicothalis fascia**
  - pectoral fascia
  - endocervical fascia
  - clavipectoral fascia**
  - Gruber's fascia**
- The following statements are true:
  - deltoidopectoral triangle is limited by: clavicle, deltoid muscle and pectoralis major muscle**
  - the cephalic vein is situated in the deltoidopectoral triangle**
  - supraclavicular nerves are situated in the subcutaneous layer of infraclavicular region**
  - superficial fascia forms the suspensory ligament of mammary gland**
  - the cephalic vein flows into the basilic vein
- The sheath of which muscle is formed by clavipectoral fascia?
  - subclavicular muscles**
  - serratus anterior muscle
  - pectoralis minor muscle**
  - deltoid muscle
  - and pectoral major muscle
- Superficial subpectoral space is limited by:
  - posteriorly by pectoralis minor muscle and clavipectoral fascia**
  - anteriorly by posterior face of pectoralis major muscle**
  - posteriorly by superficial fascia
  - anteriorly by anterior lamina of pectoralis fascia
  - inferiorly by suspensory ligament of axilla
- Deep subpectoral space is located between:
  - subcutaneous fatty tissue
  - pectoralis major muscle and posterior lamina of its fascial sheath
  - anterior and posterior laminae of the clavipectoral fascia
  - posterior surface of pectoralis minor muscle and posterior lamina of clavipectoral fascia**
  - posterior lamina of pectoral fascia
- The collection of pus from the superficial subpectoral space may spread to other regions along the following structures:
  - cephalic vein**

- b) supreme thoracic artery
  - c) coracohumeral ligament
  - d) thoracoacromial artery and anterior thoracic nerves**
  - e) lateral thoracic artery and vein
10. Clavipectoral fascia inserts on the following structures:
- a) clavicle**
  - b) coracoid process of the scapula**
  - c) medial edge of sternum
  - d) ribs I-V**
  - e) pectoralis major muscle
11. The mammary gland is innervated by:
- a) branches of the intercostal nerves II-VII**
  - b) branches of the cervical plexus**
  - c) anterior thoracic branches of brachial plexus**
  - d) phrenic nerves and intercostobrachial nerve
  - e) suprascapular nerves and coracobrachial nerve
12. What vessels and nerves pass through superficial subpectoral space?
- a) branches of thoracoacromial trunk**
  - b) supreme thoracic artery
  - c) lateral thoracic nerves and arteries
  - d) anterior thoracic nerves**
  - e) thoracodorsal artery and descending scapular artery
13. Where does cephalic vein flow?
- a) into axillary vein**
  - b) into brachial vein
  - c) into basilic vein
  - d) into internal jugular vein
  - e) into subclavicular vein**
14. What is the projection line of the axillary artery in the infraclavicular region?
- a) a line drawn from the border between the medial and middle third of the clavicle to the interior part of the coracobrachial muscle, in arm adduction
  - b) a line drawn from the lateral edge of the sternum to the greater tubercle of the humerus, in arm adduction
  - c) a line drawn from the sternal manubrium to the greater tubercle of the humerus, in arm adduction
  - d) a line drawn from the lateral edge of the sternum to the greater tubercle of humerus, in arm abduction.
  - e) a line drawn from the border between the medial and middle third of the clavicle to the internal margin of coracobrachial muscle, in arm abduction**
15. In the clavipectoral triangle, the vessels and nerves are placed in the following sequence:
- a) inferior - axillary vein, middle - brachial plexus and superior - axillary artery
  - b) inferior - axillary artery, middle - axillary vein and superior - brachial plexus
  - c) inferior - axillary vein , middle - axillary artery and superior - brachial plexus**
  - d) inferior - axillary artery, middle - brachial plexus and superior - axillary vein
  - e) inferior - brachial plexus, middle - brachial vein and superior - brachial artery
16. Which of the following arteries starts from axillary artery in the clavipectoral triangle?
- a) a. clavipectoralis
  - b) a. thoracoacromialis**
  - c) a. thoracica suprema**
  - d) ramus pectoralis
  - e) ramus deltoideus
17. Lymphatic drainage from the infraclavicular region occurs in:
- a) infraclavicular lymph nodes**
  - b) sternal lymph nodes
  - c) brachial lymph nodes
  - d) axillary lymph nodes**
  - e) prescapular lymph nodes

## SCAPULAR REGION

1. Deep fascia of scapular region forms the sheath for the following muscles:
  - a) supraspinatus muscle and seratus posterior superior muscle
  - b) infraspinatus muscle and rhomboid muscles
  - c) teres minor and teres major muscles
  - d) latissimus dorsi muscle**
  - e) trapezius muscle**
2. The superficial group of muscles from the scapular region are:
  - a) teres major and m. seratus posterior sup. muscles
  - b) teres minor and teres major muscles**
  - c) latissimus dorsi muscle**
  - d) supraspinatus and rhomboid muscles
  - e) trapezius muscles**
3. The osteofibrous scapular sheaths are filled with:
  - a) trapezius and seratus posterior sup. muscles
  - b) supraspinatus muscle**
  - c) latissimus dorsi and rhomboid muscles
  - d) infraspinatus muscle**
  - e) teres minor et major muscles**
4. Main arteries that form the scapular arterial anastomosis are:
  - a) **a. suprascapularis**
  - b) a. axilaris
  - c) a. toracoacromialis
  - d) a. circumflexa scapulae**
  - e) ramus descendens a. transversae colli**
5. The scapular region is innervated by the following nerves:
  - a) suprascapular n.**
  - b) infrascapular and axillary nerves
  - c) subscapular n.**
  - d) lateral thoracic and infraclavicular nerves
  - e) dorsal scapular n.**
6. What is the optimal segment for the axillary artery ligation?
  - a) more distal to the site of emergence of the subscapular artery
  - b) in the segment between subscapular artery and thyrocervical trunk**
  - c) more distally from the origin of anterior and posterior humeral circumflex arteries
  - d) in the segment between subscapular artery and supreme thoracic artery**
  - e) proximally to the site of emergence of the thyrocervical trunk
7. What is the critical segment for the axillary artery ligation?
  - a) proximal to the site of emergence of the thyrocervical trunk
  - b) in the segment between subscapular artery and supreme thoracic artery
  - c) in the segment between subscapular artery and thyrocervical trunk
  - d) in the segment between the subscapular artery and deep brachial artery**
  - e) in the segment between the lateral thoracic artery and supreme thoracic artery
8. What are the osteofascial lodges within the scapular region?
  - a) supraspinatus lodge (between the supraspinatus fossa and supraspinatus fascia)**
  - b) middle lodge (between fossa supraspinatus and infraspinatus fascia)
  - c) infraspinatus lodge (between the infraspinatus fossa and infraspinatus fascia)**
  - d) precapular space (anteriorly to scapula, between subscapular fossa and fascia covering the subscapularis muscle)**
  - e) subscapularis lodge (between infraspinatus fascia and supraspinatus fossa)
9. The pus from the space between trapezius muscle and supraspinatus muscle can be spread to:
  - a) axillary cavity
  - b) subdeltoid space
  - c) lateral triangle of the neck**

- d) in deep subpectoral space
  - e) superficial interpectoral space
10. The pus from prepectoral space can spread to:
- a) **axillary cavity**
  - b) subdeltoid space
  - c) lateral triangle of the neck
  - d) deep subpectoral space
  - e) superficial subpectoral space

## DELTOID REGION

1. Select the site where axillary nerve can be injured in the deltoid region:
  - a) at the level of acromial process
  - b) on the posterior margin of deltoid muscle**
  - c) on the anterior margin of deltoid muscle
  - d) at the inferior limit of deltoid muscle, 3 cm above the deltoid tuberosity
  - e) at the superior limit of deltoid muscle, 3 cm below the acromion
2. What vessels and nerves are situated in the subdeltoid space?
  - a) anterior circumflex humeral a.**
  - b) posterior circumflex humeral a.**
  - c) dorsal scapular n. and dorsal scapular artery
  - d) axillary n.**
  - e) subscapular a. and suprascapular n.
3. A patient with a wound on the posterior margin of deltoid muscle has difficulties to abduct the arm. What can be the cause?
  - a) injury of brachial plexus
  - b) injury of suprascapular and supraclavicular nerves
  - c) injury of axillary nerve**
  - d) injury of musculocutaneus and median nerves
  - e) injury of radial and ulnar nerve
4. In case of fracture of surgical neck of the humerus, the following elements can be injured:
  - a) long head of the brachial biceps muscle
  - b) circumflex posterior humeral artery**
  - c) axillary nerve**
  - d) radial and median nerves
  - e) circumflex anterior humeral artery**
5. What vessels supplies the deltoid muscle?
  - a) deltoid branch of thoracoacromial artery**
  - b) posterior circumflex artery of humerus**
  - c) anterior circumflex artery of humerus
  - d) scapular artery
  - e) circumflex artery of the scapula

! Trebuie revizuit
6. The pus from subdeltoid space can spread to:
  - a) axillary cavity, along the neurovascular bundle**
  - b) infraspinatus lodge
  - c) lateral triangle of the neck
  - d) deep subpectoral space
  - e) prescapular space

## AXILLARY REGION

- Which are the limits of axillary fossa:
  - inferior margin of pectoralis major muscle**
  - inferior margin of pectoralis minor muscle and teres major muscle
  - inferior margin of latissimus dorsi muscle**
  - conventional lines which connect pectoralis major muscle with latissimus dorsi muscle laterally and medially**
  - inferior margin of subscapular and coracobrachial muscles
- Posterior wall of the axillary cavity is made of:
  - subscapular muscle**
  - pectoralis major and pectoralis minor muscles
  - long and short heads of the brachial triceps muscle
  - latissimus dorsi muscle**
  - teres major and teres minor muscles**
- Select the anatomical structures that pass through the quadrilateral foramen of the posterior wall of the axillary cavity:
  - axillary artery and radial nerve
  - posterior circumflex humeral artery**
  - scapular circumflex artery and subscapular nerve
  - axillary nerve**
  - subscapular nerve and descendent scapular artery
- Select the anatomical structures that pass through the trilateral foramen of the posterior wall of the axillary cavity:
  - subscapular artery and radial nerve
  - subscapular nerve and descendent scapular artery
  - circumflex scapular artery**
  - circumflex posterior humeral artery and axillary nerve
  - thoracodorsal artery and descendent scapular artery
- Anterior wall of the axillary cavity is made of:
  - pectoralis minor muscle with clavipectoral fascia**
  - axillary fascia
  - deep subpectoral space and superficial intercostal muscles
  - pectoralis major muscle**
  - serratus anterior muscle and superficial intercostal muscles
- Lateral wall of the axillary cavity is made of:
  - brachioradialis and brachialis muscles
  - medial head of triceps brachii muscle
  - humerus**
  - proper fascia and short head of the triceps brachii muscle
  - coracobrachial muscle and short head of the biceps brachii muscle**
- Medial wall of the axillary cavity is made of:
  - clavipectoral fascia and suspensory ligament of axilla
  - thoracic wall**
  - pectoralis minor muscle and clavipectoral fascia
  - serratus anterior muscle**
  - pectoralis major muscle and suspensory ligament of axilla
- The projection line of the axillary artery is drawn between:
  - anterior and medial 1/3 of axillary fossa**
  - inferior margin of pectoralis major muscle
  - posterior and medial 1/3 of axillary fossa
  - half distance between pectoralis major muscle and latissimus dorsi muscle
  - coracoid process and medial epicondyle of the humerus
- Select the boundaries of the quadrilateral foramen:

- a) **teres major muscle**
  - b) coracobrachialis and infraspinatus muscles
  - c) **teres minor and subscapularis muscles**
  - d) **humerus**
  - e) **long head of the triceps brachii muscle**
10. Select the boundaries of the trilateral foramen:
- a) **teres major muscle**
  - b) coracobrachialis and infraspinatus muscles
  - c) **teres minor and subscapularis muscles**
  - d) humerus and coracoid process
  - e) **long head of the triceps brachii muscle**
11. Apex of the axillary cavity is situated between:
- a) elements of the shoulder joint
  - b) **the middle of the 1'st rib**
  - c) **the middle of the clavicle**
  - d) middle of the lateral third of the clavicle
  - e) imaginary line drawn from the apex of the axillary cavity to the supraclavicular fossa
12. Select the correct answers regarding the syntopy of anatomical structures towards the axillary artery:
- a) medially - cephalic vein and musculocutaneous nerve
  - b) **laterally - brachial plexus**
  - c) medially - the medial cord of the brachial plexus
  - d) laterally - the lateral cord of the brachial plexus
  - e) **medially - axillary vein**
13. Select the branches of the axillary artery in the pectoral triangle:
- a) superior thoracic artery
  - b) thoracoacromial artery and lateral thoracic artery
  - c) lateral thoracic artery, circumflex posterior humeral artery and circumflex scapular artery
  - d) **lateral thoracic artery**
  - e) all answers are false
- ! Trebuie revizuit
14. Select the branches of the axillary artery in the subpectoral triangle:
- a) thoracoacromial and lateral thoracic arteries
  - b) **circumflex posterior humeral artery**
  - c) circumflex scapular and suprascapular arteries
  - d) **subscapular artery**
  - e) **circumflex anterior humeral artery**
15. Collateral blood circulation will be more efficient if the ligature of the axillary artery is performed:
- a) proximally to the lateral thoracic artery and distally to posterior circumflex humeral artery
  - b) distally to the posterior circumflex humeral artery
  - c) **proximally to the subscapular artery**
  - d) distally to the subscapular artery and proximally to posterior circumflex humeral artery
  - e) proximally to the thoracoacromial artery and distally to posterior circumflex humeral artery
16. In the subpectoral triangle the axillary artery is surrounded by:
- a) **median nerve**
  - b) **musculocutaneous nerve**
  - c) **ulnar nerve, medial cutaneous nerve of arm and forearm**
  - d) **radial nerve, axillary nerve**
  - e) suprascapular and subscapular nerves
17. Select the spaces where the pus can directly spread from the axillary cavity:
- a) **to the subdeltoid space**
  - b) **to superficial subpectoral space**
  - c) **to antescalen and interscalen spaces**
  - d) **to infraspinatus lodge and prescapular spaces**
  - e) to suprascapular lodge



18. Axillary cavity is filled with:
- 5 groups of lymph nodes**
  - adipose tissue**
  - axillary neurovascular bundle**
  - branches of the axillary artery**
  - suprascapular artery and suprascapular nerve
19. Which of the following statements regarding the axillary lymph nodes are correct:
- all groups of axillary lymph nodes drain into subclavian lymphatic trunk**
  - medial group collects the lymph from the mammary gland and anterolateral wall of the abdomen and thorax, superior to umbilicus**
  - the lymph node which is situated near the 3<sup>rd</sup> rib and it is first affected in case of mammary gland cancer is called lymph node of Zorghiuss**
  - posterior group of lymph nodes, which are situated along the subscapular artery, collects the lymph from the superior part of the back and posterior region of the neck**
  - all groups of axillary lymph nodes drain into the jugular lymphatic trunk
20. Select the possible way of pus spreading from axillary cavity to the superficial subpectoral space:
- along the axillary nerve and posterior humeral circumflex artery
  - along the subscapular artery and descendent branch of transverse cervical artery
  - along the lateral thoracic artery and anterior circumflex humeral artery
  - along the thoracodorsal artery
  - along the toracoacromial artery**
21. Select the possible way of pus spreading from the axillary cavity to antescalen and interscalen spaces:
- along the circumflex scapular artery and axillary nerve
  - along the lateral thoracic artery and supreme thoracic artery
  - along the cephalic vein and lateral cutaneous nerve of the arm
  - along the axillary neurovascular bundle, in proximal direction**
  - along the thoracoacromial artery and pectoral muscular branches
22. Select the possible way of pus spreading from the axillary cavity to subdeltoid space:
- along the radial nerve and subscapular artery
  - along the axillary nerve and anterior and posterior circumflex humeral arteries**
  - along the ulnar nerve and musculocutaneous nerve
  - along the median nerve and radial nerve
  - along the circumflex scapular artery
23. What are the boundaries of the subpectoral triangle?
- the lines drawn on the inferior margin of the pectoralis minor and inferior margin of the pectoralis major muscles**
  - the lines drawn on the superior and inferior margins of the pectoralis minor muscle
  - the line drawn on the inferior margin of the pectoralis major muscle
  - the line drawn on the inferior margin of the clavicle and the inferior margin of the pectoralis minor muscle
  - the line drawn on the inferior margin of the pectoralis major muscle and the 12<sup>th</sup> rib
24. What are the boundaries of pectoral triangle?
- corresponds to the inferior margin of the pectoralis minor muscle and inferior margin of the pectoralis major muscle
  - corresponds to the boundaries of the pectoralis minor muscle**
  - corresponds to the limits of pectoralis major muscle
  - corresponds to the inferior margin of the clavicle and the inferior margin of the pectoralis minor muscle
  - corresponds to the inferior margin of the pectoralis major muscle and the 12<sup>th</sup> rib
25. The axillary cavity communicates posteriorly with:
- the prescapular space**
  - the subdeltoid space through the quadrilateral foramen, along the axillary nerve and posterior circumflex humeral artery**
  - the infraspinatus osteofibrous lodge through the trilateral foramen**
  - the infraclavicular space along the cephalic vein
  - the brachial space along the axillary nerve

26. Which statements regarding the axillary artery are correct?
- a) **the axillary artery is a continuation of subclavian artery**
  - b) **the first part of the axillary artery is projected in the clavipectoral triangle**
  - c) **the second part of the axillary artery is projected in the pectoral triangle**
  - d) **the third part of the axillary artery is found within subpectoral triangle**
  - e) the fourth part of the axillary artery passes through quadrilateral foramen
27. The medial group of axillary lymph nodes collect the lymph from:
- a) **the mammary gland**
  - b) **the anterolateral thoracic wall**
  - c) the upper limb
  - d) the neck region
  - e) **the anterolateral abdominal wall**
28. The lymph from the axillary lymph nodes is drained into:
- a) abdominal lymph nodes
  - b) the brachial lymph nodes
  - c) **the subclavicular lymph nodes**
  - d) mediastinal lymph nodes
  - e) no correct answer
29. Which of the following statements are correct?
- a) **axillary fossa is separated from axillary cavity by axillary fascia**
  - b) **serratus anterior muscle forms the medial wall of the axillary cavity**
  - c) latissimus dorsi, teres major and subscapularis muscles form the lateral wall of the axillary cavity
  - d) **quadrilateral foramen is located on the posterior wall of axillary cavity**
  - e) **trilateral foramen is located on the posterior wall of axillary cavity**
30. Which of the following statements are FALSE?
- a) pectoral and subpectoral triangles are situated on the anterior wall of the axillary cavity
  - b) ulnar nerve passes on medial wall of the axillary cavity
  - c) axillary vein lies medially to the axillary artery
  - d) **axillary vein lies anteriorly and laterally to the axillary artery**
  - e) **circumflex scapular artery passes through quadrilateral foramen**

## SHOULDER JOINT

1. Which side of the shoulder joint is not strengthened by muscles:
  - a) anterior
  - b) posterior
  - c) external
  - d) medial**
  - e) it is strengthened by muscles all around
2. Which nerve can be injured if the shoulder is dislocated in anterior-inferior direction:
  - a) median and musculocutaneous nerves
  - b) radial nerve and medial cutaneous forearm nerve
  - c) ulnar and intercostobrachial nerves
  - d) axillary nerve**
  - e) all nerves can be injured
3. The dislocation of humerus in shoulder joint occurs more often in cases of absence or underdevelopment of which ligament?
  - a) coracohumeral
  - b) coracoacromial
  - c) tendon of the long head of biceps brachii muscle
  - d) median glenohumeral ligament**
  - e) superior glenohumeral ligament
4. Articular surface between the head of humerus and articular fossa of the scapula is increased because of:
  - a) superior glenohumeral ligament
  - b) inferior glenohumeral ligament
  - c) glenoid labrum**
  - d) lateral epicondyle
  - e) medial epicondyle
5. Shoulders joint cavity is increased because of:
  - a) anteriorly by subscapular bursa**
  - b) prolapsing of synovial sheath of biceps muscle**
  - c) glenoid labrum
  - d) lateral epicondyle
  - e) medial epicondyle
6. The capsule of shoulder joint is strengthened by:
  - a) superior glenohumeral ligament**
  - b) median glenohumeral ligament**
  - c) inferior glenohumeral ligament**
  - d) anteriorly by subscapular bursa
  - e) prolapsing of synovial sheath of biceps muscle

## BRACHIAL REGION

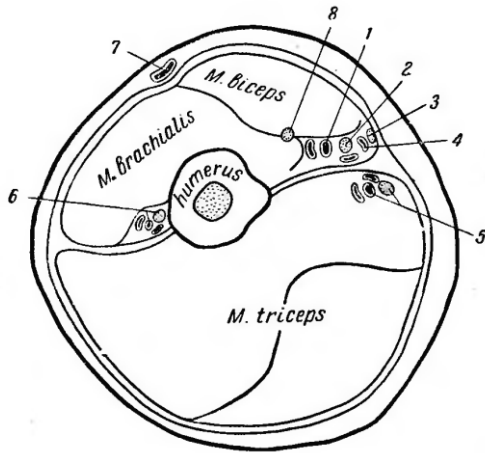
- The projection line of the brachial artery and median nerve is drawn between:
  - anterior and median 1/3 of the axillary fossa**
  - posterior and median 1/3 of the axillary fossa
  - middle of cubital fold**
  - medial humeral epicondyle
  - lateral humeral epicondyle
- The projection line of the ulnar nerve in the inferior 1/3 of the arm connects the following points:
  - the limit between median and inferior 1/3 of the medial bicipital groove**
  - medial epicondyle of the humerus**
  - humeral lateral epicondyle of the humerus
  - middle of cubital fold
  - medial margin of olecranon
- The projection of the radial nerve in the anterior region of the arm corresponds with:
  - the inferior 1/3 of the lateral bicipital groove**
  - the inferior 1/3 of the medial bicipital groove
  - the median 1/3 of the lateral bicipital groove
  - the projection of the ulnar nerve
  - has no projection on the anterior region of the arm
- Select the anatomical structures situated in the subcutaneous fatty tissue of the anterior region of the arm:
  - cephalic vein**
  - basilic vein**
  - median nerve and lateral cutaneous nerve of arm
  - medial cutaneous nerves of the arm and forearm**
  - radial nerve and lateral cutaneous nerve of the forearm
- Which anatomical structures are situated in the proximal third of the anterior fascial lodge of the arm?
  - triceps brachii muscle and radial nerve
  - coracobrachialis, biceps brachii and brachialis muscles**
  - brachialis artery and vein, median nerve and musculocutaneous nerve**
  - ulnar nerve**
  - teres minor and teres major muscles
- Which anatomical structures are situated in the distal third of the anterior fascial lodge of the arm?
  - coracobrachialis muscle, radial nerve, basilic vein
  - long head of biceps brachii muscle, cutaneous brachii lateralis nerve
  - biceps brachii muscle, brachialis muscle, brachial artery and vein, inferior collateral ulnar artery**
  - median nerve**
  - medial cutaneous nerves of the arm and forearm
- Select the contents of the main brachial neurovascular bundle in the inferior third of the arm:
  - ulnar nerve, median nerve, brachial vein, brachial artery
  - median nerve, brachial vein, brachial artery**
  - brachial vein, radial nerve, brachial artery
  - ulnar nerve, musculocutaneous nerve, brachial vein.
  - brachial artery, medial cutaneous nerve of the forearm, vena basilica
- Ulnar nerve in the superior 1/3 of the arm is situated:
  - medially and posteriorly to the median nerve**
  - laterally to brachial artery
  - medially to the brachial artery**
  - laterally to the basilic vein**
  - medially to the basilic vein
- Ulnar nerve in the inferior 1/3 of the arm is situated:
  - anteriorly and medially to brachial artery
  - between the medial epicondyle of humerus and olecranon

- c) **in the fascial sheath of the triceps brachii muscle**
  - d) between brachialis muscle and biceps brachii muscle
  - e) in the fascial sheath of the biceps brachii muscle
10. Critical area for ligation of the main arterial trunk of the upper limb is situated between:
- a) **deep brachial artery**
  - b) anterior circumflex humeral artery
  - c) scapular circumflex artery
  - d) posterior circumflex humeral artery
  - e) **subscapular artery**
11. In the median 1/3 of the arm, the musculocutaneous nerve is situated between:
- a) coracobrachialis muscle and medial head of triceps brachii muscle
  - b) **brachialis muscle**
  - c) brachioradialis and pronator teres muscles
  - d) medial head of triceps brachii muscle
  - e) **biceps brachii muscle**
12. Identify the anatomical structures situated in the posterior fascial lodge of the median 1/3 of the arm:
- a) **triceps brachii muscle**
  - b) **radial nerve**
  - c) **deep brachial artery**
  - d) musculocutaneous nerve and medial collateral ulnar artery
  - e) superior collateral ulnar artery and musculocutaneous nerve
13. The projection line of the radial nerve on the arm is the line that connects:
- a) **posterior margin of the deltoid muscle**
  - b) **inferior 1/3 of the lateral bicipital groove**
  - c) greater tubercle of the humerus bone
  - d) lateral epicondyle of the humerus
  - e) inferior 1/3 of the medial bicipital groove
14. Through the humeromuscular canal passes:
- a) axillary nerve and lateral ulnar collateral artery
  - b) posterior circumflex humeral artery
  - c) musculocutaneous nerve and medial ulnar collateral artery
  - d) **radial nerve**
  - e) **deep brachial artery and vein**
15. Select the anatomical structures that are situated in the groove formed by the medial epicondyle of the humerus and the olecranon:
- a) **ulnar n.**
  - b) **superior ulnar collateral a.**
  - c) inferior ulnar collateral a
  - d) anterior ulnar recurrent a.
  - e) deep brachial a.
16. The humeromuscular canal is situated:
- a) **in the posterior fascial lodge of the arm**
  - b) in the anterior fascial lodge of the arm
  - c) **between the humerus and the triceps brachii m.**
  - d) between the humerus and the biceps brachii m.
  - e) this canal is situated in another region
17. Terminal branches of the deep brachial a. are:
- a) **radial collateral artery**
  - b) **median collateral artery**
  - c) superior collateral ulnar artery
  - d) inferior collateral ulnar artery
  - e) none of the answers are true
18. Determine which of the statements are true:
- a) **radial nerve can be injured in cases of fracture of the humerus in the middle 1/3**
  - b) **radial nerve passes through the humeromuscular canal**

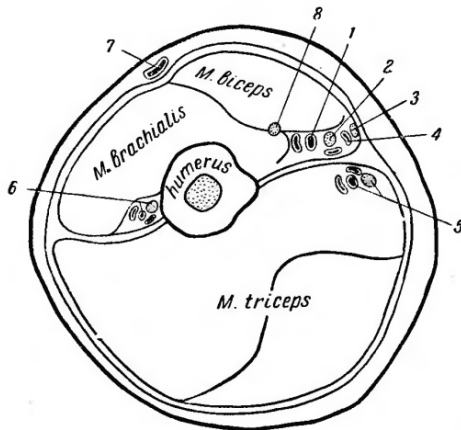
- c) ligation of the brachial artery is better to be performed proximally to the emergence of deep brachial artery
  - d) in the inferior 1/3 of the brachial region the ulnar nerve is situated in the posterior fascial lodge**
  - e) radial nerve gives branches in the middle 1/3 of the forearm
19. In case of fracture of the humerus proximally to the insertion of the deltoid muscle, the bone fragments displace:
- a) proximal fragment is rotated externally under the action of infraspinatus and teres minor muscles
  - b) proximal fragment is displaced laterally and anteriorly under the action of supraspinatus and deltoid muscles
  - c) proximal fragment is displaced medially under the action of teres major and pectoralis major muscles**
  - d) distal fragment is displaced laterally and superiorly under the action of deltoid muscles**
  - e) distal fragment is displaced posteriorly under the action of biceps brachii muscle
20. Select the correct statements regarding the basilic vein in the distal third of the arm:
- a) it is located more superficially to the deep fascia**
  - b) it is accompanied by medial cutaneous nerve of forearm**
  - c) it is located under superficial fascia
  - d) it is located between the laminae of the superficial fascia (canal of Pirogov)
  - e) it is situated along the medial bicipital groove**
21. Cephalic vein is located in the following layer of the arm:
- a) between laminae of the deep fascia
  - b) under the deep fascia
  - c) between the superficial and deep fascia**
  - d) in the middle third of the arm it is situated in Pirogov's canal
  - e) in the proximal third of the arm it is situated under the deep fascia
22. Basilic vein in the middle third of the arm is situated:
- a) under deep fascia
  - b) under superficial fascia
  - c) in the duplication of deep fascia (Pirogov's canal)**
  - d) in the subcutaneous adipose tissue
  - e) between the superficial fascia and deep fascia
23. Which of the following statements about brachial neurovascular bundle syntopy are FALSE:
- a) the median nerve in the proximal third of the arm is placed more laterally than brachial artery
  - b) the median nerve in the proximal third of the arm is placed more posteriorly than brachial artery**
  - c) median nerve intersects anteriorly the brachial artery in the middle third
  - d) median nerve intersects posteriorly the brachial artery in the middle third**
  - e) median nerve in the distal third of the arm is placed more medially than the brachial artery
24. At the border with cubital region radial nerve is located between the following structures:
- a) biceps brachii muscle
  - b) brahioradialis muscle**
  - c) triceps brachii muscle
  - d) pronator teres muscle
  - e) brachialis muscle**
25. Which of the following statements about the topography of the ulnar nerve on the arm are correct:
- a) ulnar nerve at the border between proximal and middle third of the arm leaves the anterior lodge of the arm by penetrating the medial intermuscular septum**
  - b) in the middle third of the arm it is located in anterior lodge
  - c) in the middle third of the arm it is located in the posterior lodge of the arm, parallel to the medial intermuscular septum**
  - d) in the middle and lower third of the arm it is accompanied by the superior ulnar collateral artery**
  - e) in the distal third of the arm it is located in the lodge of the triceps brachii muscle**
26. Which of the following statements about the topography of musculocutaneous nerve on the arm are correct:
- a) in the proximal third of the arm it penetrates the coracobrachialis muscle**
  - b) in the proximal third of the arm it penetrates the biceps brachii muscle
  - c) in the middle third of the arm it is located between brachialis muscle and biceps brachii muscle**

- d) **in the lower third of the arm, at the border with cubital region, it penetrates the brachial fascia and becomes a cutaneous nerve**
- e) in the lower third of the arm it is located between triceps brachii muscle and brachioradialis muscle
27. Which subcutaneous vein accompanies medial cutaneous nerve on the arm?
- axillary vein
  - cephalic vein
  - basilic vein**
  - brachial vein
  - cubital vein
28. The pulsation of brachial artery can be determined:
- at the middle of medial bicipital groove**
  - at the medial edge of the deltoid muscle
  - at the lateral edge of the biceps muscle
  - at the point of attachment of the deltoid muscle to the arm
  - artery pulsation can not be appreciated on the arm
29. Which is the optimal segment for ligation of brachial artery in the upper part of the arm?
- distally to the origin of the deep brachial artery**
  - proximally to the origin of the deep brachial artery
  - distally or proximally to the origin of the deep brachial artery
  - no answer is correct
  - the ligation of deep brachial artery only
30. Skin of posterior region of the arm is innervated by posterior cutaneous nerve of the arm, which is derived from:
- radial nerve**
  - ulnar nerve
  - axillary nerve
  - musculocutaneous nerve
  - the median nerve
31. At what level of the brachial region, the basilic vein is located in the subcutaneous tissue?
- in lower third**
  - in medium third
  - in upper third
  - basilic vein do not pass in the subcutaneous tissue of the brachial region
  - is placed in its fascial canal immediately from cubital region
32. Compression of which nerve causes paresthesia after application of tourniquet in the middle third of the arm?
- median nerve
  - musculocutaneous nerve
  - ulnar nerve
  - radial nerve**
  - axillary nerve
33. Projection line of deep brachial neurovascular bundle corresponds with:
- a line which connects the middle of the inferior border of deltoid muscle with lateral epicondyle of the humerus
  - corresponds to the lateral intermuscular septum
  - the direction of humeromuscular canal makes it impossible to determine the projection line
  - a line which connects the middle of the posterior border of deltoid muscle with the middle of the cubital fold**
  - none of these answers are correct
34. Name all the structures at the level of median third of the arm, as follows in order from 1 to 8:
- brachial artery, median n., medial cutaneous nerve of the forearm, basilic vein, ulnar n. and superior collateral ulnar a., radial n. and deep brachial artery, cephalic vein, musculocutaneous n.**
  - musculocutaneous n., brachial artery, median n., medial cutaneous n. of the forearm, basilic vein, ulnar n. and superior collateral ulnar a., radial n. and deep brachial artery, cephalic vein

- c. ulnar n. and superior collateral ulnar a., median n., medial cutaneous n. of the forearm, basilic vein, radial n. and deep brachial artery, cephalic vein, brachial artery, musculocutaneous n..
- d. brachial artery, median n., cephalic vein, basilic vein, medial cutaneous n. of the forearm, ulnar n. and superior collateral ulnar a., radial n. and deep brachial artery, musculocutaneous n..
- e. median n., medial cutaneous n. of the forearm, ulnar n. and superior collateral ulnar a., radial n. and deep brachial artery, brachial artery, cephalic vein, musculocutaneous n.

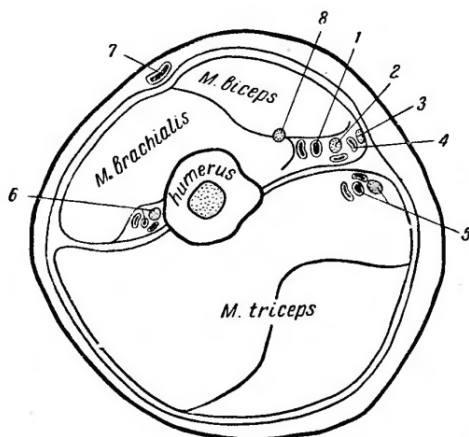


35. Name the anatomical structures indicated with number 6 in the picture that represents the cross section of the middle 1/3 of the arm:



- a. musculocutaneous nerve
- b. cephalic vein
- c. ulnar nerve and superior ulnar collateral artery
- d. median nerve
- e. radial nerve and deep brachial artery**

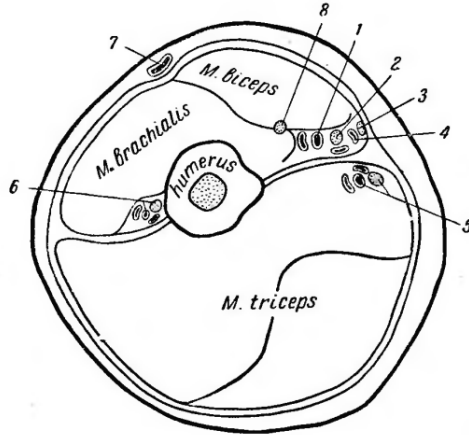
36. Name the anatomical structure indicated with number 8 in the picture that represents the cross section of the middle 1/3 of the arm:





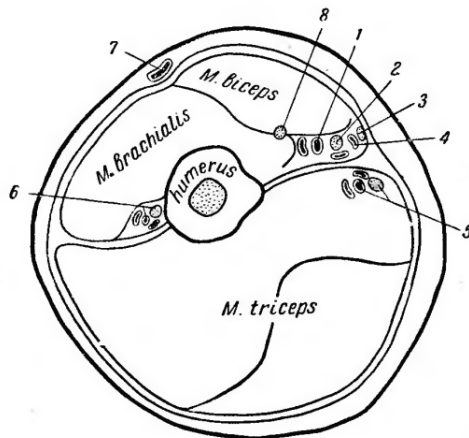
- a. **musculocutaneous nerve**
- b. cephalic vein
- c. ulnar nerve and superior ulnar collateral artery
- d. median nerve
- e. radial nerve and deep brachial artery

37. Name the anatomical structure indicated with number 7 in the picture that represents the cross section of the middle 1/3 of the arm:



- a. musculocutaneous nerve
- b. cephalic vein**
- c. ulnar nerve and superior ulnar collateral artery
- d. median nerve
- e. radial nerve and deep brachial artery

38. Name the anatomical structures indicated with numbers 5 and 8 in the picture that represents the cross section of the middle 1/3 of the arm:



- a. **musculocutaneous nerve**
- b. cephalic vein
- c. ulnar nerve and superior ulnar collateral artery**
- d. median nerve
- e. radial nerve and deep brachial artery

## CUBITAL REGION

- In the subcutaneous fatty tissue of the anterior cubital region are situated:
  - basilic and cephalic veins**
  - medial and lateral cutaneous nerves of forearm**
  - intermediate cubital vein, in case of H-shaped anastomosis**
  - median cephalic and median basilica veins in case of M-shaped anastomosis**
  - anterior cutaneous nerve of forearm
- In the cubital fossa, the brachial artery is located:
  - medially to the tendon of the biceps brachii muscle**
  - laterally to the tendon of the biceps brachii muscle
  - it is accompanied by the median nerve**
  - it is accompanied by the musculocutaneous nerve
  - superficially to the proper fascia
- What muscles are situated in the lateral fascial lodge of the cubital fossa:
  - brachioradialis m.**
  - biceps brachii m.
  - brachialis m.
  - supinator m.**
  - pronator teres m.
- What muscles are situated in the medial fascial lodge of the cubital fossa:
  - pronator teres m.**
  - palmaris longus m.**
  - flexor digitorum mm.**
  - supinator and pronator quadratus muscles
  - all answers are true
- In the cubital fossa, the radial nerve is placed:
  - in the lateral intermuscular groove, between the brachioradialis and brachialis muscles**
  - in the lateral intermuscular septum, between the brachial and biceps brachii muscles
  - in the medial intermuscular septum
  - it adheres to the capsule of the elbow joint and it is located under palmaris longus muscle**
  - in the thickness of the pronator teres muscle
- Which of the following statements are true?
  - in the cubital fossa, the superficial branch of the radial n. is situated between the brachioradialis and supinator muscles**
  - the deep branch of radial nerve enters the supinator canal**
  - the radial nerve has only one branch on the forearm
  - the superficial branch of the radial nerve is accompanied by the radial artery**
  - the deep branch of the radial nerve is accompanied by the radial artery
- Which of the following statements is correct regarding the topography of radial artery in the cubital fossa?
  - it is situated under the pronator teres m.**
  - it is situated under the palmaris longus m.
  - it is accompanied by the median n.
  - it is accompanied by the superficial branch of the radial n.
  - it is accompanied by the ulnar n
- Which of the following statements is correct regarding the topography of ulnar artery in the cubital fossa?
  - it is situated between the superficial and deep flexor digitorum muscles**
  - it is accompanied by the deep branch of the radial nerve
  - recurrent ulnar artery starts from the ulnar artery**
  - it is situated on the pronator teres m.
  - it is situated under the pronator teres m.
- The arterial network around the elbow joint is formed by the anastomosis between:
  - posterior circumflex humeral a. and recurrent interosseous a.
  - superior ulnar collateral a. and deep brachial a.
  - superior ulnar collateral a. and posterior ulnar recurrent a.**

- d) **radial collateral a. and radial recurrent a.**
  - e) **inferior ulnar collateral a. and anterior ulnar recurrent a.**
10. The osteofibrous canal, through which the ulnar nerve passes in the cubital region, is formed by:
- a) **medial epicondyle of humerus**
  - b) lateral epicondyle of humerus
  - c) **olecranon**
  - d) **proper fascia and superficial tissues**
  - e) the head of radius
11. Select the anatomical structures that pass through the canal of the ulnar nerve in the cubital region:
- a) **ulnar n.**
  - b) radial n.
  - c) median n.
  - d) **superior ulnar collateral artery**
  - e) inferior ulnar collateral artery
12. Vena basilica in the cubital region is placed:
- a) in the subcutaneous tissue
  - b) between muscles
  - c) under deep fascia
  - d) between the superficial fascia and the proper fascia
  - e) **in the duplicature of the superficial fascia**
13. Which of the subcutaneous veins of the cubital region is more convenient for venipuncture?
- a) cephalic vein
  - b) basilic vein
  - c) radial vein
  - d) ulnar vein
  - e) **anastomosis between the cephalic and basilic vein**
14. During measuring of blood pressure, the phonendoscope should be placed in the cubital fossa:
- a) on the lateral margin of the tendon of biceps brachii muscle
  - b) **on the medial margin of the tendon of biceps brachii muscle**
  - c) on the tendon of biceps brachii muscle
  - d) on the medial margin of the lateral epicondyle
  - e) none of the above mentioned are correct
15. How is the median nerve placed towards the brachial artery in the cubital fossa?
- a) posteriorly to brachial artery
  - b) **medially to brachial artery**
  - c) superiorly to brachial artery
  - d) laterally to brachial artery
  - e) these two anatomical structures go separately
16. Projection line of elbow joint corresponds to the:
- a) 1.5 cm above the cubital fold
  - b) at the medial edge of the tendon of biceps brachii muscle
  - c) **1.5 cm under the cubital fold**
  - d) corresponds to the line which joins epicondyles with olecranon
  - e) none of these statements are correct
17. Which ligaments strengthen the elbow joint?
- a) **radial collateral ligament**
  - b) oblique ligament
  - c) **annular ligament**
  - d) brachial collateral ligament
  - e) **ulnar collateral ligament**
18. Which of the following statements regarding the elbow joint are correct?
- a) **brachial muscle is situated anteriorly**
  - b) **tendon of triceps brachii muscle is situated posteriorly**
  - c) biceps brachii muscle is situated anteriorly

- d) supinator and anconeus muscles are situated latero-inferiorly**
- e) medially it is not strengthened by muscles**

## FOREARM REGION

- Projection of the ulnar neurovascular bundle on the forearm is the line that connects:
  - tendon of the biceps brachii m.
  - styloid process of the ulna
  - medial epicondyle of the humerus**
  - lateral edge of pisiform bone**
  - olecranon
- Projection of the radial neurovascular bundle on the forearm is the line that connects:
  - lateral margin of the tendon of brachial biceps m.
  - middle of the cubital fossa**
  - styloid process of the radius**
  - lateral epicondyl of the humerus
  - medial margin of the scaphoid bone
- The projection line of the median nerve on the forearm connects:
  - the middle distance between the lateral epicondyle and m. biceps brachii tendon.
  - middle of the cubital fossa**
  - middle point between the styloid processes of radius and ulna**
  - medial epicondyle of the humerus
  - middle point between the tendon of the flexor carpi radialis m. and brachioradialis m.
- Select the anatomical structures situated in the subcutaneous fatty tissue of the anterior region of the forearm:
  - cephalic and basilic vv.**
  - medial and lateral cutaneous nerves of the forearm**
  - ulnar and radial aa.
  - median n. and ulnar recurrent artery
  - median a. and deep branch of radial nerve
- Determine which of the statements are true:
  - two septa start from the proper fascia in the forearm region**
  - the Paron-Pirogov space communicates with the posterior deep space on the forearm**
  - the 4<sup>th</sup> layer of muscles is represented by pronator quadratus m.**
  - main neurovascular bundles of the forearm is situated in the subcutaneous layer
  - the Paron-Pirogov space is situated between the 3<sup>rd</sup> and 4<sup>th</sup> layers of flexor muscles**
- Between which muscles the radial artery is situated in the median 1/3 of the forearm:
  - brachioradialis m.**
  - pronator teres m.
  - flexor carpi radialis m.**
  - flexor digitorum superficialis m.
  - supinator m.
- The median nerve in the medial 1/3 of the forearm is situated between:
  - flexor digitorum superficialis m.**
  - flexor digitorum profundus m.**
  - palmaris longus m.
  - flexor carpi ulnaris m.
  - flexor carpi radialis m.
- The adipose space of Paron-Pirogov on the forearm is delimited by:
  - flexor digitorum profundus m.**
  - flexor pollicis longus m.**
  - flexor digitorum superficialis m.
  - interosseous membrane**
  - pronator quadratus**
- The lateral neurovascular bundle of the forearm is formed by:
  - radial artery and vein**
  - radial n.
  - median n.

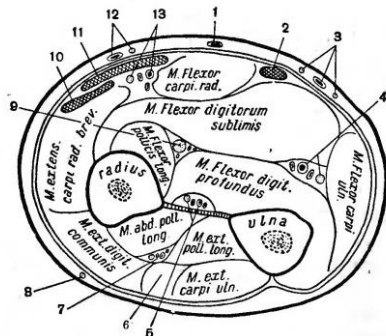
- d) **superficial branch of radial n.**  
e) deep branch of radial n.
10. The medial neurovascular bundle of the forearm is formed by:  
a) radial a.  
b) **ulnar artery and vein**  
c) radial n.  
d) median n.  
e) **ulnar n.**
11. The median nerve is accompanied on the forearm by:  
a) anterior interosseous artery  
b) **median artery as a branch of anterior interosseous artery**  
c) ulnar a.  
d) radial a.  
e) none of the answers is correct
12. In the median 1/3 of the forearm the median nerve is situated:  
a) under the proper fascia  
b) between flexor carpi radialis and palmaris longus mm.  
c) between brachioradialis and flexor carpi radialis m.  
d) between flexor digitorum superficialis m. and flexor carpi ulnaris m.  
e) **between flexor digitorum superficialis and flexor digitorum profundus muscles**
13. The radial groove in the median and inferior 1/3 of the forearm is limited by:  
a) **brachioradialis m.**  
b) pronator quadratus m.  
c) pronator teres m.  
d) palmaris longus m.  
e) **flexor carpi radialis m.**
14. The ulnar groove of the forearm is limited by:  
a) **flexor carpi ulnaris m.**  
b) pronator teres m.  
c) brachioradial m.  
d) palmaris longus m  
e) **flexor digitorum superficialis m.**
15. What passes through the supinator canal?  
a) radial nerve  
b) deep branch of the radial nerve together with the radial collateral artery  
c) **deep branch of the radial nerve**  
d) posterior branch of interosseous nerve of the forearm  
e) radial artery
16. The supinator canal has the following boundaries:  
a) annular radial ligament  
b) **supinator m.**  
c) brachioradial m.  
d) middle diaphysis of the radial bone  
e) **neck of the radius**
17. What is the manifestation of the supinatory canal syndrome:  
a) diminished skin sensibility of the anterior-lateral region of the forearm  
b) diminished skin sensibility of the posterior region of the forearm  
c) **diminished force of extension of the hand and fingers**  
d) inability to flex the hand and fingers  
e) ischemia of the tissues of the posterior region of the forearm
18. Neurovascular bundle of the posterior region of the forearm is formed by:  
a) posterior nerve of the forearm

- b) **the terminal branch of the deep branch of the radial nerve**
  - c) **posterior interosseous artery and two interosseous veins**
  - d) radial artery
  - e) posterior artery of the forearm
19. The adipose layer from the posterior region of the forearm communicates with the Pirogov space:
- a) **along the perivascular tissue of the interosseous arteries**
  - b) through the supinator canal
  - c) **through the openings into the interosseous membrane**
  - d) through the ulnar groove
  - e) through the radial groove
20. Select the correct statement regarding the deep fatty tissue space in the posterior region of the forearm:
- a) **it is situated between the superficial and the deep layers of muscles**
  - b) it is situated between the deep layer of muscles and the interosseous membrane
  - c) it is situated above the superficial layer of muscles
  - d) **is a relatively closed space and can communicate only with the deep anterior space of the forearm**
  - e) in this region the fatty tissue space does not exist
21. The median groove in the distal 1/3 of forearm is situated between:
- a) **tendon of flexor carpi radialis m.**
  - b) flexor carpi ulnaris m.
  - c) **tendon of palmaris longus m.**
  - d) flexor digitorum superficialis m.
  - e) pronator teres m.
22. The anterior interosseous neurovascular bundle from the forearm region represents branches of:
- a) **median n.**
  - b) ulnar n.
  - c) **ulnar a. and v.**
  - d) radial a. and v.
  - e) radial n.
23. The third layer of muscles from the anterior region of the forearm consists of:
- a) **flexor pollicis longus m.**
  - b) **flexor digitorum profundus m.**
  - c) flexor digitorum superficialis m.
  - d) pronator teres m.
  - e) pronator quadratus m.
24. Which of the following statements about the topography of median nerve in the proximal third of the forearm are correct?
- a) it passes under the pronator teres muscle
  - b) it passes under the supinator muscle
  - c) **it passes between the heads of pronator teres muscle**
  - d) it passes under the flexor digitorum superficialis muscle
  - e) it passes between flexor digitorum superficialis and profundus muscles
25. Which of the following statements regarding the topography of ulnar nerve in the proximal third of the forearm are correct?
- a) **at the border with the middle third of the forearm it is placed in ulnar canal of the forearm**
  - b) **it passes under the flexor carpi ulnaris muscle**
  - c) **it may pass between the heads of the flexor carpi ulnaris muscle**
  - d) it passes between flexor carpi ulnaris muscle and pronator teres muscle
  - e) it passes under pronator teres muscle
26. Which of the following statements regarding the topography of ulnar artery in the proximal third of the forearm are correct:
- a) **immediately after the bifurcation it is placed under pronator teres muscle**
  - b) immediately after the bifurcation it is placed under flexor carpi ulnaris muscle
  - c) **it passes under the flexor digitorum superficialis muscle**
  - d) it passes under the flexor digitorum profundus muscle
  - e) it passes between flexor digitorum superficialis and flexor digitorum profundus muscles

27. Which of the following statements about the topography of the radial neurovascular bundle in the forearm region are correct?
- in the proximal third of the forearm it is located between pronator teres muscle and brahioradialis muscle**
  - in the middle and distal third it is located between flexor carpi radialis m. and brahioradialis m.**
  - superficial branch of the radial nerve is more placed laterally to radial artery**
  - the superficial branch of the radial n. is disposed more medial than artery
  - radial nerve is placed deeper than artery
28. Ulnar neurovascular bundle within the forearm has the following topography:
- the proper ulnar neurovascular bundle is present in all three thirds of the forearm
  - the proper ulnar neurovascular bundle is present only in the middle and distal thirds of the forearm**
  - ulnar nerve is placed laterally to ulnar artery
  - ulnar nerve is placed medially to ulnar artery**
  - the ulnar nerve in the proximal third of the forearm passes between the heads of the flexor carpi ulnaris muscle**
29. Between tendons of which muscles the median nerve is situated in the lower third of the forearm?
- the pronator teres m.
  - flexor carpi radialis m**
  - palmaris longus m**
  - flexor carpi ulnaris m
  - flexor digitorum superficialis
30. The patient B. has a cutting wound in the lower third of the anterior region of forearm. The examination reveals impossibility of flexion of the fingers 1, 2 and 3, loss of skin sensitivity in the palmar region of the fingers 1, 2, 3. Which nerve was damaged?
- the median nerve**
  - the ulnar nerve
  - the superficial branch of the radial nerve
  - deep branch of the radial nerve
  - lateral cutaneous nerve of the forearm
31. Between the heads of which muscle passes the median nerve in the upper third of the forearm?
- brahioradialis m.
  - flexor carpi ulnaris m.
  - flexor carpi radialis m.
  - pronator teres m.**
  - palmaris longus m.
32. Which muscle covers the anterior interosseous neurovascular bundle in the lower third of the forearm?
- pronator round m
  - pronator quadratus muscle**
  - flexor digitorum profundus m.
  - flexor carpi ulnaris m.
  - flexor carpi radialis m.
33. List the elements that are part of the anterior interosseous neurovascular bundle of the forearm?
- median nerve
  - radial artery
  - anterior interosseous artery**
  - anterior interosseous nerve**
  - posterior interosseous vein
34. To assess the pulse in the lower third of the forearm, radial artery is the most optimal, which is due to the?
- location of the artery just below its fascia propria of the forearm**
  - location of the artery to the external surface of radius bone**
  - the large diameter of the radial artery
  - lack of blood collaterals and nerve
  - the location of the artery in the subcutaneous space



35. The skin in the lateral surface of the forearm is innervated by the lateral cutaneous nerve of the forearm, which originates from which nerve?
- from musculocutaneous nerve**
  - from the median nerve
  - from the radial nerve
  - from the lateral bundle of the brachial plexus
  - from medial bundle of the brachial plexus
36. List all muscles of the superficial layer of the posterior region of the forearm, from lateral to medial:
- extensor carpii radialis longus m., extensor carpii radialis brevis m., common extensor m. of fingers, extensor digiti minimi m., extensor carpii ulnaris m.**
  - extensor carpii ulnaris m., extensor carpii radialis brevis m., common extensor m. of fingers, extensor digiti minimi m., extensor carpii radialis longus m.
  - extensor carpii ulnaris m., common extensor m. of fingers, extensor carpii radialis brevis m., extensor digiti minimi m., extensor carpii radialis longus m.
  - extensor digiti minimi m., common extensor m. of fingers, extensor carpii radialis brevis m., extensor carpii ulnaris m., extensor carpii radialis longus m.
  - extensor carpii radialis brevis m., extensor digiti minimi m., common extensor m. of fingers, extensor carpii ulnaris m., extensor carpii radialis longus m.
37. List all muscles of the deep layer of the posterior region of the forearm, from lateral to medial:
- supinator m., abductor policis longus m., extensor policis brevis m., extensor policis longus m., extensor indicis m.**
  - extensor policis longus m., supinator m., abductor policis longus m., extensor policis brevis m., extensor indicis m.
  - abductor policis longus m., extensor policis longus m., supinator m., extensor policis brevis m., extensor indicis m.
  - abductor policis longus m., extensor policis brevis m., extensor policis longus m., supinator m., extensor indicis m.
  - extensor indicis m., abductor policis longus m., extensor policis brevis m., extensor policis longus m., supinator m.,
38. Posterior deep space of the forearm is located between:
- common extensor m. of fingers and abductor policis longus m. and it is separated by two vertical septa. It communicates along the vessels and nerves with Paron –Pirogov space.**
  - extensor carpii ulnaris m. and the second layer of extensor mm, and it is separated by two vertical septa. It communicates on the path of vessels and nerves with Paron –Pirogov space.
  - extensor carpii radialis brevis m. and the second layer of extensor mm, and it is separated by two vertical septa. It communicates on the path of vessels and nerves with Paron –Pirogov space.
  - extensor digiti minimi m. and the second layer of extensor mm, and it is separated by two vertical septa. It communicates on the path of vessels and nerves with Paron –Pirogov space.
  - extensor carpii radialis longus m. and the second layer of extensor mm, and it is separated by two vertical septa. It communicates on the path of vessels and nerves with Paron –Pirogov space.
39. Select the correct answer regarding neurovascular bundles on the middle third of the forearm:



- 4 – ulnar; 5 – anterior interosseous; 7 – posterior interosseous; 9 – median; 13 – radial**
- 4 – anterior interosseous; 5 – ulnar; 7 – posterior interosseous; 9 – median; 13 – radial
- 4 – ulnar; 5 – posterior interosseous; 7 – anterior interosseous; 9 – median; 13 – radial
- 4 – radial; 5 – anterior interosseous; 7 – posterior interosseous; 9 – median; 13 – ulnar
- 4 – median; 5 – anterior interosseous; 7 – posterior interosseous; 9 – ulnar; 13 – radial

## HAND REGION

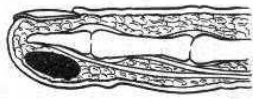
- In the subcutaneous tissue of the anterior carpal region we can find the following structures:
  - cephalic and basilic vv.**
  - cubital intermediate v.
  - medial cutaneous nerve of the forearm**
  - radial n.
  - lateral cutaneous nerve of the forearm**
- Carpal canal contains the following anatomical structures:
  - median n.**
  - superficial branch of the radial n.
  - tendons of the flexor digitorum superficialis and flexor digitorum profundus muscles**
  - tendon of the flexor pollicis longus muscle**
  - ulnar n.
- Canalis carpi ulnaris (Guyon's canal) contains:
  - tendon of the flexor carpi ulnaris m.
  - ulnar artery and vein**
  - ulnar nerve**
  - tendon of the flexor digiti minimi m.
  - tendon of the palmaris longus m.
- The syntopy of the anatomical structures in the canalis carpiulnaris (of Guyon) is:
  - the artery is situated medial to the nerve
  - the nerve is situated superficially
  - the artery is situated laterally and superficially**
  - the vein is situated medially to the nerve
  - the nerve is situated deeper and medially to the artery**
- The canalis carpi radialis contains:
  - radial artery and vein
  - radial nerve
  - tendon of the flexor carpi radialis muscle**
  - median nerve
  - superficial branch of the radial nerve
- Median nerve compression syndrome in the carpal region is determined by:
  - localization of the nerve between dense fibrous structures with low elasticity**
  - the presence of the arteria comitans of the median nerve
  - the close localization of the pisiform bone
  - thickness of the median n.
  - all answers are correct
- In the subcutaneous tissue of the posterior carpal region are situated the following structures:
  - cephalic and basilic veins**
  - tendons of the extensors mm.
  - medial and lateral cutaneous nn. of the forearm
  - posterior cutaneous n. of the forearm**
  - superficial branch of the radial n., dorsal branch of the ulnar n.**
- The radiocarpal joint is formed by:
  - the radius**
  - the trapezoid bone
  - the ulnar bone with the articular cartilage**
  - the proximal row of carpal bones**
  - the pisiform bone
- The proximal row of carpal bones are the following:
  - scaphoid**
  - semilunar**
  - triquetrum**
  - trapezium

- e) **pisiform**
10. The palmar aponeurosis is formed by:
- a) the expanded tendon of palmaris brevis muscle
  - b) the expanded tendon of palmaris longus muscle**
  - c) thickening and fusion of superficial and deep fascias
  - d) the confluence of the tendons of flexors muscles
  - e) is a triangular, thick and solid membrane of dense connective tissue**
11. The superficial palmar arterial arch is projected:
- a) on the proximal transverse palmar crease**
  - b) in the middle of metacarpal bones**
  - c) on the distal transverse palmar crease
  - d) on the metacarpophalangeal crease
  - e) it intersects twice the line between pisiform bone and the 2<sup>nd</sup> metacarpophalangeal joint**
12. The deep palmar arterial arch is situated:
- a) more proximally than the superficial arch**
  - b) more distally than the superficial arch
  - c) at the same level with the superficial arch
  - d) it is situated in deep palmar space (under deep palmar fascia)**
  - e) it is situated in the mesothenar fascial lodge**
13. In the mesothenar fascial lodge can be found:
- a) tendons of the flexor digitorum superficialis and flexor digitorum profundus muscles**
  - b) common palmar digital nerves, superficial palmar arterial arch**
  - c) tendon of the flexor pollicis longus muscle
  - d) subaponeurotic space, subtendinous space**
  - e) lumbrical muscles**
14. The pus from the subaponeurotic space of the mesothenar fascial compartment can spread:
- a) along the digital neurovascular bundles to the subcutaneous tissue of the fingers**
  - b) along the deep branch of the ulnar nerve and artery into subtendinous space
  - c) through carpal canal to the forearm, in Paron-Pirogov space**
  - d) along the lumbrical muscles to the dorsal region of the fingers**
  - e) along the deep palmar arch to the dorsal part of the hand
15. The ulnar synovial bursa contains the tendons of:
- a) flexor digitorum superficialis muscle**
  - b) flexor carpi radialis muscle
  - c) flexor digitorum profundus muscle**
  - d) flexor pollicis longus muscle
  - e) flexor carpi ulnaris muscle
16. The motor branch of the median nerve innervates the following muscles of the thenar:
- a) adductor pollicis muscle
  - b) flexor pollicis brevis muscle (deep head)
  - c) abductor pollicis brevis muscle**
  - d) opponens pollicis muscle**
  - e) flexor pollicis brevis muscle (superficial head)**
17. The deep branch of the ulnar nerve innervates the following muscles:
- a) palmaris brevis m.**
  - b) interosseous mm.**
  - c) adductor pollicis m.**
  - d) flexor pollicis brevis m. (deep head)**
  - e) flexor pollicis brevis m. (superficial head)
18. The palmar region of the fingers is innervated as follows:
- a) superficial branch of ulnar nerve - ulnar surface of the 4<sup>th</sup> and 5<sup>th</sup> fingers**
  - b) median nerve - the 1<sup>st</sup>, 2<sup>nd</sup>, 3<sup>rd</sup> fingers and radial surface of the 4<sup>th</sup> fingers**
  - c) radial nerve - the 1<sup>st</sup>, 2<sup>nd</sup>, 3<sup>rd</sup> fingers and radial surface of the 4<sup>th</sup> fingers
  - d) radial nerve - 1<sup>st</sup> finger, median nerve - 2<sup>nd</sup>, 3<sup>rd</sup> and 4<sup>th</sup>, ulnar nerve - 5<sup>th</sup> finger

- e) all answers are wrong
19. The dorsal region of the fingers is innervated as follows:
- superficial branch of radial nerve – 1<sup>st</sup>, 2<sup>nd</sup> fingers and radial surface of the 3<sup>rd</sup>**
  - median nerve - radial surface of the 1<sup>st</sup>, 2<sup>nd</sup>, 3<sup>rd</sup> and 4<sup>th</sup> fingers
  - dorsal branch of ulnar nerve -4<sup>th</sup> 5<sup>th</sup> fingers and ulnar surface of the 3<sup>rd</sup>**
  - radial nerve - radial surface of the 5<sup>th</sup> finger
  - median nerve - 3<sup>rd</sup> and 4<sup>th</sup> finger
20. The superficial palmar arterial arch is formed by:
- radial a. and deep branch of the ulnar a.
  - ulnar a. and deep branch of the radial a.
  - metacarpal aa.
  - digital aa.
  - anastomosis between the ulnar a. and superficial branch of the radial a.**
21. The limits of the mesothenar fascial lodge are:
- ligaments of the flexors muscles
  - palmar aponeurosis**
  - medial and lateral intermuscular septa**
  - the space under the ligaments
  - deep interosseous (palmar) fascia**
22. The pus from palmar ulnar and radial synovial bursae can spread:
- from one to another**
  - hypothenar lodge
  - mesothenar spaces**
  - Paron-Pirogov space**
  - radiocarpal joint**
23. What type of whitlow is the paronychia?
- cutaneous
  - subcutaneous
  - onychial**
  - pandactylitis
  - tendinous
24. The osteofibrous canals of the fingers are formed by:
- periosteum of the phalanx**
  - palmar fascia of the fingers**
  - the parietal layer of the synovial sheath
  - the visceral layer of the synovial sheath
  - flexor's ligaments
25. The tendons of the flexor digitorum profundus muscle inserts on the:
- base of middle phalanx
  - base of distal phalanx**
  - tuberosity of distal phalanx
  - midpoint of middle phalanx
  - proximal margin of the nail
26. The tendons of the flexor digitorum superficialis muscle inserts on the:
- base of middle phalanx
  - base of distal phalanx
  - tuberosity of distal phalanx
  - midpoint of middle phalanx**
  - none of the answers
27. The synovial sheaths of the flexors on the fingers are formed by:
- fibrous canal
  - peritenon**
  - periosteum of the phalanx
  - epitenon**

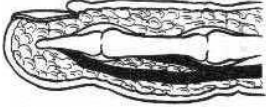
e) **mesotenon**

28. Articular line of the metacarpophalangeal joint is projected distally from the prominence of the head of metacarpal bone at a distance of:
- a) 10-12 mm
  - b) 8-10 mm**
  - c) 6-8 mm
  - d) 4-6 mm
  - e) 2-4 mm
29. Articular line of the proximal interphalangeal joint is projected distally from the prominence of the head of proximal phalanx at a distance of:
- a) 10-12 mm
  - b) 8-10 mm
  - c) 6-8 mm**
  - d) 4-6 mm
  - e) 2-4 mm
30. Articular line of the distal interphalangeal joint is projected distally from the prominence of the head of middle phalanx at a distance of:
- a) 2-4 mm**
  - b) 4-6 mm
  - c) 6-8 mm
  - d) 8-10 mm
  - e) 10-12 mm
31. A patient with a right hand trauma was admitted to the emergency department. During examination edema and pain are revealed at palpation in the "anatomic snuffbox". A bone fracture is suspected. Which bone could it be?
- a) trapezius
  - b) scaphoid**
  - c) trapezoid
  - d) lunate
  - e) pisiform
32. A patient has tenosynovitis of the 2<sup>nd</sup> finger; by the 4<sup>th</sup> day from the beginning of the illness necrosis of the tendon of flexor digitorum profundus is determined. What might be the cause of the necrosis of the tendon?
- a) compression of the digital arteries
  - b) compression of the mesotenon by the liquid accumulated in the synovial sheath**
  - c) compression of the tendon
  - d) compression of the digital muscles
  - e) compression of the digital nerves
33. Pus from the synovial sheath of the 5<sup>th</sup> finger may spread to:
- a) subcutaneous fatty tissue of the distal phalanx
  - b) Paron-Pirogov cellular space through mesothenar compartment and carpal canal**
  - c) mesothenar compartment**
  - d) dorsal region of the hand along with the lumbrical muscles**
  - e) dorsal region of the forearm
34. What type of whitlow is drawn:



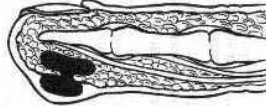
- a) subcutaneous**
- b) paronychia
- c) of the bone
- d) subungual
- e) tendineous

35. What type of whitlow is drawn:



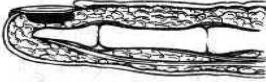- a) of the skin
- b) of the joint
- c) subepidermal
- d) tendineous**
- e) subcutaneous

36. What type of whitlow is drawn:



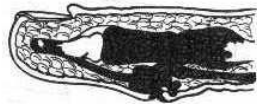
- a) cutaneo-subcutaneous – “collar stud”-shaped infection**
- b) paronychia
- c) tendineous
- d) subungial
- e) subcutaneous

37. What type of whitlow is drawn:



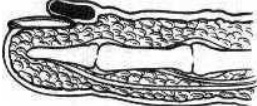
- a) of the skin
- b) paronychia
- c) subcutaneous
- d) subungual**
- e) tendineous

38. What type of whitlow is drawn:



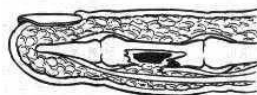
- a) subcutaneous
- b) pandactylitis**
- c) of the bone
- d) subungual
- e) tendineous

39. What type of whitlow is drawn:



- a) of the skin
- b) paronychia**
- c) of the bone
- d) subungual
- e) tendineous

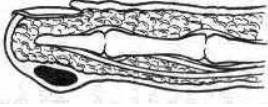
40. What type of whitlow is drawn:



- a) of the skin
- b) paronychia
- c) of the bone**

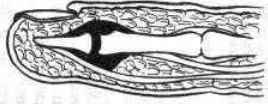
- d) subungual
- e) subcutaneous

41. What type of whitlow is drawn:



- a) **cutaneous**
- b) paronychia
- c) subcutaneous
- d) subungual
- e) tendineous

42. What type of whitlow is drawn:



- a) Subperiosteal
- b) **articular**
- c) of the bone
- d) subungual
- e) subcutaneous

43. In case of tenosynovitis and tendon bursitis of 1-st hand finger, the pus may spread:

- a) **on the entire finger**
- b) **into carpal canal**
- c) **in the distal third of the anterior region of the forearm**
- d) in the sheath of extensor carpi ulnaris muscle
- e) **in the synovial sheath of the 5'th finger (when there is a communication between both synovial bursae)**

44. The subaponeurotic space of the metacarpal region is located:

- a) between the skin and the palmar aponeurosis
- b) **between palmar aponeurosis and superficial tendons of the flexor digitorum superficialis muscle**
- c) between the tendons of flexor digitorum superficialis and profundus muscles
- d) between the tendons of the flexor digitorum profundus muscle and deep palmar fascia
- e) between the deep palmar fascia and palmar interosseus muscles

45. The subaponeurotic space of the mesothenar contains the following anatomical structures:

- a) **common digital arteries and common digital nerves**
- b) **muscular branches of the median nerve**
- c) **superficial palmar arterial arch**
- d) muscular branches of ulnar nerve
- e) **connective tissue**

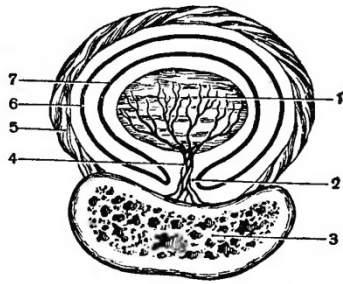
46. The subtendinous space of the mesothenar communicates with the Pirogov-Paron space through:

- a) the commissural foramina
- b) lumbrical muscles canals
- c) interosseus muscles
- d) **along the tendons of flexor digitorum profundus muscle**
- e) along the radial and ulnar arteries

47. Fascial lodge of 1'st finger communicates with the space of Pirogov-Paron through:

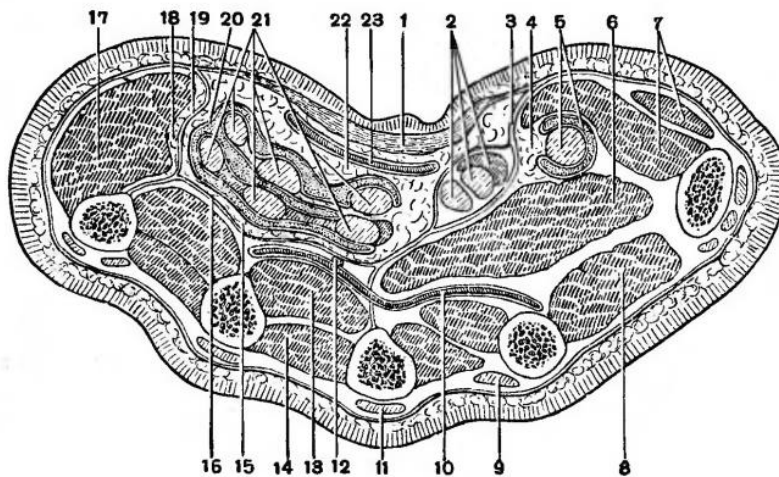
- a) along the tendon of the extensor digitorum longus m
- b) along the tendon of the abductor longus pollicis m
- c) along the tendon of the abductor pollicis brevis m
- d) along the tendon of the flexor pollicis brevis m
- e) along the **tendon of the flexor pollicis longus m**

48. Name all the structures in this cross section of the middle phalanx, as follows in order from 1 to 7:



- a) **tendon, mezotenon, phalangeal bone, tendon's arteries and nerves, proper fascia which forms osteofibros channel, epitenon, peritenon**
- b) phalangeal bone, tendon, mezotenon, tendon's arteries and nerves, proper fascia which forms osteofibros channel, epitenon, peritenon
- c) tendon's arteries and nerves, tendon, mezotenon, phalangeal bone, proper fascia which forms osteofibros channel, epitenon, peritenon
- d) proper fascia which forms osteofibros channel, tendon, mezotenon, phalangeal bone, tendon's arteries and nerves, epitenon, peritenon
- e) tendon's arteries and nerves, epitenon, peritenon, tendon, mezotenon, phalangeal bone, proper fascia which forms osteofibros channel

49. In this cross section of the hand, which numbers correspond to palmar spaces?



- a) **4, 15, 18, 22**
- b) 1, 10, 12, 17
- c) 4, 8, 19, 28
- d) 12, 15, 17, 18
- e) 5, 9, 16, 22

50. Which muscles are located in the thenar compartment of the hand?

- a) **abductor and flexor pollicis brevis mm.**
- b) **opponens pollicis m.**
- c) **tendon of flexor pollicis longus m.**
- d) **adductor pollicis m.**
- e) palmaris brevis m.

51. Which muscles are located in hypthenar compartment of the hand?

- a) **abductor digiti minimi m.**
- b) **flexor digiti minimi m.**
- c) **opponens digiti minimi m.**
- d) adductor digiti minimi m.
- e) **palmaris brevis m.**



## LOWER LIMB

### GLUTEAL REGION

- Projection of the superior gluteal a. is:
  - the superior quadrant of the gluteal region
  - middle of the gluteal region
  - the line that connects the posterior-superior iliac spine with the great trochanter, the point between the superior and medial third**
  - the middle of the line that connects posterior-superior iliac spine with the ischial tuberosity
  - none of the answers
- Projection of the inferior gluteal a. is:
  - the line that connects the posterior-superior iliac spine with the great trochanter, the point between the superior and medial third
  - more inferior and extern from the middle of the line that connects posterior-superior iliac spine with the ischial tuberosity**
  - the region of the ischial tuberosity, point between superior and medium third
  - on the external line of the sacrum, point between superior and medium third
  - the superior-inferior quadrant, point between medium and superior third
- Projection of the sciatic nerve is the line that connects:
  - middle of the distance between the ischial tuberosity and the apex of the greater trochanter**
  - middle of the popliteal fossa**
  - ischial tuberosity
  - the medial third of the gluteal fold
  - the suprapiriform hole
- Which muscle does not take part in the formation of the middle layer of the gluteal region:
  - gluteus medius m.
  - piriformis m.
  - obturator internus m.
  - obturator externus m.**
  - quadratus femoris m.
- What muscles are part of the deep layer of the gluteal region:
  - gemellus mm.
  - obturator internus m.
  - obturator externus m.**
  - gluteus minor m.**
  - piriformis m.
- The fatty tissue space under the gluteus maximus m. communicates with:
  - small pelvis cavity**
  - ischiorectal fossa**
  - posterior lodge of the thigh**
  - retroperitoneal space
  - anterior lodge of the thigh**
- The fatty tissue space from the gluteal region communicates with the small pelvis through:
  - sciatic minor orifice
  - suprapiriform orifice**
  - proximal part of the ligament of the gluteus major m.
  - infrapiriform orifice**
  - all answers are correct
- Through the suprapiriform orifice pass the following structures:
  - superior gluteal a. and v.**
  - superior gluteal n.**
  - sciatic n.
  - inferior gluteal a.
  - external pudendal n.

9. Through the infrapiriform orifice pass the following structures:
- inferior gluteal a., v., n.**
  - sciatic n., n. cutaneus femoris posterior**
  - lateral cutaneous nerve of thigh
  - internal pudendal a., v., pudendal n.**
  - external pudendal a., v., n.
10. The great sciatic foramen is limited by:
- sacrospinous lig.
  - sacrospinous lig.**
  - lesser sciatic notch
  - greater sciatic notch**
  - sacrum**
11. The lesser sciatic foramen is limited by:
- greater sciatic notch
  - sacrospinous lig.**
  - sacrospinous lig.**
  - lesser sciatic notch**
  - sacrum**
12. Superior gluteal nerve exits the pelvis through:
- greater sciatic foramen**
  - lesser sciatic foramen
  - obturator foramen
  - suprapiriform foramen**
  - infrapiriform foramen
13. Pudendal Alcock's canal contains:
- obturator a., v., n.
  - external pudendal a., v., n.
  - internal pudendal a., v.**
  - pudendal n.**
  - inferior gluteal a., v., n.
14. Which of the muscles have their insertion on the greater trochanter?
- piriformis m.**
  - gluteus maximus m.
  - gluteus minimus m.**
  - quadratus femoris m.
  - iliopsoasm.
15. The piriformis muscle has origin from:
- posterior superior iliac spine
  - ala of ilium
  - coccyx
  - anterior surface of sacrum**
  - anterior superior iliac spine
16. What is the sintopy of the sciatic nerve in the infrapiriform foramen:
- lateral than all structures**
  - more medial than all structures
  - between the pudendal and gluteal inferior neurovascular bundles
  - medial from the inferior gluteal a.
  - in general passes through the suprapiriform foramen
17. Where goes the internal pudendal a. and v. and the pudendal n. from the gluteal region:
- parietal space of the pelvis
  - the posterior compartment of the thigh
  - ischioanal fossa**
  - the anterior compartment of the thigh
  - the retrorectal space of the pelvis

18. Which of the following statements are correct regarding the topography of internal pudend neurovascular bundle:
- leaves the basin through the suprapiriform hole
  - goes out of the basin through the infrapiriform opening**
  - is located more medially in relation to the other structures**
  - surrounds the sacrospinal ligament and penetrates back into the basin through the small ischial hole**
  - is situated in obturatory membrane duplication (Alcock canal) and enters the ischiorectal fossa**
19. On the path of which formations communicates the adipose cellular tissue space of the gluteal region with medial lodge space of the thigh?
- on the line of anastomosis of the superior gluteal artery and obturator artery
  - on the line of anastomosis between inferior gluteal artery and obturator artery**
  - on the line of anastomosis of the superior gluteal artery and medial femoral circumflex artery
  - on the line of anastomosis of the superior gluteal artery and lateral femoral circumflex artery
  - on the line of anastomosis of the superior gluteal artery and internal pudend artery
20. Which of these limits refer to the gluteal region?
- midline of the sacrum and coccyx**
  - the inguinal ligament
  - line connecting the pubic symphysis to the medial condyle of the femur
  - gluteal fold**
  - the line connecting the pubic symphysis to the anterior superior iliac spine
21. The greater sciatic orifice in the gluteal region is crossed by the following muscles:
- iliopsoas m.
  - internal obturator m.
  - external obturator m.
  - piriform m.**
  - gluteus medial m.
22. Superficial gluteal cellular space is located between:
- between the superficial and deep lamina of the gluteal fascia
  - between the skin and superficial lamina of gluteal fascia
  - between gluteus maximus m and superficial lamina of proper fascia
  - between gluteus maximus m and deep lamina of proper fascia
  - between the gluteus maximus m. and piriform m.**
23. To the gluteus medius muscle from inferior joins the following muscles:
- external obturator muscle
  - piriform muscle**
  - internal obturator muscle
  - square lumbar muscle
  - muscle gemelus
24. Through infrapiriform opening in the gluteal region pass these anatomical formations ,except:
- cellular adipose tissue
  - the sciatic nerve
  - femoral nerve**
  - inferior gluteal veins
  - internal pudental artery
25. The most medial anatomical structure which leaves the infrapiriform hole:
- the pudendal nerve**
  - superior gluteal nerve
  - inferior gluteal nerve
  - the sciatic nerve
  - cutaneus femoris posterior nerve
26. Deep gluteal cellular space is located between the following muscle:
- between gluteus maximus and minimus m.**
  - between piriform m and internal obturator m.
  - between internal and external obturator mm.
  - between internal obturator and squared lumbar m.

- e) none of the above variants
27. Deep gluteal cellular space communicates with the posterior lodge of the thigh on the trajectory of:
- obturator artery
  - the sciatic nerve**
  - femoral nerve
  - superior gluteal artery
  - the pudendal nerve
28. Superficial gluteal cellular space communicates with the abductor lodge of the thigh on the trajectory of:
- the sciatic nerve
  - tendon of the internal obturator m.
  - tendon of the external obturator m.**
  - femoral nerve
  - obturator artery and vein
29. Deep gluteal cellular space communicates with the pelvic parietal cell space in the line of:
- superior gluteal neurovascular bundle**
  - obturator vessels
  - neurovascular bundles that exit from pelvis through infrapiriform hole**
  - piriform muscle
  - femoral canal
30. Deep gluteal cellular space communicates with ischiorectal fossa on the path of:
- pudental vessels**
  - the sciatic nerve
  - obturator vessels
  - femoral vein
  - lacuna musculorum
31. The deep phlegmon of the gluteal region mostly is situated :
- between the large, medium and small gluteal muscles
  - between the skin and superficial fascia
  - between large and medium gluteal muscles**
  - between the superficial fascia and the proper one
  - between the superficial and deep lamina of the proper fascia
32. What is the projection line of sciatic nerve in gluteal region:
- perpendicular line (length – 4 cm) which is drawn through the middle of distance between greater trochanter and anterior iliac spine**
  - a line which is drawn through the middle of distance between greater trochanter and anterior iliac spine
  - a line which is drawn through the middle of distance between anterior iliac spine and ischial tuberosity
  - a line which is drawn through the medial third of gluteal fold
  - a line which is drawn through the middle of gluteal region

## HIP JOINT (COXOFEMORAL ) REGION

1. Which are the internal ligaments of the coxofemoral joint:
  - a) iliofemoral lig.
  - b) pubofemoral lig.
  - c) ischiofemoral lig.
  - d) lig. capitis femoris**
  - e) orbicular zone
  
2. Which are the weak points of the capsule of the coxofemoral joint:
  - a) capsule of coxofemoral joint does not have weak points
  - b) the collections of pus can spread through every region of the joint capsule
  - c) anterior between the pubofemoral and the iliofemoral ligaments**
  - d) posterior and inferior under the inferior margin of the ischiofemoral ligament**
  - e) the lateral part of the joint
  
3. The pus from the hip joint can spread anterior on the path of the pubofemoral and iliofemoral ligaments towards:
  - a) the fascial sheath of the iliopsoas m.**
  - b) ilipectineal bursa**
  - c) gluteal region**
  - d) medial region of the thigh**
  - e) antero-lateral region of the abdomen
  
4. Blood supply of the hip joint is provided by the following arteries:
  - a) internal pudendal artery
  - b) ascending branch of the lateral circumflex femoral artery**
  - c) acetabular branch of the obturator artery**
  - d) inferior gluteal artery**
  - e) medial circumflex femoral artery**
  
5. Arterial net of the hip joint region is formed by the following arterial anastomosis:
  - a) gluteal superior a. with ascending branch of a. circumflexae femoris lateralis**
  - b) gluteal inferior a. with ascending branch of a. circumflexae femoris medialis**
  - c) gluteal superior a. with obturator artery
  - d) obturatoria with a. circumflexae femoris lateralis
  - e) a. obturatoria with a. circumflexae femoris medialis**
  
6. In case of purulent process of coxofemoral joint the exudate spreads into the gluteal region on path of:
  - a) medium gluteal muscle
  - b) the sciatic nerve
  - c) iliopsoas muscle
  - d) external obturator muscle**
  - e) obturator canal
  
7. In case of purulent process of coxofemoral joint the exudate spreads to pelvic cavity on path of:
  - a) external obturator muscle**
  - b) the femoral canal
  - c) femoral artery
  - d) lacuna musculorum
  - e) internal obturator muscle

## ANTERIOR-MEDIAL REGION OF THE THIGH

1. Lacuna musculorum contains:
  - a) femoral branch of the genitofemoral nerve
  - b) femoral a., v.
  - c) **iliopsoas m.**
  - d) **femoral n.**
  - e) **lateral cutaneous n. of thigh**
  
2. In the subinguinal vascular gap (lacuna vasorum) are:
  - a) lateral cutaneous n. of thigh
  - b) iliopsoas m.
  - c) femoral n.
  - d) **femoral a., v.**
  - e) **femoral branch of the genitofemoral n.**
  
3. The projection of the deep femoral ring is:
  - a) **the medial 1/3 of the inguinal ligament**
  - b) the external 1/3 of the inguinal ligament
  - c) the middle of the inguinal ligament
  - d) lateral from the anterior inferior iliac spine
  - e) medial from the anterior inferior iliac spine
  
4. Projection of the femoral artery is the line that connects points and what is the position of lower extremity:
  - a) **middle of the inguinal ligament**
  - b) **medial epicondyle of the femoral bone**
  - c) proximal edge of the patella
  - d) flexion and internal rotation of lower extremity
  - e) **flexion and external rotation of lower extremity**
  
5. Projection of the femoral nerve is:
  - a) **1 - 2cm laterally from the place where we can palpate the femoral a.**
  - b) inferior from the femoral a.
  - c) posterior from the femoral a.
  - d) anterior from the femoral a.
  - e) between the femoral artery and vein
  
6. Limits of the femoral triangle of Scarpa are:
  - a) **inguinal ligament**
  - b) **adductor longus m.**
  - c) vastus lateralis m.
  - d) **sartorius m.**
  - e) gracilis m.
  
7. The floor of the femoral triangle is represented by:
  - a) **iliopsoas muscle**
  - b) vastus lateralis muscle
  - c) adductor longus muscle
  - d) **pectineus muscle**
  - e) gracilis muscle
  
8. The superficial branches of the femoral artery are:
  - a) internal pudendal a.
  - b) inferior epigastric a.
  - c) **external pudendal a.**
  - d) **superficial circumflex iliac a.**
  - e) **superficial epigastric a.**
  
9. In the subcutaneous fatty tissue of the femoral region are situated the following nerves:
  - a) **genitofemoral n. (femoral branch)**
  - b) **lateral cutaneous n. of thigh**
  - c) **femoral n., anterior cutaneous branches**
  - d) **obturator n., cutaneous branches**

- e) pudendal n.
10. Anterior part of the proximal third of the thigh contains:
- sartorius m. tensor fascia latae m.
  - femoral a, v., n.,**
  - adductor longus m.
  - quadriceps femoris m.**
  - adductor brevis m.
11. Identify the structures placed in the medial (internal) part of the thigh:
- adductor brevis m., pectineus m.**
  - adductor longus m.**
  - adductor magnus m.**
  - gracilis m.**
  - sartorius m.
12. Which of the statements are correct:
- fascia lata forms the iliotibial tract**
  - fascia lata forms the lateral, medial and posterior intermuscular septums**
  - in the femoral triangle it has 2 laminae**
  - the femoral vessels are situated under the deep lamina of fascia lata
  - lamina cribrosa is part of the fascia lata**
13. Which of the following statements are correct:
- the falciform margin is situated above the sartorius m.
  - the falciform margin is situated above the femoral n.
  - fascia cribrosa is situated above the femoral v.**
  - fascia cribrosa is situated under the femoral v.
  - the falciform margin and fascia cribrosa are portions of the superficial lamina of fascia lata**
14. The fatty tissue space from the femoral triangle (Scarp) communicates with:
- retroperitoneal and subperitoneal space through lacuna vasorum and musculorum**
  - subcutaneous fatty tissue of the femur through lamina cribrosa**
  - adductor canal over the femoral neurovascular bundle**
  - medial compartment of the thigh on the path of medial circumflex femoral a.**
  - femoral canal over the femoral v.
15. The limits of the deep femoral ring:
- inguinal ligament**
  - pectineal ligament**
  - lacunar ligament**
  - arcus iliopectineus
  - the sheath of femoral vein**
16. The limits of the superficial femoral ring:
- medial margin of the sartorius m. and lateral margin of adductor magnus m.
  - the falciform margin, superior and inferior horns**
  - the sheath of femoral n. and femoral n.
  - the sheaths of femoral a. and v.
  - none of the answers
17. The femoral canal has the following limits:
- anterior - superficial lamina of fascia lata, superior horn**
  - lateral – the sheath of femoral a.
  - lateral - femoral v.**
  - posterior - deep lamina of fascia lata**
  - posterior - transversal fascia
18. Through the femoral canal passes the following structures:
- femoral artery
  - femoral hernia**
  - femoral nerve
  - femoral vein

e) saphenus nerve

19. The femoral canal contains:

- a) femoral v., a., n.
- b) safena magna v. and genitofemoral n.
- c) **hernial bag**
- d) soft connective tissue and lymph nodes
- e) inguinal superficial lymph nodes

20. The main vessel that forms "Corona mortis" is:

- a) obturator a. from external pudendal a.
- b) obturator a. from femoral a.
- c) **obturator a. from the inferior epigastric artery**
- d) obturator a. from inferior epigastric a.
- e) obturator a. from internal iliac a.

21. The adductor canal is limited by following structures:

- a) **adductor magnus m.**
- b) adductor longus and brevis mm.
- c) **vastus medialis m.**
- d) gracilis and semimembranosus mm.
- e) **lamina vastoadductoria**

22. Which of the statements are not true:

- a) through the superior foramen of the Hunter canal pass the femoral vessels and saphenus n.
- b) through the anterior foramen of the Hunter canal pass the saphenus n. and the genus descendens a. and v.
- c) **through the inferior foramen of the Hunter canal pass the femoral vessels and femoral n.**
- d) through the inferior foramen of the Hunter canal the femoral vessels pass into the popliteal fossa
- e) **through the superior foramen of the Hunter canal pass the femoral vessels and femoral n.**

23. Identify which of the following statements are correct?

- a) **lacuna musculorum is bounded from lacuna vasculorum by the iliopectineal tract**
- b) **the falciform margin bounds the saphenus opening**
- c) superficial epigastric a. takes part in forming the "corona mortis"
- d) **saphenus n. exits through the anterior foramen of the Hunter's canal**
- e) **great saphenus v. flows into the femoral v.**

24. Through the adductor canal (Hunter) pass the following structures:

- a) **femoral artery**
- b) hernial bag of femoral hernia
- c) femoral nerve and lacunar lymphatic node
- d) **femoral vein, saphenus nerve**
- e) deep femoral a. and obturator n.

25. Distal fragment of the femoral bone in case of fracture of the inferior third usually is displaced:

- a) medial towards the proximal fragment
- b) lateral towards the proximal fragment
- c) **posterior, under the pressure of gastrocnemius m.**
- d) medial and anterior, under the action of quadriceps femoris and sartorius mm.
- e) lateral and anterior towards the proximal fragment

26. In case of fracture of the femoral neck the lower limb takes the following position:

- a) internally rotated
- b) **externally rotated**
- c) semiflected in the hip and knee joint
- d) abducted
- e) no determined position

27. The femoral nerve in the superior third of the thigh is situated between:

- a) iliac m.
- b) **iliopsoas m.**
- c) femoral v.
- d) **femoral a.**



e) sartorius m.

28. Quenu line represents the projection of:

- a) the popliteal artery
- b) the sciatic nerve
- c) the femoral vein
- d) the femoral artery**
- e) the deep femoral artery

29. The femoral vein is located compared with the femoral artery in lacuna vasculorum:

- a) posterior to artery
- b) lateral to artery
- c) anterior to the artery
- d) anterolateral to artery
- e) medial to artery**

30. Medial to femoral vein within the deep femoral hole is situated:

- a) the femoral artery
- b) the femoral nerve
- c) the obturator artery
- d) cellular tissue and lymph nodes**
- e) the genito-femoral nerve

31. Femoral artery within the femoral triangle is covered from anterior by:

- a) lamina cribrosa
- b) hiatus saphenus
- c) deep lamina of fascia lata
- d) superficial lamina of fascia lata**
- e) the superficial fascia

32. Femoral nerve within lacuna musculorum is situated in:

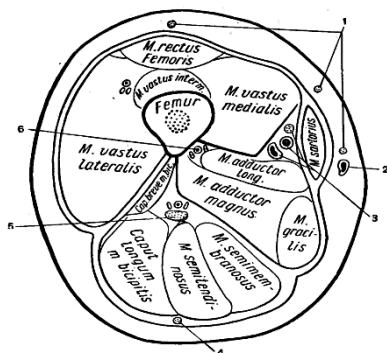
- a) the sheath of sartorius m.
- b) the sheath of right femoral m.
- c) the sheath of iliopsoas m.**
- d) the sheath of pectineal m.
- e) the sheath of adductor brevis m.

33. In case of femoral artery ligation below the deep femoral a departure , in collateral vascularization participates:

- a) circumflex femoris medialis a.
- b) ascending branches of a. perforantes
- c) popliteal a.
- d) deep circumflex ilium a.
- e) all the above variants**

## POSTERIOR REGION OF THE THIGH

1. Projection of the sciatic nerve is the line that connects:
  - a) ischial tuberosity
  - b) middle of the popliteal fossa**
  - c) **middle of the distance between the greater trochanter and the ischial tuberosity**
  - d) medial border of the fibular head
  - e) lateral border of the fibular head
  
2. Identify the structures placed in the middle third of the posterior compartment of the thigh:
  - a) gracilis m.
  - b) semimembranosus and semitendinosus mm.**
  - c) biceps femoris m.**
  - d) sciatic n., perforating aa., descendent branch of lateral circumflex femoral a.**
  - e) pectineus m., adductor magnus m.
  
3. The sciatic nerve lays in the posterior compartment of the thigh:
  - a) at the level of gluteal plica - under fascia lata**
  - b) in the superior third - covered by the long head of biceps femoris m.**
  - c) in the middle third - posterior from the adductor magnus m.**
  - d) in the inferior third between the biceps femoris and the semimembranosus mm.**
  - e) in the inferior third between the semimembranosus and the semitendinosus mm.
  
4. The fatty tissue space from the posterior compartment of the thigh communicates directly with:
  - a) gluteal region**
  - b) the antero-medial region of the thigh
  - c) popliteal fossa**
  - d) lateral region of the thigh
  - e) all answers are true
  
5. External rotation of the leg is determined by:
  - a) biceps femoris m.**
  - b) semimembranosus, semitendinosus, gracilis, sartorius and popliteus mm.
  - c) vastus medialis m.
  - d) medial part of the patellar ligament
  - e) vastus lateralis m.
  
6. Internal rotation of the leg is determined by:
  - a) biceps femoris m.
  - b) semimembranosus, semitendinosus, gracilis, sartorius and popliteus mm.**
  - c) vastus medialis m.
  - d) medial part of the patellar ligament
  - e) vastus lateralis m.
  
7. Determine on cross section of thigh (at medial 1/3 ) correctness anatomical configurations from 1 to 6:



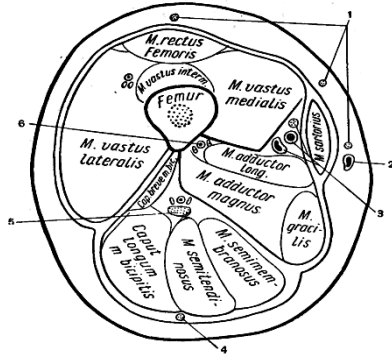
- a) **anterior cutaneous femoral nn., greater safenous v., safenous n., femoral a. and v., posterior cutaneous femoral n., sciatic n., deep femoral vessels**
- b) greater safenous v., anterior cutaneous femoral nn., safenous n., femoral a. and v., posterior cutaneous femoral n., sciatic n., deep femoral vessels
- c) posterior cutaneous femoral n., anterior cutaneous femoral nn., greater safenous v., safenous n., femoral a.

and v., sciatic n., deep femoral vessels

d) anterior cutaneous femoral nn., greater safenous v., safenous n., femoral a. and v., sciatic n., posterior cutaneous femoral n., deep femoral vessels

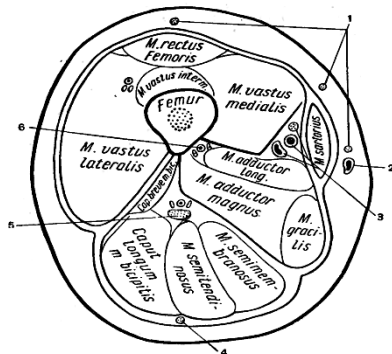
e) anterior cutaneous femoral nn., greater safenous v., safenous n., posterior cutaneous femoral n., femoral a. and v., sciatic n., deep femoral vessels

8. Number 1 anatomical structure in the transverse section of the medium third of the thigh represents:



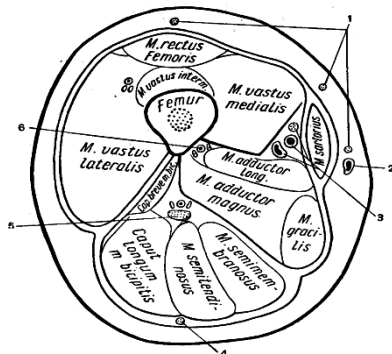
- a) greater safenous v.
- b) femoral neurovascular bundle
- c) deep femoral vessels
- d) cutaneous femoral nn.**
- e) sciatic n.

9. Number 2 anatomical structure in the transverse section of the medium third of the thigh represents:



- a) greater safenous v.**
- b) femoral neurovascular bundle
- c) deep femoral vessels
- d) cutaneous femoral nn.
- e) sciatic n.

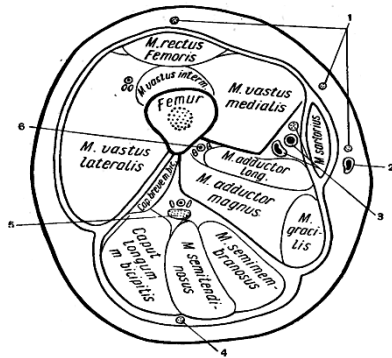
10. Number 3 anatomical structure in the transverse section of the medium third of the thigh represents:



- a) greater safenous v.
- b) femoral neurovascular bundle**
- c) deep femoral vessels

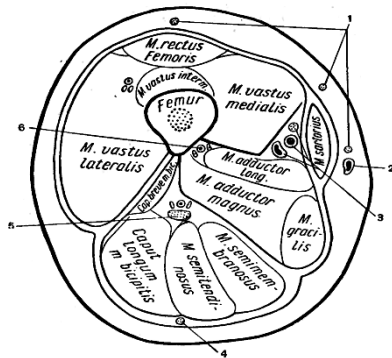
- d) cutaneous femoral nn.
- e) sciatic n.

11. Number 5 anatomical structure in the transverse section of the medium third of the thigh represents:



- a) greater saphenous v.
- b) femoral neurovascular bundle
- c) deep femoral vessels
- d) cutaneous femoral nn.
- e) sciatic n.**

12. Number 4 and 6 anatomical structures in the transverse section of the medium third of the thigh represents:

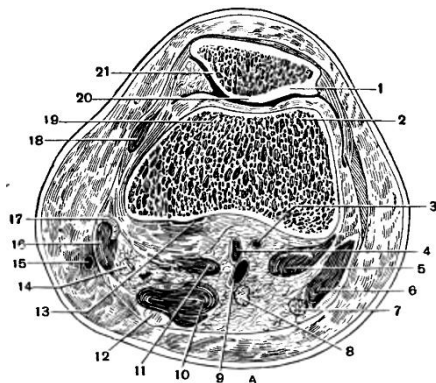


- a) greater saphenous v.
- b) femoral neurovascular bundle
- c) deep femoral vessels**
- d) posterior cutaneous femoral nn.**
- e) sciatic n.

## KNEE REGION

- Bursas of the anterior region of the knee are the following:
  - bursa prepatellaris subcutanea, subfascialis and subtendinea**
  - bursa infrapatellaris superficialis**
  - bursa infrapatellaris profunda**
  - bursa suprapatellaris**
  - bursa poplitea
- Which structures consolidate deep fascia of the anterior region of the knee:
  - retinaculum patellae mediale**
  - retinaculum patellae anterior
  - retinaculum patellae laterale**
  - oblique popliteal ligament
  - proper patellar ligament**
- Which arteries do not participate in forming of the patellar arterial net:
  - a. genus descendens
  - a. poplitea with its branches
  - a. recurrens tibialis anterior
  - r. circumflexus fibulae
  - a. peronea**
- The limits of the popliteal fossa are:
  - tendon of the biceps femoris m.**
  - semimembranosus and semitendinosus mm.**
  - adductor magnus m.
  - gastrocnemius m.**
  - gracilis m.
- What are the projection lines of the structures in the popliteal fossa region:
  - popliteal vessels and the tibial n. – a line connecting the superior angle and middle of popliteal fossa**
  - popliteal vessels and the tibial n. - medial margin of the tendon of the biceps femoris m.
  - the common fibular n. - medial margin of the tendon of the biceps femoris m.**
  - the common fibular n. - lateral margin of the biceps femoris m.
  - the common fibular n. - medial margin of the semimembranosus m.
- What structures can be found in the subcutaneous layer of the popliteal fossa:
  - small saphenous v.**
  - posterior femoral cutaneous n.**
  - tibial n. and great saphenous v.
  - popliteal a. and saphenous n.
  - common fibular n.
- Syntopy of popliteal neurovascular bundle from posterior to anterior:
  - n. tibialis, v. poplitea, a. poplitea**
  - a. poplitea, n. ischiadicus, v. poplitea
  - n. ischiadicus, a. poplitea, v. poplitea
  - v. poplitea, n. ischiadicus, a. poplitea
  - none of answers
- Which of the following statements are correct:
  - popliteal artery is situated lateral to the popliteal vein
  - popliteal vein is situated lateral to the tibial nerve
  - popliteal artery is situated medially and deeper to popliteal vein and tibial nerve**
  - popliteal artery is situated lateral to the peroneal nerve
  - all answers are incorrect
- The sural nerve is:
  - continuation of the saphenus n.
  - continuation of the femoral n.
  - continuation of the cutaneus surae lateralis n.**
  - continuation of the cutaneus surae medialis n.**

- e) all answers are correct
10. Branches of the popliteal artery in the popliteal fossa are:
- a. tibialis anterior
  - a. tibialis posterior
  - aa. genus superiores lateralis and medialis**
  - a. genus media**
  - aa. genus inferiores mediales and laterales**
11. Surgical access to the popliteal artery is more convenient via the following access:
- posterior popliteal, through popliteal fossa
  - medial access, through fossa of Jobert**
  - lateral access
  - transarticular access (through the joint)
  - all are incorrect
12. Fossa of Jobert is bounded by:
- medial condyle of the femur and the medial head of gastrocnemian m.**
  - the distal third of gracilis m.
  - tendons of the adductor magnus m., semimembranosus and semitendinosus mm.**
  - the distal third of sartorius m.**
  - the distal third of popliteus m.
13. What are the ways of spreading the pus from the fatty tissue space of the popliteal fossa:
- anterior region of the thigh**
  - lateral lodge of the leg**
  - obturator canal and Alcock canal
  - posterior region of the thigh**
  - posterior and anterior region of the leg**
14. The cross-section of the knee at the level of femoral condyles, structural elements of neurovascular bundle are located from posterior to anterior:



- popliteal a., popliteal v., sciatic n.
- tibial n., popliteal v., popliteal a.**
- popliteal a., popliteal v., common fibular n.
- sciatic n., popliteal a., popliteal v.
- popliteal a., popliteal v., sciatic n.

## KNEE JOINT

1. The structures that form the knee joint are:
  - a) **femur**
  - b) fibula
  - c) **tibia**
  - d) **patella**
  - e) all answers are correct
2. Which of the following ligaments from the knee joint region are extraarticular:
  - a) anterior cruciate lig.
  - b) **fibular collateral lig.**
  - c) **tibial collateral lig.**
  - d) **oblique popliteal lig.**
  - e) posterior cruciate lig.
3. Which ligaments strengthen the anterior portion of the knee joint:
  - a) **patellar lig.**
  - b) tibial collateral lig.
  - c) fibular collateral lig.
  - d) anterior and posterior cruciate lig.
  - e) **medial and lateral patellar retinaculum**
4. A maximum relaxation of the knee joint ligaments can be obtained in case of:
  - a) maximum flexion of the articulation
  - b) maximum extension of the articulation
  - c) **semiflexion**
  - d) internal rotation
  - e) it is impossible to obtain a simultaneous relaxation of ligaments
5. The intraarticular ligaments of the knee joint are represented by:
  - a) **anterior cruciate lig.**
  - b) **posterior meniscomfemoral lig.**
  - c) arcuate popliteal lig.
  - d) **posterior cruciate lig.**
  - e) transverse genicular lig.
6. The oblique popliteal ligament is the continuation of the following muscle tendon:
  - a) **semimembranosus m.**
  - b) semitendinosus m.
  - c) sartorius m.
  - d) gracilis m.
  - e) adductor magnus m.

## CALF REGION

- Projection of the anterior tibial artery and of the deep peroneal nerve is the line that connects:
  - middle of the distance between the head of the fibula and the tibial tuberosity**
  - middle of the bimalleolar distance**
  - medial malleolus
  - tibial tuberosity
  - head of fibula
- Projection of the posterior tibial artery and of the tibial nerve is the line that connects:
  - middle of the distance between the head of the fibula and the tibial tuberosity
  - medial border of the tibia
  - middle of the distance between Achilles tendon and the medial malleolus**
  - 1 cm lateral from the medial border of tibia
  - middle of popliteal fossa**
- The following structures can be found in the subcutaneous tissue of the leg:
  - small saphenous v.**
  - cutaneous sural nn.**
  - anterior tibial v.
  - great saphenous v. and saphenous n.**
  - anterior tibial a.
- Anterior fascial sheath of the leg region at the level of proximal third contains:
  - anterior tibial artery and vein and the deep fibular nerve**
  - brevis and longus fibular mm.
  - anterior tibial m.**
  - extensor digitorum longus m.**
  - common fibular nerve
- The superior musculo-peroneus canal is formed by:
  - fibularis longus m.**
  - neck of the fibula**
  - fibularis brevis m.
  - anterior tibial m.
  - extensor hallucis longus m.
- Identify structures present at the level of medial third of the leg in the lateral fascial sheath:
  - fibularis longus m.**
  - superficial fibular n.**
  - fibularis brevis m.**
  - fibular a. and v.
  - deep fibular n.
- The deep fibular nerve has the following position according to the anterior tibial artery:
  - in the superior 1/3 - lateral**
  - in the superior 1/3 - medial
  - in the middle 1/3 - anterior**
  - in the middle 1/3 - posterior
  - in the inferior 1/3 - medial**
- Location of the neurovascular bundle of the anterior region of the leg is:
  - in the superior 1/3 - between the anterior tibial m. and extensor digitorum longus m.**
  - in the superior 1/3 - between the extensor digitorum longus m. and extensor hallucis longus m.
  - in the inferior 1/3 - between the anterior tibial m. and extensor hallucis longus m.**
  - in the inferior 1/3 - between the extensor digitorum longus and extensor hallucis longus m.
  - posterior from all muscles of anterior compartment
- Between which muscles is located the deep fibular nerve in the inferior third of the leg:
  - interosseus membrane
  - anterior tibial m.**
  - extensor hallucis longus m.**
  - extensor digitorum longus m.



- e) fibularis longus m.
10. The course of the superficial fibular nerve is:
- in the superior and medial 1/3 passes through the fibers of the fibularis longus m., parallel to anterior intermuscular septum**
  - in the superior and medial 1/3 passes through the fibers of the fibularis brevis m.
  - in the inferior 1/3 parallel to the posterior intermuscular septum
  - between the fibers of the anterior tibial m.
  - in the inferior 1/3 is situated in the subcutaneous tissue**
11. What muscles lay in the superficial compartment of the posterior region of the leg:
- gastrocnemius m.**
  - posterior tibial m.
  - soleus m.**
  - flexor digitorum longus m.
  - plantaris m.**
12. What are the muscles from the deep fascial sheath of the posterior region of the leg:
- flexor digitorum longus m.**
  - flexor hallucis longus m.**
  - soleus m.
  - plantaris m.
  - posterior tibial m.**
13. Which structures unite to form the calcaneal tendon of Achilles:
- tendon of the soleus m.**
  - tendon of the posterior tibial m.
  - tendon of the gastrocnemius m.**
  - tendon of the plantar m.**
  - tendon of the flexor hallucis longus m.
14. The limits of the cruropopliteus canal (Gruber) are:
- interosseus membrane
  - posterior tibial m. from anterior**
  - soleus m. from posterior**
  - flexor hallucis longus m. from lateral, flexor digitorum longus m. from medial**
  - plantar m. from posterior
15. The cruropopliteus canal (Gruber) contains the following structures:
- posterior tibial a. and v.**
  - anterior tibial a. and v.
  - tibial n.**
  - common fibular n.
  - peroneal vessels
16. The limits of the inferior musculofibular canal are:
- fibularis longus m.**
  - fibularis brevis m.
  - posterior tibial m.
  - flexor hallucis longus m.
  - fibula**
17. Which structures are situated in the inferior musculofibular canal:
- common fibular n.
  - tibial n.
  - posterior tibial a.
  - fibular a and v.**
  - fibularis brevis m.
18. Identify structures present at the level of middle third of the leg in the posterior fascial sheath:
- fibularis longus m.
  - soleus m., gastrocnemius m.**
  - flexor digitorum longus and flexor hallucis longus mm., tibial n., posterior tibial a. and v.**

- d) **posterior tibial and plantaris longus mm., fibular a. and v.**
- e) anconeus m.

19. Which of the following statements are correct:

- a) **superior musculofibular canal is formed by the neck of the fibula and the fibularis longus m.**
- b) inferior musculofibular canal is formed by the fibula and the fibularis brevis m.
- c) inferior musculofibular canal contains the peroneal a., v. and n.
- d) **superior musculofibular canal contains the common fibular n.**
- e) **inferior musculofibular canal is formed by the fibula and flexor halucis longus m.**

20. Identify the wrong statements:

- a) arterial trunks can be pressed at the proximal third of the thigh
- b) pseudoarthroses of distal third of tibia are determined by the insufficient blood supply
- c) superficial and deep venous system of the leg connects via communicating veins
- d) **small saphenous vein flows into the femoral vein in the distal third of the thigh**
- e) **sural nerve is a motor nerve**

21. Posterior tibial a. and tibial n. are localized in the middle third of the lower leg between:

- a) **soleus m.**
- b) gastrocnemius m.
- c) **posterior tibial m.**
- d) **flexor hallucis longus and flexor digitorum longus mm.**
- e) flexor digitorum longus m.

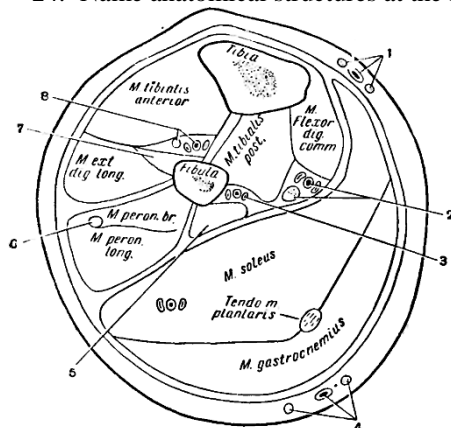
22. To which direction spreads the pus from the cruropopliteal canal:

- a) **popliteal fossa**
- b) **medial malleolar canal**
- c) **anterior fascial sheath of the leg**
- d) **lateral compartement of the leg**
- e) anerior region of the knee

23. Injury of the tibial nerve compromises (leads to):

- a) dorsal flexion of the foot and extension of the toes
- b) **plantar flexion of the foot**
- c) **flexion of the toes**
- d) dorsal flexion of the foot and flexion of the toes
- e) blood supply of the lower leg

24. Name anatomical structures at the medial third level of the leg:



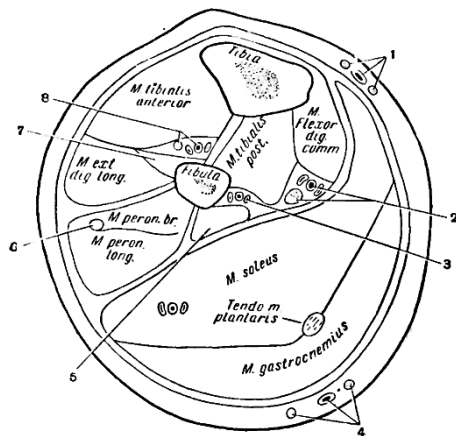
- a) **greater saphenous vein and saphenous n., tibial posterior neurovascular bundle, fibular vessels, minor saphenous vein and cutaneous suralis medialis and lateralis nn., flexor halucis longus m., fibular superficial n., extensor halucis longus m., tibial anterior neurovascular bundle.**
- b) greater saphenous vein and saphenous n., fibular superficial n., tibial posterior neurovascular bundle, fibular vessels, minor saphenous vein and cutaneous suralis medialis and lateralis nn., flexor halucis longus m., extensor halucis longus m., tibial anterior neurovascular bundle.
- c) greater saphenous vein and saphenous n., tibial posterior neurovascular bundle, fibular vessels, extensor halucis longus m., minor saphenous vein and cutaneous suralis medialis and lateralis nn., flexor halucis longus m., fibular superficial n., tibial anterior neurovascular bundle.

- d) greater saphenous vein and saphenous n., tibial posterior neurovascular bundle, fibular vessels, minor saphenous vein and cutaneous suralis medialis and lateralis nn., flexor halucis longus m., extenzor halucis longus m., tibial anterior neurovascular bundle.
- e) greater saphenous vein and saphenous n., flexor halucis longus m., tibial posterior neurovascular bundle, fibular vessels, minor saphenous vein and cutaneous suralis medialis and lateralis nn., extenzor halucis longus m., fibular superficial n., tibial anterior neurovascular bundle.

25. In case of fracture of the tibial bone the bone fragments can move:

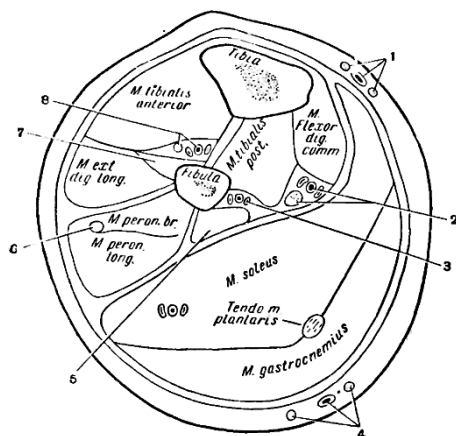
- a) **inferior fragment can move in posterior and supero-lateral directions**
- b) inferior fragment can move in medial direction
- c) **superior fragment can move in anterior direction**
- d) superior fragment can move in posterior direction
- e) inferior fragment can move in anterior direction

26. Number 2 anatomical structure in transverse section of medium third of calf represents:



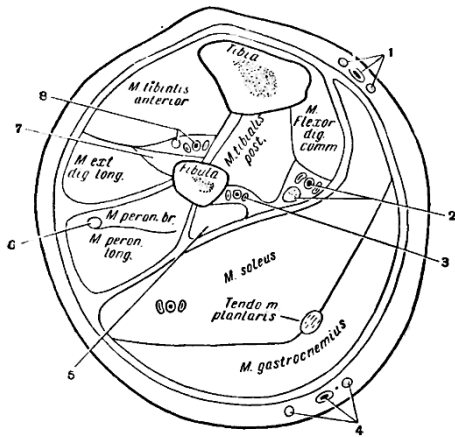
- a) anterior tibial neurovascular bundle
- b) superficial fibular n.
- c) **posterior tibial neurovascular bundle**
- d) greater saphenous vein and saphenous n.
- e) fibular vessels

27. Number 3 anatomical structure in transverse section of medium third of calf represents:



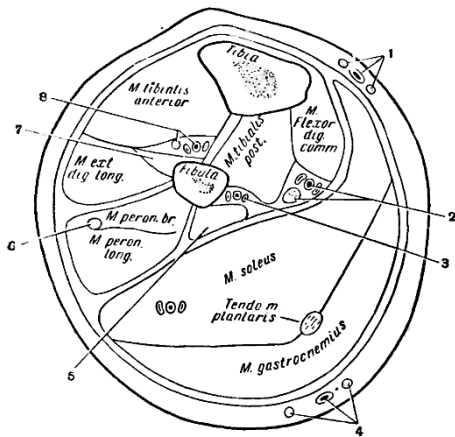
- a) anterior tibial neurovascular bundle
- b) superficial fibular n.
- c) posterior tibial neurovascular bundle
- d) greater saphenous vein and saphenous n.
- e) **fibular vessels**

28. Number 1 anatomical structure in transverse section of medium third of calf represents:



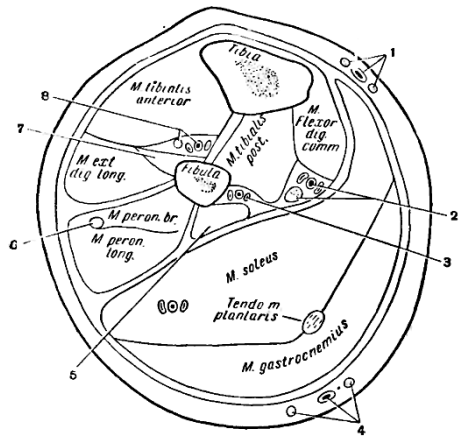
- a) anterior tibial neurovascular bundle
- b) superficial fibular n.
- c) posterior tibial neurovascular bundle
- d) greater saphenous vein and saphenous n.**
- e) fibular vessels

29. Number 6 anatomical structure in transverse section of medium third of calf represents:



- a) anterior tibial neurovascular bundle
- b) superficial fibular n.**
- c) posterior tibial neurovascular bundle
- d) greater saphenous vein and saphenous n.
- e) fibular vessels

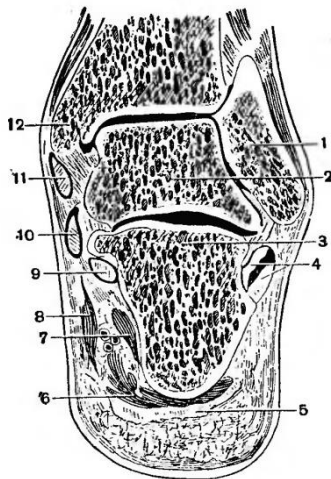
30. Number 8 anatomical structure in transverse section of medium third of calf represents:



- a) anterior tibial neurovascular bundle
- b) superficial fibular n.
- c) posterior tibial neurovascular bundle
- d) greater saphenous vein and saphenous n.
- e) fibular vessels

## THE TALOCRURAL (ANKLE) REGION

1. What structures form the ankle joint?
  - a) **tibia**
  - b) **fibula**
  - c) **astragalus (talus)**
  - d) calcaneus
  - e) navicular bone
  
2. What structures are situated between the superficial and proper fascia in the talocrural joint region:
  - a) **great saphenous v. and saphenous n., anterior from medial malleolus**
  - b) **small saphenous v. and sural n., posterior from lateral malleolus**
  - c) great saphenous v. and saphenous n., posterior from lateral malleolus
  - d) **superficial fibular n. in the anterior part of the articulation**
  - e) small saphenous v. and sural n., anterior from medial malleolus
  
3. The medial malleolar canal is formed by:
  - a) **retinaculum of flexorum mm.**
  - b) **medial part of the calcaneus bone**
  - c) retinaculum of extensorum superior mm.
  - d) lateral part of the calcaneus bone
  - e) retinaculum of the extensorum inferior mm.
  
4. The medial malleolar canal contains the following structures:
  - a) **tendon of the posterior tibial m.**
  - b) **tendons of flexor digitorum longus and flexor hallucis longus mm.**
  - c) Achilles tendon
  - d) **posterior tibial a. and v., tibial n.**
  - e) tendon of soleus m.
  
5. Syntopy of the anatomical structures in the medial malleolar canal on right talocrural cross-section is:



- a) **11- tendon of tibial posterior m., 10- tendon of flexor digitorum longus m., 9- tendon of flexor hallucis longus m.**
  - b) 11- tendon of flexor digitorum longus m., 10- tendon of tibial posterior m., 9- tendon of flexor hallucis longus m.
  - c) 11- tendon of flexor hallucis longus m., 10 - tendon of flexor digitorum longus m., 9- tendon of tibial posterior m.
  - d) **neurovascular bundle lies between the tendons of flexor digitorum longus and flexor hallucis longus mm.**
  - e) posterior from the tendon of the posterior tibial m. is situated the tendon of the flexor hallucis longus m.
- 
6. Which of the following answers are correct:
    - a) **under the superior fibular retinaculum the fibular mm. are situated in a common osteofibrous sheath**
    - b) **by the inferior fibular retinaculum the fibular mm. have separate osteofibrous sheath**

- c) fibular mm. have a separate osteofibrous sheath through the whole length
  - d) fibular mm. have a common osteofibrous sheath through the whole length
  - e) there is no superior and inferior fibular retinaculum, there is just one retinaculum
7. In the subcutaneous tissue of the lateral malleolar region can be found:
- a) **small saphenous v.**
  - b) **sural n.**
  - c) great saphenous v.
  - d) deep fibular n.
  - e) tibial n.
8. Which are the ligaments of the talocrural joint:
- a) **medial deltoid lig.**
  - b) **calcaneofibular lig.**
  - c) tendon of Achille
  - d) **anterior talofibular lig.**
  - e) **posterior talofibular lig.**
9. The sintopy of anatomical elements in medial maleolar canal from tibial posterior m. to posterior is:
- a) **tendon of flexor digitorum longus m.**
  - b) **tendon of flexor halucis longus m is the most posterior**
  - c) **neurovascular bundle is located between tendons of flexor halucis longus m. and flexor digitorum longus m.**
  - d) neurovascular bundle is located posterior than medial malleolus
  - e) tendon of flexor halucis longus is located more posterior than tendon of tibial posteior m.

## FOOT REGION

- Projection of the dorsal neurovascular bundle of the foot is the following line:
  - head of the I metatarsian bone
  - head of the II metatarsian bone
  - the II interdigital space
  - the middle of the bimalleolus distance**
  - the I interdigital space**
- In the subcutaneous tissue of the dorsal region of the foot can be found:
  - dorsal venous network**
  - dorsalis pedis a.
  - superficial fibular n.**
  - sural and saphenous nn.**
  - fibular a
- The following structures are situated under the proper fascia of the dorsal region of the foot:
  - extensor digitorum brevis m.**
  - extensor hallucis brevis m.**
  - dorsalis pedis a. and deep fibular n.**
  - anterior tibial m.
  - superficial fibular n.
- Branches of dorsalis pedis artery are:
  - arcuat a.**
  - deep plantaris branch**
  - medialis et lateralis tarsea aa.**
  - lateral plantar a.
  - medialis plantar a.
- Between which two structures is placed a. dorsalis pedis?
  - tendon of the tibial anterior muscle
  - tendon of m. extensor hallucis longus**
  - extensor hallucis brevis m.
  - tendons of extensor digitorum longus m.**
  - extensor digitorum brevis m.
- The deep fibular nerv enervates:
  - skin of the IV interdigital space
  - skin of the I interdigital space**
  - skin of the medial malleolar region
  - extensor digitorum brevis m.**
  - flexor mm.
- What muscles are situated in the medial fascial sheath of the foot:
  - flexor digitorum brevis m.**
  - quadratus plantae m.**
  - adductor halucis m.**
  - abductor halucis m.
  - lumbrical mm.**
- What anatomical structures are situated in the medial fascial sheath of the foot:
  - flexor halucis brevis m.**
  - abductor halucis m.**
  - tendon of the flexor halucis longus m.**
  - tendon of the flexor digitorum longus m.
  - tendon of the posterior tibial m.
- In the lateral fascial sheath of the foot are:
  - abductor digiti minimi m.**
  - flexor digitorum brevis m.
  - flexor digiti minimi m.**



- d) quadratus plantae m.  
e) lumbrical mm.
10. The walls of the plantar canal are:  
a) **medial and lateral intermuscular septums**  
b) **long plantar lig.**  
c) **deep fascia of the foot**  
d) superficial fascia of the foot  
e) quadratus plantae m.
11. The plantar canal contains:  
a) **quadratus plantae m.**  
b) flexor halucis brevis m.  
c) **tendons of the flexor hallucis and digiti longus mm.**  
d) **lateral and medial neurovascular bundles**  
e) flexor digitorum brevis m.
12. Boundaries of the calcaneus canal are:  
a) **calcaneus bone**  
b) **abductor halucis m.**  
c) adductor halucis m.  
d) quadratus plantae m.  
e) flexor halucis brevis m.
13. In the calcaneus canal are situated:  
a) **medial neurovascular bundle**  
b) **tendon of the flexor digitorum longus m.**  
c) tendon of the long fibular m.  
d) **tendon of the flexor halucis longus m.**  
e) tendon of the posterior tibial m.
14. The medial plantar nerve enervates the following structures:  
a) **flexor of I toe and digitorum brevis mm.**  
b) adductor halucis m.  
c) **2 medial lumbrical mm.**  
d) 2 lateral lumbrical mm.  
e) **the skin of the internal part of the I, II, III and IV toes**
15. The structures enervated by the lateral plantar nerve are:  
a) **5<sup>th</sup> toe mm. , quadratus plantae m.**  
b) **adductor halucis m.**  
c) **2 lateral lumbrical mm. and interosseus mm.**  
d) **extern part of the skin of the 5<sup>th</sup> and 4<sup>th</sup> toes**  
e) flexor digitorum brevis m.
16. Where do the tendons of the long extensor muscles insert on the dorsal part of the toes:  
a) **lateral portions - at the base of distal phalanges**  
b) **medial portions - at the base of medial phalanges**  
c) lateral portions - at the base of proximal phalanges  
d) medial portions - at the base of distal phalanges  
e) all portions are inserted at the base of distal phalanges
17. Find the correct answers:  
a) **tendons of the flexors from the toes region are united in osteofibrous canals**  
b) **tendons of the flexors have synovial sheaths**  
c) **synovial sheaths of the flexors begin from the metatarsal bones**  
d) synovial sheaths begin from the calcaneus bone  
e) **synovial sheaths of the flexors finish at the base of distal phalanges**
18. Joint of Chopart is formed by:  
a) the head of metatarsal bones  
b) base of proximal phalanx

- c) **cuboid bone**
- d) **astragalus (talus) and calcaneus**
- e) **navicular bone**

19. Tarsometatarsal joint of Lisfranc is formed by:

- a) head of metatarsal bones
- b) base of proximal phalanx
- c) **cuboid and three cuneiform bones**
- d) **base of metatarsal bones**
- e) astragalus (talus) and calcaneus bones

20. Which of the following statements concerning the pus spreading from the plant medial lodge are correct:

- a) **in posterior leg lodge through calcaneal channel and medial malleolar**
- b) **in plant medial lodge on the path of tendon the long flexor hallucis m**
- c) **in the interdigital spaces in the path of lumbrical mm.**
- d) **in the back of the foot on path deep plantar a.**
- e) in the the lateral lodge of plant on the path of the short flexor m. of the fingers

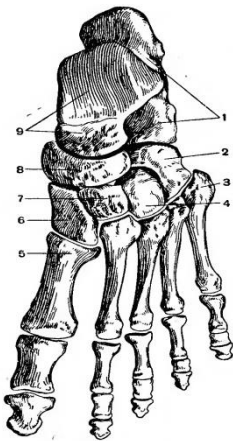
21. Which of the following statements about the topography of the medial portion of the plant are correct:

- a) muscles are disposed in three layers
- b) **muscles are arranged in four layers**
- c) **there are two cellular tissue spaces between the 1-2 layer and 2-3 layer of muscle**
- d) **the third layer of muscles is represented by the adductor halucis muscle and the tendon fibularis longus muscle.**
- e) **the first layer is represented by the short flexor of the fingers muscle**

22. Indicate the place of pulse palpation for dorsalis pedis artery.

- a) posterior to the medial malleolus
- b) anterior the lateral malleolus
- c) **between 1st and 2nd metatarsal bones**
- d) between the 3rd and 4th metatarsal bones
- e) in the midway of the intermalleolare distance

23. Indicate the correct order of plantar bones:



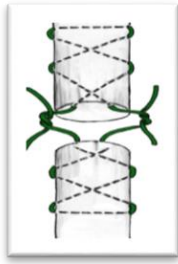
- a) **1 – calcaneu bone; 2 – cuboideu bone; 3 – the V metatarsal bone; 4, 6, 7 – cuneiform bones; 5 – the first metatarsal bone; 8 – navicular bone; 9 – talus bone**
- b) 1 – cuboideu bone; 2 – calcaneu bone; 3 – the V metatarsal bone; 4, 6, 7 – cuneiform bones; 5 – the first metatarsal bone; 8 – navicular bone; 9 – talus bone
- c) 1 – calcaneu bone; 2 – cuboideu bone; 3 – navicular bone; 4, 6, 7 – cuneiform bones; 5 – the first metatarsal bone; 8 – the V metatarsal bone; 9 – talus bone
- d) 1 – talus bone; 2 – cuboideu bone; 3 – the V metatarsal bone; 4, 6, 7 – cuneiform bones; 5 – the first metatarsal bone; 8 – navicular bone; 9 – calcaneu bone
- e) 1 – calcaneu bone; 2 – talus bone; 3 – the V metatarsal bone; 4, 6, 7 – cuneiform bones; 5 – the first metatarsal bone; 8 – navicular bone; 9 – cuboideu bone

## UPPER LIMB SURGERIES

1. A patient suffered an accident in which his thumb on his right hand was amputated at the base of the proximal phalanx. He was immediately transported to the hospital. The finger was hanging on a thin strip of skin. Determine surgeon's tactic:
  - a) stump formation at the level of proximal phalanx, because the blood circulation is poor
  - b) phalangization of the I metacarpal bone, in order to ensure a better gripping function of the hand
  - c) **replantation of the finger using microsurgical techniques.**
  - d) postponed surgical treatment, to determine the limits of devitalized tissues
  - e) transposition and reimplantation of a toe
  
2. Vascular suture techniques stipulates:
  - a) suturing only the adventitia of the vessel
  - b) **suturing all the layers of the vessel**
  - c) suturing the adventitia and circular muscular layer
  - d) only muscular layer
  - e) none of the above answers is correct
  
3. In the case of commissural phlegmon the incision will be performed:
  - a) in the carpal region
  - b) in the hypothenar region
  - c) in the thenar region
  - d) **in the region of the palmar pads**
  - e) in the projections of interdigital spaces
  
4. The surgical approach to subclavian artery:
  - a) Billroth access
  - b) **transclavicular access**
  - c) supraclavicular access
  - d) Martánov access
  - e) Jobert access
  
5. Continuous vascular suture, in which 3 equidistant stay sutures are placed, bears the name of the author:
  - a) **Carell**
  - b) Poleantsev
  - c) Jabuly-Gross
  - d) Blalock
  - e) Djanelidze
  
6. Which of the following statements are wrong:
  - a) "Bypass" is surgical rerouting of blood flow around an obstructed artery
  - b) trombembolectomy may be direct or indirect
  - c) **permutation of the nerve aims reinnervation of the muscles deprived of innervation after a nerve injury**
  - d) Clapp method is practiced in case of varicose veins
  - e) **Madelung procedure is practiced in arterial thrombosis**
  
7. Nerve plasty represents:
  - a) neurolysis
  - b) neurorrhaphy
  - c) **restoring the continuity of a damaged nerve with autogenous nerve grafts**
  - d) epineural suture application
  - e) nerve permutation
  
8. Brachial plexus blockade is performed using the:
  - a) Krukenberg procedure
  - b) Oberst-Lukashevici procedure
  - c) Braun-Usołițeva procedure
  - d) **Kulenpkampf procedure**
  - e) Madelung procedure
  
9. Digital nerve anesthesia procedure, in which the anesthetic solution is introduced at the level of proximal phalanx of the finger is called:
  - a) Krukenberg procedure

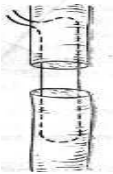
- b) **Oberst-Lukashevici** procedure
  - c) Madelung procedure
  - d) Braun-Usoļiņeva procedure
  - e) Kulenkampf procedure
10. Anesthesia procedure which consists of administering the anesthetic solution between the dorsal metacarpal bones of the hand is called:
- a) Krukenberg procedure
  - b) Madelung procedure
  - c) Oberst-Lukashevici procedure
  - d) **Braun-Usoļiņeva** procedure
  - e) Kulenkampf procedure
11. Which of the following statements do not refer to vicious stump?
- a) phantom pain
  - b) conical stump
  - c) **stump of the leg is 8 cm length**
  - d) stump ulcer
  - e) **primary prosthesis**
12. Which of the following statements do refers to the vicious stump
- a) **phantom pain**
  - b) **conical stump**
  - c) stump of the leg with a length of 8 cm
  - d) **the stump ulcer**
  - e) primary prosthesis
13. Autotransplantation is transplantation of organs, tissues from one part of the body to another in:
- a) **the same person**
  - b) identical “monozygotic “ twins
  - c) representatives of the same species
  - d) first degree relatives
  - e) second degree relatives
14. Allotransplants is the transplantation of cells, tissues, or organs, to
- a) representatives of different species
  - b) identical “monozygotic “ twins
  - c) **representatives of the same species**
  - d) first degree relatives
  - e) brothers, sisters
15. Xenotransplantation is transplantation of living cells, tissues or organs from one species to:
- a) **representatives of different species**
  - b) identical “monozygotic “ twins
  - c) representatives of the same species
  - d) first degree relatives
  - e) brothers
16. Isogenic transplantation is transplantation of living cells, tissues or organs to
- a) representatives of different species
  - b) **identical “monozygotic “ twins**
  - c) representatives of the same species
  - d) first degree relatives
  - e) second degree relatives
17. Syngenic transplantation is transplantation of living cells, tissues or organs to
- a) representatives of different species
  - b) identical “monozygotic “ twins
  - c) representatives of the same species
  - d) **first degree relatives**
  - e) second degree relatives
18. Explantation is transplantation:

- a) from human to human
  - b) from animals to humans
  - c) of inorganic material**
  - d) from first degree relatives
  - e) none of the above are correct
19. If the graft tissue keeps connection with it's origin, this kind of plasty is:
- a) free
  - b) pediculate**
  - c) dissociated
  - d) combined
  - e) composed
20. Vascularized graft may be used for:
- a) substitution of the amputated finger
  - b) inguinal canal plasty
  - c) covering the defects of the foot and hand**
  - d) covering the defects of the facial and neck region**
  - e) all of the above
21. Dissociated skin graft represent:
- a) superficial layer of the epidermis
  - b) the epidermis**
  - c) a portion from dermis**
  - d) integral dermis
  - e) dermis with a thin layer of adipose tissue
22. Cutaneous brefoplasty is transplantation of:
- a) autodermal tissue
  - b) embryonic dermis**
  - c) derma from identical twins
  - d) derma from first degree relatives
  - e) derma taken from another being
23. Replanting is:
- a) repeated transplantation
  - b) transplanting of an organ into another region
  - c) transplantation in the initial region**
  - d) restoring of the damaged organ
  - e) there is no correct answer
24. Accepted methods for preservation of tissues for transplantation are:
- a) cryopreservation**
  - b) lyophilization**
  - c) formaldehyde solution**
  - d) hypertonic solution of NaCl
  - e) pure alcohol
25. Which are the acceptable terms for collecting the cadaver bone tissue:
- a) 4 hours**
  - b) 6 hours**
  - c) 12 hours**
  - d) 24 hours
  - e) 36 hours
26. What are unacceptable terms for collecting cadaver bone tissue after death
- a) 4 hours
  - b) 6 hours
  - c) 12 hours
  - d) 44 hours**
  - e) 36 hours**
27. The drawing represents suturing the tendon after one of the authors listed below:



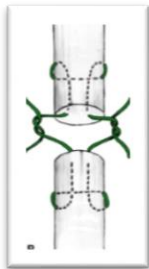
- a) Langhe
- b) Cuneo**
- c) Bunnell
- d) Rozova
- e) Martonov

28. The drawing represents suturing the tendon after one of the authors listed below:



- a) Langhe**
- b) Cuneo
- c) Bunnell
- d) Rozova
- e) Martonov

29. The drawing represents suturing the tendon after one of the authors listed below:



- a) Langhe
- b) Cuneo
- c) Bunnell
- d) Kessler**
- e) Martonov

30. During amputation, the muscles are:

- a) sectioned below the level of sectioned bone**
- b) sectioned above the level of sectioned bone
- c) sectioned in scale
- d) antagonists muscles are sutured together to cover the bone stump.**
- e) are sutured at the level of bone stump without cover it

31. During anterior arthrotomy of the shoulder joint, the following anatomical structures are sectioned:

- a) articular capsule**
- b) deltoid muscle
- c) long head sheath of biceps brachii muscle**
- d) short head sheath of biceps brachii muscle
- e) long head sheath of triceps brachii muscle

32. Which surgical approach is more frequently used to get access to the surgical neck of the humerus?

- a) deltopectoralis anterior
- b) transdeltoidian**
- c) posterior
- d) superior with sectioning the acromion

- e) transacromial
33. Which surgical approach is more frequently used to get access to the diaphysis of humerus?  
 a) medial  
 b) transdeltoidian  
 c) **antero-lateral**  
 d) anterior  
 e) combined
34. Purulent collections from deep subpectoral cellular space may spread into the axillary cavity along the trajectory:  
 a) coracohumeral ligament  
 b) **suspensory ligament of axilla**  
 c) **vessels and nerves that enter in this space from the axillary cavity**  
 d) thoracoacromial artery  
 e) all answers are correct
35. After performing an incision on the posterior margin of the deltoid muscle for a subdeltoidian phlegmon, the patient was unable to abduct his arm. What nerve was injured during the surgery?  
 a) brachial plexus  
 b) suprascapular nerve and the long tendon of triceps muscle  
 c) **axillary nerve**  
 d) musculocutaneous nerve  
 e) radial nerve
36. Which structures may be injured in case of surgical neck fracture of the humerus?  
 a) long tendon of the biceps muscle  
 b) **posterior circumflex humeral artery**  
 c) **axillary nerve**  
 d) radial nerve  
 e) only axillary nerve
37. Shoulder dislocation can occur more often in case of absence or underdevelopment of which ligament?  
 a) coracohumeral ligament  
 b) coracoacromial ligament  
 c) long tendon of the biceps  
 d) **median glenohumeral ligament**  
 e) superior glenohumeral ligament
38. The projection line of the axillary artery is drawn between:  
 a) **between anterior and median third of axillary fossa**  
 b) on inferior margin of pectoral major muscle  
 c) **it corresponds to projection of coracobrachial muscle**  
 d) the middle of the distance between pectoralis major muscle and latissimus dorsi  
 e) **anterior margin of axillary hair**
39. Which of the statements below are true?  
 a) **the radial nerve may be injured in case of the fracture of middle 1/3 of humerus**  
 b) **radial nerve passes through humeromuscular canal**  
 c) ligation of brachial artery is better to perform proximally to deep artery of the arm  
 d) **ulnar nerve, in distal 1/3 of the arm, is situated in the posterior compartment**  
 e) radial nerve divides in the middle 1/3 of the forearm
40. In case of humerus fracture proximally to the insertion of deltoid muscle:  
 a) the proximal end of the humerus rotates externally due to infraspinatus and teres minor muscles contraction  
 b) proximal end of the humerus is displaced antero-laterally due to supraspinatus and deltoid muscles contraction  
 c) **proximal end of the humerus is displaced medially due to teres major, teres minor and greater pectoral muscles contraction**  
 d) **distal end is displaced laterally and superiorly due to deltoid muscle contraction**  
 e) distal end of the humerus is displaced posteriorly due to biceps muscle contraction
41. In case of humerus fracture distally to the insertion of deltoid muscle:

- a) the proximal end of the humerus rotates externally due to infraspinatus and teres minor muscles contraction
  - b) proximal end of the humerus is displaced antero-laterally due to supraspinatus and deltoid muscles contraction**
  - c) proximal end of the humerus is displaced medially due to teres major, teres minor and greater pectoral muscles contraction
  - d) distal end is displaced laterally and superiorly due to deltoid muscle contraction
  - e) distal end of the humerus is displaced posteriorly due to biceps muscle contraction**
42. The ulnar neurovascular bundle is projected on a line that connects:
- a) long tendon of biceps brachii muscle
  - b) styloid process of the ulna
  - c) medial epicondyle of the humerus**
  - d) external margin of the pisiform bone**
  - e) the middle of the olecranon
43. Supinator canal syndrome is manifested by:
- a) reduced sensitivity on the antero-lateral region of the forearm
  - b) reduced sensitivity on the posterior region of the forearm
  - c) weakness of wrist and fingers extension**
  - d) inability to flex the wrist and fingers
  - e) ischemia of the tissues on the posterior region of the forearm
44. The projection line of the radial neurovascular bundle is drawn between (Pirogov line):
- a) tendon of biceps brachii muscle
  - b) the middle of the cubital fold**
  - c) styloid process of the radius**
  - d) lateral epicondyle of the humerus
  - e) scaphoid bone
- 45.** The projection line of the median nerve is drawn between:
- a) tendon of the biceps brachii muscle
  - b) middle of the cubital fold**
  - c) middle of line between styloid processes of the radius and ulna
  - d) medial epicondyle of the humerus
  - e) the middle of the line between flexor carpi radialis muscle and palmaris longus**
46. The projection line of the radial nerve is drawn between:
- a) posterior margin of the deltoid muscle**
  - b) distal 1/3 of the lateral bicipital groove**
  - c) greater tubercle of humerus
  - d) lateral epicondyle of the humerus
  - e) distal 1/3 of the medial bicipital groove
47. The projection line of the brachial artery:
- a) greater tubercle of the humerus
  - b) medial epicondyle of the humerus
  - c) coracoid process
  - d) it corresponds to medial bicipital groove**
  - e) the middle of the line between medial epicondyle of the humerus and the tendon of biceps brachii muscle
48. Mark the possible ways of spreading of the pus from the subaponeurotic space of the mesothelar fascial compartment of the hand:
- f) along neurovascular bundles of the fingers to the subcutaneous tissues of the fingers**
  - g) along the deep branch of the ulnar nerve and artery into subtendinous space**
  - h) on the way of the carpal canal to the forearm**
  - i) along the lumbrical muscles to the dorsal region of the hand**
  - j) along the deep palmar arch to the dorsal part of the hand
49. Median nerve compression syndrome in the carpal region is determined by:
- f) localisation of the nerve among dense fibrous structures with low stretchability**
  - g) complete injury of the median nerve
  - h) limitrophe localization of the pisiform bone
  - i) thickening of the palmar carpal ligament**



- j) thickness of the median nerve
50. A patient was admitted to the doctor with a right hand trauma. During examination, edema and pain are revealed at palpation in the "anatomic snuffbox". A bone fracture is suspected. Which bone could it be?
- f) trapezium bone
  - g) scaphoid bone**
  - h) trapezoid bone
  - i) lunate bone
  - j) pisiform bone
51. A patient has tenosynovitis of the II finger. By the 4<sup>th</sup> day from the onset of the disease, necrosis of the tendon of the flexor digitorum profundus muscle was revealed. What might be the cause of the necrosis of the tendon?
- f) compression of the digital arteries due to the liquid that accumulates in the synovial sheath
  - g) compression of the mesotenon by the liquid accumulated in the synovial sheath**
  - h) compression of the tendon by the liquid accumulated in the synovial sheath
  - i) compression of the digital muscles
  - j) none of the above
52. What kind of incisions are performed in case of tenosynovitis of the second finger of the hand:
- a) parallel incisions, from the center of the distal phalanx till the head of the metacarpal bone
  - b) parallel separate incisions on the lateral sides of proximal and middle phalanges**
  - c) parallel incisions on the lateral sides of proximal, middle and distal phalanges
  - d) cruciform incisions on the proximal, middle and distal phalanges
  - e) cruciform incisions on the distal phalanx
53. Pus from the synovial sheath of the little finger may spread to:
- f) subcutaneous fatty tissue of the distal phalanx
  - g) Paron-Pirogov cellular space through mesothenar compartment and carpal tunnel**
  - h) mesothenar compartment**
  - i) along the lumbrical mm. to dorsum of the hand**
  - j) dorsal region of the forearm
54. In case of tenosynovitis of the fifth finger, the incisions are performed:
- a) parallel incisions, from the center of the distal phalanx till the head of 2<sup>nd</sup> metacarpal bone
  - b) parallel separate incisions on lateral sides of proximal and middle phalanges**
  - c) mesothenar compartment, on the line that bounds the hypothenar**
  - d) in the distal 1/3 of the forearm, medially to the tendon of flexor carpi ulnaris muscle**
  - e) cruciform incisions on the proximal, middle and distal phalanges

## OPERATIONS ON LEG

1. During amputations, magisterial vessels are isolated, ligated and sectioned. How many ligatures are applied on isolated artery and vein?
  - a) a double bond into a vein
  - b) two bonds on vein: one proximal and one distal**
  - c) three ligatures on artery: two proximal (one sutured) and a distal**
  - d) a proximal vein ligation (sutured)
  - e) three ligatures on artery: one proximal (sutured) and two distal
2. During surgery, after a road accident, was determined the crush of femoral artery in the medial 1/3 of the thigh, on a length of 12 cm. Pulsation on a. Popliteal is missing. What could be the method of revascularisation:
  - a) Ligation of femoral artery, the classic method, by applying two ligatures on the proximal end and one distal. Vascularization and blood flow of the distal portion will be established by arterial collaterals;
  - b) plasty of injured vessel with venous autograft;**
  - c) plasty of injured vessel with a autograft from profunda femoral artery of the healthy limb;
  - d) amputation of the member because it can lead to gangrene of the member,
  - e) plasty of injured vessel with a vascular prosthesis.**
3. Surgical approach over a. Poplitea is more convenient to be performed by the following access:
  - a) popliteal;
  - b) fosa Jobert;**
  - c) lateral access;
  - d) transarticular
  - e) transligamentar
4. The discovery of n. Peroneal profundus in the medial 1/3 of the leg is performed by opening the following lodge:
  - a) anterior;**
  - b) posterior;
  - c) lateral;
  - d) do not open any facial lodge because the nerve is located anterior the tibial bone
  - e) open all lodges, as the nerve has an oblique trajectory.
5. For the plasty of femoral artery is more rational to use an autograft from :
  - a) the femoral vein;
  - b) the great saphenous vein;**
  - c) the basilic vein;
  - d) the cephalic vein
  - e) external jugular vein.
6. By the blockage of the Femoral n. we achieve anesthesia of following regions:
  - a) thigh and perineum;
  - b) anterior region of the thigh,**
  - c) anterior region of the knee and lower leg;**
  - d) entire thigh and the inguinal region of the abdominal wall;
  - e) posterior thigh and gluteal region
7. A bone resection is:
  - a) cutting the bone in case of vicious consolidation;
  - b) clinching bone fragments;
  - c) replacing a portion of bone to another;
  - d) removing a portion of bone**
  - e) transplantation of a portion of bone.
8. Osteosynthesis represents:
  - a) plasty of the bone defect;
  - b) reduction of bone fragments;
  - c) the surgical reduction and fixation of bone fragments;**
  - d) applying gypsum for fractures
  - e) filling the defect.
9. Joint resection is:

- a) stiff joints;
- b) removing a portion of the joint;**
- c) intraarticular adhesions cutting;
- d) providing a process for limiting the movements of a joint
- e) the grafting of the joint.

10. Arthrodesis is:

- a) stiff joints;**
- b) removing a portion of the joint;
- c) intraarticular adhesions sectioning;
- d) providing a process for limiting the movements in the joint;
- e) plasty of the joint.

11. Artroriza is:

- a) stiff joints;
- b) removing a portion of the joint;
- c) intraarticular adhesions sectioning;
- d) providing a process for limiting the movements of a joint**
- e) plasty of the joint.

12. Artroliza is the process by which:

- a) stiff joints;
- b) a portion of the joint is removed
- c) intraarticular adhesions are sectioned**
- d) a process for limiting the movements in the joint is provided
- e) plasty of the joint is performed.

13. Arthroplasty includes:

- a) stiff joints;
- b) restoring the joint,**
- c) intraarticular adhesions sectioning;
- d) providing a process for limiting the movements of a joint
- e) plasty of the joint.**

14. Tendoliza is surgery which includes:

- a) suturing the injured tendon;
- b) releasing the tendon of its own fascia
- c) releasing the tendon from adhesions / scars;**
- d) tendon plasty
- e) tendon injury.

15. Leg amputation includes the following basic steps:

- a) sectioning soft tissues;**
- b) processing vessels and nerves;**
- c) bone stump sectioning and processing;**
- d) sectioning muscles and tendons;
- e) forming the stump.

16. Dacă lungimea circumferenței la nivelul secționării osului este de 60 cm, care ar fi lungimea necesară, sumată a lambourilor, luând în considerație retractorii pielii și știind că  $L$  (lungimea circumferinței) =  $2\pi r$  ( $\pi = 3,14$ ). Clasificarea amputațiilor în funcție de termenii execuției:

- a) 20cm, amputația primară de urgență;**
- b) 30cm, amputație secundară;**
- c) 40cm, în doi timpi;
- d) 50cm, amputație tardivă (planificată);**
- e) 60cm, amputație repetată (reamputație).**

17. The surgery in case of leg varicose which includes removal of great saphenous vein is called:

- a) Troianov method;
- b) Beacock method;**
- c) Clapp method;
- d) Sokolov method;
- e) Madelung method;.

18. What's internal ring portion of the femoral canal could be cut to widen the gates ofstrangulated femoral hernia?  
a) posterior;  
**b) anterior;**  
**c) medial;**  
d) lateral  
e) posterior and medial.
19. What recess of the knee joint is scored more frequently to remove the fluid:  
a) superior anterior medial;  
b) superior anterior lateral;  
c) inferior anterior medial;  
**d) suprapatellar**  
e) inferior anterior lateral.
20. Opening and draining a rear leg phlegmon is made by the following incision:  
a) on the medial edge of the tibia, 2-3 cm external  
b) on the lateral edge of the tibia, 2-3 cm external  
**c) on the medial edge of the tibia, 2-3 cm posterior**  
d) on the projection line of the rear neurovascular bundle  
e) two incisions on the contralateral edges of the tibia
21. From the listed below select which is the projection line of the brachial artery:  
**a) the line connecting the apex of axillary fossa with the midway between the biceps tendon and the medial epicondyle**  
b) the line connecting the apex of axillary fossa with the midway between the biceps tendon and the lateral epicondyle  
c) the line connecting the apex of axillary fossa with the biceps tendon  
d) the line connecting the apex of axillary fossa with the middle of cubital plica cubital  
e) ) the line connecting the apex of axillary cavity with the midway between the biceps tendon and the medial epicondyle
22. From the listed below select which is the projection line of the radial artery:  
**a) the line connecting the middle of cubital plica with the pulsatile point of the radial artery**  
b) the line connecting the middle of cubital plica with the styloid process of the radius  
**c) the line connecting the middle edge of the biceps tendon with the pulsatile point of the radial artery**  
d) the line connecting the middle of cubital plica with the styloid process of the ulna  
e) the line connecting the middle of cubital plica with middle of line drawn between the styloid processes
23. From the listed below select which is the projection line of the femoral artery:  
**a) the line connecting the middle of inguinal fold with the medial epicondyle**  
**b) hip flexed and rotated externally**  
c) the line connecting the medial 1/3 of inguinal fold with the medial epicondyle  
d) thigh flexed in the hip joint  
e) the line corresponding to the projection of the tailor muscle
24. The laws regarding the neurovascular packages of the extremities are:  
**a) magisterial vessels and nerves are located in fascial sheaths**  
b) fascial sheaths walls are made of superficial fascia  
**c) fascial sheaths walls are made up of deep fascia**  
**d) fascial sheaths section have triangular shape with the base oriented external and the appex oriented internal and fixed to the bone**  
e) fascial sheaths section have triangular shape with the base oriented internal and fixed to the bone and the appex oriented external
25. Vascular suturing requirements are:  
**a) the edges of the vessel are joined to the suture line with intima**  
**b) rhe suture must not damage endothelium**  
**c) suture must not decrease the vessel lumen and has to be tight**  
d) mechanical suture is the "gold standard"  
**e) suture material must not be placed in the lumen of the vessel**

26. The surgical method that provides ligation and dissection of the great saphenous vein and saphenous tributaries at the orifice is:
- Troianov-Trendelenburg method;**
  - Bebcock method;
  - Clapp method;
  - Sokolov method
  - Madelung method.
27. The steps in vein cannulation are:
- vein puncture (syringe + needle)**
  - removing the syringe**
  - introducing a conductor through the lumen of the needle**
  - extracting the needle and catheter fixation**
  - removal of the catheter and the needle fixing
28. Of those mentioned below, which refers to intervention on the nerves:
- neurolysis and neurotomy**
  - nerve suture (neurorrhaphy)**
  - neuroma resection**
  - operations on nerve defects (neuroplastic)**
  - electrocoagulation of the nerve
29. What are the stages in operation on nerves:
- discovering the nerve and neurolysis**
  - assessing limits for resection and nerve mobilization**
  - resection of the damaged sector and neurorrhaphy**
  - subneural suture
  - wound suture and limb immobilization**
30. What is sympathectomy?
- motor nerve resection
  - sensory nerve resection
  - resection of a nerve, sympathetic ganglion**
  - neuroma resection
  - nerve transection in limb amputation
31. Sympathectomy aims:
- influence upon sympathetic innervation**
  - influence upon parasympathetic innervation
  - interruption of inappropriate centripetal impulse**
  - interruption of inappropriate centrifugal impulse**
  - removal of vascular spasm and increase of collateral circulation**
32. Tenorafia is surgery which includes:
- injured tendon suturing**
  - own fascia tendon release;
  - releasing the tendon from adhesions / scars;
  - tendon plasty
  - tendon injury.
33. Tenotomy is surgery which includes:
- injured tendon suturing
  - own fascia tendon release;
  - releasing the tendon from adhesions / scars;
  - tendon plasty
  - transection of the tendon**
34. Tenodeza is surgery which includes:
- injured tendon suturing
  - own fascia tendon release;
  - releasing the tendon from adhesions / scars;
  - limitation of joint motion of a segment in a convenient functional position**
  - transection of the tendon and tendon plasty

35. Name the amputations basic methods:

- a) **guillotine amputation**
- b) **typical amputation**
- c) **osteoplastic amputation**
- d) oblique amputation
- e) perpendicular amputation

36. Note the types of amputations after the transaction form of soft tissue

- a) **guillotine amputation**
- b) **amputation in a moment**
- c) **amputation in two moments**
- d) **amputation in three moments**
- e) amputation in four moments

37. What is guillotine amputation?

- a) **amputation of all structures in a single plane**
- b) amputation of all structures in two planes
- c) amputation of all structures in three planes
- d) amputation when bone fragments are used in the formation of the stump
- e) amputation which provides circular incision of the skin and fascia

38. What is amputation in two steps:

- a) **when the skin, muscles and bone is sectioned at different levels**
- b) the skin and muscles are cutted in the same plane
- c) the bone and muscles are cutted in the same plane
- d) bone transection plane corresponds to the skin
- e) when the skin, muscles and bone is sectioned in the same plane

39. Conical-circular amputation steps are:

- a) **incision of the skin, subcutaneous tissue and fascia**
- b) **cut superficial muscles at the level of the skin retracted**
- c) **retract the skin and cut deep muscles**
- d) **On the edge of the retracted muscles we cut the bone**
- e) at the retracted edge we cut the bone

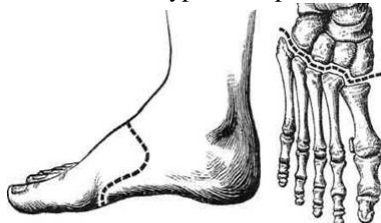
40. What is amputation in one time?

- a) **technique provides circular incision of the skin subcutaneous tissue and fascia**
- b) skin and muscles are sectioned in the same plane
- c) **On the edge of the retracted skin we cut the muscles and the bone**
- d) bone transection plane corresponds to the skin
- e) when the skin, muscles and bone is sectioned in the same plane

41. Note the bone stump processing methods

- a) **aperiosteal**
- b) epiperiosteal
- c) **subperiosteal**
- d) periosteal
- e) periosto – periosteal

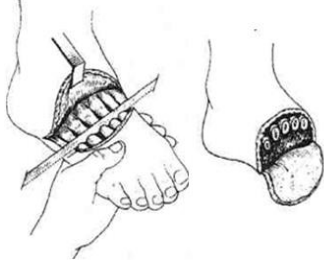
42. What type of amputation is represented in the drawing schem?



- a) **Lisfranc type amputation**
- b) Sharp type amputation
- c) Pirogov type amputation
- d) Shopar type amputation

e) Farabef type amputation

43. What type of amputation is represented in the drawing schem?

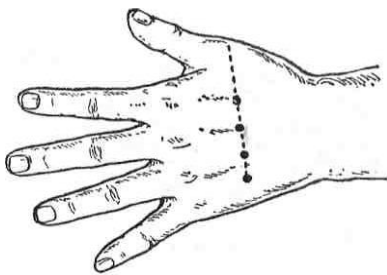


- a) Lisfranc type amputation
- b) Sharp type amputation**
- c) Pirogov type amputation
- d) Shopar type amputation
- e) Farabef type amputation

44. What type of anesthesia is represented in the drawing scheme?

- a) anesthesia by Oberst-Lukashevici**
- b) anesthesia by Braun-Usoltsev
- c) anesthesia by Vishnevski
- d) intraosseous anesthesia
- e) subcutaneous anesthesia

45. What type of anesthesia is represented in the drawing scheme?



- a) anesthesia by Oberst-Lukashevici
- b) anesthesia by Braun-Usoltsev**
- c) anesthesia by Vishnevski
- d) intraosseous anesthesia
- e) subcutaneous anesthesia

## HEAD

- Why the incisions on the face are made in radial direction:
  - to obtain a broader approach
  - not to injure the branches of the trigeminal nerve
  - not to injure mimic muscles
  - not to injure the branches of the facial a. and v.
  - to avoid the injure of the branches of the facial n.**
- What type of hematoma is formed in case of injury of medial meningeal artery:
  - epydural**
  - subdural
  - subarahnoidal
  - subpial
  - intracerebral
- Why bleeding in the case of epicraniene tissue damage is abundant?
  - epicranial vessels are located above cranial aponeurosis**
  - external tunic of vessels is intimately attached to the vertical fibrous septums**
  - epicranial vessels are located under the cranial aponeurosis
  - epicranial vessels do not collapses**
  - intima of vessels is lax fixed by the vertical fibrous septums
- The posterior auricular nerv is branch of which nerve:
  - trigeminal n.
  - facial n.**
  - trochlear n.
  - oculomotor n.
  - zigomatic n.
- Sides of the Chipaut's triangle of trepanation are:
  - a line traced from spina suprameatum to the top of mastoid process**
  - projection line of facial canal
  - a line that represents continuing the zygomatic arch on the mastoid process**
  - sigmoid sinus
  - anterior border of mastoid crest**
- Sides of attack quadrangle are:
  - the posterior side is a bisector of trepanation triangle**
  - the inferior horizontal is a line parallel to superior through external acoustic pore**
  - superior horizontal line is a continuation of the zygomatic arch on mastoid**
  - anterior side corresponds with the projection of facial nerve canal
  - line between suprameatum spina and the apex of mastoid proces,  $\frac{1}{2}$  superioră**
- Not paying attention to what side in trepanning of mastoid process is possible facial nerve damage?
  - medial side
  - anterior side**
  - posterior side
  - superior side
  - inferior side
- Superior and inferior ophthalmic veins drain into:
  - sinus sagittalis superior
  - sinus cavernosus**
  - sinus sagittalis inferior
  - posterior part of orbit**
  - do not drains
- What anatomical structures pass through the superior orbital fissure?
  - maxillar n.
  - oculomotor and ophtalmic nn.**
  - trochlear and abducens nn.**



- d) **superior ophthalmic vein**  
e) zygomatic n.
10. What passes through oval foramen:  
a) maxillar n.  
b) facial n.  
c) **mandibular n.**  
d) accessory n.  
e) meningeal accessory branch of middle meningeal a.
11. Venous drainage from the cavernous sinus goes to:  
a) **superior petrosal sinus**  
b) transverse sinus  
c) **inferior petrosal sinus**  
d) venous plexus of the carotid canal  
e) sigmoid sinus
12. Great cerebral vein drains into:  
a) sagital sinus  
b) sinuses of the cranial base  
c) **straight sinus**  
d) transverse sinus  
e) occipital sinus
13. What is projected on the middle of zygomatic arch?  
a) central cerebral sulcus of Rolando  
b) **trunk of middle meningeal artery**  
c) anterior cerebral a.  
d) internal carotid a.  
e) lateral cerebral sulcus of Sylvius
14. Facial artery is a branch of the:  
a) **external carotid a.**  
b) internal carotid a.  
c) basilar a.  
d) common carotid a.  
e) maxillary a.
15. Dorsal artery of the nose is a branch of the:  
a) **ophthalmic artery**  
b) angular artery  
c) anterior etmoidal branches  
d) posterior etmoidal branches  
e) terminal branches of superficial temporal artery
16. What passes through the mandibular canal:  
a) mental a.  
b) **inferior alveolar a. and v.**  
c) superior alveolar a.  
d) inferior labial a.  
e) **inferior alveolar n.**
17. Innervation of the face skin is done by:  
a) facial n.  
b) **trigeminal n., terminal branches**  
c) glossopharyngeal n.  
d) **auricular magnus n., anterior branch**  
e) petrosus major n.
18. Facial nerve passes through:  
a) foramen rotundum  
b) foramen spinosum  
c) carotid canal

- d) **facial canal of Falppio**
- e) **stylomastoid foramen**

19. Indicate the terminal branches of the facial nerve after its exit from the stilomastoid foramen:

- a) **temporal branches**
- b) **zygomatic and buccal branches**
- c) **mandibular and cervical marginal branches**
- d) pharyngeal branches
- e) **posterior auricular n.**

20. Where is situated the trigeminal ganglion:

- a) on the posterior surface of the petrous part of the temporal bone between two lamina of dura mater (cavum Meckeli)
- b) in the carotid canal of the petrous part of the temporal bone between two lamina of dura mater (cavum Meckeli)
- c) in the region of the small wings of the sphenoid bone between two lamina of dura mater (cavum Meckeli)
- d) in the region of the big wings of the sphenoid bone between two lamina of dura mater (cavum Meckeli)
- e) **on the superior surface of the petrous part of the temporal bone between two lamina of dura mater (cavum Meckeli)**

21. What regions are innervated by the maxillary nerve:

- a) temporal region
- b) **lateral surface of the nose and cheek**
- c) **superior lip**
- d) **mucous layer of the nasal septum**
- e) **mucous layer of the frontal and maxillary sinuses**

22. What branches start from the maxillary nerve in the pterygopalatine fossa:

- a) **zygomatic nerve**
- b) lachrymal nerve
- c) **superior posterior alveolar branches**
- d) **infraorbital nerve**
- e) deep petrosal nerve

23. What structures are innervated by motor portion of the mandibular nerve?

- a) **mylohyoidian muscle**
- b) **maseter and pterygoid muscles**
- c) posterior belly of the digastricus muscle
- d) **anterior belly of the digastricus muscle**
- e) entire digastricus muscle

24. What structures accompanies the auriculotemporal nerve?

- a) middle meningeal artery
- b) deep temporal artery and vein
- c) **superficial temporal vein**
- d) **superficial temporal artery**
- e) lateral pterygoid muscle

25. Trajectory of the lingual nerve is?

- a) **interpterygoid space**
- b) temporopterygoid space
- c) **submucous space of the buccal floor**
- d) **submandibular triangle**
- e) under the mucous layer of the tongue frenulum

26. Through what orifices the orbit communicates with the cranial cavity?

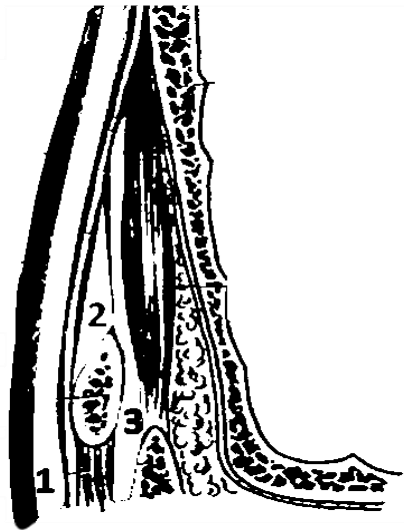
- a) **superior orbital fissure**
- b) inferior orbital fissure
- c) **optic canal**
- d) through sphenoidal sinus
- e) through anterior and posterior ethmoidal holes

27. Superior ophthalmic vein drains into:

- a) pterygoidian venous plexus
  - b) internal jugular vein
  - c) **cavernous sinus**
  - d) sagittal superior sinus
  - e) superior petrosus sinus
28. Lymph from the lips region drains into:
- a) **submandibular lymph nodes**
  - b) **buccinator lymph nodes**
  - c) retroauricular lymph nodes
  - d) **submental lymph nodes**
  - e) supraclavicular lymph nodes
29. What muscle forms the diaphragm of the oral cavity:
- a) genioglossus m.
  - b) hyoglossus m.
  - c) **mylohyoid m.**
  - d) geniohyoid m.
  - e) palatoglossus m.
30. Blood supply of the tongue is provided by:
- a) **lingual a.**
  - b) **descending palatinal a.**
  - c) ascending palatinal a.
  - d) **pharyngeal ascending a.**
  - e) sphenopalatinal a.
31. Lymph from the tongue drains into:
- a) submental lymph nodes
  - b) **submandibular lymph nodes**
  - c) **retropharyngean lymph nodes**
  - d) mastoidian lymph nodes
  - e) **deep cervical lymph nodes**
32. Name the motor nerves for the tongue muscles:
- a) mandibular n.
  - b) **hypoglossal n.**
  - c) glossopharyngian n.
  - d) intermedius n.
  - e) superior laryngeal n.
33. Boundary between head and neck is:
- a) imaginary horizontal line passing through the hyoid bone
  - b) the imaginary line which connects the upper edge of the thyroid cartilage with the superior nuchal line
  - c) **the line passing through the lower edge of the mandible**
  - d) **apex of the mastoid process**
  - e) **occipital superior nuchal line and external occipital protuberance**
34. The boundary between the visceral cranium and the cerebral cranium passes through:
- a) **the upper margin of the orbit, the zygomatic bone and arch, until external acoustic meatus**
  - b) infraorbital margin, zygomatic arch, mastoid apex, external occipital protuberance
  - c) atlas, mastoid apex, zygomatic arch, infraorbital margin
  - d) atlas, mastoid apex, zygomatic arch, supraorbital margin
  - e) atlas, stiloid apex, zigomatic arch, supraorbital margin
35. Boundary between the skull base and vault passes through:
- a) external occipital protuberance, inferior nuchal line, mastoid apex, crista infratemporalis
  - b) **external occipital protuberance, superior nuchal line, base of the mastoid process, crista infratemporalis**
  - c) internal occipital protuberance, inferior temporal line, mastoid apex, crista infratemporalis
  - d) internal occipital protuberance, superior temporal line, base of the mastoid, crista infratemporalis
  - e) internal occipital protuberance, inferior nuchal line, mastoid apex, crista infratemporalis

36. In the cerebral fornix compartment are the following regions:
- frontoparietoccipital region**
  - frontotemporomastoid region
  - temporal region**
  - mastoid region**
  - occipitotemporalis region
37. What fatty tissue spaces include the epycranial layers:
- subcutaneous, subaponeurotic, subperiosteal**
  - intradermal, subcutaneous, subaponeurotic, subperiosteal
  - intradermal, paravascular, subperiosteal
  - intradermal, subcutaneous, subaponeurotic
  - subcutaneous, paravascular, subaponeurotic
38. Galea aponeurotica connects the following muscles:
- frontal m.**
  - temporal m.
  - occipital m.**
  - nucal m.
  - trapezius m.
39. In the temporal region we can find the following fatty tissue layers:
- subcutaneous cellular spaces**
  - interaponeurotic cellular spaces**
  - subaponeurotic cellular spaces**
  - deep cellular spaces**
  - subperiosteal cellular spaces
40. What are the vascular characteristics of the vessels in epicranial tissues:
- the vessels lay above the aponeurose and are present multiple intra and intersystemic anastomosis**
  - the vessels are fixed by conjunctive septums**
  - have a radial direction against auricle**
  - do not collapse in case of injury**
  - the arteries form anastomoses with medial meningeal a. through the emissary foramina
41. Venous layers of the cerebral region are:
- subcutaneous vv., diploic vv., sinuses of the dura mater**
  - intradermal vv., periosteal vv., cerebrale vv.
  - subcutaneous vv., perforant vv., sinuses of the dura mater
  - diploic vv., emissary vv., cerebral vv.
  - diploic vv., emissary vv., perforant vv.
42. What true emissary veins can be mentioned:
- parietal emissary vv.**
  - mastoid emissary vv.**
  - occipital emissary vv.
  - frontal emissary vv.
  - foramini lacerti emissary vv.
43. Mastoid emissary veins flow into:
- sinus transversus
  - sinus sigmoideus**
  - sinus sagittalis superior
  - sinus petrosus superior
  - vena cerebri magna
44. Parietal emissary veins flow into:
- sinus sagittalis inferior
  - sinus sagittalis superior**
  - sinus sigmoideus
  - sinus rectus
  - sinus occipitalis

45. Which bony structure is fractured more frequent on a wider area in craniocerebral trauma:
- lamina vitrea**
  - diploe
  - external lamina
  - periostum
  - mastoid process
46. The trajectory of the neurovascular bundles in the head region is:
- radial**
  - parallel
  - oblique
  - perpendicular
  - “S” shape
47. Terminal branches of the ophthalmic artery are:
- frontal a.**
  - supraorbital a.**
  - superficial temporal a.
  - transvers a. of the face
  - angular a.
48. Find the correct answers:
- a. supratrohlearis passes at 2cm from the median line through incisura supratrohlearis**
  - a. supraorbitalis passes at 2,5cm from the median line through incisura supraorbitalis**
  - a. frontalis passes through incisura supraorbitalis at 2cm from the median line
  - a. supraorbitalis passes at 5cm from the median line
  - a. supraorbitalis passes through incisura frontalis
49. Lymphatic vessels from the frontoparietooccipital region flow into:
- nodi limphatici auricularis anteriores**
  - nodi limphatici auricularis posteriores**
  - nodi limphatici occipitalis**
  - nodi limphatici frontalis
  - nodi limphatici buccalis
50. Inferior sagitalis sinus flows into:
- sinus rectus**
  - sinus petrosus superior
  - confluens sinus
  - sinus sigmoideus
  - magna cerebri vein
51. How many laminas does the temporal fascia have:
- one
  - two**
  - three
  - four
  - it does not have laminas, it is an aponeurosis
52. Enumerate cellular fatty tissue layers which are located in the temporal region from 1 to 3:



- a) **subcutaneous space**
- b) **interaponeurotic space**
- c) **subaponeurotic space**
- d) intratemporal space
- e) epitemporal space

53. Find the true sentence:

- a) **medial meningeal a. gives blood supply to the dura mater, starts from the a. maxilaris, passes through foramen spinosum, gives two branches into the cranium**
- b) medial meningeal a. gives blood supply to the arachnoida, starts from the a. maxilaris, passes through foramen lacerum, gives two branches in the cranium
- c) medial meningeal a. gives blood supply to the pia mater, starts from the a. maxilaris, passes through foramen ovale, gives three branches in the cranium
- d) medial meningeal a. gives blood supply to the arachnoida, starts from the a. carotis interna, passes through foramen lacerum, gives two branches in the cranium
- e) medial meningeal a. gives blood supply to the orbit, starts from the a. carotis interna, passes through foramen rotundum, gives two branches in the cranium

54. What muscles insert on the mastoid process:

- a) **m. longissimus capitis and splenius**
- b) **m. sternocleidomastoideus**
- c) **posterior belly of m. digastricus**
- d) omohyoid m
- e) lateral pterygoid m.

55. Communication between cavum tympani and mastoid cells is insured by:

- a) **aditus ad antrum**
- b) recessus epitimpanicus
- c) tegmen tympani
- d) sinus sigmoideus
- e) Eustache's trump

56. Auditive bones are situated in:

- a) **recessus epitimpanicus**
- b) cavum tympani
- c) antrum tympanicum
- d) antrum mastoideum
- e) celullae mastoidea

57. On which side of the trepanation triangle is projected the sigmoid sinus:

- a) **posterior side**
- b) superior side
- c) anterior side
- d) anterior and superior side
- e) does not have tangencies with the trepanation triangle

58. At what depth and on which side of the trepanation triangle can be injured the facial nerve:
- anterior side, at 1,5 - 2 cm depth**
  - superior from porus acusticus externum, at 1 cm
  - posterior from spina suprameatum, subperiostal
  - anterior side, at 0,5 cm
  - facial n. is not projected in this region
59. How many structures can be injured in case of trepanation of the mastoid process:
- one
  - two
  - three
  - four**
  - five
60. What foramens can be found in the anterior cranial fossa:
- foramen caecum**
  - foramens of the lamina cribrosa**
  - foramen rotundum
  - fisura orbitalis superior
  - foramen opticum
61. What passes through the openings from the anterior cranial fossa:
- filea olfactoria**
  - a. ethmoidalis anterior**
  - a. ethmoidalis posterior
  - a. ethmoidalis media
  - a. meningeae media
62. Through the cavernous sinus passes:
- a. carotis interna**
  - n. abducens**
  - n. trochlearis
  - plexus pterigoideus
  - n. oculomotorius
63. Through the external wall of the cavernous sinus pass the following structures:
- oculomotor n.**
  - trochlear n.**
  - ophthalmic n.**
  - internal carotis a.
  - maxilar n.**
64. Through the superior ophthalmic fissure pass:
- n. ophthalmic**
  - n. trochlearis**
  - n. abducens**
  - n. facial
  - n. oculomotor**
65. Which structures are situated between the external and internal lamina of the bones of the cranium:
- lamina vitrea
  - spongy bone tissue**
  - diploic veins**
  - epidural veins
  - medial meningeal a.
66. Frontal nerve is the branch of which nerve:
- n. infraorbitalis
  - n. supratrochlearis
  - n. trochlearis
  - n. ophthalmic**
  - n. supraorbitalis

67. What structure is situated between the laminae of the temporal aponeurosis:
- superficial temporal a.
  - interaponeurotic fatty tissue**
  - deep temporal aa.
  - temporal m.
  - auriculotemporal n.
68. During mastoid trepanation was injured medial cranial fossa. Which side of the triangle of Chippaut was not respected:
- the superior edge - the line that constitutes the extension of zygomatic arch on mastoid apophysis**
  - the anterior edge - line that goes posterior to porus acusticus externus
  - inferior edge
  - the posterior edge – at medial edge of the mastoid tuberosity
  - no answer is correct
69. What structures pass through ethmoid bone:
- v. ophthalmica superior
  - fila olfactoria**
  - ethmoidalis anterior nerve**
  - ethmoidalis posterior nerve**
  - v. emissariae
70. What passes through foramen rotundum:
- n. maxilaris**
  - n. petrosus minor
  - vv. emissariae
  - n. vagus
  - ramus meningeus n. mandibularis
71. Where does the dura mater intimately join with the bones of the cranium:
- on the vertex of the cranium
  - on the sphenoidal bone, circular from the cella turcica**
  - lamella cribrosa of the ethmoid bone**
  - temporal pyramid**
  - squamous part of the temporal bone
72. In which anatomical structure flows the inferior sagittal sinus:
- sinus sagittalis superior
  - sinus rectus**
  - sinus sigmoideus
  - sinus transversus
  - sinus occipitalis
73. Which artery is formed at the confluence of the aa. vertebralis dextra et sinistra:
- posterior communicating a.
  - anterior communicating a.
  - a. basilaris**
  - a. cerebri media
  - a. carotis interna
74. What nerve innervates the mimic muscles:
- n. trigeminus
  - n. facialis**
  - n. oculomotorius
  - n. accessorius
  - n. trochlearis
75. What branches give a. temporalis superficialis at the superior margin of the orbit:
- r. parietalis**
  - rr. parotidei
  - a. auricularis posterior
  - rr. auriculares anterior



e) **r. frontalis**

76. Which artery is situated in the temporoptyergoid space:

- a) a. meningeia media
- b) a. alveolaris inferior
- c) **a. maxilaris**
- d) a. auricularis profunda
- e) a. tympanica anterior

77. Through which foramen enters the medial meningeal a. into the cranial cavity:

- a) foramen rotundum
- b) **foramen spinosum**
- c) foramen ovale
- d) foramen magnum
- e) foramen stilomastoideum

78. Pterygoidian plexus communicate whith which veins:

- a) **with facial vein through deep facial v.**
- b) **with retromandibular v. through maxillar v.**
- c) with sigmoid sinus
- d) **with cavernos sinus through emissary veins from the spinosum, ovale and lacerum foramena**
- e) with sinus rectus

79. Which nerv evervates the masticator muscles:

- a) n. trochlearis
- b) n. facialis
- c) n. glossopharyngeus
- d) n. accesorius
- e) **n. trigemenus**

80. Which nerves begin from the semilunar ganglion (Gasser):

- a) **n. ophthalmicus**
- b) n. auricularis posterior
- c) n. zigomaticus
- d) **n. maxilaris**
- e) **n. mandibularis (n. mandibularis)**

81. What structures can be found in the sphenopalatin fossa:

- a) n. auriculotemporalis
- b) **n. zigomaticus**
- c) **rr. ganglionares of n. maxilaris**
- d) **ganglionum pterigopalatinum**
- e) ganglionum ciliare

82. Through which foramen the mandibular nerve leaves the cranium cavity:

- a) **foramen ovale**
- b) foramen spinosum
- c) foramen rotundum
- d) foramen stylomastoideum
- e) none of the answers

83. The projection of the transvers sinus is:

- a) inferior temporal line
- b) **superior nuchal line**
- c) inferior nuchal line
- d) the line that connects lambda with asterion
- e) zygomatic arch

84. Which structures pass through the internal acustic porus:

- a) **internal auditiv a.**
- b) **facial n.**
- c) **vestibulochohlear n.**
- d) petros major n.

- e) petros minor n.
85. Which structures pass through the jugular foramen:  
 a) **n. glossopharyngeus**  
 b) **n. vagus**  
 c) **n. accesorius**  
 d) **internal jugular v.**  
 e) n. hypoglossus
86. The intracranial portion of the facial nerve is situated in the midst of which bone:  
 a) **temporal**  
 b) parietal  
 c) sphenoidal  
 d) occipital  
 e) frontal
87. Intracerebral cisterns are formed in the following space:  
 a) **subarahnoidian**  
 b) subdural  
 c) epidural  
 d) in cerebral ventricles  
 e) none of the answers
88. In which space is the circulus arteriosus Willissii situated:  
 a) **subarahnoidian**  
 b) subdural  
 c) epidural  
 d) subperiostal  
 e) extracranial
89. What regions does the lateral compartment of the face include:  
 a) buccal (oralis) region  
 b) **parotydomasseteric region**  
 c) **deep facial region**  
 d) **genian region**  
 e) nasolabialis region
90. Where is situated the ganglion of trigeminal nerve:  
 a) **on the impressio trigemini of the pyramid in the dura mater's duplicature (cavum Meckeli)**  
 b) subdural on the impressio trigemini of the pyramid  
 c) epidural on the impressio trigemini of the pyramid  
 d) on the impressio trigemini of the pyramid in the pia mater duplicature  
 e) none of the answers
91. What does the pharyngoprevetebralis aponeurosis limit:  
 a) **retropharyngeal space from the parapharyngeal space**  
 b) anterior parapharyngeal space from the posterior parapharyngeale space  
 c) retropharyngeal space from the pterygomandibular space  
 d) retropharyngeal space from the prevertebral cervical space  
 e) previsceral cervical space from the cervicale neurovascular space
92. What are the limits of the parotideomasseteric region and retromandibular fossa:  
 a) **anterior - anterior margin of the masseter m.**  
 b) **posterior - anterior margin of the sternocleidomastoidean m., porus acusticus externus and mastoid process**  
 c) anterior - anterior margin of the parotid gland  
 d) **inferior - mandible margin**  
 e) **superior - zygomatic arch**
93. How many weak points has the capsule of the parotid gland  
 a) one - infratemporal  
 b) **two - auricular and pharyngeal**  
 c) three - mastoid, interptergoidian and pharyngeal

- d) four - mastoid, temporopecterigoidian, interpterigoidian and pharyngeal  
e) does not have weak points
94. What are the limits of the cellular fatty tissue space of the sublingual gland:  
a) **superior - mucosa of the buccal cavity**  
b) **lateral - the mandible**  
c) **medial - genyoglossus and genyohyod mm.**  
d) **inferior - mylohyoid and hyoglossus mm.**  
e) inferior - platisma m.
95. What muscles does the facial nerve enervate:  
a) **mimmic mm.**  
b) **frontal and occipital mm.**  
c) **stylohyoid m. and posterior belly of the digastric m.**  
d) **platisma m.**  
e) mylohyoid m.
96. What muscles are enervated by the third branch of the trigeminal nerve?  
a) **masseter m.**  
b) **temporal m.**  
c) **medial and lateral pterygoid mm.**  
d) **mylohyoid m. and anterior belly of the digastric m.**  
e) frontal m.
97. Where does the sphenoidal sinus open:  
a) **above the superior nasal conchae**  
b) in the medial nasal meatus  
c) in the inferior nasal meatus  
d) in the mesopharynx  
e) in the maxilar sinus
98. The maxillary sinus opens:  
a) **in the medial nasal meatus**  
b) in the inferior nasal meatus  
c) in the superior nasal meatus  
d) in the bulla ethmoidalis  
e) in the nasopharynx
99. Where does the nasolacrimal canal open:  
a) medial nasal meatus  
b) **inferior nasal meatus**  
c) superior nasal meatus  
d) nasopharynx  
e) buccal cavity
100. Which muscles contribute to the formation of the buccal diaphragm:  
a) **mylohyoid m.**  
b) digastric mm.  
c) geniohyoid mm.  
d) genioglossus m.  
e) hyoglossus m.
101. Which muscles form the soft palate:  
a) **uvulae m.**  
b) **levator veli palatini m.**  
c) **tensor veli palatini m.**  
d) lateral pterygoid m.  
e) medial pterigoid m.
102. The posterior margin of the soft palate passes into the lateral wall of the pharynx by the means of two folds which contain the following muscles:  
a) **palatoglossal m.**  
b) **m. palatopharyngeal**

- c) uvulae m.
- d) levator veli palatini m.
- e) tensor veli palatini m.

103. What are the limits of the genian region:

- a) **superior - inferior margin of the orbit**
- b) **inferior - margin of the mandible**
- c) **posterior - anterior margin of the masseter m.**
- d) **anterior - nasolabial and nasobuccal folds**
- e) posterior - ramus of the mandible

104. Where is situated the corpus adiposum buccae of Bichat:

- a) **on the buccal m., anterior from the masseter m.**
- b) under the buccal m., anterior from the masseter m.
- c) under the zygomatic bone, in infratemporalis fossa
- d) on the parotid gland
- e) under the buccopharyngeal fascia

105. Which structures are in direct neighbourhood with the weak points of the parotid gland:

- a) **Anterior parapharyngeal space**
- b) **cartilage portion of the external acoustic porus**
- c) canal of the facial n.
- d) retropharynx
- e) the capsule of the submandibular gland

106. Where does the external carotid artery give terminal branches:

- a) **in the mass of parotid gland**
- b) posterior from the parotid gland
- c) at the entrance of the parotid gland
- d) above the zygomatic arch
- e) between the pterygoid mm.

107. Which are the terminal branches of the external carotid artery:

- a) **a. temporalis superficialis**
- b) **a. maxilaris**
- c) a. facialis
- d) a. temporalis profunda
- e) a. meningea media

108. Name the branches of the facial nerve which spread from the parotid plexus:

- a) **temporal and zygomatic**
- b) **buccal**
- c) **marginal of the mandible**
- d) **cervical**
- e) auriculotemporal

109. Name elements located in the facial canal:

- a) **facial n.**
- b) **stylomastoidian a and v.**
- c) **big and small superficial petrosal nn.**
- d) **chorda tympani.**
- e) auriculotemporal n.

110. What passes through the anterior parapharyngeal space?

- a) **branches of ascending palatine a.**
- b) maxillary a.
- c) vagus n.
- d) retromandibular v.
- e) maxillary n.

111. What passes through the posterior parapharyngeal space?

- a) **internal jugular v. and internal carotid a.**
- b) external carotid a.
- c) **glossopharyngeal, vagus and accessory nn.**
- d) **hypoglossal and sympathetic nn..**
- e) mandible n.

112. Retropharyngeal space limits are:

- a) **retropharyngeal fascia.**
- b) **prevertebral fascia.**
- c) **fascial sheet between the pharynx and fascia prevertebralis**
- d) endocervical fascia.
- e) parotid fascia.

113. In what direction can be propagated purulent collections located in the adipose body of the cheek?

- a) **temporal cellular space**
- b) **infratemporal cellular space**
- c) **orbital cellular space**
- d) cellular space of the floor of the mouth
- e) parapharyngeal cellular space

114. Purulent collections of temporopterigoidian space may spread to:

- a) **cranial cavity**
- b) **orbital and nasal cavity**
- c) **oral cavity**
- d) **adipose body of cheek**
- e) none is correct

115. Purulent collections from interpterigoidian space may spread to:

- a) **temporopterigoidian and parapharyngeal space**
- b) **cranial cavity**
- c) **oral**
- d) retropharyngeal space
- e) none is correct

116. What are the limits of lateral parapharyngeal space?

- a) **medial - pharynx with its fascia**
- b) **lateral- parotid capsule and medial pterigoid m.**
- c) **superior - the skull base**
- d) lateral - parotid capsule and lateral pterigoid m.
- e) medial - pharynx and parotid gland

117. What anatomical structures are located in the anterior portion of the parapharyngeal space?

- a) **ascending palatine a. and v.**
- b) sympathetic trunk
- c) vagus n.
- d) hypoglossal n.
- e) facial n.

118. What anatomical structures are located in the posterior portion of the parapharyngeal space?

- a) ascending palatine a and v.
- b) **internal jugular v. and internal carotid a.**
- c) **glossopharyngeal and vagus nn.**
- d) **accessory , hypoglossal nn. and sympathetic trunk**
- e) facial and mandibular nn.

119. Retropharyngeal space it is situated between:

- a) **pharynx and prevertebral fascia**
- b) pharynx and endocervical fascia
- c) pharynx and parotid capsule
- d) pharynx and pterygoid mm.
- e) none is correct

120. Select landmarks through which passes the limit between cerebral portion of the head and facial portion of the head.
- a) superficial temporal line
  - b) supraorbital edge of the frontal bone**
  - c) superior edge of the zygomatic arch**
  - d) nuchal superior line
  - e) inferior edge of the orbit
121. Select the bones that form the lateral wall of the orbit.
- a) frontal apophyses of the maxillary bone
  - b) lacrimal bone
  - c) greater wing of sphenoid bone**
  - d) small wing of the sphenoid bone
  - e) zygomatic bone**
122. Select the bones that form the superior wall of the orbit.
- a) ethmoid bone
  - b) frontal bone**
  - c) greater wing of sphenoid bone
  - d) zygomatic bone
  - e) small wing of the sphenoid bone**
123. Select the muscles innervated by the oculomotor nerve.
- a) oblique superior m.
  - b) elevating muscle of upper eyelid**
  - c) rectus superior**
  - d) rectus inferior**
  - e) oblique inferior**
124. Select dura mater expansions.
- a) falx sellae
  - b) falx cerebri**
  - c) tentorium cerebelli**
  - d) diaphragma sellae**
  - e) tentorium rectus
125. Select cisterns derived from the subarachnoid space.
- a) cistern of the lateral fossa**
  - b) interpeduncular cistern**
  - c) chiasmatica cistern**
  - d) the cistern of anterior cerebral fossa
  - e) cisterna cerebromedullaris**
126. Select arteries which pump blood into the brain.
- a) internal carotid artery**
  - b) vertebral artery**
  - c) meningeal posterior artery
  - d) ophthalmic artery
  - e) middle meningeal artery
127. Middle meningeal artery branches are the following.
- a) anterior**
  - b) superior
  - c) inferior
  - d) lateral
  - e) posterior**
128. Facial nerve branches are:
- a) great auricular n**
  - b) stapedius n**
  - c) supraorbital n
  - d) chorda tympani**
  - e) lacrimal n.

129. Frontal sinus opens into:

- a) superior nasal meatus
- b) medial nasal meatus**
- c) external nose
- d) oral cavity
- e) inferior nasal meatus

130. Pirogov-Waldeyer's lymphatic ring consists of the following elements:

- a) laryngeal tonsil
- b) palatine tonsils**
- c) lingual tonsils**
- d) tubal tonsils**
- e) pharyngeal tonsils**

131. Excretory duct of the parotid gland opens at the level of:

- a) inferior nasal meatus
- b) the first two lower molars
- c) the upper incisors
- d) the first two upper molars**
- e) upper canines

132. The components of the nasal septum are:

- a) the membranous part**
- b) the cartilaginous part**
- c) the spongios part
- d) the cutaneous part
- e) the bone**

133. Through the round opening of large wings of sphenoids bone passes:

- a) the first branch of the trigeminal nerve
- b) the second branch of the trigeminal nerve**
- c) the third branch of the trigeminal nerve
- d) medial meningeal artery
- e) vertebral artery

134. Superior nasal meatus communicates with:

- a) posterior ethmoid cells**
- b) sphenoid sinus
- c) maxillary sinus
- d) frontal sinus
- e) oral cavity

135. Lymphatic drainage from the lateral region of the face is carried out in the following lymph nodes:

- a) buccinator lymph nodes
- b) deep facial lymph nodes
- c) parapharyngeal and retropharyngeal lymph nodes
- d) para-auricular lymph nodes**
- e) none of the following groups

136. Buccinator lymph nodes are situated in:

- a) the anterior border of the masseter muscle
- b) the thickness of the parotid gland parenchyma
- c) in the parotid capsule
- d) the inner surface of the buccinator muscle**
- e) the line of facial vein

137. Lymph paraauricular nodes are situated:

- a) just below the parotid capsule
- b) posterior parathyroid gland
- c) on the anterior edge of the masseter muscle**
- d) lateral masseter muscle capsule
- e) on the line of the internal carotid artery

138. The orbit communicates through superior orbital fissure with the:

- a) pterygopalatine fossa
- b) middle cerebral fossa**
- c) fossa subtemporală
- d) the mastoid bone cells
- e) temporal fossa

139. Through the inferior orbital fissure, orbit communicates with:

- a) pterygopalatine, temporal and infratemporal fossas**
- b) anterior ethmoid cells
- c) posterior ethmoid cells
- d) inferior nasal meatus
- e) middle cranial fossa

140. Posterior ethmoid cells communicate with:

- a) anterior ethmoid cells
- b) orbit**
- c) middle cranial fossa
- d) anterior cranial fossa
- e) paranasal sinuses

141. Ways of exudate spreading from ethmoidal labyrinth:

- a) to inferior nasal meatus
- b) to orbit**
- c) to the dura mater**
- d) to maxillary sinus**
- e) to parapharyngeal cellular tissue

142. The anterior wall of frontal sinus is formed by:

- a) nasal and frontal processes of the nasal bones**
- b) paranasal sinuses
- c) inferior nasal meatus
- d) radix nasi and supraciliary arch
- e) all the above-named versions are correct

143. From superior to the sphenoid sinus join next anatomical structures:

- a) turkish saddle**
- b) the body of the sphenoid bone
- c) pituitary gland**
- d) optical chiasma**
- e) cavernous sinus of the dura mater**

144. From inferior to the sphenoid sinus join next anatomical structures:

- a) upper jaw body
- b) the body of the sphenoid bone**
- c) the posterior part of superior nasal meatus**
- d) the posterior part of nasal meatus**
- e) pharyngeal tonsils**

145. Towards the posterior sphenoid sinus adhere the following anatomical structures except:

- a) turkish saddle
- b) upper jaw body**
- c) cavernous sinus**
- d) ophthalmic vein**
- e) dura mater

146. To bilateral sphenoid sinus adhere the following anatomical structures except:

- a) upper jaw body
- b) cavernous sinus
- c) maxillary nerve and the round foramen walls
- d) ophthalmic vein
- e) anterior face of the occipital bone clivus**



147. Towards the lower maxillary sinus join these anatomical structures:

- a) upper jaw body
- b) branch of infraorbital artery and nerve
- c) maxillary tuberosity
- d) alveolar processes of the upper jaw**
- e) pterygopalatine ganglion

148. Towards the posterior maxillary sinus join these anatomical structures except:

- a) body and maxillary superior tuberosity
- b) pterygopalatine artery
- c) superior alveolar nerves
- d) pterygopalatine ganglion
- e) zygomatic process of the maxilla**

149. Superficial lymph nodes group from the parotidomasseteric region is located:

- a) between the skin and subcutaneous cellular space
- b) between subcutaneous cellular space and superficial fascia
- c) between the superficial sheet of the propria fascia and parotid parenchyma**
- d) between parotid parenchymal septum
- e) between the parenchymal gland and internal sheet of fascia propria

150. Parotid parenchyma contains anatomical formations:

- a) retromandibular vein**
- b) branches of the facial nerve**
- c) sublingual vein
- d) superficial temporal artery**
- e) auriculotemporal n.**

151. Parotid parenchyma contains anatomical formations except the following:

- a) the external carotid artery
- b) maxillary artery
- c) superior alveolar nerve**
- d) deep group of lymph nodes
- e) superficial temporal artery

152. The cellular deep subpterygoidian space of the deep face region is situated between:

- a) temporal muscle and the lateral pterygoid muscle
- b) medial and lateral pterygoid muscle
- c) the mandible and medial pterygoid muscle**
- d) the maxillary tuberosity and the pterygoid process
- e) none of the above mentioned

153. Possible ways of propagation of infected exudate from parotidomasseteric area are:

- a) temporo-ptyergoid cellular tissue
- b) interpterygoidian cellular tissue
- c) parapharyngeal cellular tissue**
- d) external auditiv channel**
- e) maxillary sinus

154. Interpterygoidian cellular space of the deep face region includes:

- a) mandibular nerve with its branches**
- b) internal carotid artery
- c) the internal jugular vein
- d) IX pair of cranial nerves
- e) all the above variants

155. The third branch of the trigeminal nerve is located in:

- a) cellular tissue under the masseter muscle
- b) cellular tissue under buccinator muscle
- c) cellular temporo-ptyergoidean space
- d) cellular interpterygoid space**
- e) cellular pterygomandibular space

156. Towards the maxillary sinus from posterior join next anatomical structures except:

- a) body and maxillary tuberosity
- b) middle nasal meatus
- c) pterygopalatine ganglion
- d) pterygoid muscles
- e) **the pterygopalatine process**

157. Mental nerve is a branch of the nerve:

- a) maxillary nerve (branch 2 of the trigeminal nerve)
- b) trochlear nerve (fourth pair of cranial nerves)
- c) optic nerve (cranial nerves II pair)
- d) **inferior alveolar nerve** (3<sup>rd</sup> branch of trigeminal nerve)
- e) oculomotor nerve

158. Interaponeurotic cellular space of the temporal region communicates with the following cellular spaces:

- a) subcutaneous space of the temporal region
- b) the cellular tissue of the temporo-pterigoid region
- c) interptergoidean cellular tissue
- d) the cellular tissue of the bucal region
- e) **do not communicate**

159. Clinical significance of emissary veins:

- a) **propagation of the inflammatory process**
- b) **the compensatory adjust of intracerebral pressure**
- c) triggers arterio-venous shunt at the increase of HTA
- d) triggers veno-venous shunt at the increase of HTA
- e) have no great importance due to small size

160. What type of hematoma presents the lenticular aspect:

- a) epicranial subaponeurotic
- b) subdural
- c) **epidural**
- d) subarachnoid
- e) intraparenchymatous

161. Trauma of the temporal region is aggravated by the following regional particularities:

- a) **presence on the internal face of medial meningeal a.**
- b) presence on the internal face of cerebral media a
- c) **the absence of diploe**
- d) proximity to sphenopalatina a.
- e) **thickness of 2 mm of temporal squamus**

162. Name the possible variety of hematoma in fronto-parietal-occipital region:

- a) intradiploic
- b) **subcutaneous**
- c) **subperiosteal**
- d) **subaponeurotic**
- e) intraparenchymal

163. Suggest hemostasis method available to diploic vein injury:

- a) ligation of diploic vein
- b) using coagulation
- c) application of hemostatic forceps
- d) **treating the defect edge with Wax**
- e) procoagulant intravenous medication

164. The scalp injuries represent:

- a) epicranial tissue take off together with the periosteal covering
- b) **epicranial tissue take off including the aponeurosis**
- c) **severe injury, high regenerative potential**
- d) injury of medium gravity, low regenerative potential
- e) obligatory association with bone fracture

165. The presence of inflammatory / purulent affections at the nasal-labial triangle generate:

- a) **compression of the facial v. by edema of soft tissues**
- b) **septic emboli migration through angular v.**
- c) dissemination process through lingual v.
- d) pterigoidian venous plexus thrombosis
- e) **cavernous sinus thrombosis**

166. Differentiation of cerebral sinus and cisterns includes:

- a) **sinuses are expansion of dura matter**
- b) sinuses - circulatory system for cerebrospinal fluid
- c) cisterns- provide cerebral venous return path
- d) **cisterns- circulatory system for cerebrospinal fluid**
- e) **cisterns - sectoral expansion of subarachnoid space**

167. Facial nerve injury results in:

- a) **ipsilateral paralysis of mimic muscles**
- b) **ipsilateral eyelid ptosis, lacrimation**
- c) contralateral ptosis of the eyelid, lacrimal hyopsecretion
- d) **moving the mouth corner toward the healthy side**
- e) naso-labial fold attenuation on the healthy side

168. Theft from cerebral circulation (Steal syndrome) can take place through:

- a) obstruction of the brachiocephalic arterial trunk
- b) obstruction axillary art.
- c) **obstruction of subclavian a. proximal to origin of vertebral art.**
- d) **the compensatory blood circulation through arterial polygon Willis**
- e) **shunting cerebral circulation**

169. Clinical significance of fontanel:

- a) allow the increase in the amount of neurons during their active division
- b) **allow passage of the head through the birth canal**
- c) increase cerebral tissue oxygenation
- d) **serve as evidence for late diagnosis of meningeal inflammatory conditions**
- e) **allow venous abord of the superior sagittal sinus**

170. Cephalic shape "the tower" met in hereditary pathologies of hemoglobin is called:

- a) dolichocephalics
- b) platicefalic
- c) braficefalic
- d) ortocefalic
- e) **hipsicefalic**

171. Normal volume of the nasal cavity ventilation include:

- a) medial meatus + superior meatus
- b) medium meatus
- c) superior meatus
- d) **inferior meatus + medium meatus**
- e) all nasal meatus are included

172. Location of the olfactory mucosa is bounded by:

- a) superior edge of superior nasal concha
- b) **superior edge of rhe medial nasal concha**
- c) superior edge of the inferior nasal concha
- d) **roof of the nasal cavity**
- e) a horizontal line drawn through the anterior ethmoid hole

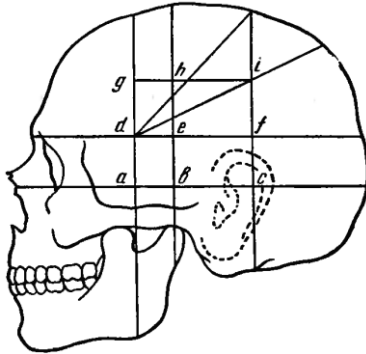
173. Superior nasal meatus can serve as an access way in:

- a) **minimally invasive treatment of neoplasms of the sella turcica**
- b) lateral ventriculostomia realization
- c) **decompression of the optic chiasm**
- d) punction of the maxillary sinus
- e) meatus is only the upper segment of the nasal cavity

174. Retroocular adipose tissue damage is encountered in:

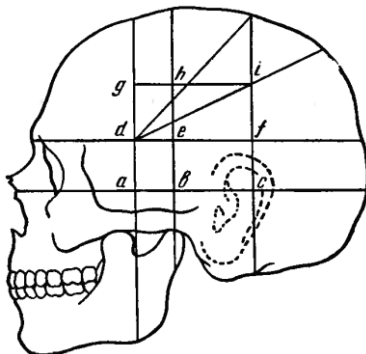
- a) hypoparathyroidism
- b) hyperparathyroidism
- c) hypothyroidism
- d) hypogonadism
- e) **hyperthyroidism**

175. Intersection of anterior vertical line with two horizontal lines in topographical scheme Kronlein correspond to the:



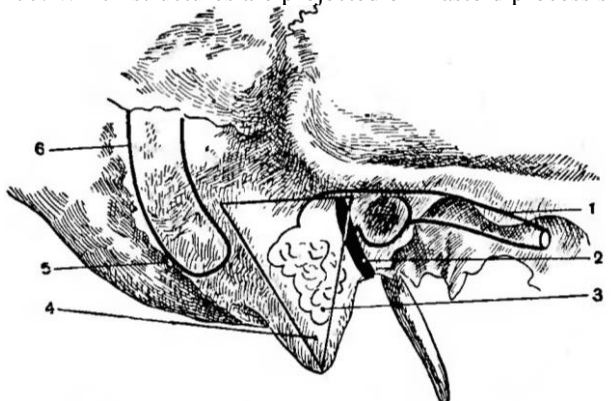
- a) **trunk and anterior branch of medial meningeal a.**
- b) trunk and posterior branch of medial meningeal a.
- c) trunk and medial branch of medial meningeal a.
- d) the inferior intersection corresponds with pituitary but superior with epiphysis
- e) do not have clinical importance

176. Intersection of medial vertical line with superior horizontal line in topographical scheme Kronlein corresponds to the:



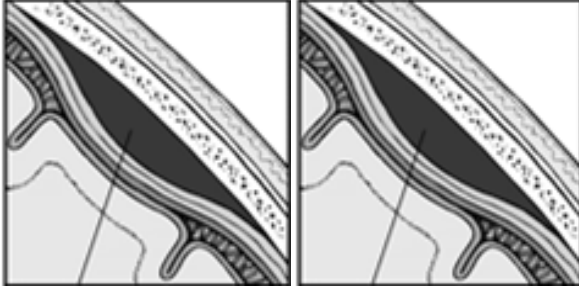
- a) **trunk of posterior branch of medial meningeal a.**
- b) trunk of medial branch of meningeal a.
- c) trunk of anterior branch of medial meningeal a.
- d) trunk of medial meningeal artery
- e) do not have clinical importance

177. Which structures are projected on mastoid process surface following numbers:



- a) **internal auditiv canal, facial n., mastoid cells, mastoid crist, mastoid emisaria vein, sigmoid sinus**
- b) facial n., internal auditiv canal, mastoid cells, mastoid crist, mastoid emisaria vein, sigmoid sinus
- c) mastoid cells, internal auditiv canal, facial n., mastoid crist, mastoid emisaria vein, sigmoid sinus
- d) mastoid crist, internal auditiv canal, facial n., mastoid cells, mastoid emisaria vein, sigmoid sinus
- e) mastoid emisaria vein, internal auditiv canal, facial n., mastoid cells, mastoid crist, sigmoid sinus

178. What types of hematomas are represented on this picture?



- a) **epidural**
- b) subarahnoidal
- c) intracerebral
- d) **subdural**
- e) subpial

## OPERATIONS ON THE HEAD

1. Why the incisions on the face are performed radially?
  - a) to obtain a better access
  - b) to avoid lesion of branches of the trigeminal nerve
  - c) to avoid lesion of the facial muscles
  - d) to avoid lesion of the branches of the facial artery and vein
  - e) **to avoid lesion of branches of the facial nerve**
  
2. Which material is preferred in cranioplasty
  - a) **allografts extracted and processed by chemical and physical methods**
  - b) pediculated bone flap, modeled from nearby tissue
  - c) patient's rib
  - d) xenotransplant
  - e) allografts extracted and used immediately
  
3. In which region of the skull is performed decompressive trepanation?
  - a) **directly on the pathologic site**
  - b) in temporal region
  - c) in sagittal sinus
  - d) in parietal region
  - e) in occipital region
  
4. In which way the dura mater may be cut during the skull trepanation?
  - a) longitudinal
  - b) transversal
  - c) **cruciform**
  - d) **shaped flap, the base of which is oriented towards the sagittal sinus**
  - e) shaped flap, the base of which is oriented against the sagittal sinus
  
5. Which basic maneuver is performed during trepanation of the skull, Olivecron procedure?
  - a) resection of the bone lamella
  - b) **separated modelling of the flaps**
  - c) simultaneous modelling of the flaps (one-flap trepanation)
  - d) separated modelling of the bone and periosteum
  - e) resection of dura mater
  
6. What does Vagner-Wolf's trepanation procedure consist of?
  - a) resection of bone lamella
  - b) separated modelling of the flaps
  - c) **simultaneous modelling of the flaps (one-flap trepanation)**
  - d) resection of dura mater
  - e) separated modelling of the bone and periosteum
  
7. What kind of hematoma is formed in case of the lesion of middle meningeal artery?
  - a) **progressive epidural**
  - b) localized subdural
  - c) diffuse subarachnoid
  - d) spontaneous subpial
  - e) spontaneous intracerebral
  
8. Which vessels or tissues bleed in case of penetrating head trauma ?
  - a) **meningeal vessels of the brain**
  - b) **dural venous sinuses**
  - c) brain tissues
  - d) **epicranial tissues**

- e) **diploic veins**
9. What kind of sutures are applied on the dura mater after primary surgical treatment of penetrating head trauma?
- a hermetic suture
  - rare separated sutures
  - a single suture, then a drainage is placed
  - sutures are not applied**
  - one of the above, depending on surgical volume
10. What to do in case of a penetrating skull trauma with a small orifice?
- if necessary, to extend the orifice, after a qualified clinical and paraclinical examination**
  - to cover the defect with a bone graft
  - to make a supplementary orifice in the skull
  - to resect the injured segment of the skull
  - to remove the injured part of the brain
11. Note the hemostatic methods used in case of bleeding from diploic veins:
- coagulation
  - digital compression
  - tamponage
  - bone wax application**
  - vessels suturing
12. In case of head injuries, accumulation of blood between the skull and brain, can be into three types:
- epidural hematoma**
  - intradural hematoma
  - subdural hematoma**
  - intradiploic hematoma
  - subarachnoidal hematoma**
13. Puncture of the maxillary sinus is performed through:
- superior nasal meatus
  - inferior nasal meatus**
  - anterior wall of the maxillary sinus
  - medium nasal meatus
  - superior wall of the maxillary sinus
14. Haemostasis in the lesions of superior sagittal sinus is performed by
- bilateral ligation of the sinus**
  - buffering the sinus**
  - plasty of the sinus defect with external lamella of the dura mater (Burdenco technique)**
  - applying sutures in the case of small defects**
  - electrocoagulation
15. Buffering the superior sagittal sinus in case of massive injury involves:
- Introducing the gauze between the inferior wall of the sinus and the arachnoid
  - Introducing the gauze in the sinus lumen
  - Introducing the gauze between the superior wall of the sinus and cranial vault bones**
  - Introducing the gauze in the subarachnoid space
  - All answers are incorrect
16. What is trephination of the skull?
- epicraniene tissue sectioning
  - dura mater sectioning
  - access way to the subaponeurotic space
  - access way to the subperiosteal space
  - opening the cranial cavity**
17. What are the indications for performing trephination of the skull?

- a) **brain tumor**
  - b) **intracerebral hematoma**
  - c) **intracerebral aneurysm**
  - d) **subdural hematoma**
  - e) concussion
18. Primary surgical healing of the non-penetrative brain wound consists of:
- a) **hemostasis from epicraniene vessels**
  - b) **removing bone fragments in the case of cranial vault fracture**
  - c) **processing the wound with antiseptic**
  - d) sectioning of the dura mater
  - e) ligation of the intracerebral sinuses
19. Primary surgical healing of the penetrating brain wound consists of:
- a) **removing bone fragments thrust in the brain tissue**
  - b) **wide opening of the dura mater**
  - c) **hemostasis from dura mater sinuses**
  - d) **none-suturing the dura mater**
  - e) no answer is correct
20. Penetrating wounds from cerebral portion of the head involves:
- a) Bone injury of the cranial vault
  - b) **dura mater injury**
  - c) epicraniene tissue damage
  - d) presence of an scalp wounds
  - e) injury of the vitreous lamella
21. Temporary hemostasis in case of bleeding from epicranium vesels involves:
- a) vessels clamping
  - b) electrocoagulation
  - c) suturing the vessels
  - d) **digital compression of the wound edges to the cranial vault bones**
  - e) compression of the common carotid artery to the the carotid tubercle
22. What are the indications for trephination of the mastoid apophysis ?
- a) **purulent media otitis complicated with inflammation of the mastoid cells**
  - b) external purulent otitis
  - c) facial nerve paralysis
  - d) internal purulent otitis
  - e) middle meningeal artery injuries
23. What are the indications for maxillary sinus trephination?
- a) **tumors**
  - b) **polyps**
  - c) **purulent inflammation of the of the sinus**
  - d) **presence of foreign bodies in trauma**
  - e) sinus lavage
24. The surgical procedure which consists in maxillary sinus trephination is:
- a) **Koldwell-Luc**
  - b) Olivecron
  - c) Killian
  - d) Vagner-Wolf
  - e) no answer is not correct
25. Performing spinal puncture will be present the blood in the cerebrospinal fluid, in case of?
- a) epidural hemorrhage
  - b) subdural hemorrhage
  - c) **subarachnoid hemorrhage**
  - d) bleeding from diploic vessels
  - e) bleeding from subcutaneous vessels



## NECK

- Choose the correct answer concerning the limits between neck and head:
  - inferior edge of the mandible, tip of the mastoid process, superior nuchal line, external occipital protuberance**
  - horizontal plane which passes through inferior edge of the mandible
  - frontal plane which passes through transverse processes of cervical vertebrae
  - horizontal plane which passes at the level of C<sub>7</sub> and sternal notch
  - horizontal plane which passes through sternal notch and superior edge of clavicle
- Borders of the medial triangle of the neck:
  - edge of mandibula, anterior edge of sternocleidomastoid muscle, middle line of the neck**
  - posterior belly of digastricus muscle, sternocleidomastoid muscle, middle line of the neck
  - edge of mandibula, sternocleidomastoid muscle, superior belly of omohyoid muscle
  - posterior belly of digastricus muscle, sternocleidomastoid muscle, inferior belly of the omohyoid muscle
  - horizontal line which on the level of hyoid bone, middle line of the neck, trapezius muscle
- Borders of the lateral triangle of the neck:
  - inferior edge of the mandibula, posterior border of sternocleidomastoid muscle, trapezius muscle
  - posterior belly of digastricus muscle, sternocleidomastoid muscle, trapezius muscle
  - inferior edge of the mandibula, sternocleidomastoid muscle, omohyoid muscle
  - clavicle, posterior edge of sternocleidomastoid muscle, trapezius muscle**
  - horizontal line traced on the hyoid bone, sternocleidomastoid muscle, trapezius muscle
- Indicate the elements of medial neurovascular bundle of the neck:
  - common carotid artery**
  - vagus nerve**
  - internal jugular vein**
  - vertebral a., hypoglossal n., external jugular v.
  - threocervical trunk, glosopharyngeal nerve, anterior jugular v.
- Indicate the elements of lateral neurovascular bundle of the neck:
  - subclavicular artery**
  - external carotid artery, phrenic nerve
  - subclavicular vein**
  - brachial plexus**
  - branches from cervical plexus, jugular vein
- Borders of the submandibular triangle:
  - inferior edge of mandible**
  - anterior edge of sternocleidomastoid muscle
  - superior belly of omohyoid muscle
  - both bellies of digastricus muscle**
  - free edge of mylohyoid muscle
- Borders of the carotid triangle:
  - posterior belly of digastricus muscle**
  - anterior edge of sternocleidomastoid muscle**
  - posterior edge of sternocleidomastoid muscle
  - inferior edge of the mandible
  - superior belly of omohyoid muscle**
- Limits of the omotrapezoid triangle:
  - superior edge of clavicle
  - trapezius muscle**
  - inferior belly of omohyoid muscle**
  - sternocleidomastoid muscle**
  - posterior belly of digastricus muscle
- What structures are situated in the suprasternal interaponeurotic space?
  - extern jugular veins
  - lymph nodes**
  - anterior jugular veins

- d) **anterior jugular venous arch**
  - e) anterior supraclavicular nerves
10. Indicate the limits of the prevertebral space:
- a) From the edge of mandible till manubrium sterni and clavicles
  - b) From the edge of mandible till the hyoid bone
  - c) **From the hyoid bone till the superior edge of sternum**
  - d) From the superior edge of the thyroid cartilage till manubrium sterni and clavicles
  - e) From the edge of the mandibula till the superior edge of the thyroid cartilage
11. Which cellular spaces of the neck communicates with the anterior mediastinum?
- a) Suprasternal interaponeurotic space
  - b) **Prevertebral cervical space**
  - c) Retrovertebral cervical space
  - d) Retropharyngeal space
  - e) **Paravascular space of the main neurovascular bundle of the neck**
12. Borders of the infrahyoid region:
- a) **hyoid bone and the posterior belly of digastric muscle**
  - b) **anterior edge of sternocleidomastoid muscle**
  - c) horizontal line traced on the level of thyroid cartilage
  - d) inferior edge of mandible
  - e) **sternum and clavicle**
13. Syntopy of the cervical portion of the trachea:
- a) **Anteriorly – thyroid gland isthmus**
  - b) **Anteriorly and bilaterally – thyroid gland lobes**
  - c) **Posteriorly - esophagus**
  - d) **At the level of jugular notch – common carotid arteries**
  - e) Internal carotid arteries
14. Indicate arteries that supply the thyroid gland:
- a) **Superior thyroid arteries**
  - b) **Inferior thyroid arteries**
  - c) Medium thyroid arteries
  - d) Recurrent thyroid artery
  - e) **Thyroid ima artery**
15. Lymphoepithelial pharyngeal ring is formed by:
- a) **Pharyngeal tonsils**
  - b) **Palatine tonsils**
  - c) **Tubal tonsils**
  - d) Submandibular tonsils
  - e) **Lingual tonsils**
16. Innervation of the cervical part of esophagus is provided by:
- a) **Vagus nerve**
  - b) Accessory nerve
  - c) **Cervical ganglia of the sympathetic trunk**
  - d) Hypoglossus nerve
  - e) **Recurrent nerves**
17. Indicate three possible levels of the common carotid artery bifurcation:
- a) **Superior border of C<sub>5</sub>**
  - b) Superior border of C<sub>6</sub>
  - c) **Superior border of thyroid cartilage**
  - d) At the level of cricoid cartilage
  - e) **Inferior border of C<sub>4</sub>**
18. Indicate differences between internal and external carotid arteries:
- a) **External carotid artery is positioned anteriorly and medially to the internal carotid artery**
  - b) **External carotid artery has branches but the internal carotid artery has no branches in the region of neck**

- c) **Internal carotid artery begins with a dilatation – carotid sinus**
  - d) **Pressure of the external carotid artery in wound stops pulsation of the superficial temporal artery on zygomatic arch**
  - e) Internal carotid artery gives rise to the superior thyroid artery
19. Carotid reflexogenic zone is situated:
- a) At the level of hyoid bone
  - b) At the level of superior border of thyroid gland
  - c) In the region of manubrium sterni
  - d) In the region of cricoid cartilage
  - e) **In the region of common carotid artery bifurcation**
20. Indicate the limits of interscalenic space:
- a) Sternothyroid muscle
  - b) **Anterior scalene muscle**
  - c) Posterior scalene muscle
  - d) Omohyoid muscle
  - e) **Medium scalene muscle**
21. What veins participate in the formation of the jugular venous angle?
- a) **Subclavicular vein**
  - b) **Internal jugular vein**
  - c) Anterior jugular vein
  - d) External jugular vein
  - e) Brachiocephalic vein
22. What structures are situated in the scalenovertebral triangle?
- a) **A. subclavia, thyriocervical trunk, a. vertebralis**
  - b) **Thoracic lymphatic duct**
  - c) Internal jugular vein
  - d) **Middle cervical ganglion of the sympathetic trunk**
  - e) **Inferior cervical ganglion of the sympathetic trunk**
23. Arterial branches from the subclavicular artery in the scalenovertebral triangle:
- a) **Vertebral artery**
  - b) Transverse cervical artery
  - c) Suprascapular artery
  - d) **Thyriocervical trunk**
  - e) **Internal thoracic artery**
24. Thoracic lymphatic duct drains into:
- a) Right subclavian artery
  - b) Right brachiocephalic vein
  - c) Right internal jugular vein
  - d) Left external jugular vein
  - e) **Left jugular venous angle**
25. Main routes of the pus spreading from the region of the neck are:
- a) **Posterior mediastinum**
  - b) Abdominal cavity
  - c) Retroperitoneal space
  - d) **Anterior mediastinum**
  - e) Pleural cavity
26. In which triangle is performed the ligature of the lingual artery?
- a) **Lingual triangle of Pirogov**
  - b) Carotid
  - c) Submandibular
  - d) Lateral triangle of the neck
  - e) Medial triangle of the neck

27. Borders of the omoclavicular triangle:
- Superior belly of the omohyoid muscle
  - Sternocleidomastoidian muscle**
  - Clavicle**
  - Inferior belly of the omohyoid muscle**
  - Median line of the neck
28. What is the syntopy of the stellate ganglion?
- Inferiorly – cupola of pleura**
  - Anteriorly – vertebral and subclavicular artery**
  - Vertebral nerve originates from it**
  - Medially – phrenic nerve
  - Posteriorly - the long cervical muscle**
29. Choose the structures that have sheath from the first superficial fascia of the neck:
- Sternocleidomastoid muscle
  - Submandibular gland
  - Parotid gland
  - Platysma m.**
  - Posterior belly of digastricus muscle
30. The projection of the carotic tubercle on the neck is:
- middle of the anterior margin of sternocleidomastoideus m.**
  - middle of the sternocleidomastoideus m. when the head is turned laterally
  - at the level of cricoid cartilage
  - middle of the sternocleidomastoideus m. when the head is in maximal extension
  - none of the answers
31. What can be palpated under the inferior margin of the mandible:
- submandibular gland**
  - lymphatic nodes**
  - carotic a.
  - lingual a.
  - hyoid bone
32. Which vessel intersects the sternocleidomastoidian muscle from the exterior:
- external jugular v.**
  - internal jugular v.
  - anterior jugular v.
  - jugular venous arch
  - thyroid ima v.
33. The projection of the vocal ligaments is at the level of:
- inferior margin of the thyroid cartilage**
  - hyoid bone
  - cricothyroid membrane
  - angle of the mandible
  - cricoid cartilage
34. Apex of the pleural cupola is projected:
- in the supraclavicular fossa**
  - in the infraclavicular fossa
  - incisura jugularis
  - does not come out of the thoracic boundaries
  - in the deltoideopectoral fossa
35. According to V. N. Şevkunenko how many cervical fascias we have:
- one
  - two
  - three
  - four
  - five**

36. Which fascias serve as boundary for the suprasternal interaponeurotic space:
- fascia superficialis colli and lamina superficialis of the fascia colli propria
  - superficial and deep lamina of the fascia colli propria**
  - omoclavicular aponeurosis and endocervical fascia
  - endocervical fascia and prevertebral fascia
  - visceral and parietal laminae of the endocervical fascia
37. The area of the retrovisceral cervical space is situated between:
- basis of the cranium and the diaphragm**
  - basis of the cranium and the hyoid bone
  - basis of the cranium and incisura jugularis
  - basis of the cranium and Th<sub>5</sub>
  - basis of the cranium and Th<sub>1</sub>
38. The prevertebral space is limited by:
- cervical vertebra and prevertebral fascia**
  - mm. longus capitis and prevertebral fascia
  - mm. longus colli and prevertebral fascia
  - lamina superficialis fasciae colli propriae and fascia prevertebralis
  - parietal and prevertebral fascias
39. The prevertebral space contains:
- mm. longus capitis**
  - mm. longus colli**
  - sympathetic trunk**
  - vagus n.
  - mm. splenius capitis
40. The external jugular vein forms at the confluence of:
- retromandibular v.**
  - posterior auricular v.**
  - facial v.
  - deep facial v.
  - angular v.
41. The cutaneous nerves of the neck can be found in the superficial layers at the level of:
- middle of the posterior margin of the sternocleidomastoidian m.**
  - middle of the anterior margin of the sternocleidomastoidian m.
  - angle of the mandible
  - hyoid bone
  - vertebra C<sub>3</sub>
42. The subcutaneous nerves of the neck are localized:
- subcutaneous
  - between the I and the II fascia**
  - between the II and the III fascia
  - between the I and the III fascia
  - none of the answers
43. Which cervical fascia forms a fascial sheath for the submandibular gland:
- I fascia
  - II fascia**
  - III fascia
  - IV fascia
  - V fascia
44. Where do the sheaths of the II cervical fascia which form a capsule for the submandibular gland fix:
- inferior margin of the mandible**
  - linea mylohyoidea**
  - superior margin of the mandible
  - body of the hyoid bone
  - submandibular duct

45. What are the limits of the lingual triangle (Pirogov)?
- superior - hypoglossus n.**
  - inferior - intermedial tendon of the digastric m.**
  - medial - free margin of the mylohyoideus m.**
  - superior - lingual n.
  - anterior - free margin of the hyoglossus m.
46. The floor of the lingual triangle (Pirogov) is formed by:
- hyoglossus m.**
  - mylohyoid m.
  - digastric m.
  - deep lamina of the II fascia
  - stylohyoid m.
47. Which branch is the lingual artery from its origin - external carotid artery:
- lingual a. is the first branch
  - lingual a. is the second branch**
  - lingual a. is the third branch
  - lingual a. is the fourth branch
  - does not originate from the external carotid artery
48. Which fascias participate at the formation of linea alba colli:
- I fascia
  - II fascia**
  - III fascia**
  - IV fascia
  - V fascia
49. For which muscles the omoclavicular aponeurosis forms a fascial sheath:
- pretraheal mm.**
  - prevertebral mm.
  - suprahyoid mm.
  - scalen mm.
  - submandibular mm.
50. Which nerves enervate the pretraheal muscles:
- cervical loop**
  - vagus n.
  - phrenic n.
  - n. recurrens dexter
  - ganglion stellatum
51. What is the syntopy of the elements of the main neurovascular bundle of the neck:
- medial - a. carotis communis, lateral - v. jugularis interna, between the vein and the artery and posterior -vagus n**
  - lateral - a. carotis communis, medial - v. jugularis interna, between the vessels -vagus n.
  - medial - a. carotis communis, between the artery and nerve - v. jugularis interna, lateral - vagus n.
  - between v. jugularis interna and vagus n.- a. carotis communis, medial -vagus n.
  - lateral - a. carotis communis, between the artery and nerve - v. jugularis interna
52. What is the origin of the subclavicular arteries:
- right - from the brachiocephalic arterial trunk, left - aortic arch**
  - left - from the brachiocephalic arterial trunk, right - aortic arch
  - left - from the brachiocephalic trunk, right - brachiocephalic arterial trunk
  - left - aortic arch, right - aortic arch
  - none of the answers
53. In what cases is affected the interaponeurotic suprasternal space:
- in case of purulent myositis**
  - in case of osteomyelitis of sternal manubrium**

- c) in case of osteomyelitis of the clavicles
  - d) in case of trachea diseases
  - e) in case of larynx damage
54. In what cases is affected the previsceral space from cervical region
- a) in the case of diseases of the farynx
  - b) in case of diseases of the trachea**
  - c) in case of diseases of the larynx**
  - d) in case of diseases of the esophagus
  - e) in the case of diseases of the thyroid gland**
55. In what cases is affected the retrovisceral space?
- a) tiroide gland lesions
  - b) the trachea lesions
  - c) in the lesions of the larynx
  - d) in the cervical segment of the thoracic duct injuries
  - e) injury (iatrogenic, post-combustion) of the esophagus**
56. What separates the previsceral space from the anterior mediastinum?
- a) deep fascia
  - b) omoclavicular fascia
  - c) deep tab of the own throat fascia
  - d) parietal blade moving in the visceral endocervical fascia (being penetrated by vessels and nerves)**
  - e) prevertebral fascia
57. In what cases is affected sternocleidomastoid m cellular tissue sheath space?
- a) in some types of mastoiditis**
  - b) in purulent myositis**
  - c) in purulent affecting of the parotid gland
  - d) in purulent diseases of the submandibular gland
  - e) in thymic diseases
58. Which of the following statements concerning the area of superficial cellular tissue located in lateral triangle of the neck are correct?
- a) is disposed between the II and III fascia
  - b) is disposed between the II and V fascia within omotrapezoidian triangle**
  - c) is disposed between the III and V fascia within the omoclavicular triangle**
  - d) on the path of suprascapular artery communicates with the deep spaces of scapular region**
  - e) on the trajectory of lateral neurovascular bundle items of the neck communicates with axillary cavity
59. Which of the following statements concerning the area of cellular tissue located in deep lateral triangle of the neck are correct?
- a) is disposed between the II and III fascia
  - b) is disposed between the fascia II and V within omotrapezoidian triangle
  - c) is deeper disposed to V fascia around the lateral neurovascular bundle neck elements**
  - d) on the path of suprascapular artery communicates with the deep spaces of scapular region
  - e) on the path of lateral neurovascular bundle elements of the neck communicates with axillary cavity**
60. Read the following statements carefully and enumerate the correct ones:
- a) accessor n penetrates II fascia 1.5 cm higher of the middle of posterior edge of the sternocleidomastoid m**
  - b) accesor n within the lateral triangle limits of the neck is located on. levator scapula muscle**
  - c) tumors localized in the lateral triangle of the neck can compress the cervical plexus branches accompanied by pain radiating in all directions**
  - d) common carotid artery pulsation can be palpate between the front edge of the sternocleidomastoid m and cervical viscera**
  - e) subclavian artery passes through antescalen space
61. Which of the following statements about topography of the superior laryngeal nerv are correct?
- a) move within the carotid triangle**
  - b) passes posterior to the basics element of the medial neurovascular bundle of the neck, oblique from top to bottom**

- c) **branches into external branch (which along with another branch of the vagus n forming n tion - n depressant cordis) and internal branch**
- d) **is a branch of the vagus nerv**
- e) passes anterior to the basics element of the medial neurovascular bundle of the neck
62. In case of surgical interventions on thyroid gland ,which nerve can be damaged?
- a) recurrent laryngeal n
- b) **inferior laryngeal n**
- c) superior laryngeal n
- d) vagus n
- e) sympathetic trunk
63. Which of the following statements are correct about the topography of cervical loop (cervical ansa)?
- a) **superior branch descends into composition of hypoglossal nerve, from which emerges in limits of the carotid triangle**
- b) **superior branch starts from II cervical spinal nerve**
- c) **inferior branch start from. III and IV cervical nerves**
- d) **innervate pretracheal groups muscle so it is a motor branch**
- e) is a sensory branch
64. Which of the following statements about the topography of the cervical sympathetic trunk are correct?
- a) **has superior and inferior nodes (permanent), medium and intermediar (non-permanent)**
- b) **is mostly located deeper of V fascia on prevertebral muscles**
- c) **superior ganglion is located at the level of transverse processes of the cervical II-III vertebrae**
- d) **medium ganglion, intermediar and inferior are located in limits of the scalenovertebral triangle**
- e) medium ganglion, intermediar and inferior are located in limits of the interscalen area
65. The following triad of symptoms: miosis, narrowing of the palpebral fissure and enophthalmos may occur at:
- a) damage of vagus nerve in the cervical region
- b) damage of hypoglossal nerve
- c) **damage of sympathetic trunk (cervical spine trauma, compression by tumors in the cervical region)**
- d) damage of phrenic nerve
- e) damage of superior and inferior laryngeal nerves
66. During surgical intervention on the thoracic duct in limit of the cervical region can be injured:
- a) vague n
- b) inferior laryngeal n
- c) recurrent laryngeal n
- d) **phrenic n**
- e) sympathetic trunk
67. In what cases is affected deep space of adipos cellular tissue (deeper the V fascia)?
- a) in case of trachea damage
- b) **in case of tuberculous disease of the cervical vertebrae (cold abscess)**
- c) in case of esophagus damage
- d) in case of myositis
- e) in case of larynx damage
68. Limits of submandibular triangle:
- a) **the inferior border of the mandible**
- b) milohioid muscle
- c) strenocleidomastoidian muscle
- d) **anterior and posterior belly of digastric muscle**
- e) hyoid bone
69. Fascia No.3 of the neck is called:
- a) endocervical fascia
- b) submandibular fascia
- c) **omoclavicular fascia**
- d) fascia propria
- e) superficial fascia



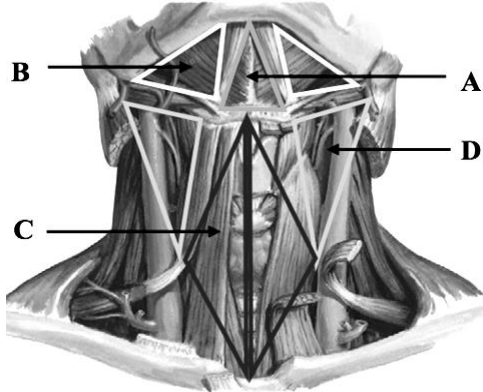
70. Submandibular gland bag contains:
- a) **submandibular gland**
  - b) **facial artery and v.**
  - c) trigeminal nerve
  - d) lingual artery
  - e) thyroid arteries
71. Boundaries of sternocleidomastoid region are:
- a) anterior edge of the trapezius muscle
  - b) the inferior edge of the mandible
  - c) the superior edge of the clavicle
  - d) **correspond to the sternocleidomastoid muscle**
  - e) the superior edge of the manubrium sterni
72. Extra lobe of the thyroid gland is called:
- a) **pyramidal lobe**
  - b) basal lobe
  - c) parathyroid lobe
  - d) tracheal lobe
  - e) lingual lobe
73. The esophagus begins at the vertebra:
- a) C<sub>3</sub>
  - b) C<sub>2</sub>
  - c) C<sub>7</sub>
  - d) **C<sub>6</sub>**
  - e) C<sub>5</sub>
74. Superficial fascia after Shevkunenکو classification is located between:
- a) skin and subcutaneous fat tissue
  - b) **skin and the second fascia**
  - c) platysma muscle and sternocleidomastoid muscle
  - d) sternocleidomastoid muscle and the anterior scalene muscle
  - e) sternocleidomastoid muscle and common carotid artery
75. Superficial lamina of fascia propria of the neck forms a sheath for:
- a) **submandibular gland**
  - b) platysma muscle
  - c) sternotiroid muscle
  - d) common carotid artery
  - e) the internal jugular vein
76. Visceral sheet of neck fascia covers the following formations:
- a) **parotiroide glands**
  - b) **recurrent laryngeal nerve**
  - c) **esophagus**
  - d) submandibular gland
  - e) **thyroid gland**
77. Suprasternal interaponeurotic cellular space contains:
- a) common carotid artery
  - b) internal jugular vein
  - c) external jugular vein
  - d) **jugular venous arch (juguli venous arch)**
  - e) aortic arch
78. Subcutantat cellular tissue in limits of the carotid triangle contains:
- a) platysma muscle
  - b) **external jugular vein and cervical plexus branches**
  - c) the internal jugular vein
  - d) facial vein
  - e) descending branch of the nerve sublingual

79. The vagus nerve in relation to carotid artery in the region of carotid triangle is situated:
- anterior and medial
  - posterior and medial
  - anterior and lateral
  - d) posterior and lateral**
  - between the artery and vein
80. In limits of submandibular triangle posterior of platysma muscle there is:
- inframandibular nerve
  - sublingual nerve
  - lingual nerve
  - d) facial nerve (cervical branch)**
  - cervical plexus
81. In omoclavicular triangle the external jugular vein is situated in:
- subcutaneous adipose tissue
  - the thickness of the platysma muscle
  - prevertebral fascia
  - d) deep lamina of superficial fascia**
  - none of the above variants
82. **In the omoclavicular triangle the phrenic nerve is situated between:**
- superficial and deep sheet of the deep fascia
  - b) anterior scalene muscle and prevertebral fascia**
  - anterior and medium scalene muscle
  - medial and posterior scalene muscle
  - superficial fascia and deep fascia
83. Scheletotopic larynx corresponds to cervical vertebrae:
- C<sub>2</sub> - C<sub>4</sub>
  - C<sub>1</sub> - C<sub>3</sub>
  - C<sub>3</sub> - C<sub>4</sub>
  - d) C<sub>5</sub> - C<sub>6</sub>**
  - C<sub>7</sub> - C<sub>8</sub>
84. Posterior to trachea adheres intimately the following organ:
- a) cervical portion of the esophagus**
  - pharynx with pharyngeal lobe of the parotid gland
  - common carotid artery
  - impair thyroid venous plexus
  - cervical vertebrae
85. Pretracheal cellular space of the neck region communicates with the cellular space of:
- intraponeurotic suprasternal space
  - b) anterior mediastinum**
  - posterior mediastinum
  - retroesofagian
  - none of the above variants
86. Lingual artery ligation in the Pirogov triangle:
- a) provides postlesional intraoperative hemostasis**
  - b) is used in lingual neoplasm resection**
  - contribute to decrease the organ in volume
  - is not used lingual artery ligation in the lingual triangle
  - all answers are correct
87. Innervation of Carotid sinus (Hering n) is achieved by:
- mandibular n
  - short and long ciliary n.
  - vagus n
  - d) glossopharyngeal n**
  - sphenopalatin n

88. Major clinical sign of laryngeal recurrent nerve damage is:
- loss of appetite
  - dysphagia
  - dyspnoea
  - aphonia**
  - euphoria
89. The afonia cause in the recurrent laryngeal n lesion:
- reflector spasm of the vocal cords
  - vocal muscle paresis**
  - epiglottis contracture
  - regurgitation of food with aspiration
  - acute laryngeal dilatation
90. Branches of subclavian artery in the prescalen segment are:
- vertebral artery**
  - transverse coli artery
  - internal thoracic artery**
  - costocervical trunk
  - tireocervical trunk**
91. Branches subclavian artery in the interscalen segment are:
- vertebral artery
  - transvera coli artery
  - internal thoracic artery
  - costocervical trunk**
  - tireocervical trunk
92. Branches subclavian artery in the interscalen segment are:
- vertebral artery
  - transvera coli artery**
  - internal thoracic artery
  - costocervical trunk
  - tireocervical trunk
93. The major risk of wounds with cervical localization is conditioned by:
- presence of main (magistral) arterial trunk**
  - the negative pressure in the venous system at this level**
  - lymphatic lesion of magistral pathways
  - the possibility of diffusion of the inflammatory process to the mediastinum**
  - veins ambience due to parietal fixing through fascia**
94. Central venous abord is done by catheterization of:
- anterior jugular v.
  - external jugular v.
  - internal jugular v.**
  - jugular venous arch
  - subclavian v.**
95. What fascia forms the sternocleidomastoid and trapezoid muscles sheath:
- superficial fascia
  - superficial lamina of the fascia colli propria**
  - deep lamina of the fascia colli propria
  - endocervicalis fascia
  - prevertebralis fascia
96. Which of the cervical fascia form sheath for infrahyoid muscles:
- superficial fascia
  - superficial lamina of the fascia colli propria
  - deep lamina of the fascia colli propria**
  - fascia endocervicalis
  - fascia prevertebralis

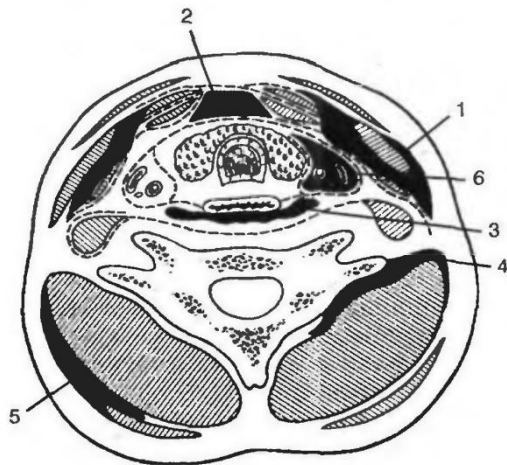
97. The highest vascularization index organ (5ml/min/g) is:
- myocardium
  - thymus
  - brain tissue
  - thyroid**
  - parathyroid

98. Indicate the correct order of following triangles:



- submental, submandibular, omotracheal, carotid**
- submandibular, submental, omotracheal, carotid
- omotracheal, submental, submandibular, carotid
- carotid, submental, submandibular, omotracheal
- submental, submandibular, omotracheal, lingval

99. Name typical cellular space which can be affected by purulent process on the neck in appropriate order :



- phlegmon of sternocleidomastoid m. sheath, previsceral phlegmon, retroesophageal phlegmon, deep phlegmon in posterior part of the neck, superficial phlegmon in posterior part of the neck, phlegmon of medial neurovascular bundle of the neck**
- previsceral phlegmon, phlegmon of sternocleidomastoid m. sheath, retroesophageal phlegmon, deep phlegmon in posterior part of the neck, superficial phlegmon in posterior part of the neck, phlegmon of medial neurovascular bundle sheath of the neck
- retroesophageal phlegmon, phlegmon of sternocleidomastoid m. sheath, previsceral phlegmon, deep phlegmon in posterior part of the neck, superficial phlegmon in posterior part of the neck, phlegmon of medial neurovascular bundle sheath of the neck
- deep phlegmon in posterior part of the neck, phlegmon of sternocleidomastoid m. sheath, previsceral phlegmon, retroesophageal phlegmon, superficial phlegmon in posterior part of the neck, phlegmon of medial neurovascular bundle sheath of the neck
- phlegmon of sternocleidomastoid m. sheath, previsceral phlegmon, retroesophageal phlegmon, phlegmon of medial neurovascular bundle sheath of the neck, deep phlegmon in posterior part of the neck, superficial phlegmon in posterior part of the neck,

## NECK SURGERY

- The most common site of superficial phlegmons of the neck is:
  - submandibular space
  - subcutaneous fatty tissue**
  - previsceral space
  - retrovisceral space
  - prevertebral space
- What are the requirements for incisions performed on the neck:
  - adequate operative access**
  - the dissection of the tissues is performed layer by layer, fasciae and cellular spaces are used as reference points**
  - cosmetic result**
  - considering the compact topographic position of the organs**
  - all of the above answers are false
- Mark the recommended incisions on the neck:
  - vertical**
  - oblique**
  - transversal**
  - combined**
  - circular
- Where the inflammatory process from the neck may spread?
  - in the posterior mediastinum**
  - in the abdominal cavity
  - in the retroperitoneal space**
  - in the superior mediastinum**
  - in the pleural cavity
- Choose the adequate incision in case of submandibular triangle phlegmon:
  - the upper 1/3 of the anterior margin of sternocleidomastoidian muscle
  - 1 cm medially and parallel to the inferior margin of mandibula**
  - from mentum to angle of mandibula
  - along the angle of mandibula
  - transversal access, parallel to hyoid bone
- Choose the incision made in case of phlegmon spreading to the lateral triangle of the neck:
  - on posterior margin of the sternocleidomastoidian muscle**
  - on posterior margin of the trapezoid muscle
  - from acromion to the angle formed by trapezoid muscle and sternocleidomastoidian muscle
  - infraclavicular incision
  - superior and parallel to clavicle
- Choose the cosmetic incisions made in case of phlegmon in the previsceral space of the neck:
  - transversal**
  - longitudinal on median line
  - oblique
  - combined
  - tie-shaped incision**
- Choose the incision made in case of phlegmon in the retrovisceral space of the neck:
  - transversal incision
  - longitudinal on median line
  - tie-shaped incision
  - on posterior margin of sternocleidomastoidian muscle
  - on anterior margin of sternocleidomastoidian muscle**
- Choose the adequate approach for opening and drainage of retropharyngeal abscess:
  - On median line
  - through oral cavity**
  - tie-shaped incision

- d) combined
  - e) on posterior margin of sternocleidomastoid muscle
10. Name the triangle where lingual artery can be ligated:
- a) **lingual triangle**
  - b) carotid triangle
  - c) submandibular triangle
  - d) lateral triangle of the neck
  - e) medial triangle of the neck
11. Choose the incision made for ligation of the common carotid artery:
- a) transversal incision, from superior margin of thyroid gland
  - b) **anteriorly to sternocleidomastoid muscle, from the upper margin of thyroid cartilage, 5-6 cm inferiorly**
  - c) on anterior margin of sternocleidomastoid muscle, from the angle of mandibula
  - d) from superior margin of thyroid gland, on posterior margin of sternocleidomastoid muscle
  - e) on inferior margin of posterior belly of digastric muscle
12. Choose the incision made for ligation of the external carotid artery:
- a) transversal incision, from superior margin of thyroid gland
  - b) on anterior margin of sternocleidomastoid muscle, from superior margin of thyroid cartilage
  - c) **on anterior margin of sternocleidomastoid muscle, from angle of mandibula inferiorly**
  - d) on posterior margin of sternocleidomastoid muscle, from superior margin of thyroid gland
  - e) on inferior margin of posterior belly of digastric muscle
13. Choose the level of ligation of external carotid artery:
- a) between the lingual and facial artery
  - b) **between the lingual and superior thyroid artery**
  - c) proximally to lingual artery
  - d) proximally to facial artery
  - e) distally to superior thyroid artery
14. Mark the surgical procedures on the upper airways of extreme emergency:
- a) **coniotomy**
  - b) **cricoconiotomy**
  - c) tracheotomy
  - d) tracheostomy
  - e) percutaneous tracheostomy
15. Mark the urgent surgical interventions on the upper airways:
- a) coniotomy
  - b) cricoconiotomy
  - c) **tracheotomy**
  - d) **tracheostomy**
  - e) **percutaneous tracheostomy**
16. The indications for tracheostomy are:
- a) **laryngeal or tracheal oedema**
  - b) **laryngeal or tracheal stenosis due to inflammatory process**
  - c) **pseudocroup and foreign bodies in the larynx**
  - d) **traumatic brain injury**
  - e) tracheoesophageal fistula
17. What should be the length of the incision on the trachea during a tracheostomy?
- a) **it corresponds to the diameter of tracheostomy tube**
  - b) it corresponds to the diameter of wound retractor
  - c) it corresponds to the diameter of aerophore tube
  - d) it corresponds to the diameter of Trousseau tracheal dilator
  - e) it corresponds to the diameter of bronchoscope
18. Possible complications of tracheostomy are:
- a) **Injury of the neighboring formations**
  - b) **Introducing the cannula for tracheostomy in the submucosal space**

- c) **Injury of the posterior wall of the trachea**
  - d) **Marginal necrosis, subcutaneous emphysema**
  - e) Vocal cord Injury
19. What are the indications for conicotomy?
- a) presence of a foreign body in the right bronchus
  - b) **presence of a foreign body in the upper airways**
  - c) presence of a foreign body in the left bronchus
  - d) cancerous affection of the larynx
  - e) inflammatory disease of the larynx and trachea
20. What are the types of tracheostomy?
- a) **Superior**
  - b) Middle
  - c) **Inferior**
  - d) Liniar
  - e) Paramedian
21. Why in children is performed more frequently lower tracheostomy?
- a) underdevelopment of the upper tracheal rings
  - b) **position of the thyroid isthmus is more proximal**
  - c) underdevelopment of the thyroid isthmus
  - d) position of the thyroid isthmus is more distal
  - e) persistence of the thymus
22. What is the predilection place for the introduction of needle in subclavian vein puncture in adults (Aubaniac procedure)?
- a) point between lateral and middle third of the clavicle on the inferior edge
  - b) point between lateral and middle third of the clavicle on the superior edge
  - c) point between lateral and middle third of the clavicle with 1 cm below the inferior edge
  - d) **point between median and middle third of the clavicle with 1 cm below**
  - e) point that corresponds to the sternoclavicular joint
23. Possible complications of the subclavian vein catheterization are:
- a) **hydro- or pneumothorax**
  - b) **subclavian artery puncture**
  - c) **air embolism**
  - d) **brachial plexus injury**
  - e) cephalic vein injury
24. What cervical veins except subclavian vein can be catheterized?
- a) **external jugular vein**
  - b) **internal jugular vein**
  - c) superior thyroid vein
  - d) anterior jugular vein
  - e) lingual vein
25. Puncture of the cervical veins is accompanied by the risk of:
- a) **bleeding**
  - b) **air embolism due to negative venous pressure**
  - c) fat embolism
  - d) infection
  - e) **common carotid artery injury**

## THORACIC CAVITY

- Thoracic cavity is delimited by:
  - ribs, sternum, vertebral column and superior domes of the pleura
  - space between aperture thoracic superior and diaphragm
  - ribs, sternum, vertebral column and diaphragm**
  - space between intercostal muscles and diaphragm
  - space between aperture thoracic superior and anterior
- What does the pleural cavity represent?
  - Cavity that is delimited by the visceral and parietal pleura**
  - Space between lungs and mediastinum
  - Cavity between lungs, diaphragm and mediastinum
  - Cavity delimited by the sheaths of the parietal pleura
  - It is a part of the thoracic cavity where the magistral vessels pass
- Which statements are correct concerning the lymphatic drainage from the mammary gland?
  - There is superficial and deep lymphatic reflux**
  - Parasternal lymphatic nodes receive lymph from the axillary lymph nodes
  - Lymph node of Zorgius that lays at the edge of the pectoral major muscle is a sentinel node of the first step**
  - From the internal-superior quadrat the lymph reaches the epigastric ganglions
  - Main collectors of lymph are the axillary lymph nodes**
- Venous system of mammary gland is composed by:
  - Superficial venous rete**
  - Deep venous rete**
  - Intercostal venous rete
  - Subclavian venous rete
  - Axillary venous rete
- Which fascia forms the capsule for the mammary gland?
  - Superficial lamina of pectoral fascia
  - Clavipectoral fascia
  - Superficial fascia**
  - Transversal fascia
  - Coracoclavicopectoral fascia
- Which arteries supply the mammary gland?
  - Internal thoracic artery**
  - Lateral thoracic artery**
  - Intercostal arteries**
  - Epigastric superior artery
  - Subclavian artery
- Mammary gland is innervated by:
  - Branches of the II-VII intercostal nerves**
  - Branches of cervical plexus**
  - Anterior branches of the brachial plexus**
  - Phrenic nerves
  - Vagus nerves
- How is called the deep lamina of pectoral fascia:
  - Coracoclavicopectoral fascia**
  - Gruber`s fascia**
  - Endocervical fascia
  - Clavipectoral fascia**
  - Axillary fascia
- The fascial sheath of which muscle is formed by the coracoclavipectoral fascia:
  - Major pectoral muscle



- b) **Minor pectoral muscle**
  - c) Seratus anterior muscle
  - d) Deltoid muscle
  - e) Intercostal muscles
10. Superficial subpectoral space is placed:
- a) **Behind the major pectoral muscle**
  - b) **In front of the clavipectoral fascia and minor pectoral muscle**
  - c) Behind the fascia superficialis
  - d) In front of deep fascia
  - e) In the subcutaneous fatty tissue
11. Deep subpectoral space is placed:
- a) In front of the major pectoral muscle
  - b) Behind the major pectoral muscle
  - c) In front of the minor pectoral muscle
  - d) **Behind the minor pectoral muscle**
  - e) Behind subclavian muscle
12. Which of the following sinuses of the pleural cavity is the deepest?
- a) **Costodiaphragmatic sinus**
  - b) Costomediastinic sinus
  - c) Diaphragmmediastinic sinus
  - d) Costal sinus
  - e) Mediastinal sinus
13. Space between the sternal part and costal part of the diaphragm on the right side is named?
- a) Triangle of Pirogov
  - b) Triangle of Larey
  - c) **Triangle of Morganye**
  - d) Triangle of Bohdalec
  - e) Triangle of Ghesselbach
14. Space between the sternal part and costal part of the diaphragm on the left side is named?
- a) Triangle of Pirogov
  - b) **Triangle of Larey**
  - c) Triangle of Morganye
  - d) Triangle of Bohdalec
  - e) Triangle of Ghesselbach
15. Diaphragm is vascularized by:
- a) **musculophrenic arteries**
  - b) **intercostal arteries**
  - c) **superior phrenic arteries**
  - d) **inferior phrenic arteries**
  - e) superior epigastric artery
16. Main respiratory muscle is:
- a) M. rectus abdominis
  - b) M. obliquus abdominis externus
  - c) M. obliquus abdominis internus
  - d) mm. intercostales
  - e) **Diaphragm**
17. All of the mentioned below refer to congenital anomalies of the heart, excepting:
- a) Persistence of the duct of Botallo
  - b) Interatrial sept undevelopment
  - c) Dextro-position of the heart
  - d) **Rheumatic mitral stenosis**
  - e) Interventricular septum underdevelopment
18. In the azygos vein flows:
- a) **hemiazygos v.**

- b) Left intercostal veins
  - c) **Esophageal veins**
  - d) **Posterior bronchial veins**
  - e) **Mediastinal veins**
19. To which rib corresponds the sternal angle (Ludovic):
- a) I
  - b) **II**
  - c) III
  - d) IV
  - e) V
20. In the intercostal fissure are situated:
- a) superficial and deep intercostal muscles
  - b) **intercostals artery**
  - c) **intercostal vein**
  - d) **intercostals nerve**
  - e) endothoracic fascia
21. Syntopy of the intercostal neurovascular bundle from superior to inferior:
- a) superior - intercostal a., inferior - nerve and more inferior - vein
  - b) superior - nerve, inferior - vein and more inferior - intercostal artery
  - c) **superior - vein, inferior - intercostals artery and more inferior - nerve**
  - d) the nerv is situated more medial, vessels - more lateral
  - e) lateral is situated the nerv, medial - vessels
22. What represents the pulmonary ligament:
- a) Ligament that connects the right lung with the left lung
  - b) Ligament between the pulmonary artery and vein
  - c) **Double fold of visceral pleura extending from the pulmonary hilum toward diaphragm**
  - d) Duplication of the parietal pleura in which are placed the pulmonary vessels
  - e) Ligament between the aortic arch and the pulmonary artery
23. At the level of what rib can be found the inferior border of the right lung:
- a) V<sup>th</sup> rib - on the medioclavicular line
  - b) X<sup>th</sup> rib - on the anterior axillar line
  - c) X<sup>th</sup> rib - on the scapular line
  - d) **XI<sup>th</sup> rib - on the paravertebral line**
  - e) IX<sup>th</sup> rib - on the posterior middle line
24. What element intersects from posterior the right bronchus:
- a) right ventricle
  - b) internal thoracic a.
  - c) superior vena cava
  - d) left atrium
  - e) **azygos vein**
25. Syntopy of the right pulmonary root components from superior to inferior:
- a) Artery, bronchus, vein
  - b) Bronchus, vein, artery
  - c) Vein, artery, bronchus
  - d) **Bronchus, artery, vein**
  - e) Artery, vein, bronchus
26. What intersects the left bronchus from posterior:
- a) **descendent aorta**
  - b) **left vagus nerve**
  - c) left phrenic nerve
  - d) hemiazygos vein
  - e) left pulmonary vein
27. What branches originate from the arch of aorta from right to left?
- a) Right common carotid artery, right suclavicular artery

- b) Left common carotid artery, left subclavicular artery
  - c) **Arterial brachiocephalic trunk, left common carotid artery, left subclavicular artery**
  - d) Left subclavicular artery, left common carotid artery, ima a.
  - e) Right common carotid artery, left common carotid artery, left subclavicular artery.
28. What nerve crosses the arch of aorta from anterior?
- a) Right phrenic nerve
  - b) Right vagus nerve
  - c) Left phrenic nerve
  - d) Left splanchnic nerve
  - e) **Left vagus nerve**
29. Where is situated the arterial canal of Botallo?
- a) Between aorta and superior vena cava
  - b) Between inferior vena cava and aorta
  - c) **Between pulmonary artery and arch of aorta**
  - d) Between the right auricle and superior vena cava
  - e) Between the left common carotid artery and subclavian artery
30. At what level right and left recurrent laryngeal nerves start?
- a) **Right – at the level of right subclavian artery**
  - b) Left – at the level of left brachiocephalic trunk
  - c) **Left – at the level of aortic arch**
  - d) Right – at the level of trachea bifurcation
  - e) Left and right – at the level of IV cervical vertebra
31. Where does the right phrenic nerve superiorly to the pulmonary hilum pass?
- a) Between aorta and superior vena cava
  - b) Between the superior vena cava and right common carotid artery
  - c) **Between superior vena cava and mediastinal pleura**
  - d) Between the brachiocephalic trunk and superior vena cava
  - e) Anterior to the arch of aorta
32. Anterior the trachea and manubrium sterni are placed:
- a) **left common carotid artery**
  - b) left subclavian a. and left phrenic n.
  - c) **left brachiocephalic vein**
  - d) recurrent laryngeal nerve
  - e) **arch of aorta with brachiocephalic trunk**
33. What passes immediately posterior from the right bronchus
- a) **Azygos vein and right vagus nerve**
  - b) Right pulmonary artery
  - c) Right pulmonary vein
  - d) Sympathetic trunk
  - e) Inferior vena cava
34. What criteria correspond to the pulmonary arteries?
- a) Deliver oxygenated blood to the heart
  - b) Deliver oxygenated blood to the lungs
  - c) **Deliver unoxygenated blood from the the heart to the lungs**
  - d) **Are parallel to the bronchi**
  - e) Vascularize the pulmonary parenchyma till the alveolas
35. Anterior mediastinum contains everything, **EXCEPT**:
- a) Thymus
  - b) Ascending aorta and arch of aorta
  - c) Brahiocefalic trunk, common carotid artery and left subclavicular artery
  - d) **thoracic lymphatic duct**
  - e) trachea
36. Posterior mediastinum contains the following, **EXCEPT**:
- a) esophagus

- b) descending aorta
  - c) thoracic lymphatic duct
  - d) pulmonary hilum, bifurcation of the trachea, arch of aorta**
  - e) azygos and hemiazygos veins
37. Posterior mediastinum contains:
- a) Azygos vein and sympathetic trunks**
  - b) Thoracic lymphatic duct, thoracic aorta, hemiazygos vein, intercostal vessels**
  - c) Esophagus and vagus nerves**
  - d) Pulmonary arteries and veins
  - e) Inferior vena cava and portal vein
38. Deviation of esophagus in the thoracic part, at the level of V-th thoracic vertebra:
- a) To left
  - b) To right**
  - c) Posterior
  - d) Anterior
  - e) Localized strictly on the median line, anterior of the vertebral column
39. On the level of which vertebra esophagus intersects the aorta from anterior:
- a) Th<sub>3</sub>
  - b) Th<sub>5</sub>
  - c) Th<sub>6</sub>
  - d) Th<sub>7</sub>
  - e) Th<sub>8</sub>**
40. Venous reflux from the inferior 1/3 of the esophagus directed to:
- a) Vena cava inferior
  - b) Vena cava superior
  - c) Azygos and hemiazygos veins**
  - d) Left gastric vein**
  - e) Portal vein
41. Lymphatic thoracic duct passes through:
- a) Esophageal opening of the diaphragm
  - b) Aortal opening of the diaphragm**
  - c) Costo-lumbar triangle of the diaphragm
  - d) Inferior vena cava opening
  - e) Vena azygos opening
42. How many narrowings does the esophagus have:
- a) a single narrow
  - b) two narrowings
  - c) three narrowings**
  - d) four constrictions
  - e) does not have narrow places
43. Which organ lesion is a criterion for a thoraco-abdominal trauma?
- a) Lung
  - b) Liver
  - c) Spleen
  - d) Diaphragm**
  - e) Heart and pericardium
44. What nerve crosses aorta from inferior and ascends in cranial direction?
- a) right frenic n.
  - b) left vagus n
  - c) the right recurrent laryngeal n
  - d) the sympathetic trunk
  - e) the left recurrent laryngeal n.**
45. Which statement is correct concerning the stratigraphy of the chest wall?

- a) skin, subcutaneous cellular layer, superficial fascia., external intercostal muscle, neuro-vascular bundle, internal intercostal muscle., fascia endotoracica, prepleural tissue, visceral pleura.
- b) skin, subcutaneous cellular layer, superficial fascia, fascia propria, external intercostal muscle, neuro-vascular bundle, internal intercostal muscle, fascia endotoracica, prepleural tissue, parietal pleura.**
- c) skin, subcutaneous cellular layer, superficial fascia, fascia propria, external intercostal muscle, vasculo-nervous bundle., subcostal muscle, fascia endotoracica, prepleural tissue, pleura.
- d) skin, subcutaneous cellular layer, superficial fascia, fascia propria, external intercostal muscle, vasculo-nervous bundle., internal intercostal muscle, fascia endocervical, prepleural tissue, visceral pleura.
- e) skin, subcutaneous cellular layer, fascia superficialis, fascia propria, external intercostal muscle., vasculo-nervous bundle, internal intercostal muscle., endotoracica fascia, preperitoneal tissue, pleura.
46. Which nerves enervate the diaphragm:
- a) **phrenic nn.**
- b) **branches from vagus and sympathetic nn.**
- c) **6 pairs of inferior intercostals nn.**
- d) branches of the lumbar plexus
- e) infraclavicular nn.
47. What are the internal thoracic artery branches?
- a) **pericardophrenic a.**
- b) **superior epigastric a.**
- c) **musculophrenic a.**
- d) **mediastinal branches**
- e) superior diaphragmatic aa.
48. What is the terminal branch of the internal thoracic artery?
- a) artery pericardiacofrenică
- b) superior epigastric artery**
- c) **musculophrenic artery**
- d) mediastinal branches
- e) superior diaphragmatic artery
49. Which of the following statements about the toracoacromial trunk are correct:
- a) toracoacromial arterial trunk starts from the subclavian a.
- b) toracoacromial trunk is a branch of the axillar a.**
- c) toracoacromial trunk penetrates the coracoclavipectoral fascia**
- d) penetrates into the superficial subpectoral fatty tissue space**
- e) gives pectoral, acromial and deltoid branches**
50. Which of the following statements about the costodiaphragmatic sinus are WRONG:
- a) is formed between the vertebral column and ribs
- b) extends from the sternum till the ribs
- c) as a rule the lung enters this sinus at a deep inspiration**
- d) it is formed as a result of passing costal pleura into the diaphragmatic pleura
- e) in case of hydrothorax, hemothorax, chylothorax and pyothorax in this sinus liquid does not cumulate**
51. The syntopy of the right pulmonary pediculus from superior to inferior is as follows:
- a) ABV
- b) BVA
- c) BAV**
- d) VAB
- e) VBA
52. The syntopy of the left pulmonary pediculus from superior to inferior is as follows:
- a) ABV**
- b) BVA
- c) BAV
- d) VAB
- e) VBA
53. The syntopy of the left and right pulmonary pediculus from anterior to posterior is as follows:
- a) left - VAB**

- b) **right - VAB**
  - c) left - AVB
  - d) right - VBA
  - e) right - AVB
54. Which are the pericardiac sinuses:
- a) **transversal**
  - b) vertical
  - c) **oblique**
  - d) **antero-inferior (apical)**
  - e) anterior
55. Internal thoracic artery is situated between the following layers of the thoracic wall:
- a) **endothoracic fascia**
  - b) parietal pleura
  - c) transversal thoracic m.
  - d) **internal face of the ribs and of the internal intercostal mm.**
  - e) parapleural tissue
56. Which of the following statements concerning the topography of the phrenical nerves in the anterior mediastinum are correct:
- a) **penetrate into the anterior mediastinum between the subclavian a. and v.**
  - b) **right phrenic n. initially is situated between the lateral wall of the superior vena cava and mediastinal pleura**
  - c) **pass anterior from the pulmonary hilum**
  - d) pass posterior from the pulmonary hilum
  - e) the left nerve passes on the anterior surface of the esophagus, the right - on the posterior surface
57. The topography of azygos vein in posterior mediastinum is:
- a) **penetrates into posterior mediastinum between the medial and median diaphragmatic legs, together with splanhnic nerves**
  - b) **located on the right side of vertebrae, immediately posterior to intercostal arteries, esophagus – anteriorly, and thoracic duct medially**
  - c) **cross the right bronchus and enters the superior cava vein**
  - d) located on the right side of vertebrae, immediately posterior to thoracic aorta, esophagus – anteriorly, and thoracic duct medially
  - e) penetrates into posterior mediastinum between the medial and lateral diaphragmatic legs, together with splanhnic nerves
58. Which are the weak places of the diaphragm:
- a) **esophagian opening**
  - b) **aortal opening**
  - c) tendineus center and inferior cava vein opening
  - d) **sterno-costal triangles**
  - e) **lumbo-costal triangles**
59. Which are the weak points of the diaphragm:
- a) **esophagian opening**
  - b) **aortal opening**
  - c) tendineus center and inferior cava vein opening
  - d) **sterno-costal triangles**
  - e) **lumbo-costal triangles**
60. The most common source of spreading the purulent collections in the mediastinum is:
- a) **pretracheal space**
  - b) **neurovascular bundle space of the neck**
  - c) antescalen space
  - d) **retrovisceral space**
  - e) sterno cleido –mastoid space
61. In case of anterior mediastinal purulences they can spread in the following areas:
- a) **the external direction through intercostal spaces**
  - b) **pleura**

- c) tendieus center
  - d) pericardium**
  - e) triangles lumbo-costal
62. In case of posterior mediastinum purulences they can spread in the following areas:
- a) subpleural cellular space**
  - b) cellular retroperitoneal space**
  - c) lungs
  - d) sterno-costal triangles
  - e) pericardium
63. What cellular spaces of the mediastinum do you know?
- a) prepericardial**
  - b) aortic hiatus
  - c) tendinous center
  - d) pretracheal**
  - e) paraesofagian**
64. Prepericardial area has the following limits:
- a) anterior - endothoracic fascia**
  - b) posterior - thymus and pericardium**
  - c) anterior - costal pleura
  - d) posterior - mediastinal pleura
  - e) **inferior - pleurodiaphragmatic fascia**
65. Pretracheal space has the following limits:
- a) anterior - posterior wall of the pericardium and the thymus**
  - b) posterior - fascia of the bronches and trachea**
  - c) right - costal pleura and vena hemiazygos
  - d) left- aortic arch and its branches**
  - e) right - mediastinal pleura and azygos vein**
66. Paraesofagian area communicates with:
- a) cervical retrovisceral space**
  - b) cervical previsceral space
  - c) retroperitoneal space**
  - d) preperitoneal space
  - e) paranefral space
67. What are the factors that contribute to the purulent spread in the mediastinum?
- a) mediastinal cellular spaces are not strictly delimited**
  - b) continuous movements of the diaphragm and pleura**
  - c) well-developed cellular spaces
  - d) changing volume of mediastinal organs**
  - e) mediastinal cellular spaces are strictly delimited
68. In what direction can be propagated purulences from prepericardial space?
- a) retropharyngeal space
  - b) preperitoneal space**
  - c) paracolon
  - d) previsceral cervical space**
  - e) parapleural cellular tissue
69. What branches of the sympathetic trunk take part in forming the reflexogenes areas of the thoraco-abdominal region?
- a) major and minor splanchnic nerves**
  - b) cardiac thoracic and splachnicus imus nn.**
  - c) vagus nn
  - d) phrenic nn.
  - e) esophageal and pulmonary branches**
70. Thoracic segment of the vagus nn. gives the following branches:
- a) bronchial**

- b) diaphragmatic
  - c) **oesophageal**
  - d) **pericardial**
  - e) mediastinal
71. What nerve plexus are situated in the heart region?
- a) **right and left anterior plexus**
  - b) **the right and left posterior plexus**
  - c) **right and left atrial plexus**
  - d) right and left ventricular plexus
  - e) anterior-inferior plexus
72. What statements about the thoracic duct are true?
- a) **is formed on the Th 12 - L1**
  - b) are formed on the L2 - L3
  - c) **are formed at the merger of two lombar lymph collectors**
  - d) **beginning of the duct has a dilatation**
  - e) the beginning of the duct has no peculiarity
73. Plan which separates upper and lower mediastinum passes through:
- a) sternal manubrium
  - b) **bifurcation of the trachea**
  - c) I thoracic vertebra
  - d) aortic arch
  - e) xiphoid apophysis
74. The mammary gland is located between the ribs:
- a) 2 rib
  - b) **3 rib**
  - c) 6 rib
  - d) 7 rib
  - e) **5 rib**
75. Locating of the Zorhius lymph node corresponds to:
- a) the lateral edge of the sternum – the third intercostal space
  - b) I intercostal space, medioclavicular, in infraclavicular fossa
  - c) anterior edge of the sternocleidomastoid muscle
  - d) **seratus anterior muscle**
  - e) **under inferior margin of the pectoral major muscle at the level of the III rib**
76. True ribs are:
- a) the first 4
  - b) the last 2
  - c) the first 10
  - d) **the first 7**
  - e) all are true ribs
77. Upper chest aperture is limited by:
- a) **thoracic vertebrae Th1**
  - b) cervical vertebra C7
  - c) **sternal notch of the manumbrium**
  - d) **first ribs**
  - e) clavicle
78. Muscular portion of the diaphragm is divided into:
- a) vertebral portion
  - b) **sternal portion**
  - c) **costal portion**
  - d) **lumbar portion**
  - e) pulmonary portion
79. Upper lobe of the right lung has the following segments:
- a) **apical segment**



- b) **posterior segment**
- c) medium segment
- d) lower segment
- e) **anterior segment**

80. How many lobes has the thymus gland?

- a) 4 lobes
- b) 3 lobes
- c) 1 lob
- d) **2 lobes**
- e) 6 lobes

81. Oval fossa is located on:

- a) interventricular septum
- b) first portion of the aorta
- c) **interatrial septum**
- d) left atrial wall
- e) first portion of the pulmonary trunk

82. The lower limit of the right lung on the medial axillary line corresponds to:

- a) cartilage of the 7 rib
- b) the upper edge of the 11 rib
- c) **the lower edge of the 9 rib**
- d) 6 rib
- e) 5 intercostal space

83. The lower limit of the left lung on medioclavicular line corresponds to:

- a) **7 rib**
- b) 5 rib
- c) 8 rib
- d) 9 rib
- e) 6 intercostal space

84. Right lung is divided into lobes by following fissures:

- a) **oblique fissure**
- b) transverse fissure
- c) **horizontal fissure**
- d) lateral fissure
- e) sagittal fissure

85. Middle mediastinum contains:

- a) **Heart**
- b) **the lower portion of the superior vena cava**
- c) **the ascending aorta**
- d) **pulmonary arteries and veins**
- e) the esophagus

86. Atrioventricular node is located in:

- a) wall of the right atrium
- b) wall of the left atrium
- c) **the lower portion of the interatrial septum**
- d) in the upper portion of the interventricular septum
- e) the wall of the left ventricle

87. Diaphragmatic triangle Larey:

- a) can be used as surgical access to pulmonary pedicle
- b) **can be used for transepigastic puncture of the pericardium**
- c) represent a strong place, corresponds to the tendinous center
- d) **is a weak point of the diaphragm**
- e) corresponds to the esophageal hiatus

88. The most common diaphragm hernias have the location in:

- a) lombocostal Bogdalek triangle

- b) sternocostal Larey triangle
  - c) hiatus aorticus
  - d) hiatus esophageus**
  - e) tendineus center
89. Puncture of pleural cavity is made between the lines:
- a) anterior axillary
  - b) medial axially
  - c) posterior axillary**
  - d) scapular**
  - e) paravertebral
90. Vertical level of pleural cavity puncture corresponds to:
- a) V intercostal space
  - b) VI intercostal space**
  - c) VII intercostal space**
  - d) VIII intercostal space
  - e) IX intercostal space
91. As a rule, costodiafragmatic sinus:
- a) containing 20-50 ml pleural fluid
  - b) has a depth of 6-8 cm**
  - c) is occupied entirely by lung at maximum of inspiration
  - d) is occupied partially by the lung even at maximum of inspiration**
  - e) becomes evident in the accumulation of pathological collections**
92. Intercostal spaces puncture is performed by the absolute rule at the level of:
- a) upper costal margin**
  - b) middle of intercostal space
  - c) lower costal margin
  - d) costal angle
  - e) aponeurotic intercostal membrane
93. According to anatomical particularities, localization of foreign body occurs more often in the:
- a) middle segment of trachea
  - b) bifurcation of the trachea
  - c) right bronchus**
  - d) left bronchus
  - e) anatomical narrowing of the trachea in the lower third
94. Cavo-portal anastomosis by v. esophageal and gastric v. gets maximum clinic value in case:
- a) erosive esophagitis
  - b) Acute pancreatitis
  - c) fatty liver dystrophy
  - d) portal hypertension**
  - e) calculous cholecystitis
95. Separation of mediastinum anterior from posterior is performed by a plan:
- a) sagittal through the pulmonary trunk origin
  - b) frontal through the pulmonary trunk bifurcation
  - c) sagittal through the tracheal bifurcation
  - d) frontal passed through tracheal bifurcation**
  - e) bringing together the origin of the pulmonary trunk with tracheal bifurcation
96. Select anterior mediastinum elements:
- a) the thoracic aortal segment
  - b) pulmonary trunk**
  - c) internal thoracic artery**
  - d) superior vena cava**
  - e) hemiazygos v.
97. Select posterior mediastinum elements:
- a) ascending portion of the aorta

- b) aortic arch, subclavicular arteries, brahiochefalic trunk
- c) **azigos and hemiazygos veins**
- d) **thoracic duct**
- e) internal thoracic vein and artery

98. Select anterior mediastinum elements:

- a) **diaphragmatic nerv**
- b) right vague nerve and thoracic duct
- c) the sympathetic chain, azigos vein
- d) **parasternal lymph nodes**
- e) prevertebral lymph nodes, hemiazigos vein

99. Which of the following statements about the topography of thoracic segment of aorta are correct:

- a) **anterior – pumonar left hilum and in the Th8-9 is crossed by esophagus; posterior - v. hemiazygos**
- b) **left – adheres to mediastinal pleura, near the diaphragm - the esophagus; right - v. azygos and esophagus at the level of Th8-9**
- c) anterior – joins the mediastinal pleura and at Th8-9 is intersected by esophagus; posterior - v. azygos and v. hemiazygos
- d) left - left pumonar hilum, adheres to mediastinal pleura; right - v. hemiazygos and esophagus up to the Th8-9
- e) previous - near the diaphragm - the esophagus, and in the Th8-9 is intersected by esophagus; posterior - v. azygos and v. hemiazygos

100. Intercostal nerve anesthesia puncture will be made by intercostal space at the absolute rule:

- a) superior costal margin
- b) middle of intercostal space
- c) **lower rib margin**
- d) costal angle
- e) intercostal aponeurotic membrane

101. Name the pleural cavity sinuses:

- a) **costodiafragmal sinus**
- b) **frenicomedial sinus**
- c) **anterior costomediastinal sinus**
- d) **posterior costomediastinal sinus**
- e) oblique pleural sinus

102. What landmark is used in determining the intercostal space projection VII in patients with obesity and palpation unable intercostal spaces.

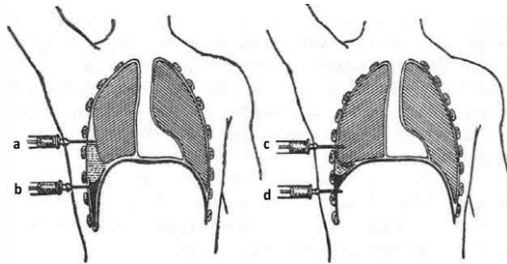
- a) VII intercostal space corresponds to the half way line drawn from the acromion to the apex coast XII
- b) VII intercostal space corresponds to the upper third of a line drawn from the angle of the scapula to the posterior superior iliac
- c) VII intercostal space corresponds to a line drawn from the posterior third of the xiphoid process to the coast XII
- d) VII intercostal space corresponds scapular crest
- e) **VII intercostal space corresponds to the angle of the scapula**

## OPERATIONS ON THE THORAX

1. Which kind of anesthesia is used in case of multiple ribs fractures?
  - a) stellate ganglion blockade
  - b) paravertebral blockade**
  - c) epidural blockade
  - d) intercostal blockade**
  - e) cervical vago-sympathetic blockade
2. What nerve can be injured during ligation of Botallo's duct?
  - a) left phrenic nerve
  - b) left vagus nerve
  - c) 3<sup>rd</sup> intercostal nerve
  - d) sympathetic trunk
  - e) left recurrent laryngeal nerve**
3. How to suture the pericardial cavity in case of a penetrating cardiac injury:
  - a) it is sutured hermetically
  - b) it is not sutured
  - c) the pericardial cavity is drained with a tube
  - d) the pericardial cavity is drained with tampon
  - e) rare sutures are applied**
4. Mark the main surgical approach in lungs surgery:
  - a) anterolateral and lateroposterior intercostal approach**
  - b) median sternotomy
  - c) through posterior mediastinum
  - d) through anterior mediastinum
  - e) thoracoabdominal incision
5. Which tissues are injured in case of penetrating chest trauma?
  - a) skin, muscles and fascia
  - b) skin, fascia and one rib fracture
  - c) fascia and lungs, with bronchus rupture
  - d) skin, muscles, fascia and parietal pleura**
  - e) external haemorrhage caused by injured intercostal artery
6. First aid treatment in case of an open pneumothorax:
  - a) tube insertion in pleural cavity
  - b) sterile occlusive bondage**
  - c) pleural puncture
  - d) compressive dressing to the chest
  - e) artificial ventilation of the lungs
7. First aid treatment in case of a tension pneumothorax
  - a) artificial ventilation of the lungs
  - b) sterile occlusive dressing to the wound and active air aspiration**
  - c) sterile occlusive dressing to the wound and continuous drainage
  - d) tube insertion in pleural cavity
  - e) compressive dressing inferiorly to the wound
8. In which cases the mediastinum moves towards the traumatized part?
  - a) open pneumothorax
  - b) pulmonary atelectasis**
  - c) hemothorax
  - d) diaphragmatic rupture
  - e) pulmonary laceration
9. Which type of pneumothorax is more dangerous and has more severe evolution?
  - a) tension pneumothorax**
  - b) closed pneumothorax
  - c) open pneumothorax
  - d) infected pneumothorax
  - e) all types have the same severity

10. What does thoracotomy means?
  - a) excision of the segments of the thoracic wall
  - b) removal of scar tissue and adhesions
  - c) **desection of the thoracic wall and the opening of the pleural cavity**
  - d) removal of visceral pleura
  - e) removal of ribs and plugging the deffect whith muscles
  
11. Indications for rib resection are:
  - a) **pleural empiema**
  - b) **tumor or osteomielitis of the rib**
  - c) open pneumothorax
  - d) closed pneumothorax
  - e) mastectomy also includes resection of the ribs
  
12. Which of the incisions below is the most reasonable in case of retromammary abscess?
  - a) two radial incisions superiorly and inferiorly to mammary gland
  - b) only radial incisions inferiorly to mammary gland
  - c) **incision on the inferior margin of mammary gland**
  - d) radial incisions, which then are sutured hermetically
  - e) two longitudinal incisions on both sides of mammary gland
  
13. Incisions made in case of interstitial mastitis:
  - a) transversal incisions
  - b) longitudinal incisions
  - c) **radial incisions, from the areola**
  - d) radial incisions, from the mamelon
  - e) the type of incision is not important
  
14. What is the purpose of thoracocentesis?
  - a) to detect the pathologic liquid
  - b) to obtain a qualitative radioscropy
  - c) to administer drugs
  - d) to obtain a qualitative aortography
  - e) **all of the above are correct**
  
15. Which complications can occur during rapid liquid aspiration from pleural cavity?
  - a) **the sudden shift of the mediastinum towards the traumatized part**
  - b) **pleuropulmonary shock**
  - c) nothing will happen
  - d) the patient will feel relief in breathing
  - e) nausea and vomit
  
16. Typical site for thoracocentesis to evacuate the air:
  - a) **2'nd or 3'rd intercostal space on medioclavicular line**
  - b) 3'th intercostal space on anterior axillary line
  - c) 7'rd intercostal space on posterior axillary line
  - d) 5'th intercostal space on medioclavicular line
  - e) 4'th intercostal space on posterior axillary line
  
17. Typical spot for pleural cavity puncture to evacuate the pathologic liquid:
  - a) 5'th intercostal space on medioclavicular line
  - b) 3'rd intercostal space on anterior axillary line
  - c) **6'th or 7'th intercostal space on posterior axillary or scapulary lines**
  - d) 2'nd intercostal space on medioclavicular line
  - e) 4'th intercostal space on posterior axillary line
  
18. On which lines of the thoracic wall the thoracocentesis is performed to evacuate the exudate?
  - a) medioclavicular line
  - b) anterior axillary line
  - c) median axillary line
  - d) **posterior axillary line**
  - e) **scapular line**

19. Which of the below pictures shows the wrong placement of thoracocentesis needle



- a) **A –the needle is located above the collection of liquid**
  - b) **B- the needle is located into the collection of liquid**
  - c) **C- the needle is located into lung tissue**
  - d) **D- the needle is located into peritoneal cavity**
  - e) B- the needle is located in the liver
20. Usually, acute mastitis occurs:
- a) **during lactation period**
  - b) in superio-medial quadrant of the mammary gland
  - c) in retromammar space
  - d) **in superio-lateral quadrant of the mammary gland**
  - e) in inferio-lateral quadrant of mammary gland
21. The types of thoracotomy:
- a) **Antero-lateral**
  - b) **Postero-lateral**
  - c) **Median sternotomy**
  - d) Antero-posterior
  - f) Anterior
22. The types of costal resection:
- a) **Subperiostal**
  - b) Marginal
  - c) **Transperiostal**
  - d) Aperiostal
  - e) Circular
23. The approach to the organs of anterior mediastinum
- a) Antero-lateral thoracotomy
  - b) Lateral thoracotomy
  - c) Transversal sternotomy
  - d) **Longitudinal sternotomy**
  - e) Anterior thoracotomy
24. Name the phases for the surgical treatment of penetrant thoracic wounds:
- a) **Excision of soft tissue till the healthy tissue**
  - b) **Fractured ribs are resect**
  - c) **Lavage of the pleural cavity**
  - d) **The sutures of the thoracic wall are made in 3 layers**
  - e) The sutures of the thoracic wall are made in 5 layers
25. The places for the pericardic puncture:
- a) Right sterno- costal angle
  - b) **Left sterno- costal angle (Marfan procedure)**
  - c) **Under thy xiphoid process on the median anterior line (Morgagni procedure)**
  - d) In the III intercostal space on the left parasternal line
  - e) In the IV intercostal space on the right parasternal line
26. Name the vessels that can be used for aorto- coronarian by-pass:
- a) Small saphenous vein
  - b) **Great saphenous vein**
  - c) **Internal thoracic artery**

- d) Femoral artery
- e) The elbow's intermediate vein

27. The surgical approaches on the oesophagus :

- a) **Cervical**
- b) **Transpleural**
- c) **Transabdominal**
- d) Transmediastinal
- e) Transthoracic

28. Name the indications for the aorto- coronarian by pass:

- a) Infarct
- b) **Chronical hearth ischemia**
- c) **The stenosis of the initial parts of the coronary arteries**
- d) Valve pathology
- e) Aorta coarctation

## ABDOMEN

### ANTEROLATERAL WALL OF THE ABDOMEN

1. In case of direct inguinal hernia, which wall of the inguinal canal is affected?
  - a) **posterior**
  - b) anterior
  - c) superior
  - d) inferior
  - e) all walls
2. Congenital inguinal hernia can be:
  - a) sliding inguinal hernia
  - b) direct
  - c) strangulated
  - d) **oblique**
  - e) direct sliding inguinal hernia
3. What is the cause of congenital inguinal hernia?
  - a) tension of abdominal wall muscle
  - b) increase of intra-abdominal pressure
  - c) **persistent peritoneo-vaginal process**
  - d) cryptorchidism
  - e) dilatation of inguinal space
4. What nerves innervate the inguinal region?
  - a) **iliohypogastric nerve**
  - b) **ilioinguinal nerve**
  - c) genitofemoral nerve
  - d) subcostal nerves
  - e) all answers are correct
5. What structures form the external orifice of the inguinal canal?
  - a) the borders of the orifice correspond with the limits of Hesselbach triangle
  - b) **lateral and medial crura of external oblique m. aponeurosis**
  - c) **fissure of external oblique muscle aponeurosis**
  - d) **ligament reflex from the inguinal ligament**
  - e) **intercrural fibers.**
6. Which vessel forms "corona mortis"?
  - a) obturator artery from internal iliac artery
  - b) inferior epigastric artery from femoral artery
  - c) **obturator branch of the inferior epigastric artery**
  - d) obturator artery from superficial epigastric artery
  - e) obturator vein from inferior epigastric vein
7. What fossa on the inner surface of the abdominal wall corresponds to the internal orifice of the inguinal canal?
  - a) medial inguinal fossa
  - b) suprapubic fossa
  - c) **lateral inguinal fossa**
  - d) femoral fossa
  - e) umbilical fossa
8. What structure forms the anterior wall of the inguinal canal in patients with hernia?
  - a) superficial lamina of the superficial fascia
  - b) external abdominal oblique muscle aponeurosis
  - c) transverse abdominal muscle aponeurosis
  - d) **aponeurosis of the external abdominal oblique muscle**
  - e) aponeurosis of the internal abdominal oblique muscle and cremaster muscle
9. What structure forms the posterior wall of the inguinal canal?
  - a) **transversal fascia**



- b) inferior margin of external oblique muscle
  - c) ileopectineal fascia
  - d) inferior margin of transversalis muscle
  - e) iliac bone crest
10. What structure forms the inferior wall of the inguinal canal?
- a) transversal fascia
  - b) interior margin of external oblique muscle
  - c) Jimbernat's ligament
  - d) inguinal ligament**
  - e) the margin of the iliac bone
11. What structure separates the lateral inguinal fossa from the medial inguinal fossa, on the inner surface of the abdominal wall?
- a) median umbilical fold
  - b) medial umbilical fold
  - c) lateral umbilical fold**
  - d) umbilical artery
  - e) transverse peritoneal fold
12. What inguinal fossa is involved in descending of the testicle?
- a) medial fossa
  - b) lateral fossa**
  - c) supravescical fossa
  - d) lateral and medial fossa
  - e) median fossa
13. Which nerves passes through the external orifice of the inguinal canal?
- a) iliohypogastric nerve
  - b) ilioinguinal and genitofemoral nerves
  - c) ilioinguinal nerve and genital branch of genitofemoral nerve**
  - d) obturator nerve and external spermatic nerve
  - e) ilioinguinal nerve and external spermatic nerve
14. Which are the borders of the inguinal triangle?
- a) inferior-lateral – inguinal ligament**
  - b) medial – pectineal ligament
  - c) medial – lateral margin of rectus abdominis muscle**
  - d) superior – the line that connects the umbilicus with the anterior-superior iliac spine
  - e) superior - the line that connects the point between the lateral and medial 1/3 of the inguinal ligament with lateral margin of rectus abdominis muscle**
15. The inguinal space is:
- a) the space between the anterior and posterior wall of the inguinal canal
  - b) the space between the superior and inferior wall of the inguinal canal**
  - c) the space between the anterior and superior wall of the inguinal canal
  - d) the space between the posterior and inferior wall of the inguinal canal
  - e) the space between the inguinal ligament and the pectineal ligament
16. The elements of the spermatic cord are all, except:
- a) testicular artery
  - b) pampiniform plexus
  - c) vas deferens
  - d) deferential artery
  - e) genital branch of genitofemoral nerve**
17. Which of the following statements concerning the descent of the testes are correct:
- a) the testes begins to descend under the action of gubernaculum testis, starting with the 4<sup>th</sup> month of intrauterine development**
  - b) in the 7<sup>th</sup> month the testes can be found at the level of future internal inguinal orifice**
  - c) initially, it can be found in the lumbar region near the primary kidney**
  - d) in the 9<sup>th</sup> month it descends in the scrotum**
  - e) in the 7<sup>th</sup> month descends in the scrotum

18. In case of hernia, the walls of the inguinal canal are:
- anterior - aponeurosis of external oblique abdominal muscle**
  - superior - free margins of the internal oblique abdominal and transverse abdominal muscles**
  - inferior - inguinal ligament**
  - posterior - aponeurosis of the internal oblique abdominal muscle
  - posterior - transverse fascia**
19. Which of the following statements about inguinal hernias are wrong?
- the inguinal canal is a weak place of the antero-lateral wall of the abdomen
  - direct inguinal hernia occurs when abdominal contents protrudes through lateral inguinal fossa**
  - in oblique inguinal hernias, the hernial sac can be found in the spermatic cord
  - in direct inguinal hernias, hernial sac can descend in the scrotum (inguino-scrotal hernia)**
  - congenital inguinal hernia is oblique
20. Which structures forms the anterior wall of inguinal canal in patients without hernias (healthy):
- aponeurosis of internal oblique abdominal muscle
  - aponeurosis of external oblique abdominal muscle**
  - fibers of the transvers abdominal muscle
  - fibers of cremaster muscle
  - fibers of internal oblique abdominal muscle**
21. What anatomical structures consolidate the floor of the inguinal space (transverse fascia):
- falx aponeurotica inguinalis**
  - falx aponeurotica femoralis
  - fibers of m. cremaster
  - interfoveolar ligament**
  - fibers of transvers abdominal muscle
22. Common vaginal sheath of the testes and spermatic cord is formed as a result of:
- spermatic cord penetration through the transverse fascia
  - descent of the testes**
  - infundibular protrusion of the transverse fascia by the spermatic cord**
  - protrusion of the parietal peritoneum
  - all answers are true
23. What is the lateral limit of the antero-lateral wall of the abdomen:
- the continuation of the anterior axillary line below
  - a line connecting the middle of the XIIth rib with the anterior superior iliac spine
  - the continuation of the medial axillary line below - Lesgaft line**
  - left and right paravertebral lines
  - a line that represents a continuation of the posterior axillary line below
24. Name the superior and inferior borders of the anterolateral abdominal wall:
- a line passing through the upper edge of the pubis, inguinal ligament and iliac crest**
  - a line that connects the anterior iliac spine with the umbilicus
  - a perpendicular line from the anterior-superior iliac spine to the lateral margin of the rectus abdominal muscle
  - a line which passes through the xiphoid process and costal arch**
  - a line which passes through the XIth rib
25. Which nerves innervate the skin in the hypogastric region of the anterolateral abdominal wall
- intercostal nn. V-VIII
  - intercostal nn. IX - XI
  - intercostal nn. XII (n. subcostalis)**
  - ileohypogastric n.**
  - ileoinguinal n.**
26. Which nerves innervate the skin from the mezogastric region?
- intercostal nn. X - XI**
  - intercostal n. IX
  - intercostal XII n. (n. subcostalis)
  - ileohypogastric n.

- e) ileoinguinal n.
27. Which nerves innervate the skin from the epigastric region:
- n. iliohypogastric
  - n. intercostal X - XI
  - n. intercostal XII (n. subcostalis)
  - nn. intercostal VI - IX**
  - n. ileoinguinal
28. Which subcutaneous veins take part in formation of cavo-caval anastomosis around the umbilicus:
- thoracoepigastric v.**
  - paraumbilical vv.
  - inferior epigastric v.
  - superficial epigastric v.**
  - superior epigastric v.
29. Which subcutaneous veins take part in formation of porto-caval anastomosis around the umbilicus:
- superficial epigastric v.**
  - paraumbilical vv.**
  - epigastric inferior v.
  - thoracoepigastric v.**
  - epigastric superior v.
30. Which anatomical structures form the internal femoral orifice:
- medial - lacunar ligament (Gimbernati)**
  - lateral - femoral a.
  - lateral - fascial sheath of femoral vein**
  - anterior and superior - inguinal ligament (Poupart)**
  - posterior and inferior - pectineal ligament (Cooper)**
31. Name the layers of umbilical ring:
- skin**
  - subcutaneous fatty tissue
  - scar tissue**
  - umbilical fascia**
  - parietal peritoneum**
32. The main trunks of the intercostal arteries are situated:
- between the internal oblique and transverse abdominal mm.**
  - between the external and internal oblique abdominal mm.
  - between the aponeurotic laminae of the internal oblique abdominal m.
  - between the subcutaneous fatty tissue and the external oblique abdominal m.
  - in the rectus sheath
33. In the hypogastric region, the inferior epigastric artery is situated:
- between the internal oblique and transverse abdominal mm.
  - between the transverse muscle and the peritoneum
  - between the transverse fascia and parietal peritoneum (in the preperitoneal tissue)**
  - between the aponeurosis of external and internal oblique abdominal mm.
  - in the subcutaneous fatty tissue
34. In which umbilical fold the inferior epigastric artery is situated?
- medial umbilical fold
  - median umbilical fold
  - transverse vesical fold
  - lateral umbilical fold**
  - inferior epigastric fold
35. Which of the following statements are correct?
- deep lamina of the superficial fascia of the antero-lateral wall of the abdomen in the hypogastric region is called Thompson fascia**
  - superficial lamina of the superficial fascia of the antero-lateral wall of the abdomen in the hypogastric region is called Thompson fascia

- c) **in case of portal hypertension, the superficial veins around the umbilicus are distended ("caput medusae" sign)**
  - d) **the round ligament of the liver forms as a result of obliteration of the umbilical vein in the postnatal period**
  - e) **umbilical hernias protrudes more frequently through the superior semicircumference of the umbilical ring**
36. In the surgical treatment of which type of hernia, "corona mortis" can be injured:
- a) oblique inguinal hernia
  - b) strangulated direct inguinal hernia
  - c) **strangulated femoral hernia**
  - d) obturator hernia
  - e) strangulated oblique inguinal hernia
37. The connection between the portal vein and the veins of the abdominal wall is done through:
- a) **paraumbilical vv.**
  - b) testicular v.
  - c) inferior epigastric v.
  - d) superior epigastric v.
  - e) intercostal v.
38. Which muscles form the anterolateral abdominal wall?
- a) **rectus abdominis and pyramidal mm.**
  - b) **transvers abdominal mm.**
  - c) **external oblique mm.**
  - d) **internal oblique mm.**
  - e) iliopsoas m.
39. The superficial epigastric artery is a branch of the:
- a) **femoral a.**
  - b) extern iliac a.
  - c) intern a. iliac
  - d) profunda femoris a.
  - e) obturator a.
40. The anterolateral abdominal wall is supplied by:
- a) **superficial epigastric a., inferior epigastric a.**
  - b) **superior epigastric a., intercostal aa.**
  - c) external pudend a., obturator a.
  - d) internal pudend a., external iliac a.
  - e) **lumbar aa.**
41. Inferior epigastric artery is a branch of the:
- a) femoral a.
  - b) internal iliac a.
  - c) **external iliac a.**
  - d) obturator a.
  - e) a. profunda femoris
42. The preperitoneal tissue communicates directly with:
- a) parametral space and parietal space in the pelvis
  - b) **prevesical space**
  - c) paranephral space
  - d) **retroperitoneal space**
  - e) pararectal space
43. Which structure covers the posterior face of rectus abdominis muscle below the arcuate line (Douglas line)?
- a) parietal peritoneum
  - b) parietal peritoneum and aponeurosis of transverse abdominal m.
  - c) **transverse fascia**
  - d) parietal pelvic fascia
  - e) aponeurosis of transverse abdominal muscle

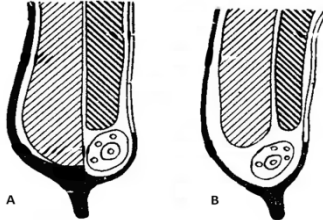
44. The anterior wall of the rectus sheath above the arcuate line (Douglas line) is formed by:
- aponeurosis of the transverse abdominal muscle
  - aponeurosis of the external oblique abdominal muscle**
  - transverse fascia
  - anterior lamina of the aponeurosis of internal oblique abdominal muscle**
  - aponeurosis of internal oblique abdominal muscle
45. The anterior wall of the rectus sheath below the arcuate line (Douglas line) is formed by:
- aponeurosis of transverse abdominal m.**
  - aponeurosis of external oblique abdominal m.**
  - transverse fascia
  - anterior lamina of the aponeurosis of internal oblique abdominal m.
  - aponeurosis of internal oblique abdominal m.**
46. The posterior wall of the rectus sheath above the arcuate line (Douglas) is formed by:
- aponeurosis of transverse abdominal m.**
  - aponeurosis of external oblique abdominal m.
  - transverse fascia
  - posterior lamina of the aponeurosis of internal oblique abdominal m.**
  - aponeurosis of internal oblique abdominal m.
47. What is the arcuate line (Douglas line)?
- the limit where the external oblique abdominal muscle's aponeurosis passes from anterior to posterior
  - the limit where the transverse muscle's aponeurosis passes from anterior to posterior
  - the limit where the transverse muscle's aponeurosis passes from posterior to anterior**
  - the limit where the internal oblique abdominal muscle's aponeurosis passes from posterior to anterior**
  - the limit where the transverse fascia passes from posterior to anterior
48. The superior and inferior epigastric arteries are situated:
- between the internal and external oblique abdominal muscles
  - in the subcutaneous fatty tissue
  - posterior to the rectus abdominal muscle**
  - in the rectus sheath**
  - between internal oblique and transverse abdominal muscles.
49. The superficial arteries in the hypogastric region are:
- superficial epigastric artery**
  - superior epigastric artery
  - superficial iliac circumflex artery.**
  - inferior epigastric artery.
  - external pudendal arteries.
50. What is semilunar line (Spiegel's line)?
- the limit where the internal oblique abdominal muscle passes into its aponeurosis
  - the limit where the external oblique abdominal muscle passes into its aponeurosis
  - the limit between the mezogastric region and hypogastric region
  - a line situated 2-3 cm below the umbilicus
  - the limit where the transverse abdominal muscle passes into its aponeurosis**
51. Which of the following statements concerning the umbilical ring are correct:
- is a weak place of the anterolateral wall of the abdomen**
  - in the intrauterine period, the urachus and two umbilical arteries passes through the inferior 1/2 of the umbilical ring**
  - is a region where the subcutaneous fatty tissue and the preperitoneal tissue is absent**
  - in the intrauterine period, the umbilical vein passes through the superior 1/2 of the umbilical ring**
  - it has 6 layers
52. The anterolateral wall of the abdomen is divided into:
- 6 regions
  - 8 regions
  - 9 regions**
  - 4 regions

e) 10 regions

53. The inferior border of the anterolateral abdominal wall passes through:

- a) **the upper margin of the pubic symphysis**
- b) **iliac crest**
- c) arcuate line (Douglas line)
- d) **inguinal ligament**
- e) semilunar line (Spiegel's line)

54. Which picture represents the sagittal section through inguinal canal in healthy subjects and in patients with hernia?



- a) **A - healthy subjects; B – patients with hernia**
- b) A - patients with hernia; B - healthy subjects
- c) A - patients with hernia; B - oblique inguinal hernia
- d) A - direct inguinal hernia; B - oblique inguinal hernia
- e) A - oblique inguinal hernia; B – congenital oblique inguinal hernia

55. The following statement about umbilical canal is correct:

- a) **it is located between the umbilical fascia and white line of the abdomen**
- b) it is located between the endoabdominal fascia and the white line of the abdomen
- c) it is located between the umbilical fascia and endoabdominal fascia
- d) it is located between the fascia of transverse muscle and endoabdominal fascia
- e) it is located between umbilical fascia and round ligament of the liver

56. The borders of the umbilical canal are:

- a) anterior border- anterior surface of the umbilical fascia; posterior border - posterior surface of the white line and medial margins of m. rectus abdominis
- b) anterior border - anterior surface of the umbilical fascia and medial margins of m. rectus abdominis; posterior border - posterior surface of the white line
- c) anterior border - the posterior surface of the white line and medial margins of m. rectus abdominis; posterior border - anterior surface of the umbilical fascia
- d) **anterior border - posterior surface of the white line and medial margins of m. rectus abdominis; posterior border - anterior surface of the umbilical fascia**
- e) anterior border - posterior surface of the umbilical fascia and lateral margins of m. rectus abdominis; posterior border - anterior surface of the white line

57. Which structure passes through umbilical canal:

- a) umbilical artery
- b) urachus
- c) **umbilical vein**
- d) urachus and umbilical arteries
- e) round ligament of the liver

58. What shapes the inguinal space can have:

- a) **cracked**
- b) **round**
- c) **oval**
- d) **triangular**
- e) semilunar

59. Where the internal inguinal ring is projected on anterolateral abdominal wall:

- a) 1.5 cm superior to the point between medial and lateral 1/3 of inguinal ligament
- b) 1.5 cm superior to the point between medial and internal 1/3 of inguinal ligament
- c) **1.5 cm superior to the middle of inguinal ligament**
- d) 1.5 cm superior to the external 1/3 of inguinal ligament

e) 1.5 cm superior to the internal 1/3 of inguinal ligament

60. Name the layers of the spermatic cord:

- a) **external cremaster fascia; cremaster fascia**
- b) tunica dartos, gubernaculum testis
- c) vaginal process of peritoneum
- d) **m. cremaster; internal cremaster fascia**
- e) spermatic artery sheath, Thompson fascia

61. Select the correct definition of a hernia:

- a) abdominal hernia is a partially or total exit of an organ in the subcutaneous tissue through a weak area of the abdominal wall
- b) abdominal hernia is strangulation of a organ in an anatomic preexisting weak area of the abdominal wall
- c) **abdominal hernia is a partially or total exit of one or more organs from peritoneal cavity through a anatomic preexisting weak area of the abdominal wall, together with the parietal peritoneum**
- d) abdominal hernia is a partially or total exit of one or more organs from abdominal cavity, through a weak area of the abdominal wall, together with the visceral peritoneum
- e) hernia is a partially or total exit of one or more organs from abdominal cavity

62. Note the correct statement regarding persistent patent processus vaginalis:

- a) it represents the continuation of testicular fascia, that is carried into the scrotum by the descent of the testicle from lumbar region
- b) it represents the continuation of Thompson fascia, that is carried into the scrotum by the descent of the testicle from lumbar region
- c) **it represents the continuation of parietal peritoneum, that is carried into the scrotum by the descent of the testicle from lumbar region**
- d) it represents the continuation of endoabdominal fascia, that is carried into the scrotum by the descent of the testicle from lumbar region
- e) it represents the continuation of transverse fascia, that is carried into the scrotum by the descent of the testicle from lumbar region

63. Note the correct statement regarding congenital inguinal hernia:

- a) **in this type of hernia, processus vaginalis forms the hernial sac**
- b) this type of hernia is characterized by transverse fascia defect due to descend of the testicle
- c) in this type of hernia, the hernial sac penetrates through medial inguinal fossa
- d) in this type of hernia, the hernial sac passes through inguinal space
- e) in this type of hernia, the hernial sac is located between the abdominal muscles

64. What type of hernia is represented in the picture:



- a) **congenital inguinal hernia**
- b) acquired inguinal hernia
- c) inghino - scrotal hernia
- d) sliding inguinal hernia
- e) direct inguinal hernia

65. What type of hernia is represented in the picture:



- a) congenital inguinal hernia
- b) **acquired inguinal hernia**

- c) inghino - scrotal hernia
- d) sliding inguinal hernia
- e) direct inguinal hernia



## HERNIAS

1. What type of procedure is performed to strengthen the posterior wall of the inguinal canal in case of direct inguinal hernia?
  - a) **Bassini procedure**
  - b) Bobrov procedure
  - c) Spasokukočki procedure
  - d) Kimbarovski procedure
  - e) Girard procedure
2. In case of direct inguinal hernia, which wall of the inguinal canal has low resistance?
  - a) **posterior wall**
  - b) anterior wall
  - c) superior wall
  - d) inferior wall
  - e) resistance of all walls
3. Congenital inguinal hernia is a:
  - a) sliding hernia
  - b) direct hernia
  - c) strangulated hernia
  - d) **oblique hernia**
  - e) sliding and direct hernia
4. What is the relationship between hernial sac and the inguinal ligament in case of oblique inguinal hernia?
  - a) it is situated anterior to the inguinal ligament
  - b) it is situated posterior to the inguinal ligament
  - c) it is situated lateral to the inguinal ligament
  - d) it is situated medial to the inguinal ligament
  - e) it is parallel to the inguinal ligament
5. Select the particularities of the oblique inguinal hernia?
  - a) spermatic cord is situated laterally to the hernial sac
  - b) **the hernial bag protrudes into the spermatic cord**
  - c) **in case of small hernias, the main components of the spermatic cord are located medially to the hernial sac**
  - d) **in case of big hernias, the main components of the spermatic cord are located on the surface of hernial sac**
  - e) the spermatic chord is not affected
6. What is the relationship between hernial sac and the inguinal ligament in case of direct inguinal hernia?
  - a) **it is situated anteriorly to the inguinal ligament**
  - b) it is situated posteriorly to the inguinal ligament
  - c) **transversally and forms an angle with the spermatic cord**
  - d) it is situated medially to the inguinal ligament and is parallel with the spermatic cord
  - e) it is situated laterally to the inguinal ligament
7. What is the relationship between hernial sac and the spermatic cord in case of direct inguinal hernia?
  - a) **spermatic cord is situated laterally to the hernial sac and remain intact**
  - b) the hernial sac penetrates into the spermatic cord
  - c) in case of small hernias, the main components of the spermatic cord are located medially to the hernial sac
  - d) in case of big hernias, the main components of the spermatic cord are placed on the surface of hernial sac
  - e) correlation between spermatic cord and hernia sac has no special significance
9. In which type of hernia, the testicle is present in hernial sac?
  - a) **congenital hernia**
  - b) direct hernia
  - c) oblique hernia
  - d) femoral hernia
  - e) sliding hernia
10. What are the predisposing factors in development of abdominal hernia:
  - a) the increased tone and strength of rectus abdominal muscles
  - b) **the difference between increased load applied on the muscle and the reduced strength of the muscles**
  - c) **increased intraabdominal pressure**
  - d) **abdominal wall nerves paralysis**

**e) pathologies that lead to increased intraabdominal pressure**

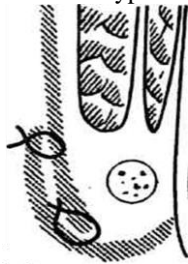
11. What is the cause of congenital inguinal hernia:

- a) strain of the abdominal muscles
- b) increasing intraabdominal pressure
- c) persistent processus vaginalis**
- d) cryptorchidism
- e) expansion of inguinal space

12. Select the surgical steps of herniotomy and hernioplasty:

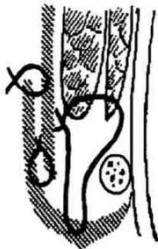
- a) anesthesia, mobilizing of hernial sac**
- b) returning of the hernial sac contents into peritoneal cavity without revision
- c) revision and returning the contents of the hernial sac into peritoneal cavity**
- d) excision of the hernial sac - herniotomy**
- e) restore abdominal wall defect - hernioplasty**

13. What type of procedure to strengthen the anterior wall of inguinal canal is represented in the picture:



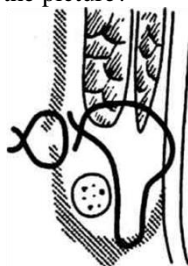- a) the Martinov procedure**
- b) the Bassini procedure
- c) the Girard procedure
- d) the Kukujanov procedure
- e) the Lichtenstein procedure

14. What type of procedure for restoring the walls of inguinal canal in case of indirect inguinal hernia is represented in the picture?



- a) the Martinov procedure
- b) the Bassini procedure
- c) the Girard procedure**
- d) the Kukujanov procedure
- e) the Lichtenstein procedure

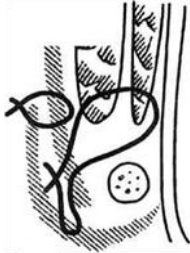
15. What type of procedure for restoring the walls of inguinal canal in case of direct inguinal hernia is represented in the picture?



- a) the Martinov procedure

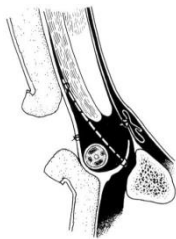
- b) the Bassini procedure**
- c) the Girard procedure
- d) the Kukujanov procedure
- e) the Lichtenstein procedure

16. What type of procedure for restoring the walls of inguinal canal in case of direct inguinal hernia is represented in the picture?



- a) the Martinov procedure
- b) the Bassini procedure
- c) the Kimbarovski procedure**
- d) the Kukujanov procedure
- e) the Lichtenstein procedure

17. What type of procedure for restoring the walls of inguinal canal in case of direct inguinal hernia is represented in the picture?



- a) the Martinov procedure
- b) the Bassini procedure
- c) the Kimbarovski procedure
- d) the Kukujanov procedure
- e) the Lichtenstein procedure**

18. Select the surgical steps in case of strangulated hernia (without organ necrosis):

- a) dissection and mobilization of hernial sac**
- b) opening the hernial sac and transection of strangulation ring**
- c) to fix the hernial sac contents and determine their viability**
- d) returning the contents into peritoneal cavity and transection of hernial sac and restoring the defect - hernioplasty**
- e) resection of the strangulated intestine and anastomosis

19. Select the surgical steps in case of strangulated hernia (with organ necrosis):

- a) dissection and mobilization of hernial sac**
- b) opening the hernial sac and fix its contents**
- c) opening the hernial sac and returning its contents into peritoneal cavity
- d) transection of strangulation ring and determine the viability of the hernial sac contents**
- e) resection of the strangulated intestine and anastomosis**

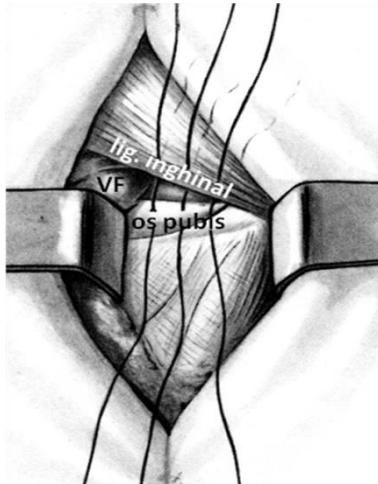
20. Limits of intestinal resection in case of strangulated hernia are:

- a) 5-10 cm proximally and 10-20 cm distally from affected bowel
- b) 10-15 cm proximally and 50-70 cm distally from affected bowel**
- c) ) 10 proximally and distally from affected bowel
- d) ) 20-25 cm proximally and 30-40 cm distally from affected bowel
- e) intestinal resection will be performed at the level of strangulation ring with anastomosis application


21. Bassini procedure in femoral hernia hernioplasty consists of:

- a) a 7-8 cm vertical or oblique incision, which starts 2 cm above the inguinal ligament
- b) mobilization of hernial sac up to the its neck
- c) opening of hernial sac, examination of the contents and excision of the hernial sac
- d) deep femoral ring closure by suturing the inguinal ligament to the rectus sheath
- e) deep femoral ring closure by applying 2-3 sutures between the inguinal ligament and pubic periosteum

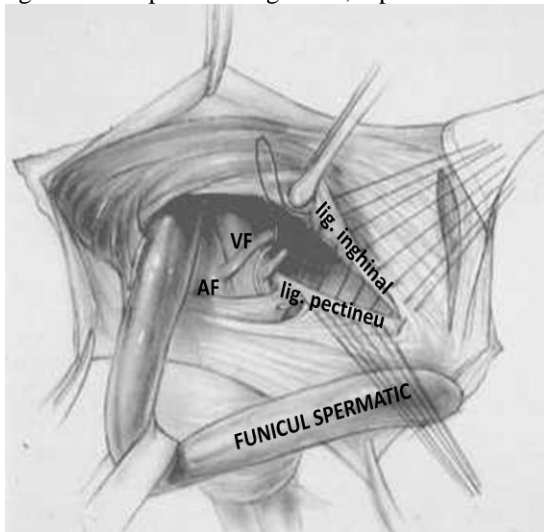
22. The surgical procedure which consists of deep femoral ring closure by applying 2-3 sutures between the inguinal ligament and pubic periosteum, represented in the picture, is called:



- a) Ruggi procedure
- b) **Bassini procedure**
- c) Marcy procedure
- d) Kukujanov procedure
- e) Lichtenstein procedure



24 The surgical procedure which consists of deep femoral ring closure by applying 2-3 sutures between the inguinal ligament and pectineal ligament, represented in the picture, is called:



- a) **Ruggi procedure**
- b) Bassini procedure
- c) Marcy procedure

- d) Kukujanov procedure
- e) Lichtenstein procedure

25. Reich procedure in femoral hernia hernioplasty consists of:

- a) **a 7-8 cm vertical or oblique incision, which starts 2 cm above the inguinal ligament**
- b) **mobilization of hernial sac up to the its neck and opening it**
- c) **examination of the contents and excision of the hernial sac**
- d) the sutures will pass through external oblique m. → internal oblique m. → transverse m. → inguinal ligament
- e) **the sutures will pass through internal oblique m. → transverse m. → periosteum of the pubis → inguinal ligament**

26. The surgical procedure in case of femoral hernias, which consists of closure of the deep femoral ring and inguinal space, by applying sutures through internal oblique m. → transverse m. → periosteum of the pubis → inguinal ligament is called:

- a) Ruggi procedure
- b) Bassini procedure
- c) **Reich procedure**
- d) Kukujanov procedure
- e) Lichtenstein procedure

27. Which surgical procedure is applied in children in case of umbilical hernia?

- a) Mayo procedure
- b) Sapejco procedure
- c) **Lexer procedure**
- d) Bassini procedure
- e) Martinov procedure

28. Which type of suture is applied in case of white line hernia?

- a) continuous suture
- b) purse-string suture
- c) **U-suture**
- d) Z-suture
- e) Multanovski suture

## PERITONEAL CAVITY

- Which veins form the portal vein?
  - left gastric and superior mesenteric veins
  - inferior mesenteric and renal veins
  - inferior mesenteric and left testicular (ovarian) veins
  - superior mesenteric, inferior mesenteric and splenic veins**
  - superior mesenteric and renal veins
- Portal vein is localized:
  - in the omental bursa, anterior to the head of the pancreas
  - initially, in the retroperitoneal space, posterior to the head of the pancreas**
  - anterior to the head of the pancreas, at the entrance into omental bursa
  - between the laminae of the hepatoduodenal ligament**
  - behind the stomach, between the laminae of the hepatoduodenal ligament
- Which part of the duodenum crosses the portal vein:
  - superior**
  - descending
  - inferior
  - ascending
  - the portal vein does not pass behind the duodenum
- The relationship of the common bile duct and portal vein are:
  - the common bile duct is situated in front of the portal vein
  - the common bile duct is situated behind the portal vein
  - the common bile duct is situated to the right of the portal vein**
  - the common bile duct is situated to the left of the portal vein
  - between portal vein and proper hepatic artery
- Left to the portal vein passes:
  - right gastroepiploic artery
  - left gastroepiploic artery
  - left gastric artery
  - proper hepatic artery**
  - hepatic common artery
- The hepatoduodenal ligament starts from:
  - from the left hepatic lobe
  - from the right hepatic lobe
  - from the quadrate lobe
  - from the hepatic hilum**
  - from the caudate lobe of the liver
- The contents of the hepatoduodenal ligament are:
  - a. hepatica comunis, common bile duct, a. lienalis
  - common bile duct, v. porta, a. hepatica propria**
  - a. gastrica sinistra, vv. hepatica, common bile duct
  - a. hepatica comunis, a. gastrica dextra, common bile duct
  - common bile duct, portal vein, common hepatic artery
- Which structures contribute to the formation of the hepatoduodenal ligament?
  - two laminae of visceral peritoneum constituting the gastropancreatic ligament
  - two laminae of parietal peritoneum from hepatorenal ligament
  - two laminae of the visceral peritoneum from the lesser omentum**
  - transverse fascia and transverse muscle aponeurosis
  - transverse fascia and visceral peritoneum
- Which border of the omental foramen does hepatoduodenal ligament form?
  - anterior**
  - posterior
  - superior

- d) inferior
  - e) medial
10. The arteries situated in the lesser omentum are:
- a) a. gastrica sinistra, a. gastrica dextra, portal vein
  - b) a. gastrica sinistra, a. gastrica dextra, a. lienalis
  - c) a. gastrica sinistra, a. gastrica dextra, a. colica media
  - d) a. gastrica sinistra, a. gastrica dextra, a.gastroduodenalis
  - e) **a. gastrica sinistra, a. gastrica dextra, a. hepatica propria**
11. Left gastric artery originates from:
- a) a. mesenterica superior
  - b) a. mesenterica inferior
  - c) **truncus celiacus**
  - d) a. lienalis
  - e) a. hepatica
12. Right gastric artery originates from:
- a) truncus celiacus
  - b) **a. hepatica comunis**
  - c) a. hepatica propria
  - d) a. lienalis
  - e) abdominal aorta
13. Where the main trunk of the left gastric artery is situated:
- a) in the hepatogastricum ligament
  - b) in the phrenicocolicum ligament
  - c) **in the phrenicogastric ligament**
  - d) in the gastrocolicum ligament
  - e) in the hepatoduodenal ligament
14. Lesser omentum is formed by the following ligaments:
- a) gastrocolic, hepatogastric, gastrolial
  - b) gastrolial, hepatorenal, lacunar
  - c) **hepatoduodenal, hepatogastric, phrenicogastric**
  - d) hepatogastric, gastropancreatic
  - e) gastrolial, duodenorenal
15. Hepatoduodenal ligament connects the hepatic hilum and:
- a) Descending part of duodenum
  - b) Ascending part of duodenum
  - c) **Superior part of duodenum**
  - d) Lesser curvature of the stomach
  - e) Omental bursa
16. Hepatoduodenal ligament is a part of:
- a) greater omentum
  - b) **lesser omentum**
  - c) gastropancreatic ligament
  - d) duodenorenal ligament
  - e) hepatogastric ligament
17. Which structures bound the omental foramen?
- a) **inferiorly – duodenum**
  - b) **superiorly – caudate lobe of the liver**
  - c) **anteriorly – hepatoduodenal ligament**
  - d) **posteriorly – parietal peritoneum which covers the inferior vena cava**
  - e) laterally – hepatorenal ligament
18. Which structures are situated in the hepatogastric ligament?
- a) **left gastric artery**
  - b) proper hepatic artery
  - c) **right gastric artery**

- d) **left gastric vein**
  - e) splenic vein
19. The posterior wall of the omental bursa is formed by:
- a) spleen
  - b) left hepatic lobe
  - c) **parietal peritoneum which covers the pancreas, aorta, inferior vena cava and left kidney**
  - d) visceral peritoneum
  - e) hepatic caudate lobe
20. What structures form the superior wall of the omental bursa?
- a) **diaphragm**
  - b) **inferior surface of the caudate lobe of the liver**
  - c) posterior wall of the stomach
  - d) posterior part of the left hepatic lobe
  - e) inferior part of the duodenum
21. Right gastroepiploic artery originates from:
- a) lienal artery
  - b) superior mesenteric artery
  - c) **gastroduodenal artery**
  - d) inferior mesenteric artery
  - e) left gastric artery
22. What is the relationship between the stomach and peritoneum?
- a) retroperitoneal
  - b) **intraperitoneal**
  - c) mesoperitoneal
  - d) posterior wall is retroperitoneal
  - e) anterior wall is mesoperitoneal
23. Abdominal part of the esophagus can be situated:
- a) retroperitoneal
  - b) **intraperitoneal**
  - c) **mesoperitoneal**
  - d) in posterior mediastinum
  - e) in anterior mediastinum
24. Portal vein of liver is situated in:
- a) hepatogastric ligament
  - b) gastropancreatic ligament
  - c) **hepatoduodenal ligament**
  - d) gastrocolic ligament
  - e) hepatolienal ligament
25. Which ducts are localized in the hepatoduodenal ligament?
- a) **left and right hepatic ducts**
  - b) **cystic duct**
  - c) **common bile duct**
  - d) pancreatic duct
  - e) accessory pancreatic duct
26. The blood from the liver is drained into:
- a) **inferior vena cava**
  - b) superior vena cava
  - c) splenic vein
  - d) superior mesenteric vein
  - e) right gastric vein and short gastric veins
27. What is the relationship of the gallbladder with peritoneum?
- a) Intraperitoneal
  - b) Retroperitoneal
  - c) **Mesoperitoneal**



- d) Neck - intraperitoneal, body - mezoperitoneal
  - e) Does not have relation with the peritoneum
28. Veins of the esophagus flow into:
- a) portal v., splenic vein
  - b) azygos, hemiazygos veins**
  - c) left gastric vein**
  - d) inferior vena cava
  - e) superior mesenteric and portal veins
29. Where is situated the motor branch of vagus - the nerve of Latarjet?
- a) Near the greater curvature of stomach
  - b) In the lesser omentum parallel to the lesser curvature of stomach**
  - c) Near the fundus of the stomach
  - d) Along the piloroduodenal canal
  - e) Along the gastrolial ligament
30. A. gastroepiploica sinistra originates from:
- a) a. gastrica sinistra
  - b) a. gastrica dextra
  - c) a. lienalis**
  - d) a. mezentérica superior
  - e) a. hepática propria
31. Blood supply of the greater curvature of stomach is provided by:
- a) a. mesenterica superior
  - b) a. gastroepiploica dextra**
  - c) a. lienalis
  - d) a. gastroepiploica sinistra**
  - e) short gastric arteries**
32. Which nerves are attached to the abdominal part of the esophagus?
- a) right and left splanhnic nerves
  - b) right and left diaphragmatic nerves
  - c) sympathetic trunk
  - d) anterior and posterior vagus nerves**
  - e) anterior vagus nerve and Latarjet nerve
33. Anterior wall of the omental bursa is formed by:
- a) Lesser omentum and spleen, gastropancreatic ligament
  - b) Lesser omentum and spleen, anterior wall of the stomach, caudate lobe of the liver
  - c) Hepatogastric ligament, anterior gastric wall
  - d) Right hepatic lobe, lesser omentum, gastrocolic ligament
  - e) Lesser omentum, posterior gastric wall and gastrocolic ligament**
34. Omental foramen forms a communication between:
- a) supramesocolic and inframesocolic compartments of the abdominal cavity
  - b) abdominal cavity and preepiploic space
  - c) subhepatic recess and omental bursa**
  - d) supramesocolic and inframesocolic compartments of the peritoneal cavity
  - e) Abdominal cavity and peritoneal cavity
35. Common hepatic duct is formed by confluence of:
- a) Cystic and left hepatic ducts
  - b) Cystic and right hepatic ducts
  - c) Right and left hepatic ducts**
  - d) Left hepatic and common bile ducts
  - e) Common bile duct and pancreatic ducts
36. Common bile duct is formed by confluence of:
- a) Cystic and common hepatic ducts**
  - b) Cystic and right hepatic ducts

- c) Right and left hepatic ducts
  - d) Left hepatic and common bile ducts
  - e) Common bile duct and pancreatic duct
37. Gallbladder is situated on the following surface of the liver:
- a) Posterior
  - b) Anterior
  - c) Diaphragmal
  - d) Visceral**
  - e) Medial
38. Usually, cystic artery originates from:
- a) Common hepatic artery
  - b) Proper hepatic artery
  - c) Left hepatic artery
  - d) Right hepatic artery**
  - e) Left gastric artery
39. Boundaries of the Budd triangle are:
- a) Superior – liver**
  - b) Inferior – cystic duct**
  - c) Medial – common hepatic duct**
  - d) Superior – right hepatic artery
  - e) Medial – common bile duct
40. Superior compartment of peritoneal cavity is separated from inferior compartment by:
- a) gastrocolic ligament
  - b) mesentery of the descending colon
  - c) mesentery of the ascending colon
  - d) transverse mesocolon**
  - e) mesentery of the small intestine
41. The following parts of duodenum are situated retroperitoneal:
- a) Superior part
  - b) Descending part**
  - c) Inferior part**
  - d) Ascending part
  - e) whole duodenum
42. Common bile duct drains into:
- a) small intestine
  - b) hepatopancreatic ampulla**
  - c) descending part of duodenum**
  - d) inferior part of duodenum
  - e) ascendent part of duodenum
43. The relationship between the spleen and the peritoneum is:
- a) retroperitoneal
  - b) intraperitoneal**
  - c) it is not covered by peritoneum
  - d) mesoperitoneal
  - e) partially covered by peritoneum
44. Pancreas is situated:
- a) in hepatic bursa
  - b) in the inferior compartment of the peritoneal cavity
  - c) in retroperitoneal space**
  - d) in duodenojejunal recess
  - e) in the omental bursa
45. Pancreatic duct opens into:
- a) inferior portion of the duodenum
  - b) descending portion of the duodenum**

- c) minor duodenal papilla in descending portion of duodenum
  - d) hepatopancreatic ampulla**
  - e) omental bursa
46. Hepatopancreatic ampulla opens into:
- a) the lower portion of the duodenum
  - b) descending duodenum**
  - c) the superior horizontal portion of the duodenum
  - d) in apex of smaller duodenal papilla
  - e) in apex of greater duodenal papilla**
47. Hepatic bursa is limited by:
- a) posterior - right coronary ligament**
  - b) right - falciform ligament
  - c) left -falciform ligamen**
  - d) superior - diaphragm**
  - e) inferior - right lobe of the liver**
48. What represents the right subdiaphragmatic space?
- a) the lowest point of subhepatic recess
  - b) the lowest point of the hepatic bursa**
  - c) it is situated posterior to the superior surface of the right hepatic lobe**
  - d) can serve as a site of accumulation of pathologic fluids**
  - e) does not have any practical significance
49. Boundaries of pregastric bursa are:
- a) posterior – lesser omentum and anterior wall of the stomach**
  - b) superior – diaphragm**
  - c) anterior – anterolateral abdominal wall**
  - d) superior – hepatic hilum
  - e) inferior – it is not limited and communicates freely with the preepiploic space**
50. What are the limits of preepiploic space
- a) posterior – the greater omentum**
  - b) anterior – visceral peritoneum
  - c) anterior – anterolateral abdominal wall**
  - d) posterior – small omentum
  - e) inferior – it is not limited and communicates freely with inframesocolic compartment**
51. Which of the following statements concerning bursa omentalis are correct?
- a) it is situated posteriorly to the stomach and lesser omentum**
  - b) serves as a way of access to the pancreas**
  - c) serves as space of accumulating of fluids in case of pancreatitis or gastric contents in case of perforations of the stomach**
  - d) has three recesses - inferior, superior and left**
  - e) it is situated anteriorly to the stomach and lesser omentum
52. What are the boundaries of the Callot's triangle:
- a) left – proper hepatic a.
  - b) right – common biliar hepatic duct
  - c) left – common hepatic biliar duct**
  - d) inferior-lateral – ductus cysticus**
  - e) at the base – a. cistica or right hepatic a.**
53. The common bile duct has the following parts:
- a) hillar
  - b) supraduodenal**
  - c) retroduodenal**
  - d) pancreatic**
  - e) intramural**
54. In case of cancer of pancreatic head, which part of the common bile duct is compressed initially :
- a) hilar

- b) supraduodenal
  - c) retroduodenal
  - d) pancreatic**
  - e) intramural
55. Select the superficial ligaments of the stomach:
- a) hepatogastric ligament**
  - b) gastropancreatic ligament
  - c) phrenicogastric ligament**
  - d) gastrocolic ligament**
  - e) gastrolial ligament**
56. Select the deep ligaments of the stomach:
- a) hepatogastric ligament
  - b) gastrocolic ligament
  - c) left gastropancreatic ligament**
  - d) gastrolial ligament
  - e) right gastropancreatic ligament (piloropancreatic ligament)**
57. Which veins participate in formation of portocaval anastomosis at the level of abdominal esophagus:
- a) inferior diaphragmatic vein
  - b) medial diaphragmatic vein
  - c) left gastric vein**
  - d) right gastric vein
  - e) inferior esophageal veins**
58. Which are the branches of the celiac trunk?
- a) left gastric a.**
  - b) right gastric a.
  - c) common hepatic a.**
  - d) proper hepatic a.
  - e) splenic a.**
59. Which of the following statements concerning the Letarjet nerve are correct:
- a) is a long branch of the vagus nerve**
  - b) is a branch that innervate cardial part of the stomach
  - c) is a branch that innervate the antral and pyloric part of the stomach**
  - d) passes on lesser curvature of the stomach between laminae of hepatogastric ligament**
  - e) passes between the laminae of phrenicogastric ligament
60. Which vessels start from the splenic artery?
- a) a. gastrica sinistra
  - b) a. gastrica dextra
  - c) a. gastroepiploica sinistra**
  - d) aa. gastrici brevis**
  - e) a. hepatica propria and gastroepiploica dextra
61. The route of the splenic artery is:
- a) along the posterior margin of the pancreas
  - b) along the inferior margin of the pancreas
  - c) along the superior margin of the pancreas**
  - d) through the pancreatic parenchyma
  - e) it has no relationships with the pancreas
62. Right mesenteric sinus is bounded by:
- a) mesentery of sigmoid colon
  - b) superior - transverse colon and its mesocolon**
  - c) from the right - ascending colon**
  - d) medial - descendent colon
  - e) from the left and inferior – the mesentery of small intestine**
63. Which are the intraperitoneal parts of the large intestine?
- a) cecum

- b) ascending colon, descending colon
  - c) **appendix, transverse and sigmoid colon, supraampullary part of the rectum**
  - d) **supraampullary part of rectum**
  - e) ampullary part of the rectum
64. Which parts of the large intestine are located mesoperitoneal?
- a) **cecum**
  - b) **ascending colon**
  - c) appendix, transverse and sigmoid colon
  - d) **descending colon**
  - e) **ampullary part of the rectum**
65. Which of the following statements concerning the small intestine are WRONG?
- a) **it is situated mesoperitoneal**
  - b) is situated intraperitoneal
  - c) receives blood supply from superior mesenteric a.
  - d) **receives blood supply from the inferior mesenteric a.**
  - e) ileal arteries and jejunal arteries start from the left semicircumference of the superior mesenteric artery
66. The right part of the large intestine receives blood supply from:
- a) splenic artery
  - b) gastroepiploic arteries
  - c) inferior mesenteric artery
  - d) **superior mesenteric artery**
  - e) appendicular artery
67. The most common place of pus accumulation in case of perforating appendicitis are:
- a) **right lateral canal**
  - b) duodenojejunal recessus of Treitz
  - c) **subdiaphragmal space**
  - d) pregastric bursa
  - e) cavity of pelvis
68. What veins connect the portal vein system with inferior vena cava system?
- a) left gastric vein, esophageal veins, azygos and hemiazygos
  - b) **superior rectal vein, medial rectal veins, and internal iliac vein**
  - c) **paraumbilical veins, inferior epigastric vein, external iliac vein**
  - d) superior epigastric vein and internal thoracic vein
  - e) all are incorrect
69. Appendicular artery passes is localized:
- a) retroperitoneal
  - b) within small intestine mesentery
  - c) **within appendicular mesentery**
  - d) on the posterior surface of the cecum
  - e) posterior to the terminal part of small intestine
70. The appendicular artery is a branch of:
- a) right colic a.
  - b) **ileocolic a.**
  - c) a. colica media
  - d) ileal a.
  - e) external iliac a.
71. What nerves form celiac plexus?
- a) **greater and lesser splanchnic nerves**
  - b) **vagus and right phrenic nerves**
  - c) hepatic plexus
  - d) lumbar plexus
  - e) intercostal and subcostal nerves
72. Which of the following statements concerning the right lateral canal are correct?
- a) **from the right it is limited by the anterolateral wall of the abdomen**

- b) **from the left it is limited by ascending colon**
  - c) **superiorly communicates with the subhepatic bursa and right hepatic bursa**
  - d) **inferiorly communicates with the right iliac fossa and cavity of the pelvis**
  - e) it is situated medially to the ascending colon
73. Which of the following statements concerning the left lateral canal are correct?
- a) **from the left it is limited by the anterolateral wall of the abdomen**
  - b) **from the right it is limited by descending and sigmoid colon**
  - c) **it is situated superiorly to the phrenicocolic ligament**
  - d) **inferiorly it communicates with the cavity of the pelvis**
  - e) inferiorly does not communicate with the cavity of the pelvis
74. Which of the following recesses are situated in the ileocecal flexure of the intestine?
- a) subhepatic recess
  - b) **superior ileocecal recess**
  - c) **inferior ileocecal recess**
  - d) retroappendicular recess
  - e) **retrocecal recess**
75. What artery supplies the left half of the colon?
- a) superior mesenteric a.
  - b) **inferior mesenteric a.**
  - c) celiac trunk
  - d) lumbar aa.
  - e) a. colica media
76. The Riolan's arcade is formed by the anastomosis of the following arteries:
- a) median colic and right colic arteries
  - b) ileocolic and right colic arteries
  - c) **median colic and left colic arteries**
  - d) left colic and sigmoid arteries
  - e) median colic and ileocolic arteries
77. The critical segments in the colon vascularisation are:
- a) incipient portion of the jejunum
  - b) **terminal ileon and iliocecal angle (Trave)**
  - c) **splenic flexure of the colon (Griffiths)**
  - d) hepatic flexure of the colon
  - e) **rectosigmoid portion of the colon (Zudeck)**
78. List the branches of the superior mesenteric artery:
- a) **ileocolic a.**
  - b) **right colic a.**
  - c) left colic a.
  - d) sigmoid aa.
  - e) **a. colica media**
79. Which surface of the liver is not covered by peritoneum?
- a) Superior surface
  - b) **Posterior surface**
  - c) Inferior surface
  - d) Anterior surface
  - e) none is correct
80. How many segments are distinguished in the duodenum?
- a) 2
  - b) **4**
  - c) 5
  - d) 3
  - e) 7
81. Projection points of the base of the appendix on antero - lateral wall of abdomen are:
- a) Moris Chimmel point

- b) **McBurney point**
- c) Douglas point
- d) Sonnemburg point
- e) **Lanz point**

82. How many sphincters does greater duodenal papilla have:

- a) 2 sphincters
- b) 4 sphincters
- c) 1 sphincter
- d) **3 sphincters**
- e) it doesn't have any sphincters, because the antireflux mechanism is sustained by valves

83. Which structure is present in the hernial sac in case of Littre's hernia?

- a) vermicular appendix
- b) the intestinal wall
- c) **Meckel diverticulum**
- d) greater omentum
- e) colon

84. Skelotopy of the left kidney is:

- a) **between 11'th and 12'th thoracic vertebrae**
- b) between 10'th and 11'th thoracic vertebrae
- c) between 1'st and 2'nd lumbar vertebrae
- d) between 12'th thoracic and 1'st lumbar vertebrae
- e) between 2'nd and 3'rd lumbar vertebrae

85. The anterior-inferior surface of the stomach is projected on the anterolateral abdominal wall in the following limits (Labbe's triangle):

- a) **left - the left costal margin**
- b) left – the margin of the rectus abdominis muscle
- c) **superior – the line connecting the left 10'th rib and right 8'th rib**
- d) right – the right costal margin
- e) **inferior - the line connecting the 10'th ribs bilaterally**

86. What are the boundaries of Moosman area?

- a) left – the proper hepatic artery
- b) right - the common hepatic bile duct
- c) **left - the common hepatic bile duct**
- d) **inferior-lateral - the cystic duct**
- e) **superior - lower surface of the liver**

87. What factors contribute to spreading of pathologic liquids from the right iliac fossa to supramesocolic compartment of the peritoneal cavity?

- a) **the movements of the diaphragm**
- b) contractions of anterolateral abdominal muscles
- c) **ascending colon peristalsis**
- d) liquids do not spread because of right hepatocolic ligament
- e) **the inclined surface of posterior abdominal wall**

88. Places for accumulation of pus in case of perforated appendicitis are:

- a) **hepatorenal recess (Morrison recess)**
- b) duodenojejunal recess of Treits
- c) **subdiafragmal space**
- d) **right mesenteric sinus**
- e) **pelvic cavity**

89. Relationships of duodenal segments with peritoneum are:

- a) **the upper segment is intraperitoneal**
- b) **the descending segment is retroperitoneal**
- c) **the lower segment is retroperitoneal**
- d) **the ascending segment is mesoperitoneal**
- e) duodenum is a totally retroperitoneal organ.

90. Select the correct statement regarding Meckel diverticulum:

- a) **is a congenital vestigial remnant that can be present in the adult, that has a "glove finger" shape, localized on the antimesenteric margin of the terminal ileum**
- b) is an acquired vestige in the adult, that has a "glove finger" shape, localized on the mesenteric margin of the terminal ileum
- c) is vestigial remnant that can appear in the adult, that has a "glove finger" shape, localized on the mesenteric margin of the terminal ileum
- d) is vestigial remnant that can appear in the adult, that has a "glove finger" shape, localized on the mesenteric margin of the terminal jejunum
- e) ) is a congenital vestigial remnant that can be present in the adult, that has a "glove finger" shape, localized on the antimesenteric margin of sigmoid colon

91. Note the correct statement regarding Meckel diverticulum:

- a) it is located 70–100 cm distally to the duodenojejunal flexure and has a “glove finger” shape.
- b) umbilical segment of omfalomesenteric duct is not obliterated
- c) **only the umbilical segment of omfalomesenteric duct is obliterated**
- d) **it is a vestigial remnant of the omphalomesenteric duct**
- e) **it is located within 70–100 cm of the ileocecal valve and has a “glove finger” shape**

92. What are the criteria for distinguishing the large intestine from small intestine during surgery?

- a) **diameter and color**
- b) **the presence of haustra and taenia**
- c) **the presence of epiploic appendices**
- d) the presence of visceral peritoneum
- e) density and hardness

93. Skeletotopy of spleen is:

- a) **between 8'th and 10'th ribs**
- b) between 8'th and 12'th ribs
- c) between 10'th and 12'th ribs
- d) between 7'th and 12'th ribs
- e) between 5'th and 10'th ribs

94. Select the correct statements regarding the topography of the spleen:

- a) **holotopy – it is located in the left hypochondrium**
- b) **skeletotopy – it is situated between VIII'th and X'th ribs**
- c) **syntopy – concave surface adheres to the diaphragm; superiorly and medially – to the gastric fundus; inferiorly and medially – to the tail of the pancreas**
- d) syntopy – concave surface adheres superiorly to the diaphragm and inferiorly to the suprarenal gland; superiorly and medially – to the body of the stomach; inferiorly and medially – to the upper pole of the left kidney
- e) holotopy – it is located in the left hypochondrium, scheletotopy – it is intersected by the VII'th rib



## OPERATIONS ON THE ABDOMINAL CAVITY

1. What is laparotomy?

- a) **surgical procedure that consists of opening the abdominal cavity**
- b) surgical procedure that consists of closing the abdominal cavity
- c) surgical procedure that consists of suturing of abdominal wall
- d) **surgical approach to the abdominal organs**
- e) none of the variants are correct

2. What layers are dissected during appendectomy through McBurney incision:

- a) skin, subcutaneous tissue, transverse abdominal muscle, preperitoneal tissue, peritoneum
- b) skin, subcutaneous tissue, aponeurosis of the external oblique muscle, preperitoneal tissue, peritoneum
- c) **skin, subcutaneous tissue, aponeurosis of the external oblique muscle, internal oblique and transverse muscles, preperitoneal tissue, peritoneum**
- d) skin, subcutaneous tissue, external oblique muscle, internal oblique and transverse muscles, preperitoneal tissue, peritoneum
- e) all variants are incorrect

3. What types of incisions are performed to get access to the stomach?

- a) middle midline laparotomy
- b) lower midline laparotomy
- c) **upper midline laparotomy**
- d) **transrectal laparotomy**
- e) **laparoscopic approach**

4. During stomach resection – Billroth II procedure:

- a) anastomosis is created between duodenum and jejunum
- b) anastomosis is created between residual stomach and duodenum
- c) anastomosis is created between duodenum and ileum
- d) **the duodenal stump is completely sutured**
- e) the duodenal stump is not sutured

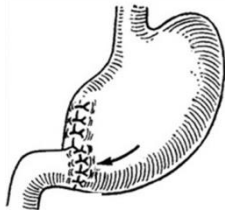5. What structure can be injured during creating a hole in the transverse mesocolon? Creating hole in the transverse mesocolon is a phase in gastric resection Billroth II procedure, when a retrocolic anastomosis between residual stomach and jejunum is performed.

- a) common bile duct (retroduodenal segment)
- b) portal vein
- c) superior mesenteric a.
- d) inferior mesenteric a.
- e) **middle colic artery**

6. Billroth II gastric resection (Hoffmeister-Finsterer modification) consists of creating an anastomosis between residual stomach and short loop (8-10cm) of jejunum. In this cases, through which structure the jejunum is brought in the superior compartment of peritoneal cavity and what is the relationship with the transverse colon?

- a) anterior to transverse colon (antecolic)
- b) through greater omentum
- c) **posterior to transverse colon (retrocolic)**
- d) **through the transverse mesocolon**
- e) through the mesenterium

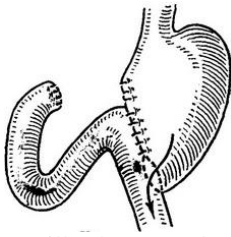
7. What gastric resection procedure is represented in the picture?



- a) **Billroth I procedure**
- b) Billroth II procedure
- c) Hoffmeister-Finsterer procedure
- d) Kocher procedure

e) Balfour procedure

8. What gastric resection procedure is represented in the picture?



- a) Billroth I procedure
- b) Billroth II procedure**
- c) Hoffmeister-Finsterer procedure
- d) Kocher procedure
- e) Balfour procedure

9. During gastric resection (procedure Hoffmeister-Finsterer), an anastomosis is created between:

- a) residual stomach sutured 2/3 and upper duodenum
- b) residual stomach sutured completely and ileum
- c) residual stomach sutured 2/3 and jejunum**
- d) residual stomach sutured 2/3 and the horizontal part of duodenum
- e) end-to-end anastomosis between residual stomach and small intestine

10. During mobilization of the stomach for resection, what ligament should not be cut:

- a) gastrophrenic ligament
- b) hepatogastric ligament
- c) hepatoduodenal ligament**
- d) gastrocolic ligament
- e) gastrosplenic ligament

11. One of the surgical phases during gastric resection is ligation of left gastric artery. Where it is located and where this artery is ligated?

- a) in small omentum**
- b) in the hepatogastric ligament
- c) in the gastrocolic ligament
- d) in gastropancreatic ligament
- e) in cardial part of stomach

12. Select the gastric resection procedure that maintains a physiological passage of food:

- a) Hoffmeister-Finsterer
- b) Ryhle-Polya
- c) Billroth II
- d) Billroth I**
- e) Roux

13. Select the indication for applying of artificial anus:

- a) cancer of the sigmoid
- b) gastric cancer
- c) gastric fistula (Toprover type)
- d) inoperable rectal cancer**
- e) strangulated femoral hernia

14. Select the indications for gastroenterostomy:

- a) gastric ulcer complicated with perforation
- b) duodenal ulcer complicated with perforation
- c) cardial gastric cancer
- d) inoperable antral cancer**
- e) inoperable cancer of the head of pancreas**

15. Indications for gastrostomy:

- a) inoperable gastric cancer

- b) stomach ulcer
- c) pilorostenosis
- d) narrowing of the esophagus**
- e) inoperable esophageal cancer**

16. Which of the interventions listed below are palliative:

- a) cholecystectomy
- b) appendectomy
- c) colostomy**
- d) creating artificial anus**
- e) left hemicolectomy

17. Which of the interventions listed below are considered to be radical?

- a) gastric resection for cancer**
- b) gastric resection for ulcer disease**
- c) pancreaticoduodenal resection for pancreatic head cancer**
- d) gastrostomy in case of esophageal cancer
- e) gastroenterostomy in case of stomach cancer

18. Which interventions performed on the colon, listed below, are considered to be radical?

- a) inter-intestinal anastomosis
- b) applying of intestinal stoma in case of colon cancer
- c) hemicolectomy**
- d) transverse colon resection**
- e) creating artificial anus

19. What should be the length of the intestinal loop in order to perform a posterior retrocolic gastroenterostomy?

- a) 5-10 cm
- b) 15-20 cm**
- c) 20-30 cm
- d) 30-40 cm
- e) 45-50 cm

20. What should be the length of the intestinal loop in order to perform an anterior antecolic gastroenterostomy?

- a) 10-15 cm
- b) 15-20 cm
- c) 20-30 cm
- d) 30-40 cm
- e) 40-60 cm**

21. Gastrojejunostomy is a surgical procedure in which an anastomosis is created between the stomach and the proximal loop of the jejunum. Select the variants of gastroenterostomies that can be performed:

- a) anterior antecolic gastroenterostomy**
  - b) posterior antecolic gastroenterostomy**
  - c) anterior retrocolic gastroenterostomy**
  - d) posterior retrocolic gastroenterostomy**
  - e) anterior-posterior gastroenterostomy
- ! Must be reviewed

22. Note what are the indications for splenectomy:

- a) massive rupture of the spleen**
- b) splenomegaly**
- c) echinococcus hydatid cyst**
- d) cancer major duodenal papilla
- e) fracture of V-VII left ribs

23. In the thickness of what anatomical structure the splenic vessels are ligated in case of splenectomy:

- a) hepatogastric ligament
- b) gastropancreatic ligament
- c) gastrosplenic ligament**
- d) lesser sac
- e) hepatoduodenal ligament

24. Select the methods of hemostasis in case case of liver damage?
- Kuzniřov-Penschi suture**
  - plasty of liver wounds with omentum**
  - use of hemostatic sponge**
  - Albert suture
  - Lambert suture
25. What incisions are performed to get access to the liver:
- Fiodorov incision**
  - Courvoisier-Kocher incision**
  - Rio-Branco incision**
  - Pfannenstiel incision
  - Lenander incision
26. Select the types of appendectomy:
- intermedian appendectomy
  - mixed appendectomy**
  - anterograde appendectomy**
  - retrograde appendectomy**
  - all answers are correct
27. Select the incisions performed to get acces to vermicular appendix:
- Kocher incision
  - Pfannenstiel incision
  - Lenander incision**
  - Mc Burney incision**
  - middle midline laparotomy**
28. What is gastrostomy?
- gastrostomy is the creation of an external gastric fistula**
  - gastrostomy is the creation of a jejunal fistula
  - gastrostomy is the creation of a ileal fistula
  - gastrostomy is the creation of a fistula between the stomach and the jejunum
  - gastrostomy is the creation of a fistula between the stomach and the duodenum
29. Select the surgical techniques that are used in the treatment of perforated ulcer?
- simple suture of the ulcer**
  - suturing and plumbing the ulcer with a part of omentum**
  - excision and suturing of the ulcer**
  - perforated ulcer is not operated
  - truncal vagotomy
30. What is enterotomy?
- surgical procedure that open the gastric lumen
  - surgical procedure that open the intestinal lumen**
  - surgical procedure that close the intestinal lumen
  - surgical procedure that consists of creating a interintestinal anastomosis
  - surgical procedure that consists of creating a gastroenteroanastomosis
31. The anastomosis is applied in order to restore the intestinal tract continuity. Depending the type of connection we distinguish:
- end-to-end anastomosis**
  - side-to-side anastomosis**
  - end-to-side anastomosis**
  - side-to-end anastomosis**
  - anastomosis between the proximal and afferent loop
32. One of nonsurgical methods to stop the bleeding from esophageal veins is tamponade the esophageal veins. What type of device is used for tamponade (hemostasis) of esophageal veins:
- tamponade of the esophagus with Foley tube
  - tamponade of the esophagus with Linton tube
  - tamponade of the esophagus with Linton – Nachlas tube
  - tamponade of the esophagus with Sengstaken-Blakemore tube**

e) tamponade of the esophagus with nasogastric tube

33. What type of device, used for stopping the bleeding from esophageal veins, is represented in the picture:



a) Fogarty tube

b) Linton tube

c) Linton-Nachlas tube

**d) Sengstaken-Blakemore tube**

e) nasogastric tube

34. Cholecystectomy is a surgical procedure that consists of removal of the gallbladder. Select the insisions performed to get access to gallbladder:

a) **superior midline laparotomy**

**b) right subcostal (Kocher) laparotomy**

c) **angular laparotomy (Rio - Branco approach)**

**d) laparoscopic approach**

e) middle midline laparotomy

35. Select the methods of removing the gallbladder:

a) **anterograde cholecystectomy**

**b) retrograde cholecystectomy**

c) **bipolar cholecystectomy**

d) cholecystotomy

e) cholecystostomy

36. Select the particularities of intestinal suture:

a) it is a type of suture applied on all organs of abdominal cavity

b) it is a type of suture applied on pharynx, esophagus, stomach

**c) it is a type of suture applied on small and large intestines**

**d) only round needles (intestinal) are used in this type of suture**

e) only triangular needles ("cutting" needles) are used in this type of suture

37. Select the principles that should be in applying of an intestinal suture:

**a) superposition of homologous tissues**

**b) it should be hermetic and durable**

**c) maintain good blood supply and adequate hemostasis**

**d) avoid excessive narrowing of the lumen**

e) superposition of two segments of different caliber

! Must be reviewed

38. Select the types of intestinal suture according to its communication with the intestinal lumen:

**a) penetrating (all layers of intestinal wall are included)**

**b) non-penetrating (extramucosal)**

c) sero-serosal suture

d) sero-muscular

e) continuous suture

39. Select the types of non-penetrating (extramucosal) intestinal suture:

**a) sero-serosal**

b) continuous suture

**c) sero-muscular**

**d) sero-muscular-submucosal**

e) mucosal

40. Select the types of intestinal sutures according to apposition of the intestinal wall layers:

a) marginal

b) inverting suture (apposition of serosal layers)

c) everting suture (apposition of mucosal layers)

- d) combined (inverting-everting)
  - e) sero-serosal
41. Select the particularities of Lembert intestinal suture:
- a) **apposition of serosal layers**
  - b) **it is used in gastrointestinal surgery**
  - c) **it is used to suture the gastric and intestinal wounds**
  - d) **it is a sero-serosal suture**
  - e) it is a purse-string suture
42. Select the particularities of laparocentesis:
- a) **it is a puncture of peritoneal cavity**
  - b) **it can be performed in the point situated in middle of the line that connects the umbilicus and superior margin of the pubic symphysis**
  - c) it is performed on the superior margin of the pubic symphysis
  - d) **it is a diagnostic and therapeutic procedure**
  - e) **it can be performed in the point situated in middle of the line that connects the umbilicus and superior anterior iliac spine.**
43. Select the intestinal suture patterns that can be used in suturing of small wounds of the intestine:
- a) **sero-muscular suture**
  - b) **purse-string suture**
  - c) **Z-shaped suture**
  - d) double layer suture
  - e) triple layer suture
44. Select the surgical approach to the pancreas:
- a) **through gastrocolic ligament**
  - b) through lesser omentum
  - c) through lumbar region
  - d) through epiploic foramen
  - e) through gastrosplenic ligament

## SPINAL REGION

1. Select the normal inward (anterior) curvatures of the spine:
  - a) **cervical curvature – lordosis**
  - b) thoracic curvature – lordosis
  - c) lumbar curvature – kyphosis
  - d) sacral curvature – kyphosis
  - e) **lumbar curvature – lordosis**
2. Which ligaments fix the vertebral bodies along the vertebral column?
  - a) interspinal ligaments of vertebrae
  - b) **anterior longitudinal ligament**
  - c) **posterior longitudinal ligament**
  - d) ligamenta flava
  - e) transverse ligaments
3. Determine the right sequence (order) of the meningeal layers of spinal cord, from exterior to interior:
  - a) Pia matter, arachnoid, dura matter
  - b) **Dura matter, arachnoid, pia matter**
  - c) Arachnoid, dura matter, pia matter
  - d) Arachnoid, pia matter, dura matter
  - e) Dura matter, pia matter, arachnoid
4. Select the right definition of kyphosis:
  - a) **Curvature of the vertebral column with the convexity oriented posteriorly**
  - b) Curvature of the vertebral column with the convexity oriented anteriorly
  - c) Curvature of the vertebral column with the convexity oriented laterally
  - d) Curvature of the vertebral column with the convexity oriented medially
  - e) Vertebral column has no curvatures
5. Select the right definition of scoliosis:
  - a) Curvature of the vertebral column with the convexity oriented posteriorly
  - b) Curvature of the vertebral column with the convexity oriented anteriorly
  - c) **Curvature of the vertebral column with the convexity oriented laterally**
  - d) Curvature of the vertebral column with the convexity oriented medially
  - e) Vertebral column has no curvatures
6. Select the right definition of lordosis:
  - a) Curvature of the vertebral column with the convexity oriented posteriorly
  - b) **Curvature of the vertebral column with the convexity oriented anteriorly**
  - c) Curvature of the vertebral column with the convexity oriented laterally
  - d) Curvature of the vertebral column with the convexity oriented medially
  - e) Vertebral column has no curvatures
7. Select the WRONG definitions of the vertebral column's curvatures:
  - a) Cervical curvature with the convexity oriented anteriorly - lordosis
  - b) Thoracic curvature with the convexity oriented posteriorly - kyphosis
  - c) **Lumbar curvature with the convexity oriented anteriorly - kyphosis**
  - d) **Sacral curvature with the convexity oriented posteriorly - lordosis**
  - e) Lumbar curvature with the convexity oriented anteriorly - lordosis
8. Which arteries supply the cervical vertebrae?
  - a) **vertebral arteries**
  - b) **ascending cervical arteries**
  - c) **deep cervical arteries**
  - d) external carotid artery
  - e) internal carotid artery
9. Which arteries supply the thoracic vertebrae?
  - a) Inferior epigastric arteries
  - b) **Supreme intercostal arteries**
  - c) **Intercostal arteries**

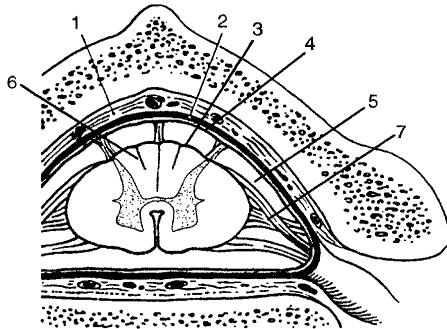
- d) Transverse arteries of the neck
  - e) Superficial cervical arteries
10. Which arteries supply the lumbar and sacral vertebrae:
- a) **lumbar arteries.**
  - b) **lateral sacral arterie.**
  - c) **median sacral artery**
  - d) superior rectal artery
  - e) inferior rectal artery
11. The lumbar puncture is performed:
- a) Between spinous processes of Th<sub>11-12</sub> vertebrae
  - b) Between spinous processes of Th<sub>12-11</sub> vertebrae
  - c) Between spinous processes of L<sub>1-2</sub> vertebrae
  - d) Between spinous processes of T<sub>2-3</sub> vertebrae
  - e) **Between spinous processes of L<sub>3-4</sub> vertebrae or L<sub>4-5</sub>**
12. In children, the lumbar puncture is performed:
- a) Between spinous processes of Th<sub>12</sub> - L<sub>1</sub> vertebrae
  - b) Between spinous processes of L<sub>1-2</sub> vertebrae
  - c) Between spinous processes of L<sub>2-3</sub> vertebrae
  - d) Between spinous processes of L<sub>3-4</sub> vertebrae
  - e) **Between spinous processes of L<sub>4-5</sub> vertebrae**
13. Where is situated the spinal epidural space?
- a) between dura mater and arachnoid
  - b) **between the periosteum of the spinal canal and dura mater**
  - c) between arachnoid and pia mater
  - d) between laminae of dura mater
  - e) between dura mater and pia mater
14. Where is situated the subdural space?
- a) between pia mater and brain
  - b) between laminae of dura mater
  - c) **between dura mater and the arachnoid**
  - d) between dura mater and the periosteum of spinal canal
  - e) between the arachnoid and pia mater
15. Where is situated the subarachnoid space?
- a) between pia mater and brain
  - b) between laminae of dura mater
  - c) between dura mater and the arachnoid
  - d) between dura mater and the periosteum of spinal canal
  - e) **between the arachnoid and pia mater**
16. How many pairs of spinal nerves with the origin in the spinal cord we can distinguish:
- a) C - 7, Th - 12, L - 5, S - 5, Co - 1 = 30 pairs of spinal nerves
  - b) **C - 8, Th - 12, L - 5, S - 5, Co - 1 = 31 pairs of spinal nerves**
  - c) C - 8, Th - 12, L - 5, S - 5, Co - 2 = 32 pairs of spinal nerves
  - d) C - 9, Th - 13, L - 6, S - 4, Co - 1 = 33 pairs of spinal nerves
  - e) C - 10, Th - 12, L - 5, S - 5, Co - 3 = 35 pairs of spinal nerves
17. Select the correct answer:
- a) **imaginary line that connects both inferior angles of the scapula corresponds to spinous apophysis of Th8**
  - b) imaginary line that connects both inferior angles of the scapula corresponds to spinous apophysis of Th5
  - c) **imaginary horizontal line passing through both spina scapulae corresponds to Th3**
  - d) **the imaginary line connecting both iliac crests corresponds to L4-L5**
  - e) imaginary line connecting both iliac crests corresponds to L3-L4
18. What layers are pierced during lumbar puncture?
- a) **skin and subcutaneous fat tissue**
  - b) **supraspinous, interspinous and yellow ligaments**



- c) **dura mater and arachnoid**
  - d) dura mater and pia mater
  - e) supraspinous, intertransversal and yellow ligaments
19. The epidural space contains:
- a) **cellular tissue**
  - b) denticulate ligament
  - c) **venous plexus**
  - d) connective tissue
  - e) cerebrospinal fluid
20. Where is the subdural space situated?
- a) under the pia mater
  - b) under arachnoid
  - c) **between the dura mater and arachnoid**
  - d) between the dura mater and periosteum of the spinal canal
  - e) between the arachnoid and pia mater
21. What space that contains cerebrospinal fluid?
- a) epidural
  - b) subdural
  - c) **subarachnoid**
  - d) between dura mater foils
  - e) none is correct
22. Which statement are correct?
- a) **the average diameter of the spinal canal is 2.5 cm<sup>2</sup>**
  - b) **the diameter of spinal canal in lumbar region is 3.5 cm<sup>2</sup>**
  - c) **the diameter of spinal canal in cervical region is 2.9 cm<sup>2</sup>**
  - d) the diameter of spinal canal in lumbar region is 2.5 cm<sup>2</sup>
  - e) the average diameter of the spinal canal is 3.5 cm<sup>2</sup>
23. What is the relationship between the origin of the spinal nerves from spinal cord and the exit of spinal nerves from the spinal canal in the cervical region?
- a) **in the upper cervical region – the nerves have a horizontal direction**
  - b) upper cervical region – the nerves have a diagonal direction
  - c) **in the inferior cervical region and the superior thoracic region – the origins of spinal nerves are situated one vertebrae above the exit level from spinal canal**
  - d) in the inferior cervical region and the superior thoracic region – the origins of spinal nerves are situated two vertebrae above the exit level from spinal canal
  - e) in the inferior cervical region and the superior thoracic region – the origins of spinal nerves are situated at the same level as the exit from spinal canal
24. What is the relationship between the origin of the spinal nerves from spinal cord and the exit of spinal nerves from the spinal canal in the thoracic and lumbar region?
- a) **in the median thoracic region – the origins of spinal nerves are situated two vertebrae above the exit level from spinal canal**
  - b) in the inferior thoracic region – the origins of spinal nerves are situated two vertebrae above the exit level from spinal canal
  - c) **in the inferior thoracic region – the origins of spinal nerves are situated three vertebrae above the exit level from spinal canal**
  - d) **the exit level of lumbar spinal nerves are Th10,11 and partially Th12**
  - e) the exit level of lumbar spinal nerves is L1,2 and L3
25. The link between the sympathetic trunk and spinal nerves is done by:
- a) meningian branches
  - b) postganglionic branches
  - c) **communicating branches**
  - d) preganglionic branches
  - e) spinal ganglions
26. Select the CORRECT statements about Adamkiewicz artery:
- a) **Adamkiewicz artery supply lower 2/3 of the spinal cord**

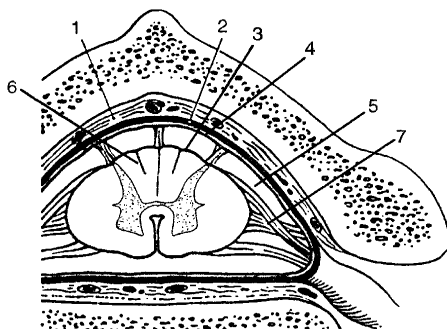
- b) **Adamkiewicz artery enters the spinal canal through an intervertebral orifice in 75% of cases from the left side (Th9-Th11)**
- c) Adamkiewicz artery in 25% of cases enters the spinal canal from the left side
- d) **Adamkiewicz artery has a diameter about 2 mm**
- e) Adamkiewicz artery has a diameter about 8 mm

27. Select the numbers that indicate the meningeal membranes of the spinal cord, from exterior to interior:



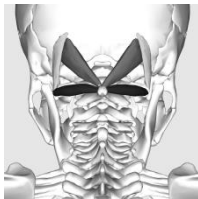- a) 1, 2, 4
- b) **2, 3, 4**
- c) 4, 5, 7
- d) 3, 4, 7
- e) 2, 4, 7

28. Select the numbers that indicate intermeningeal spaces of the spinal cord:



- a) 1, 2
- b) 2, 4
- c) **1, 5**
- d) 2, 5
- e) 4, 5

29. Select the limits of suboccipital triangle:



- a) **superior-lateral – obliquus capitis superior muscle**
- b) **inferior-lateral – obliquus capitis inferior muscle**
- c) **medial – rectus capitis major muscle**
- d) superior-external – semispinalis capitis muscle
- e) inferior-external – splenius capitis muscle

30. Select the anatomical structures that passes through suboccipital triangle:

- a) **suboccipitalis nerve**
- b) **vertebral artery**
- c) occipitalis minor nerve
- d) occipitalis major nerve
- e) basilaris artery

31. Which of the following statements about the intervertebral discs are WRONG?

- a) it constitute about 20% of the height of the spine
- b) consists of annulus fibrosus and nucleus pulposus
- c) they have a very good blood supply**
- d) the biomechanics of the spine depends on the condition of intervertebral discs
- e) are insignificant structures between two vertebrae**

## LUMBAR REGION

- Boundaries of lumbar region:
  - Superior** – XIIth rib
  - Inferior** – **iliac crests and sacrum**
  - Medial – paravertebral line
  - Medial** – vertical line passing through spinous processes of lumbar vertebrae
  - Lateral** – **the continuation of the middle axillary line**
- Which muscles are situated in the medial portion of the lumbar region?
  - psoas muscle**
  - erector spinae muscle**
  - quadratus lumborum muscle**
  - internal oblique abdominal muscle
  - external oblique abdominal muscle
- Which muscles are situated in the lateral portion of the lumbar region?
  - transverse abdominal muscle**
  - internal oblique abdominal muscle**
  - external oblique abdominal muscle**
  - psoas muscle
  - quadratus lumborum muscle
- What anatomical structure forms the sheath for erector spinae muscle?
  - fascia thoracolumbalis**
  - external oblique abdominal m.
  - internal oblique abdominal m.
  - transversal abdominal m.
  - trapezius m.
- Select the boundaries of lumbar triangle of Petit:
  - the margin of latissimus dorsi muscle**
  - the margin of external oblique abdominal muscle**
  - the margin of internal oblique abdominal muscle
  - superior margin of the iliac crest**
  - transverse abdominal muscle
- The floor of lumbar triangle of Petit is formed by:
  - latissimus dorsi m.
  - external oblique abdominal m
  - internal oblique abdominal m.**
  - iliac crest
  - transverse abdominal muscle
- Select the anatomical structure that passes through lumbar triangle of Petit:
  - lumbar artery
  - subcostal neurovascular bundle
  - iliohypogastric nerve
  - ilioinguinal nerve
  - no anatomical structure**
- The boundaries of the lumbar space of Grynfeltt-Lesshaft:
  - serratus posterior inferior muscle**
  - 12'th rib**
  - internal oblique abdominal muscle**
  - erector spinae muscle**
  - aponeurosis of the transverse abdominal muscle
- The floor of lumbar space of Grynfeltt-Lesshaft is formed by:
  - serratus posterior inferior muscle
  - 12'th rib
  - internal oblique abdominal muscle
  - erector spinae muscle

- e) **aponeurosis of transverse abdominal muscle**
10. The lumbar space of Grynfeltt-Lesshaft is situated under:
- a) serratus posterior inferior muscle
  - b) trapezius muscle
  - c) internal oblique abdominal muscle
  - d) erector spinae muscle
  - e) **latissimus dorsi muscle**
11. The lumbar space of Grynfeltt-Lesshaft is penetrated by:
- a) **subcostal neurovascular bundle**
  - b) 12th rib
  - c) iliohypogastric nerve
  - d) lumbar artery
  - e) psoas minor muscle
12. The lumbar triangle of Petit and the lumbar space of Grynfeltt-Lesshaft have clinical importance because:
- a) **they are weak points and here can form lumbar hernias**
  - b) **can serve as a miniinvasive access (endoscopic)**
  - c) **can serve as a place of draining of purulent collections from the retroperitoneal space**
  - d) serve as an external landmarks
  - e) can be easily determined anatomically, but have no clinical significance
13. Lumbocostal ligament is formed by:
- a) **aponeurosis of transverse abdominal muscle**
  - b) lombodorsal fascia
  - c) fascia propria
  - d) fascia quadrata
  - e) none is correct
14. What nerves pass between quadratus lumborum muscle and fascia that covers it:
- a) **subcostal nerve**
  - b) **iliohypogastric nerve**
  - c) **ilioinguinal nerve**
  - d) femoral nerve
  - e) sciatic nerve

## RETROPERITONEAL SPACE

- The limits of the retroperitoneal space are:
  - posterior – endoabdominal fascia**
  - posterior – retroperitoneal fascia
  - anterior – retroperitoneal fascia
  - anterior – posterior lamina of parietal peritoneum**
  - anterior - prerenal fascia
- Select the fascias that are situated in the retroperitoneal space:
  - fascia retroperitonealis**
  - fascia prerenalis**
  - fascia retrorenalis**
  - fascia retrocolica (Toldt's fascia)**
  - fascia endoretroperitonealis
- The proper retroperitoneal fatty tissue space is limited by:
  - fascia endoabdominalis (transverse fascia)**
  - fascia retrorenalis**
  - fascia prerenalis
  - fascia retroperitonealis
  - parietal peritoneum
- The paranephral fatty tissue space is limited by:
  - fascia endoabdominalis
  - fascia retrorenalis**
  - fascia prerenalis**
  - fascia retroperitonealis
  - parietal peritoneum
- The paracolic fatty tissue space is limited by:
  - fascia endoabdominalis and parietal peritoneum
  - fascia retrorenalis and parietal peritoneum
  - fascia prerenalis**
  - fascia retroperitonealis and parietal peritoneum
  - fascia retrocolica (Toldt's fascia) and parietal peritoneum**
- Select the anatomical structures that are situated in the proper retroperitoneal fatty tissue space?
  - branches of the lumbar plexus**
  - sympathetic trunk**
  - lymph nodes**
  - celiac plexus
  - superior mesenteric plexus
- What anatomical structures are situated in paranephral fatty tissue space?
  - kidneys and renal pedicles**
  - adrenal glands**
  - the abdominal aorta**
  - inferior vena cava**
  - portal vein
- What anatomical structures are situated in paracolic fatty tissue space?
  - ureter
  - the descending and inferior horizontal parts of the duodenum**
  - pancreas**
  - suprarenal gland
  - aorta and inferior vena cava
- Fascial sheath for the suprarenal gland is formed by:
  - fascia endoabdominalis
  - fascia retrorenalis
  - fascia prerenalis**

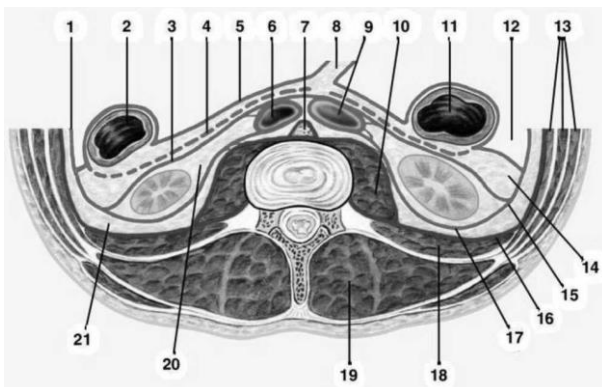
- d) fascia retroperitonealis
  - e) fascia retrocolica
10. Select the possible routs of pus and hematomas spreading from proper retroperitoneal space:
- a) in the paranephral fatty tissue space
  - b) in the paracolic fatty tissue space
  - c) **in the parapleural space through weak points of the diaphragm**
  - d) **in the inguinal region through lacuna musculorum**
  - e) in the paraureteral space
11. Select the direct possible rout of pus spreading from paranephral space:
- a) in the proper retroperitoneal fatty tissue space
  - b) in the paracolic fatty tissue space
  - c) **direct spreading is not possible, because the collection of pus is delimited by strong fascial septa**
  - d) parietal fatty tissue space of the pelvis
  - e) in the paraureteral space
12. Possible direct routs of pus spreading from paracolic space:
- a) in the parapleural and subdiaphragmal extraperitoneal spaces
  - b) in the proper retroperitoneal fatty tissue space
  - c) in the parapleural space
  - d) **in the parietal fatty tissue space of the pelvis**
  - e) in the paraureteral space
13. The ureter's syntopy with the retroperitoneal structures are:
- a) posterior from the lumbar arteries and veins
  - b) **posteriorly to the testicular (ovarian) vessels**
  - c) **anteriorly to the genitofemoral nerves**
  - d) **it is attached to the parietal peritoneum at the level of linea terminalis of the pelvis**
  - e) lateral from the quadratus lumborum muscle
14. The femoral nerve is situated between:
- a) the psoas major muscle and quadratus lumborum muscle
  - b) **iliac muscle and psoas major muscles**
  - c) the greater and lesser psoas
  - d) quadratus lumborum muscle and its fascia
  - e) psoas muscle and common iliac vessels
15. Where is situated the genitofemoral nerve?
- a) **it penetrates the psoas fascia, then runs on the anterior face of psoas major muscle**
  - b) on the posterior surface of psoas major muscle
  - c) between psoas major and quadratus lumborum muscles
  - d) between psoas major and iliac muscles
  - e) between transverse fascia and the parietal peritoneum
16. The aberrant renal artery:
- a) **can cause hydronephrosis**
  - b) **it can start from the renal artery or the aorta**
  - c) **the majority of aberrant arteries supply the inferior pole of the kidney**
  - d) **ignoring of this artery during surgery can lead to profuse bleeding or necrosis of the inferior pole of the kidney**
  - e) it has no clinical significance
17. What structures the ureters cross in the retroperitoneal space?
- a) **on the left - common iliac artery**
  - b) **on the right - external iliac artery**
  - c) on the left - external iliac artery
  - d) on the right - common iliac artery
  - e) on the left and right - common iliac artery
18. Kidney projection on the anterolateral abdominal wall is:
- a) **in the epigastric, right and left hypochondrium regions**
  - b) in the mesogastric region and lateral abdominal regions

- c) in the epigastric and mezogastric regions
  - d) in the hypogastric, right and left inguinal regions
  - e) in the umbilical region and lateral abdominal regions
19. The renal hilum projection on the anterior abdominal wall is:
- a) **at the intersection of rectus abdomini muscle with costal arch**
  - b) 5 cm below the intersection of rectus abdominis muscle with costal arch
  - c) at the level of costal arch and xiphoid process
  - d) 2 cm above of umbilicus
  - e) at the level of apex of xiphoid process
20. The renal hilum projection on the posterior abdominal wall is
- a) **at the intersection of lateral margins of erector spinae muscle and 12'th rib**
  - b) 10 cm below the intersection of lateral margins of erector spinae muscle with 12'th rib
  - c) 5 cm below the intersection of lateral margins of erector spinae muscle with 12'th rib
  - d) at the intersection of an imaginary horizontal line drawn through the L3 and linea scapularis
  - e) at the middle of the distance between the 12'th rib and iliac crest
21. The structures of renal hilum from anterior to posterior are placed in the following order:
- a) Artery, vein, ureter
  - b) **Vein, artery, ureter**
  - c) Artery, ureter, vein
  - d) Ureter, artery, vein
  - e) Vein, ureter, artery
22. The syntopy of the right kidney:
- a) **right lobe of liver**
  - b) **descending part of duodenum**
  - c) **superior portion of the ascending colon and the small intestine loops**
  - d) aorta
  - e) stomach
23. The syntopy of the left kidney:
- a) **tail of pancreas and spleen**
  - b) **superior portion of the descending colon**
  - c) **small intestine loops**
  - d) **posterior wall of the omental bursa**
  - e) sigmoid colon
24. The syntopy of the right suprarenal gland:
- a) **anteriorly – right lobe of the liver**
  - b) **posteriorly – the diaphragm**
  - c) abdominal aorta
  - d) **inferior vena cava**
  - e) **ganglions of the coeliac plexus**
25. The syntopy of the left suprarenal gland:
- a) **body of pancreas**
  - b) **posterior wall of omental bursa**
  - c) inferior vena cava
  - d) **abdominal aorta and coeliac plexus**
  - e) **diaphragm from the posterior**
26. Projection of the ureters on anterolateral abdominal wall:
- a) **at lateral margins of the rectus abdominis muscles**
  - b) at medial margins of the rectus abdominis muscles
  - c) 6 cm laterally to the lateral margin of rectus abdominis muscle
  - d) 6 cm medially to the medial margin of rectus abdominis muscle
  - e) on linea alba
27. Projection of the ureters on the posterior abdominal wall:
- a) corresponds to the vertical line that passes through anterior margin of 12'th rib
  - b) **the line that connects the transverse processes of lumbar vertebrae**



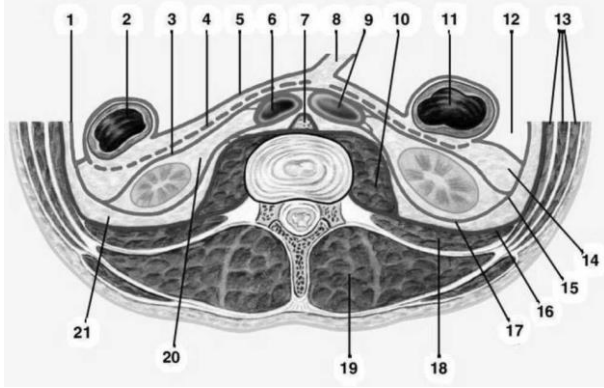
- c) corresponds to scapular lines
  - d) corresponds to posterior axillary lines
  - e) corresponds to middle axillary lines
28. Select the visceral branches of abdominal aorta:
- a) **celiac artery**
  - b) **testicular (ovarian) arteries**
  - c) **superior and inferior mesenteric arteries**
  - d) **renal and median suprarenal arteries**
  - e) inferior phrenic arteries
29. Select the parietal branches of abdominal aorta:
- a) **inferior phrenic arteries**
  - b) **lumbar arteries**
  - c) **median sacral artery**
  - d) testicular (ovarian) arteries
  - e) median suprarenal arteries
30. What anatomical structures cross the inferior vena cava from posterior?
- a) **right renal artery**
  - b) left renal artery
  - c) **right lumbar arteries**
  - d) left testicular (ovarian) artery
  - e) superior phrenic artery
31. Select the visceral branches of the inferior vena cava:
- a) lumbar veins
  - b) **hepatic veins**
  - c) superior and inferior mesenteric veins
  - d) **right testicular (ovarian) vein**
  - e) **renal and suprarenal veins**
32. Select the parietal branches of inferior vena cava:
- a) **inferior phrenic veins**
  - b) testicular (ovarian) veins
  - c) renal veins
  - d) **median sacral vein**
  - e) **lumbar veins**
33. How many constrictions the ureter has?
- a) one
  - b) two
  - c) **three**
  - d) four
  - e) five
34. How many parts of the ureter are considered equal?
- a) None
  - b) **Two**
  - c) Three
  - d) Four
  - e) Five
35. Select the anatomic structures situated anteriorly to aorta:
- a) **pancreas**
  - b) **ascending part of duodenum**
  - c) **root of the mesentery**
  - d) **left renal vein**
  - e) left testicular (ovarian) vein
36. Proximally to iliac vessels, the ureter is situated posteriorly to:
- a) **terminal portion of the ileum (from the right side)**
  - b) cecum (from the right side)

- c) **root of the sigmoid mesentery (from the left side)**
  - d) descending colon (from the left side)
  - e) rectosigmoid portion of the colon (from the left side)
37. The 12<sup>th</sup> rib intersect the kidneys in the following way:
- a) **left kidney is crossed at the middle**
  - b) left kidney: between superior 1/3 and inferior 2/3
  - c) **right kidney: superior 1/3 and inferior 2/3**
  - d) right kidney is crossed at the middle
  - e) 12th rib do not intersect kidneys
38. What are the anatomical structures and factors that maintain kidneys in their position:
- a) **hepatoduodeno- and lienorenal ligaments**
  - b) **adipose and external capsule**
  - c) **renal pedicle**
  - d) **intraabdominal pressure**
  - e) visceral peritoneum
39. Paracolicitis (inflammation of paracolon space) may develop as a result of pathological processes in:
- a) **pancreas and duodenum**
  - b) **caecum and appendix**
  - c) **ascending and descending colon**
  - d) **transverse colon**
  - e) small intestine
40. Purulent collections in the kidneys and ureters can lead to:
- a) **paranebritis**
  - b) **paraurethritis**
  - c) paracolicitis
  - d) retroperitonitis
  - e) peritonitis
41. Retroperitonitis (retroperitoneal phlegmon) develops as a result of spreading of pus from :
- a) **parapleural space**
  - b) transverse colon
  - c) **extraperitoneal connective tissue space from pelvis**
  - d) duodenum
  - e) the connective tissue space around the kidney
- ! Must be reviewed
42. What numbers in the picture corresponds to retrorenal and prerenal fascias:



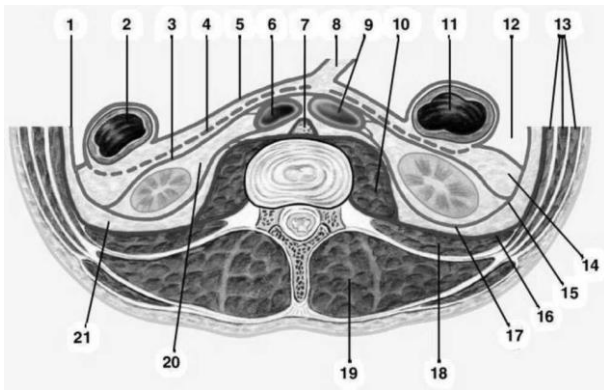
- a) 4, 17
- b) **3, 17**
- c) 3, 4
- d) 5 17
- e) 4, 16

43. What numbers in the picture corresponds to the layers of retroperitoneal fatty tissue spaces:



- a) 8, 14, 21
- b) 12, 14, 21
- c) **14, 20, 21**
- d) 6, 7, 9
- e) 11, 14, 20

44. Name correct statements:



- a) descending colon - 2
- b) paranefron - 20
- c) prerenal fascia - 3
- d) **ascending colon – 11**
- e) endoabdominal fascia – 1

## LUMBAR SURGERIES, RETROPERITONEAL AND SPINAL

1. Select the surgical approaches to the retroperitoneal organs:

- a) **laparotomy**
  - b) **Feodorov access**
  - c) **Pean access**
  - d) **Bergmann-Israel access**
  - e) Pfannenstiel access
- 

2. What kind of sutures are applied in case of kidney injury?

- a) **simple interrupted sutures**
  - b) simple continuous suture
  - c) the continuous U-shaped suture
  - d) **interrupted U-shaped sutures**
  - e) purse string suture
- 

3. Select the definition of laminectomy

- a) anterior opening of spinal canal
- b) **posterior opening of spinal canal**
- c) lateral opening of spinal canal
- d) opening of the cranial cavity
- e) opening of the retroperitoneal space

4. Select the surgical operation that consists of fixing of the vertebral bodies:

- a) **spondylodesis**
- b) vertebral resection
- c) laminectomy
- d) vertebrectomy
- e) none of them

5. What position should the patient take to perform a lumbar puncture?

- a) supine position
- b) **sitting, with hunched back**
- c) **lying on one side, with hunched back**
- d) lying on abdomen
- e) vertical with his head bent

6. Select the surgical operations for fixation of spinal column?

- a) **corporodesis**
  - b) laminectomy
  - c) **spondylodesis**
  - d) **spondylolysis**
  - e) vertebral resection
- ! Must be reviewed
- 

7. Select the correct definition for kidney resection:

- a) total removal of the kidney;
- b) sectioning of the kidney;
- c) **removing a portion of the kidney;**
- d) suturing the kidney;
- e) transplantation of the kidney.

8. Select the correct definition for nephrectomy:

- a) partial removal of the kidney;
- b) suturing the kidney;
- c) **total removal of the kidney;**
- d) kidney transplantation;
- e) sectioning the kidney.

9. Select the surgical operation that consists of opening the renal pelvis:

- a) kidney resection

- b) **pielotomy**
  - c) nephrotomy
  - d) nephrectomy
  - e) nefropexy
10. Surgical operation that consists of opening of renal pelvis and removal of stones in case of nephrolithiasis is called:
- a) kidney resection
  - b) **pielotomy**
  - c) nephrotomy
  - d) **litextraction**
  - e) nephropexy
11. What is pielostomy ?
- a) **applying a fistula on renal pelvis**
  - b) applying a fistula on ureter
  - c) applying a fistula on urinary bladder
  - d) applying a fistula between the pelvis and ureter
  - e) applying a fistula between the urethra and bladder
12. What is nephrostomy ?
- a) **applying a fistula on renal pelvis through renal parenchyma**
  - b) applying a fistula between renal pelvis and lumbar wall
  - c) applying a fistula between the renal pelvis and ureter
  - d) applying a fistula between the urethra and bladder
  - e) applying a fistula between renal pelvis and the abdominal wall
13. What kind of sutures are applied to the ureter in case of injury?
- a) suture in "Z"
  - b) penetrating suture
  - c) **non-penetrating (extramucosal) suture**
  - d) continuous sutures
  - e) **U-shaped interrupted sutures**
14. What type of graft is more beneficial in kidney transplantation?
- a) **izogenic** allotransplant
  - b) autotransplant
  - c) xenotransplant
  - d) explant
  - e) non-izogenic allotransplant
15. From paranefral space, the pus or hematoma can directly spread to:
- a) **the opposite paranefral space;**
  - b) prevezical adipose space;
  - c) the thoracic cavity;
  - d) the paracolon
  - e) **retroperitoneal fatty tissue space.**
16. Select the possible spaces where the pus or hematoma can spread from paracolic fatty tissue space:
- a) paranefral fatty tissue space
  - b) proper retroperitoneal fatty tissue space
  - c) in the fatty tissue space at the root of mesenterium
  - d) **posterior to the descending and ascending colon**
  - e) **the mesocolon**
17. Select the levels where lumbar puncture can be performed in the adults:
- a) between the spinous processes of the vertebrae L1-2
  - b) **between the spinous processes of the vertebrae L3-4**
  - c) **between the spinous processes of the vertebrae L4-5**
  - d) between the spinous processes of the vertebrae T11-12
  - e) it is not performed in the lumbar region

18. Select the level where lumbar puncture can be performed in children:

- a) between the spinous processes L1-2
- b) between the spinous processes L2-3
- c) between the spinous processes L3-4
- d) between the spinous processes of L4-5**
- e) is not made in children

19. Select the statements that defines spondylolisthesis.

- a) absence of a vertebra in the spine column
- b) anterior displacement of the vertebral body**
- c) posterior displacement of the vertebral body**
- d) crack in the vertebra arch
- e) none is correct

20. Select the statements that define the congenital defect of the spinal column – "spina bifida":

- a) strengthening of components of the spinal canal
- b) crack within the vertebral body**
- c) crack in the vertebral arch**
- d) crack in the vertebral arch and the vertebral body**
- e) lack of the apophyses of vertebral body

21. What is a herniated spinal disc?

- a) prolapsing of the posterior ligament of the spine;
- b) prolapsing of nucleus pulposus toward the spinal canal;**
- c) prolapsing of the anterior ligament of the spine;
- d) it is a congenital hernia;
- e) it is an acquired hernia.**

22. Select the definition of nephrotomy:

- a) removing of a portion of the kidney;
- b) performing an incision on the kidney;**
- c) total removal of the kidney;
- d) kidney transplantation;
- e) suturing the kidney.

23. Select the extraperitoneal surgical approaches to the ureteres:

- a) Feodorov's incision;
- b) Ovnatanian's incision;
- c) Pirogov's incision;**
- d) Bergman-Israel's incision;**
- e) midline laparotomy;

24. Select the methods of transplanting of ureters:

- a) in the peritoneal cavity;
- b) on the surface of the skin;**
- c) in the urinary bladder;**
- d) in the large intestine;**
- e) no correct answer.

## PELVIS

- Line between great and small pelvis pass through:
  - Arcuate line iliac bones**
  - Superior border of pubic symphysis**
  - Sacrotuberous and sacrospinous ligaments and sacrum bone
  - Inferior border of pubic symphysis, ischial bones and coccyx
  - Promontory sacrum**
- Internal walls of the pelvis are covered by the next muscles:
  - Obturator external
  - Piriformis**
  - Gemellus superior and inferior
  - Gluteus minor and iliopsoas
  - Obturator internal m.**
- Exit from the pelvic cavity is closed by:
  - Gluteus major and medius
  - transversus perinei profundus m. (urogenital diaphragm)**
  - ischiocavernosus and bulbocavernosus mm.
  - m. levator ani (anal diaphragm)**
  - superficial perineal transvers m.
- Greater sciatic foramen is delimited by:
  - Sacrotuberous ligament
  - Sacrospinal ligament**
  - Sacrococcygian ligament
  - Greater sciatic notch**
  - Sacrum bone**
- Lesser sciatic foramen is delimited by:
  - Sacrotuberous ligament
  - Sacrospinal ligament**
  - Sacrococcygian ligament
  - Lesser sciatic notch**
  - Sacrum bone**
- Piriform muscle origin is:
  - Posterior superior iliac spine
  - Iliac bone wing
  - Coccyx bone
  - Anterior surface of sacrum**
  - Anterior superior iliac spine
- Levator ani muscle originates from:
  - Terminal line of pelvis
  - iliac bone wings
  - Tendinous arch of pelvic fascia**
  - Ischiatic bones
  - Sacrospinal ligament
- Gluteal superior nerve is coming out from pelvis through:
  - Lesser sciatic foramen
  - Obturator canal
  - Pudendal canal
  - Suprapiriform foramen**
  - Infrapiriform foramen
- Visceral pelvic muscles are:
  - Sphincter ani externus**
  - Obturator internal muscle
  - Coccygian m.**
  - Levator ani muscle**

- e) Piriform muscle
10. Pelvic fascia is a continuation of:
- Fascia lata
  - Obturator fascia
  - aponeurosis of transverse m
  - Endoabdominal fascia**
  - Retroperitoneal fascia
11. In the anterior compartment of subperitoneal level of pelvis in male are the following:
- Urinary bladder and pelvic portion of the ureters**
  - Prostate**
  - Seminal vesicles**
  - Rectum
  - Ampulla of deferens canals**
12. In the anterior compartment of the subperitoneal level of pelvis in female are the following:
- uterine cervix**
  - greater vestibular gland of Bartholini
  - ampulla of rectum
  - extraperitoneal portion of the urinary bladder**
  - incipient portion of the vagina**
13. What is situated behind the peritoneo-perineal fascia of Denonvilliers in female?
- Vagina
  - Posterior fornix of vagina
  - Rectum**
  - Internal iliac a.
  - Lumbar plexus
14. Tendinous arch of pelvic fascia is between:
- Ischial tuberosities
  - Inferior margin of pubic symphysis**
  - Superior margin of pubic symphysis and ischial tuberosity
  - Inferior margin of pubic symphysis and sacrum
  - Ischial tuberosity**
15. Urogenital organs in pelvis are separated from rectum by:
- Capsule of prostate of Retzius-Pirogov
  - Capsule of rectum of Amussat
  - Obturator fascia
  - Endopelvin fascia
  - Peritoneo-perineal fascia of Denonvilliers**
16. Purulence of the lateral celluloadipose space of pelvis can spread to the gluteal region through:
- Suprapiriform foremen**
  - Infrapiriform foramen**
  - Pudental (Alcock's) canal
  - Obturator canal
  - Along the round ligament of uterus
17. Purulence of the lateral celluloadipose space of pelvis can spread to the medial fascial sheath of the thigh:
- Along the femoral branch of genitofemoral nerve
  - Along the lateral femoral cutaneous nerve
  - Through the Alcock's canal
  - Through the obturator canal**
  - Along the round ligament of uterus
18. Parametral cellular space is localized between:
- Laminas of the broad ligament of uterus**
  - Around the cervix uteri**
  - On the transverse perineal muscles
  - In the rectouterine pouch of Douglas



- e) No one is correct
19. Purulence of parametral celluloadipose space can spread immediately to:
- anterior region of the thigh along the femoral branch of genitofemoral n.
  - Retrovezical space**
  - Retroperitoneal fatty tissue space**
  - Retrorectal fatty tissue space
  - Lateral pelvic fatty tissue space**
20. In the parametrium cellular space is localized:
- Uterine and ureteral arteries**
  - Sacral plexus
  - Venous and nervous uterine plexuses**
  - Cardinal ligament of the uterus Mackenrodt**
  - Ovaries
21. How many floors we distinguish in the pelvis
- One
  - Two
  - Three**
  - Four
  - It is not separated into stories
22. Peritoneal floor of pelvis is localized:
- Between wings of the iliac bones
  - Between pelvic diaphragm and peritoneum
  - Between peritoneum and fascia of Denonvilliers
  - Between urogenital diaphragm and peritoneum
  - Is portion of the pelvic organs covered by the peritoneum**
23. Indicate the folds and excavations of the peritoneal pelvic floor in female:
- Transverse vesical fold**
  - Vesicouterine fold**
  - Rectovesical folds
  - Sacrouterine folds, rectouterine excavation**
  - Vesicouterine excavation**
24. Indicate the folds and excavations of the peritoneal pelvic storey in male:
- Transverse vesical fold**
  - Vezicorectale fold**
  - Sacrorectal fold
  - Lateral umbilical folds
  - Vesicorectal excavations**
25. Subperitoneal floor of the pelvis is delimited by:
- Iliac wings
  - Fascia that covers levator ani muscle**
  - Fascia of Denonvilliers
  - Bottom of the peritoneal bag**
  - Represent pelvic organs covered by peritoneum
26. Subcutaneous pelvic floor is localized between:
- iliac wings
  - skin and pelvic diaphragm**
  - skin and superficial fascia
  - the superficial and deep transverse perineal muscles
  - peritoneum and muscle levator ani
27. Ischiorectal fossa is delimited by:
- iliac bone wing
  - superficial transverse perineal muscle**
  - great gluteal muscle**
  - levator ani muscle**

e) **tuber of ischial bone together with the obturator internal muscle**

28. The position of the internal iliac vein in relation to the internal iliac artery is:

- a) **Medial**
- b) Lateral
- c) **Posterior**
- d) Superior
- e) Anterior

29. Pelvic portocaval anastomosis, it is a connection between:

- a) **superior rectal vv. and vv. rectale medii**
- b) inferior and superior rectal vv
- c) middle and inferior rectal vv.
- d) in the pelvis there are no portocaval anastomoses
- e) venous plexus around the urinary bladder

30. Where is localized sacral plexus?

- a) On the obturator internal muscle
- b) On the obturator external muscle
- c) On the gemelli muscles
- d) **On the piriform muscle**
- e) On the anterior surface of the sacrum

31. Where is localized the sympathetic trunk in pelvis?

- a) On the obturator internal muscle
- b) **Medial to the anterior sacral foramens**
- c) On the gemelli muscles
- d) On the piriform muscle
- e) Lateral to the anterior sacral foramens

32. Lymph drains from the external genital organs to lymph nodes that are situated:

- a) **Along the common iliac artery**
- b) Internal iliac artery
- c) On the anterior surface of sacrum
- d) **Along the external iliac artery**
- e) Along the obturator artery

33. Pudendal (Alcock's) canal is delimited by:

- a) Ischial tuberosity and obturator membrane
- b) **Fascial duplication of the internal obturator muscle**
- c) Obturator membrane and obturator internal muscle
- d) Ischial tuberosity and obturator internal muscle
- e) Sacrospinous and obturator internal muscle

34. Pudendal (Alcock's) canal contains:

- a) Obturator artery, vein, and nerve
- b) **Pudendal nerve**
- c) **Pudendal internal artery and vein**
- d) Gluteus inferior artery, vein and nerve
- e) Pudendal external artery and vein

35. What is situated immediately before the rectum in female?

- a) **peritoneo-perineal aponeurosis of Denonvillier**
- b) uterine tubes, cervix uteri
- c) parametral space
- d) Posterior fornix of vagina
- e) Uterus, posterior wall of vagina

36. How many arteries provide the vascularization of rectum?

- a) One
- b) Two
- c) Three
- d) Four

- e) **Five**
37. Rectum is divided, concerning anatomic-topographical structure, into how many parts:
- One
  - Two
  - Three**
  - Four
  - Five
38. The largest portion of rectum is:
- Ampullar part**
  - Rectosigmoid part
  - Anal part
  - Sigmoid part
  - Transverse part
39. What is situated in front of the rectum in male?
- peritoneo-perineal aponeurosis of Denonvillier**
  - Ureter and vesical triangle
  - Urethra, prostatic capsule
  - Ductus deferens
  - Prostate, seminal vesicles
40. How many curves forms rectum in sagittal plane?
- One ( sacral)
  - Two (sacral superior and perineal inferior)**
  - One ( perineal)
  - Three (sacral superior, coccygeal middle and perineal inferior )
  - Rectum does not form any curves
41. Indicate the sphincters of the rectum:
- External**
  - Internal**
  - Tertiary**
  - Longitudinal
  - Intermediate
42. Which of the following statements are correct?
- peritoneum covers the bottom and the body of the uterus, the posterior surface of the cervix and a portion of the posterior wall of the vagina**
  - Longitudinal axis of the uterus is bended anteriorly**
  - Position of the body of the uterus to its neck is that of antelexion**
  - on the surface of vesical peritoneum get up to anterior fornix of the vagina
  - Uterus has no mesentery**
43. In what anatomical structure is situated the mesentery of the uterine tube and ovary?
- Round ligament of uterus
  - Cardinal ligaments
  - Sacropubic ligaments
  - Broad ligament of uterus**
  - Parietal pelvic celluloadipose space
44. The uterine tube is located:
- In the round ligament of uterus
  - Along the cardinal ligament of uterus
  - On the inferior border of the sacropubic ligament
  - On the superior edge of the broad ligament of uterus**
  - In the parietal pelvic celluloadipose space
45. What ligaments stabilize the position of uterus?
- Round ligaments of uterus
  - infundibulopelvic ligament
  - Sacrouterine ligaments**

- d) Broad ligament of the uterus
  - e) **Cardinal ligaments of uterus Mackenrodt**
46. Uterine tube is divided into the following parts:
- a) **Uterine part**
  - b) **Isthmus of uterine tube**
  - c) Intermediar part
  - d) **Ampulla and infundibulum of uterine tube**
  - e) Ovarian part
47. How many ligaments the ovary has?
- a) One
  - b) **Two**
  - c) Three
  - d) Four
  - e) It has no ligaments
48. Indicate the main ligaments of the ovary:
- a) **Suspensory ligament**
  - b) **Proper ligament**
  - c) Round ligament
  - d) Cardinal ligament
  - e) Broad ligament
49. How many proper ligaments the ovary has?
- a) **One**
  - b) Two
  - c) Three
  - d) Four
  - e) It has no proper ligaments
50. Ovary in the pelvis is located:
- a) On the round ligament of uterus
  - b) Between the leaves of broad ligament of uterus
  - c) On the ampulla of the uterine tube
  - d) **On the posterior lamina of the broad ligament of uterus**
  - e) On the anterior leaf of the broad ligament of uterus
51. What structures does the suspensory ligament of ovary contain?
- a) Cardinal ligament
  - b) **Ovarian vein**
  - c) **Ovarian artery**
  - d) Tubar artery and vein
  - e) Uterine artery and vein
52. Pathway of the cardinal ligament of the uterus is:
- a) **Along the uterine vessels**
  - b) Along the mesosalpinx
  - c) Along the mesovarium
  - d) Along the ovarian artery
  - e) Along the posterior wall of the vagina
53. What parts does the fornix of the vagina include?
- a) **Anterior**
  - b) **Posterior**
  - c) **Left**
  - d) **Right**
  - e) It does not have any parts
54. The projection of the tendinous center of the perineum on skin?
- a) From the pubic symphysis to the sacrum
  - b) **the middle point of the line that connects ischial tuberosities**

- c) Between the ureters and the vagina
  - d) posterior from the rectum
  - e) Middle point of the innominate line
55. Urogenital diaphragm is consisted by:
- a) Levator ani muscle
  - b) Superficial transverse muscle of the perineum and superficial fascia
  - c) Superficial and deep transverse muscles of the perineum
  - d) Deep transverse perineal muscle and the fascias that cover it**
  - e) Bulbocavernos muscle
56. What structures pass through the urogenital diaphragm in female?
- a) Ducts of greater vestibular (Bartholin's) glands and rectum
  - b) Genital branch of the genitofemoral nerve
  - c) Urethra**
  - d) Vagina**
  - e) Round ligament of the uterus and anal canal
57. What structures pass through the urogenital diaphragm in male?
- a) Seminal ducts
  - b) Genital branch of the genitofemoral nerve
  - c) Urethra**
  - d) Deferent duct
  - e) Spermatic cord
58. Innervation of skin in the region of perineum is realized in women by:
- a) Genitofemoral nerve**
  - b) Ilioinguinal nerve
  - c) Iliohypogastric nerve
  - d) Pudental nerve**
  - e) Cutaneous femoris posterior nerve
59. Between what anatomical structure is placed dorsal artery of the penis?
- a) Spongios and cavernous bodies
  - b) Skin and superficial fascia
  - c) lamina albuginea**
  - d) between the cavernous bodies
  - e) proper fascia**
60. How many segments can be distinguished in a man's urethra?
- a) One
  - b) Two
  - c) Three**
  - d) Four
  - e) Five
61. What segments can be distinguished in a man's urethra?
- a) Membranous part**
  - b) Spongy part**
  - c) Terminal part
  - d) Vesical part
  - e) Prostatic part**
62. How many segments can be distinguished in a woman's urethra?
- a) One**
  - b) Two
  - c) Three
  - d) Four
  - e) Five
63. Indicate with which structures does the inferior wall of the urinary bladder come in contact in men?
- a) Prostate**
  - b) seminal vesicles and the ampullas of deferent ducts**

- c) Posterior wall of the rectum
  - d) urethra
  - e) **ureters**
64. Indicate with which structures does the lateral wall of the urinary bladder come in contact in men?
- a) Lateral wall of pelvis
  - b) **ductus deferens**
  - c) Posterior wall of the rectum
  - d) Urethra, prostate
  - e) Ureters, seminal vesicles
65. Involuntary sphincter of the urinary bladder is located in the:
- a) Terminal, intramural part of ureters
  - b) Membranous part of urethra
  - c) **Initial part of urethra**
  - d) Spongy part of urethra
  - e) All of the sphincters of the urinary bladder are voluntary
66. The voluntary sphincter of the urinary bladder is located in the:
- a) Terminal, intramural part of ureters
  - b) **Membranous part of urethra**
  - c) Initial part of urethra
  - d) Spongy part of urethra
  - e) All of the sphincters of the urinary bladder are voluntary
67. Which one of the following statements are correct?
- a) **length of the pelvic part of the ureter is of 15-16cm**
  - b) pelvic part of the ureter is divided into the rectal and visceral portions
  - c) **at the level of the terminal line the left ureter crosses the left common iliac artery**
  - d) **at the level of the terminal line the right ureter crosses the right external iliac artery**
  - e) **in front of the initial part of the ureter on the right is located the ileum, on the left the mesentery of the sigmoid colon**
68. Where does the ureter form its first cross with the uterine artery?
- a) **At the level of initial part of internal iliac artery, being located anteriorly to the artery**
  - b) On the lateral pelvic wall, at the level of initial part of internal iliac artery, being located deeper to the artery
  - c) At the level of cervix uteri, being located deeper to the uterine artery
  - d) At the level of cervix uteri, being located superficially to the uterine artery
  - e) At the entrance of pelvis, being located lateral to the uterine artery
69. Where does the ureter form its second cross with the uterine artery?
- a) On the lateral pelvic wall, at the level of initial part of internal iliac artery, being located superficial to the artery
  - b) On the lateral pelvic wall, at the level of initial part of internal iliac artery, being located deeper to the artery
  - c) **At the level of cervix uteri, being located deeper to the uterine artery**
  - d) At the level of cervix uteri, being located superficially to the uterine artery
  - e) At the entrance of pelvis, being located lateral to the uterine artery
70. Which of the statements involves the description of the prostate?
- a) **It is a musculoglandular organ with the shape of a chestnut**
  - b) **In its structure can be distinguished the apex, base, anterior and posterior parts, two lateral and one middle lobes**
  - c) **It is surrounded by a dense fascial sheath (capsule of Retzius-Pirogov)**
  - d) Gland is separated from the urinary bladder by celluloadipose tissue
  - e) **Prostate venous plexus is located outside of the prostate capsule**
71. Which of the statements describes correctly the location of the seminal vesicles?
- a) It is a glandular organ with the shape of a chestnut
  - b) **They are situated in the pelvis upper to the prostate**
  - c) **They are close to the posterior wall of the urinary bladder**

- d) **They are located between two structures: ampulla of ductus deferens is medially and ureter is laterally**
- e) **Adheres to peritoneo-perineal aponeurosis Denonvillier**
72. Which muscles are inserted in the tendinous center of the perineum in women?
- a) **Bulbospongiosus**
- b) **Sphincter ani externus, levator ani**
- c) Sphincter ani internus
- d) **Transversus perinei profundus and superficialis**
- e) Ischiocavernosus
73. Round ligaments of uterus end in:
- a) Labium minus pudendi
- b) Pubic symphysis
- c) Anterior wall of the vagina
- d) **Labium majus**
- e) Aponeurosis of external oblique abdominal muscle
74. What are the regions of the perineum?
- a) **anal region**
- b) perianal region
- c) the genital region
- d) urinary region
- e) **urogenital region**
75. Which of the statement are correct?
- a) The perineum represents the superior wall of the pelvic cavity
- b) **The perineum represents the inferior wall of the pelvic cavity**
- c) The perineum represents the anterior wall of the pelvic cavity
- d) The perineum represents the posterior wall of the pelvic cavity
- e) None of the answers
76. Landmarks for determining the limits of perineum are:
- a) **anterior –inferior margin of the pubic symphysis**
- b) **posterior - coccyx**
- c) posterior-lateral - ischiosacral ligaments
- d) **lateral - ischial tuberosities**
- e) none of the answers
77. Through the subcutaneous fatty tissue of the anal region pass
- a) **Perineal nerves**
- b) **perineal branches of cutaneus femoris posterior nerves**
- c) **cutaneous branches of the inferior gluteal artery and vein**
- d) branches of inferior rectal artery and vein
- e) superior clunium nerves
78. External fascia of spermatic cord is an extension of:
- a) **superficial fascia of the abdominal wall**
- b) aponeurosis of the obliquus externus abdominis muscle
- c) transverse fascia
- d) peritoneum
- e) deep fascia of the abdominal wall
79. Internal fascia of spermatic cord is an extension of:
- a) superficial fascia of the abdominal wall
- b) aponeurosis of the obliquus externus abdominis muscle
- c) **transverse fascia**
- d) peritoneum
- e) proper fascia of the abdominal wall
80. Fascia cremasterica is an extension of: is an extension of:
- a) superficial fascia of the abdominal wall
- b) **proper fascia of the abdominal wall**

- c) transverse fascia
- d) peritoneum
- e) is no correct answer

81. Vaginal tunic of the testicle is an extension of:

- a) superficial abdominal fascia
- b) aponeurosis of the obliquus externus abdominis muscle
- c) **transverse fascia**
- d) peritoneum
- e) pelvic fascia

82. Embryogenesis of the testicle occurs:

- a) in the peritoneal cavity
- b) in the pelvic cavity
- c) **in retroperitoneal space**
- d) in scrotum
- e) is no correct answer

83. The elements of the spermatic cord are:

- a) **deferent duct, a. and v. of the deferent duct**
- b) **testicular artery and vein**
- c) **cremasteric artery and vein**
- d) **peritoneal vaginal process**
- e) external pudendal artery

84. Testicular artery is a branch of the artery:

- a) the internal pudendal
- b) perineal
- c) external pudendal
- d) **abdominal aorta**
- e) inferior mesenteric

85. That form testicular veins?

- a) prostatic plexus
- b) **pampiniform plexus**
- c) perineal plexus
- d) sacral plexus
- e) scrotal plexus

86. Which answers are correct:

- a) both testicular vein draining into inferior vena cava
- b) **right testicular vein flows in acute angle in the inferior vena cava**
- c) **left testicular vein flows in right angles to the left renal vein**
- d) right testicular vein flows in right angles in right renal vein
- e) both veins draining into renal veins

87. Which answers are correct:

- a) **right testicular vein flows in acute angle in the inferior vena cava**
- b) left testicular vein flows in acute angles in the inferior vena cava
- c) left testicular vein flows in right angles in the inferior vena cava
- d) both veins draining into renal veins
- e) both testicular vein draining into inferior vena cava

88. The length of the prostatic urethra is:

- a) 2 cm
- b) **4cm**
- c) 8cm
- d) 12cm
- e) 15cm

89. The urethra length in the membranous portion is:

- a) **2 cm**
- b) 4cm



- c) 8cm
- d) 12cm
- e) 15cm

90. The length of the spongy portion of the urethra is

- a) 2 cm
- b) 4cm
- c) 8cm
- d) 12cm
- e) **15cm**

91. Great vestibular glands (Bartholin) are located?

- a) on the medial face of the labium minus
- b) **on the base of the labium majus**
- c) in the vestibulum of the vagina
- d) **in the thickness of deep transverse muscle of perineum**
- e) **partial are covered by bulbocavernosus m.**

92. Where do the orifices of the great vestibular glands (Bartholin) open?

- a) **between the labia minor and hymen**
- b) at the base of major labium
- c) between small and major labia
- d) on the clitoris
- e) in urethral meatus

93. Which of the following statements are correct about the pelvic fascia:

- a) **parietal lamella covers parietal muscles of the pelvis**
- b) **continue on the upper surface of the levator ani muscle**
- c) **obturator fascia represents a more compact portion of the parietal fascia and forms tendinous arches of the pelvic fascia**
- d) visceral lamella covers intraperitoneal portions of the pelvic organs
- e) **visceral lamella covers extraperitoneal portions of the pelvic organs in case of males**

94. Which of these capsules are formed by fascia pelvis:

- a) **Amiussv capsule**
- b) **Pirogov-Retsius capsule**
- c) Littre capsule
- d) Anderson capsule
- e) Paron capsule

95. For prevezicală fascia is characteristic:

- a) **has a triangular form**
- b) **is stretched between the lateral umbilical folds**
- c) **subperitoneal ruptures of the urinary bladder are accompanied by prevesical fascial ruptures, which leads to urinary bladder infiltration not only of the preperitoneal space but also of the prevesical space**
- d) **separates the two areas of adipose tissue located between the pubic bone and the bladder**
- e) prevezicală fascia is stretched between the medial umbilical folds

96. Which of the following statements are correct concerning the limits of retrovesical space:

- a) **is bounded above the visceral fascia that covers the vesical bladder**
- b) **is bounded laterally by longitudinal septa of visceral pelvic fascia**
- c) **posterior is bounded by peritoneo-perineal aponeurosis**
- d) **inferior is bounded by superior fascia of the urogenital diaphragm**
- e) anterior is bounded by the vesical bladder

97. What structures are contained in retrovezical cellular tissue space in the case of men?

- a) **prostate**
- b) **seminal vesicles**
- c) **ductus deferens**
- d) **ureter**
- e) urethra

98. What structures are contained in retrovesical cellular tissue space in the case of women?
- vagina**
  - cervix
  - uterus
  - ureter**
  - urethra
99. Possible ways of pus diffusion in the retrovesical space are:
- on the trajectory of ductus deferens in the inguinal canal**
  - on the trajectory of vesical arteries in the parietal area of the pelvis
  - on the trajectory of the ureter in the retroperitoneal space**
  - on the trajectory of vesical veins in the parietal space of the pelvis
  - the pus is not diffused
100. Which of the following statements about retrorectal space are wrong:
- is located between the rectum capsule and sacrum
  - contains the sacral portion of the sympathetic trunk, sacral and median arteries
  - contains superior rectal arteries, on the trajectory pus may spread into the retroperitoneal space and the parietal area of the pelvis
  - is located between the capsule and the wall of the rectum**
  - contains the aorta and inferior vena cava**
101. List the components of the epididymis:
- head**
  - body**
  - neck
  - tail**
  - bulb
102. List the parts of the penis:
- two cavernous bodies**
  - one spongios body**
  - one cavernous body
  - two spongy bodies
  - two membranous bodies
103. We distinguish the following parts of Fallopian tube:
- uterine part**
  - isthmus of fallopian tube**
  - ampulla of fallopian tube**
  - vesical part
  - pavilion of fallopian tube**
104. The limit between external female genitals organs and the internal one are:
- small labia
  - big labia
  - incipient portion of the vagina
  - hymen**
  - cervix
105. The coccygeal muscle insertion points are:
- ischial spine**
  - the lateral border of the coccyx**
  - the top of the sacrum
  - pubis bone
  - the iliac crest
106. Perineum is composed of the following sections:
- urogenital diaphragm**
  - tendinous part of diaphragm
  - superficial diaphragm
  - pelvic diaphragm**
  - coccygeal diaphragm

107. Perineal region boundaries are:

- a) **anterior to the lower edge of pubic symphysis**
- b) **posterior to coccyx apex**
- c) anterior of line drawn between superior anterior iliac spines
- d) lateral sacrotuberale ligaments
- e) **lateral to the lower branches of the pubic and ischial bones**

108. The length of the female urethra is:

- 1. 5 - 6 cm
- 2. **3,5 - 4 cm**
- 3. 4,5 - 5,5 cm
- 4. 2 - 3 cm
- 5. 7 - 8 cm

109. Choose the correct statements about the labia minora.

- a) **contain a large number of elastic fibers**
- b) **are composed of connective tissue**
- c) **posterior edges forms frenulum of labia minora**
- d) have a length of 7-8 cm
- e) constitutes a skin fold

110. What vaginal fornix is punctured to extract pathologic fluid from the peritoneal cavity.

- a) anterior fornix
- b) **posterior fornix**
- c) left lateral fornix
- d) right lateral fornix
- e) in this case is not made fornix puncture

111. What are the layers of the scrotum:

- a) **skin, dartos tunic, superficial fascia**
- b) **cremasteric fascia, cremasteric muscle, common vaginal tunic**
- c) **proper vaginal tunic**
- d) mucousa and proper vaginal tunic
- e) common vaginal tunic, proper and testicular capsule

## PELVIC SURGERY

1. Bispinos diameter connects the two anterior superior iliac spines and has an average of:

- a) 18 cm
- b) 20 cm
- c) 24 cm**
- d) 28 cm
- e) 32 cm

2. Bicristar diameter, connecting tubers of the iliac crests and has an average of

- a) 18cm
- b) 20cm
- c) 24cm
- d) 28cm**
- e) 32cm

3. Bitrochanterian diameter has an average of:

- a) 28 cm
- b) 30 cm
- c) 34 cm
- d) 32 cm**
- e) 27 cm

4. Biischiadic diameter has an average of:

- a) 10cm
- b) 12cm**
- c) 14cm
- d) 18cm
- e) 22cm

5. Promontorio-suprapubian diameter (*anatomic conjugate of the pelvis*) has an average of:

- a) 9 cm
- b) 10 cm
- c) 11 cm**
- d) 12 cm
- e) 14 cm

6. Promontorio-retropubian diameter (*conjugata vera*) has an average of:

- a) 9,5 cm
- b) 10,5 cm**
- c) 11,5 cm
- d) 12,5 cm
- e) 13,5 cm

7. Promontorio-infrapubian diameter has an average of:

- a) 9 cm
- b) 10 cm
- c) 11 cm
- d) 12 cm**
- e) 13 cm

8. Michaelis's top rhombus is bounded by:

- a) spinous process of the L5 vertebra**
- b) coccyx apex
- c) postero-superior iliac spines;
- d) postero- inferior iliac spines;
- e) antero- superior iliac spines;

9. Craniocaudal diagonal of Michaelis rhombus measures approx:

- a) 9cm
- b) 11cm**
- c) 13cm
- d) 14cm

e) 15cm

10. Transversal diagonal of Michaelis rhombus measures approx:

- a) 9cm
- b) 10cm**
- c) 11cm
- d) 12cm
- e) 13cm

11. By vaginal touch following organs can be examined:

- a) uterus and cervix**
- b) urinary bladder
- c) fallopian tubes**
- d) ovaries**
- e) rectum

12. What anatomical structures can be examined by rectal tact in women?

- a) cervix**
- b) urinary bladder
- c) fallopian tubes
- d) vagina**
- e) ovaries

13. Which pathologies listed below does not relate to anorectal malformations?

- a) anal stenosis
- b) imperforate anal membrane
- c) anal atresia
- d) rectal aplasia
- e) Hirschsprung disease**

14. What anatomic formations are located in the wide ligament of the uterus?

- a) mezo of the uterine tube**
- b) cardinal ligaments**
- c) round ligament of the uterus**
- d) sacral plexus
- e) hemorrhoidal vein plexus

15. What are the indications for drainage of the prevezical space?

- a) urinary infiltration**
- b) phlegmon of the prevezical space**
- c) cystic stones
- d) prostatitis
- e) symphysitis

16. Indication to puncture the bladder is:

- a) cystic stones
- b) prostatitis
- c) foreign body in the urinary bladder
- d) cystitis
- e) Bladder catheterization failure**

17. Bladder puncture needle will be inserted on the midline:

- a) in midway between the belly button and the pubic symphysis
- b) the upper edge of the symphysis pubis
- c) perpendicular and 2 cm superior the pubic symphysis**
- d) the inferior part of the symphysis pubis
- e) 5 cm below the umbilicus in a full bladder

18. The surgical access to prostate can be performed:

- a) transvezical**
- b) retropubic**
- c) transperineal**
- d) trans-symphisian

**e) transurethral**

19. Which of abscesses listed below are located in the subperitoneal floor of the pelvis?

- a) subcutaneous
- b) recto-uterin
- c) submucosal
- d) ischiorectal
- e) parametral**

20. Indicate which of the cuts listed below are used for opening and draining anorectal abscesses?

- a) semilunar on the sides of the anus**
- b) semilunar anterior portion of the anus
- c) semilunar posterior anus**
- d) it is preferred radial incisions on the sides of the anus
- e) preferably located posterior to the anus because there are few vessels and nerves in this region.

21. Approach to the pelvic organs in case of ectopic pregnancy can be performed by:

- a) laparoscopic approach**
- b) lower median laparotomy**
- c) by transvaginal access
- d) by transrectal access
- e) Pfannenstiel laparotomy**

22. Rectouterine excavation (Douglas) puncture may be made by:

- a) anterior vaginal fornix
- b) lateral fornix of the vagina
- c) posterior vaginal fornix**
- d) by rectum
- e) transperineal through the tendinous center

23. What are the indications for anesthesia of the pudendal nerve?

- a) coccyx fracture
- b) anesthesia in operations on lower limb
- c) fractures of the pelvis
- d) arthrosis of the hip joint in order to diminish pain
- e) perineal surgery**

24. Anesthesia of the pudendal nerve requires following needle insertion:

- a) midway between the ischiadic tuberosity and anus
- b) directly medial to ischiadic tuberosity**
- c) directly lateral to anus
- d) previous to the anus
- e) posterior to the anus

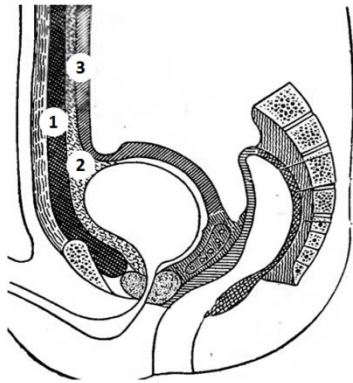
25. Surgical technique in phimosis requires preputial removal and is called:

- a) frenotomy
- b) circumcision**
- c) penile amputation
- d) Winkelmann operation in hydrocele testis
- e) testicular varicocele surgery Ivanisevic

26. In case of secluded hydrocele the following surgical technique is required:

- a) Bergmann-Winkelman;**
- b) Shkolnikov-Selivanov;
- c) Madelung;
- d) Mikulicz;
- e) Milligan-Morgan

27. Bladder fascia do not fuse at the upper pole, their fusion occurs at umbilicus level, in this way the two fascia limit three cell spaces anterior the bladder, Name them:



- a) **1 – anterior prevezical , limited by endoabdominal fascia and anterior prevezical fascia**
- b) **2 - medial prevezical between bladder laminas**
- c) **3 – posterior prevezical between rear foil and parietal peritoneum**
- d) 1 - anterior prevezical between the sheath of m. rectum and transverse fascia
- e) 2 - medial prevezical between anterior prevezicală fascia and parietal peritoneum

28. Note the access for drainage of the prevezical spaces :

- a) **lower median laparotomy**
- b) transrectal laparotomy
- c) transverse laparotomy (Pfannenstiel)
- d) Extraperitoneal access parallel to inguinal ligament (Pirogov)
- c) **transperineal access**

29. Name the intervention stages in acute paraproctitis:

- a) **opening and open drainage of the abscess**
- b) opening and closed drainage of the abscess
- c) abscess punction and draining pus
- d) **fistula closure**
- e) puncturing the abscess and introducing local antiseptics

30. Note the types of perirectal abscesses:

- a) interfascial
- b) **subcutaneus, submucos**
- c) **ischio-rectal**
- d) **pelvio-rectal**
- e) **retrorectal**