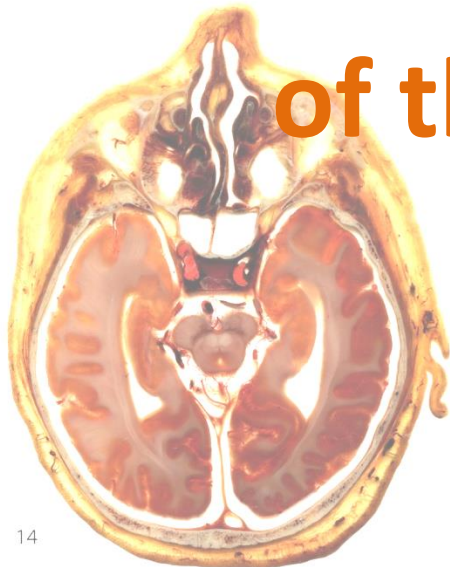
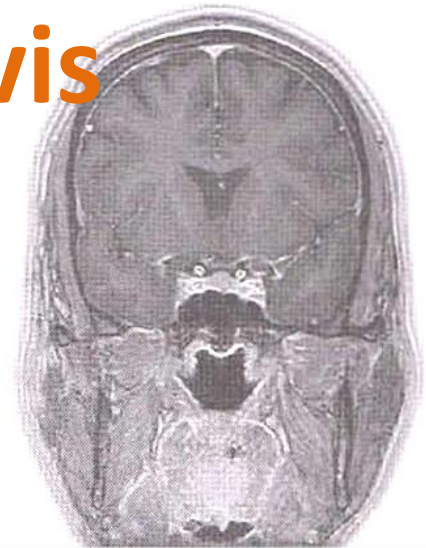
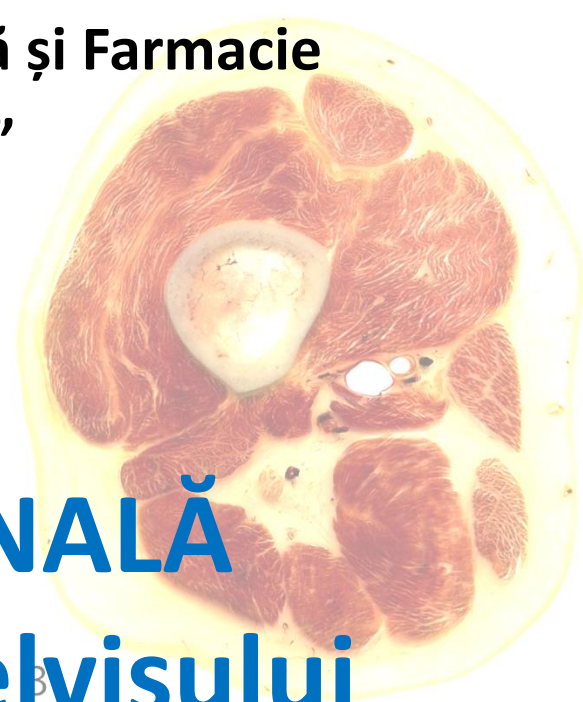

ANATOMIE SECȚIONALĂ
a Abdomenului și a Pelvisului

Sectional Anatomy
of the Thorax and Pelvis



Lecturer Lilian Globa



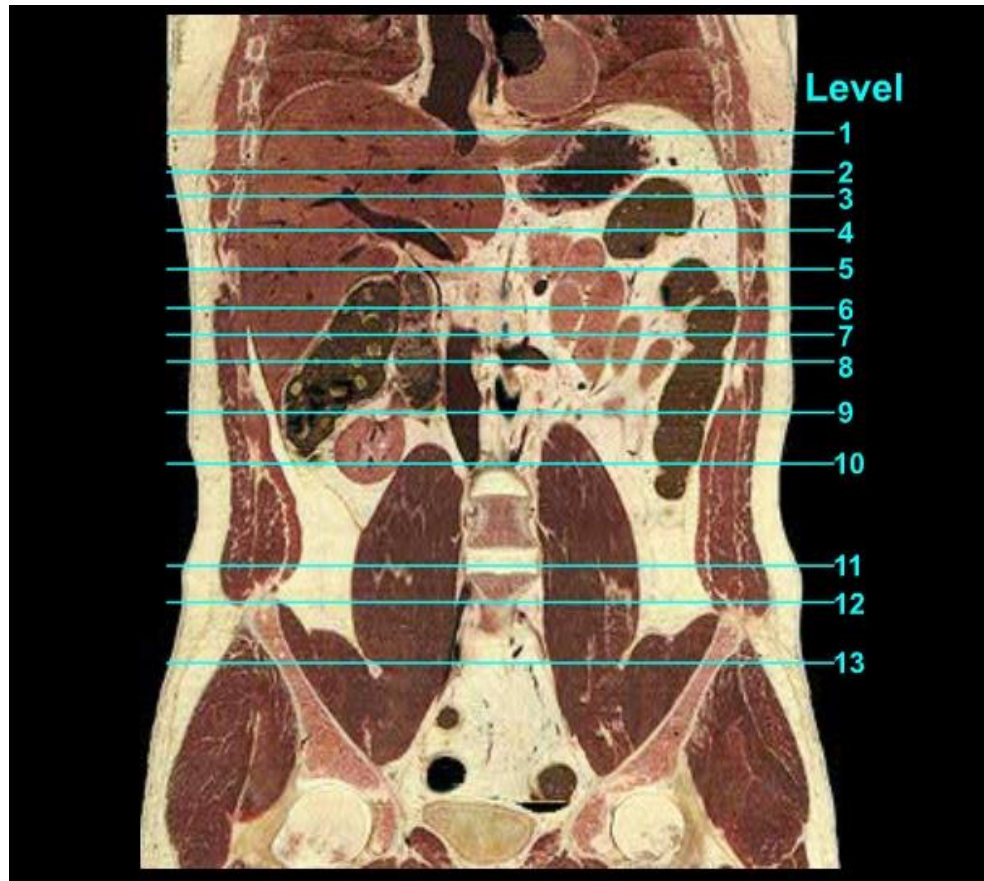
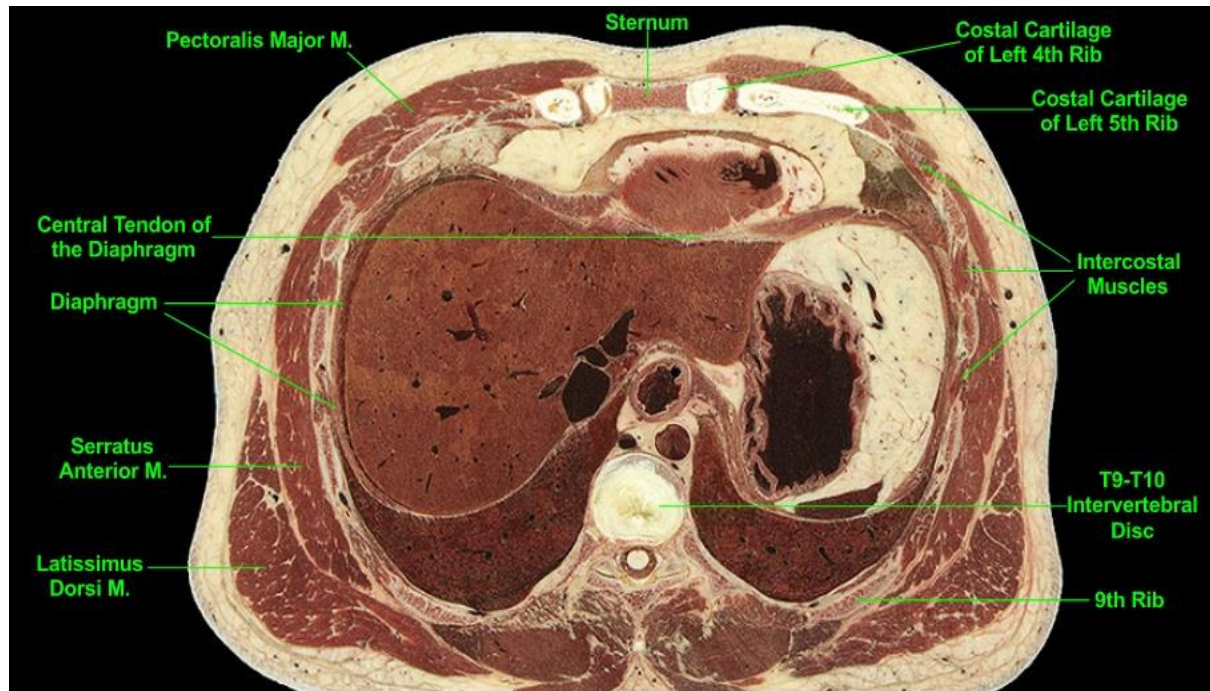


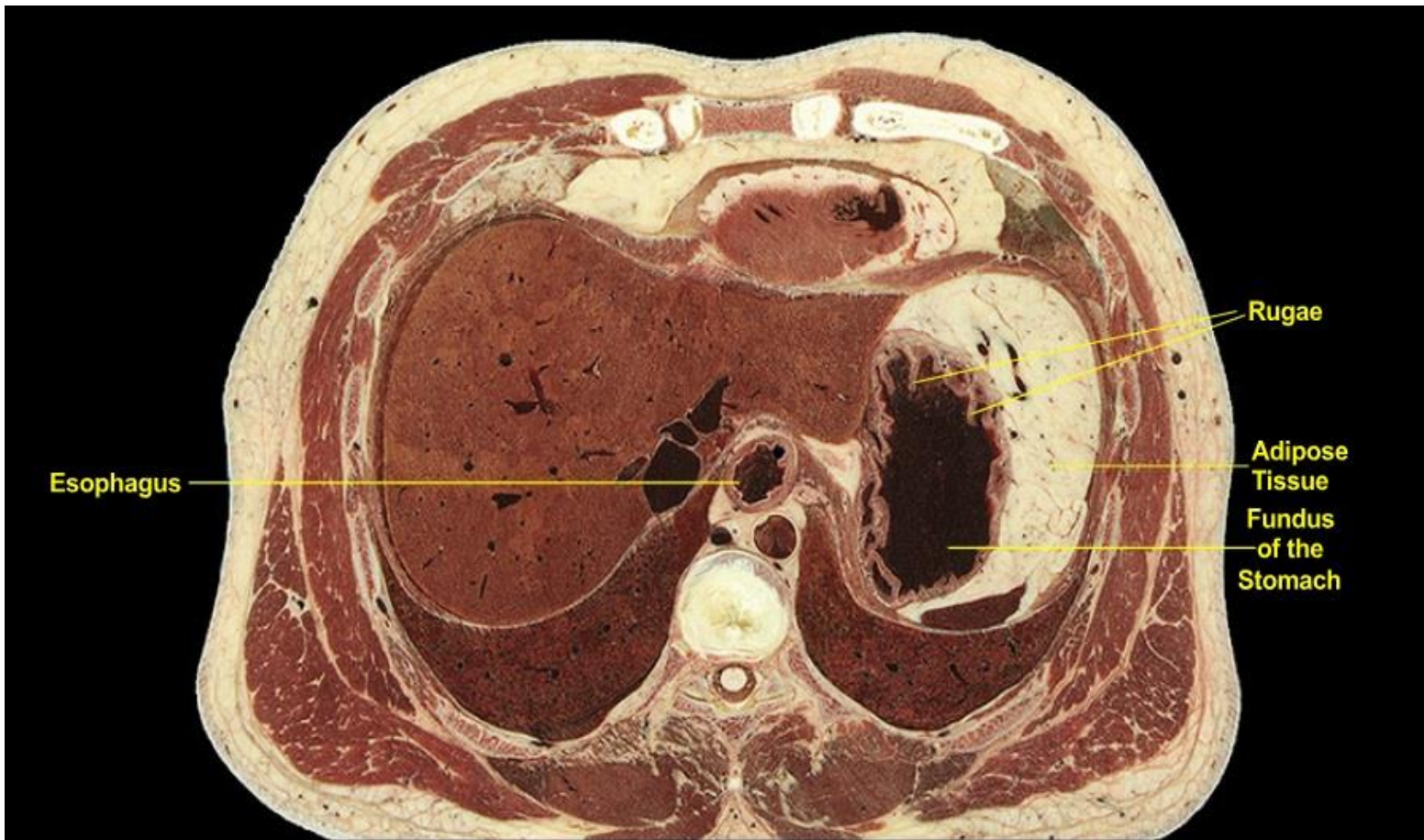Figura 1. The cross sectional levels.

Sagittal section through the Visible Male cadaver. The diaphragm forms the roof of the abdominal cavity and also contributes to its upper posterior wall by virtue of its lumbar origin, which extends as far inferiorly as the 3rd lumbar vertebra. The sternal origin of the diaphragm from the xiphoid process lies significantly more superiorly in the body than does the lumbar origin, giving the diaphragm the shape of an inverted letter J in sagittal section. Therefore, abdominal cross-sections will be entirely surrounded by diaphragm at and above the xiphoid process while they will be only partially surrounded by diaphragm when the plane-of-section lies between the xiphoid process and the 3rd lumbar vertebra.

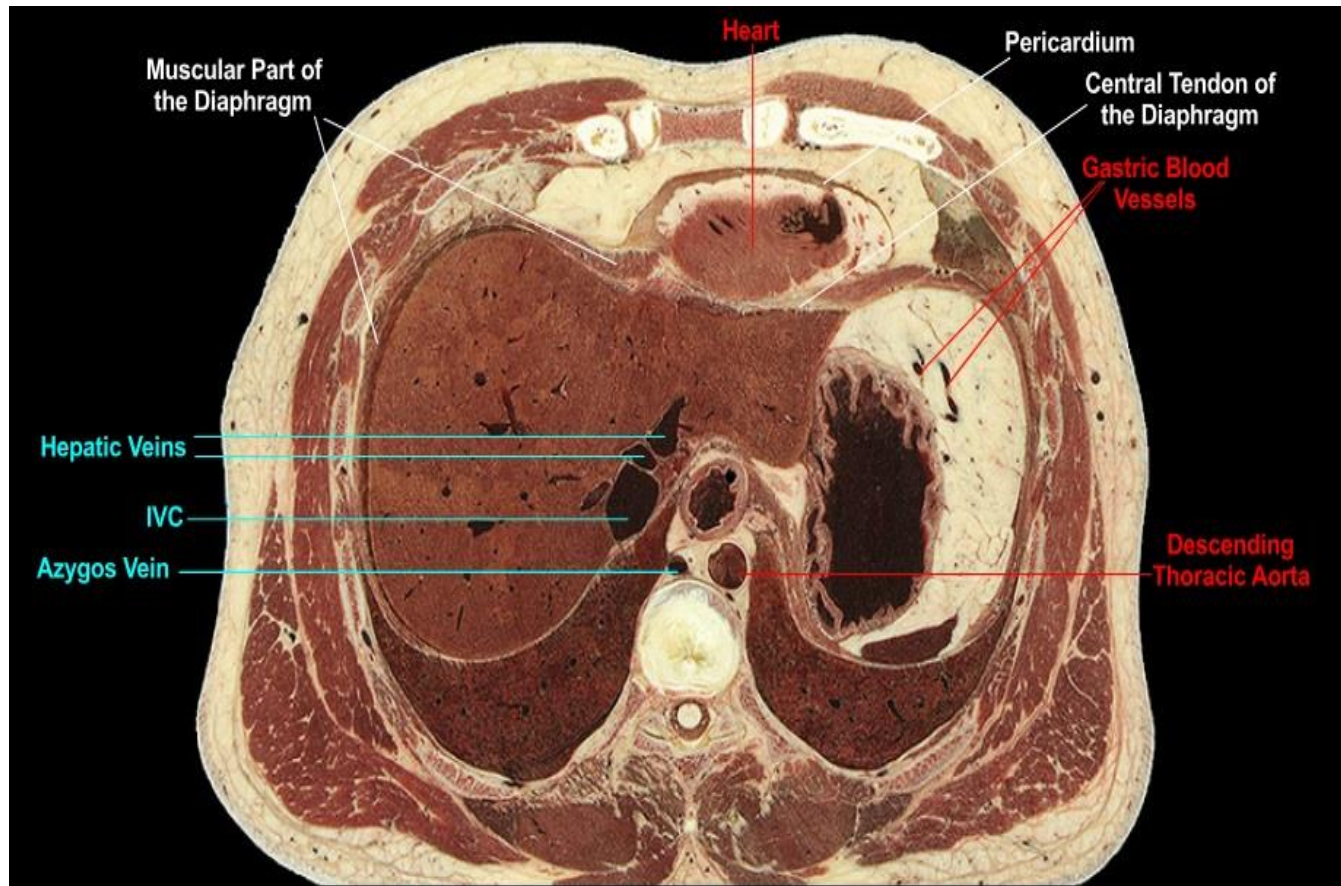
Level 1 (T9)



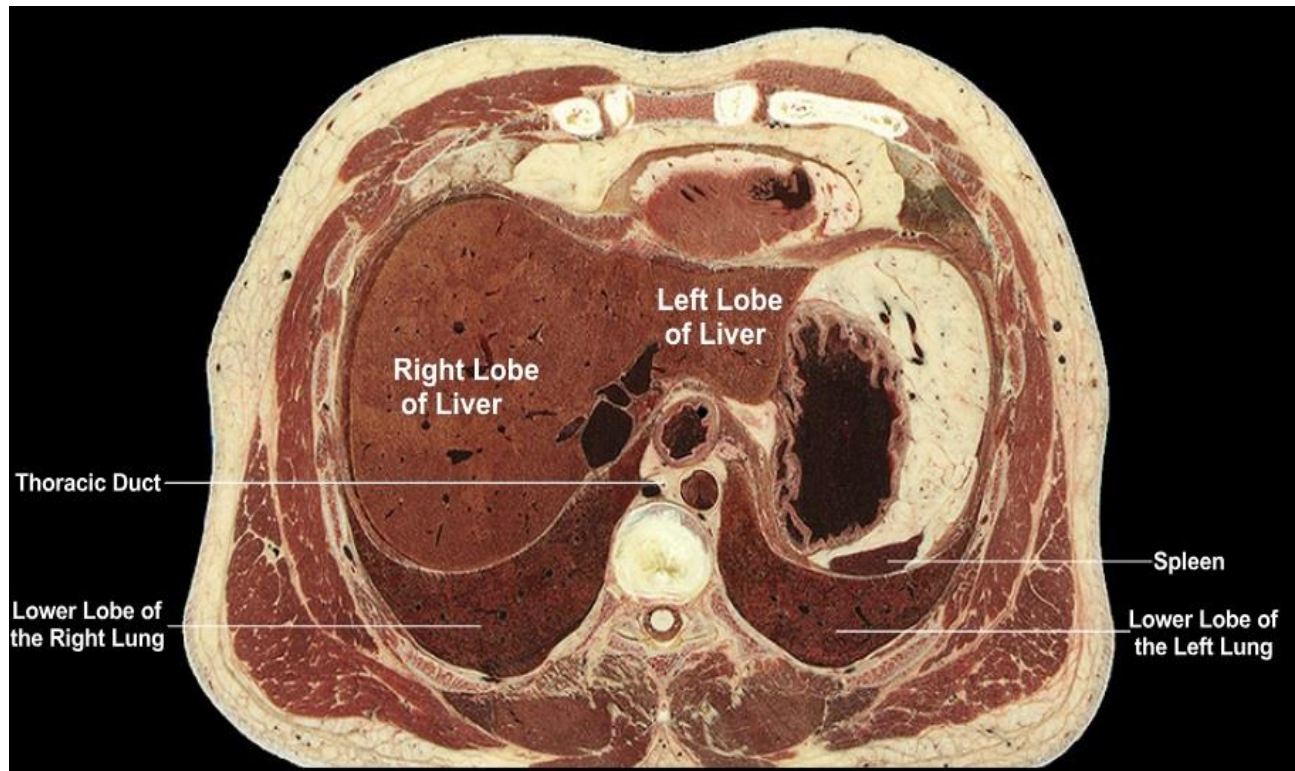
- Figura 2. Musculoskeletal aspect of the level 1.
- MUSCULOSKELETAL:
- Level of the T9-T10 intervertebral disc. We note the intercostal muscles of the thorax and the bones (ribs, sternum, and thoracic vertebrae) of the thoracic cage. Muscles of the upper limbs lie superficial to the thoracic wall. The dome-shaped diaphragm forms the roof of the abdomen and as such viscera in the upper abdominal cavity lie deep to the thoracic wall. Note the close proximity of the liver to the adjacent thoracic wall and right lung with the thin diaphragm intervening between the two body regions. Hence cross-sections of lower thorax and upper abdomen include significant structures of each region within the same plane.



- Figura 3. Gastrointestinal aspect of the level 1.
- GASTROINTESTINAL:
- We note the close proximity of the fundus of the stomach to the diaphragm and liver; when viewed in three dimensions the fundus typically lies immediately inferior to the left dome of the diaphragm and the left lobe of the liver. We observe the rugae (longitudinal folds of mucous membrane) lining the inner walls of the stomach. A large volume of intra-abdominal adipose tissue surrounds much of the stomach.

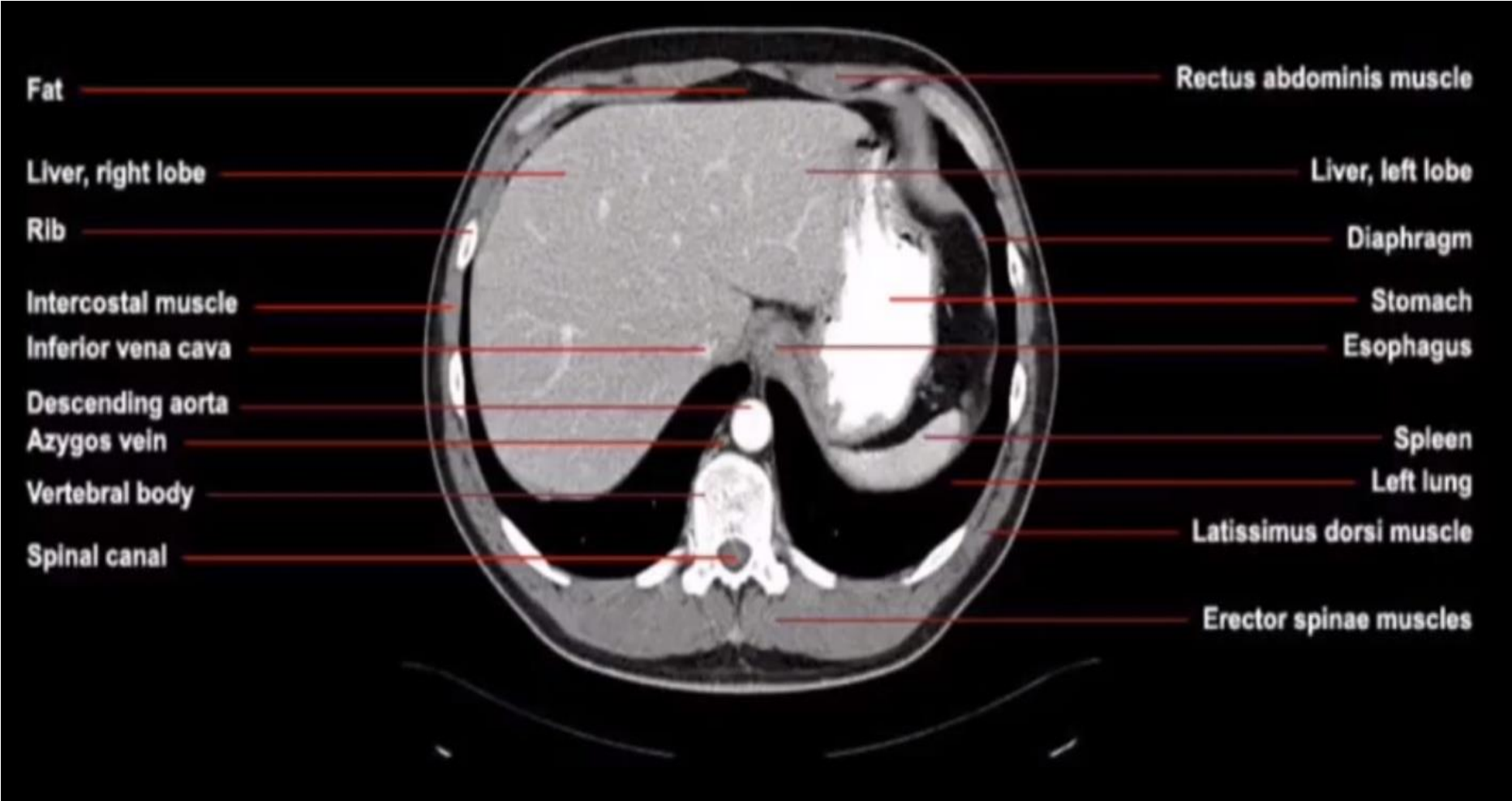


- Figura 4. Vascular aspect of the level 1.
- VASCULAR:
- We note the close contact between the inferior vena cava (IVC) and the liver, which has a depression on its posterior medial surface to accommodate the IVC. Hepatic veins, most of which join the IVC near the superior surface of the organ, are prominent. In the adipose tissue adjacent to the fundus of the stomach there are some vascular profiles of gastric blood vessels. The descending aorta and azygos vein lie within the thorax immediately anterior to the vertebral column while the inferior aspect of the heart lies anteriorly, separated from the abdomen by the diaphragm.

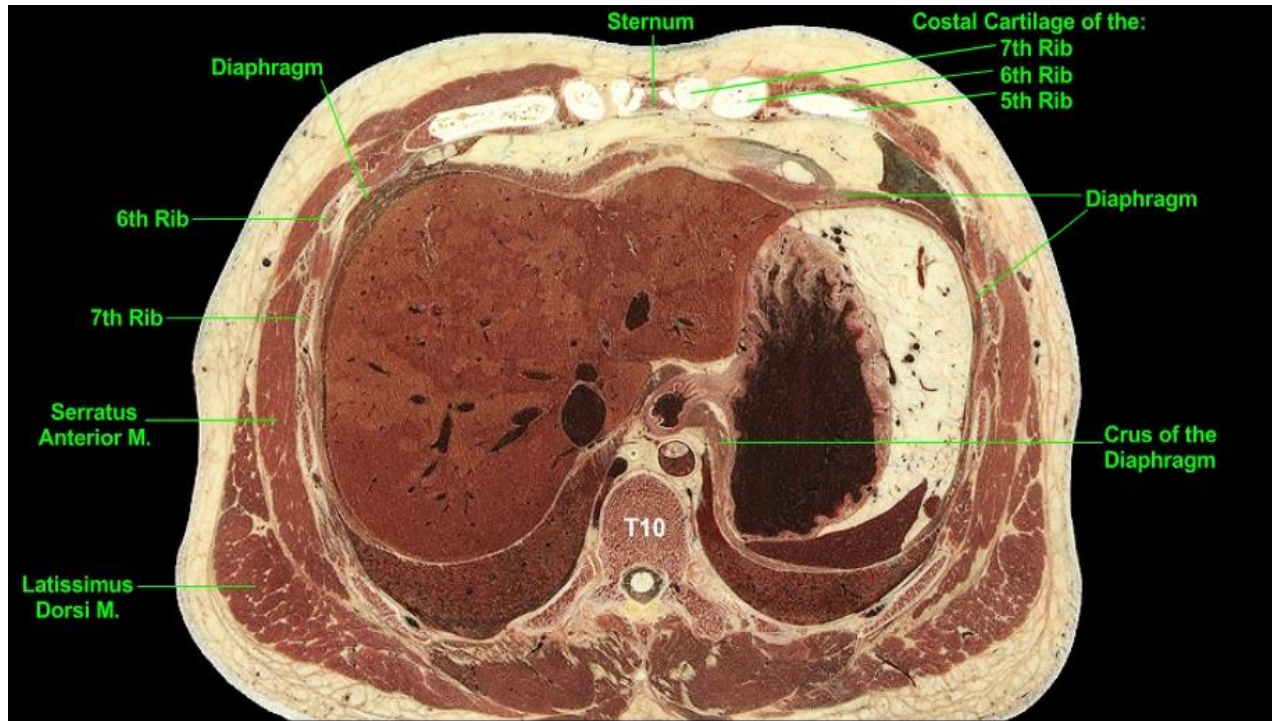


- Figura 5. Other organs at the level 1.
- OTHER:
- The liver is the largest organ in the body and occupies a large cross-sectional area at this level; its right lobe dominates the right side of the upper abdominal cavity. We note the liver's close proximity (with intervening peritoneum and fascia) to the diaphragm and its position deep to the thoracic wall. The smaller left lobe of the liver extends across the midline. The lower lobe of the right lung lies immediately posterior to the liver (with intervening diaphragm). The spleen, positioned on the left posterior aspect of the abdominal cavity adjacent to the diaphragm, is sectioned at its superior most aspect.

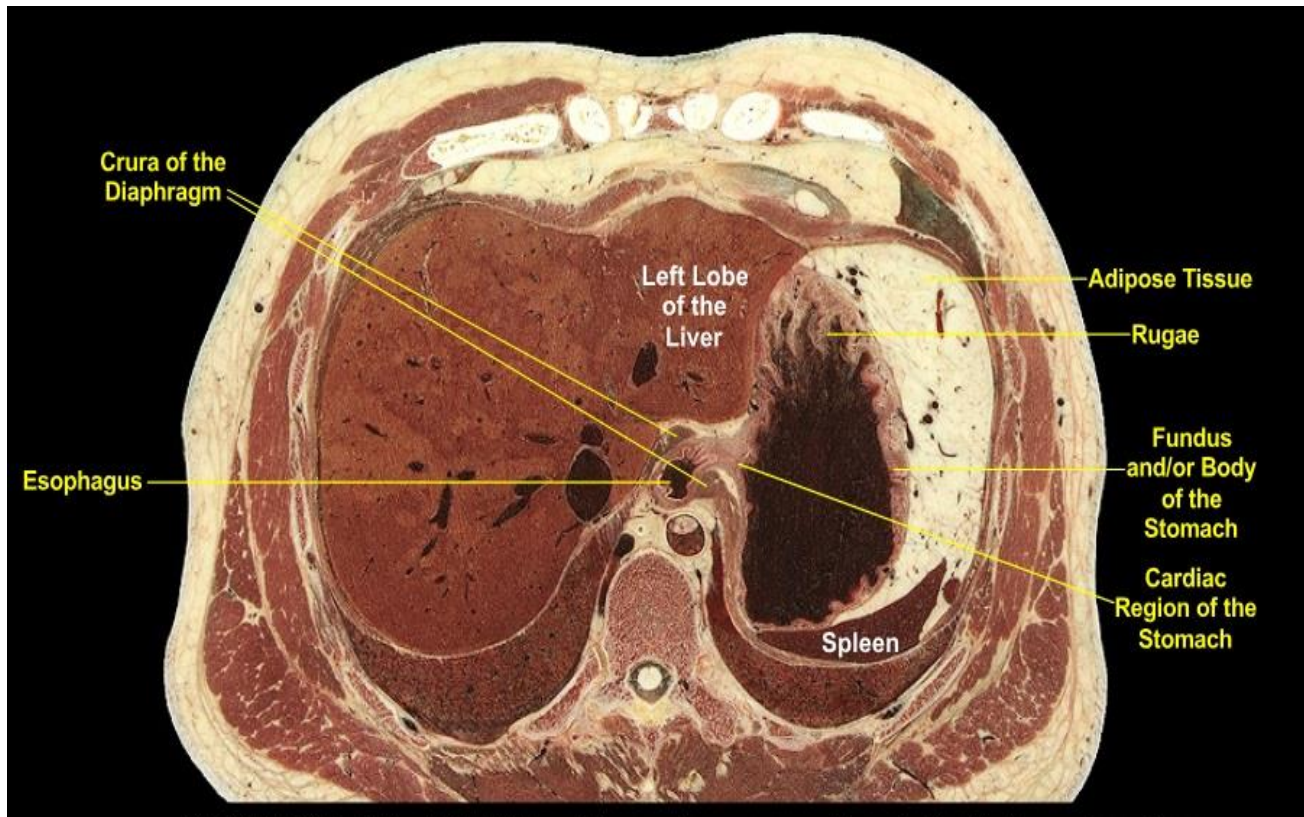
CT VIEW



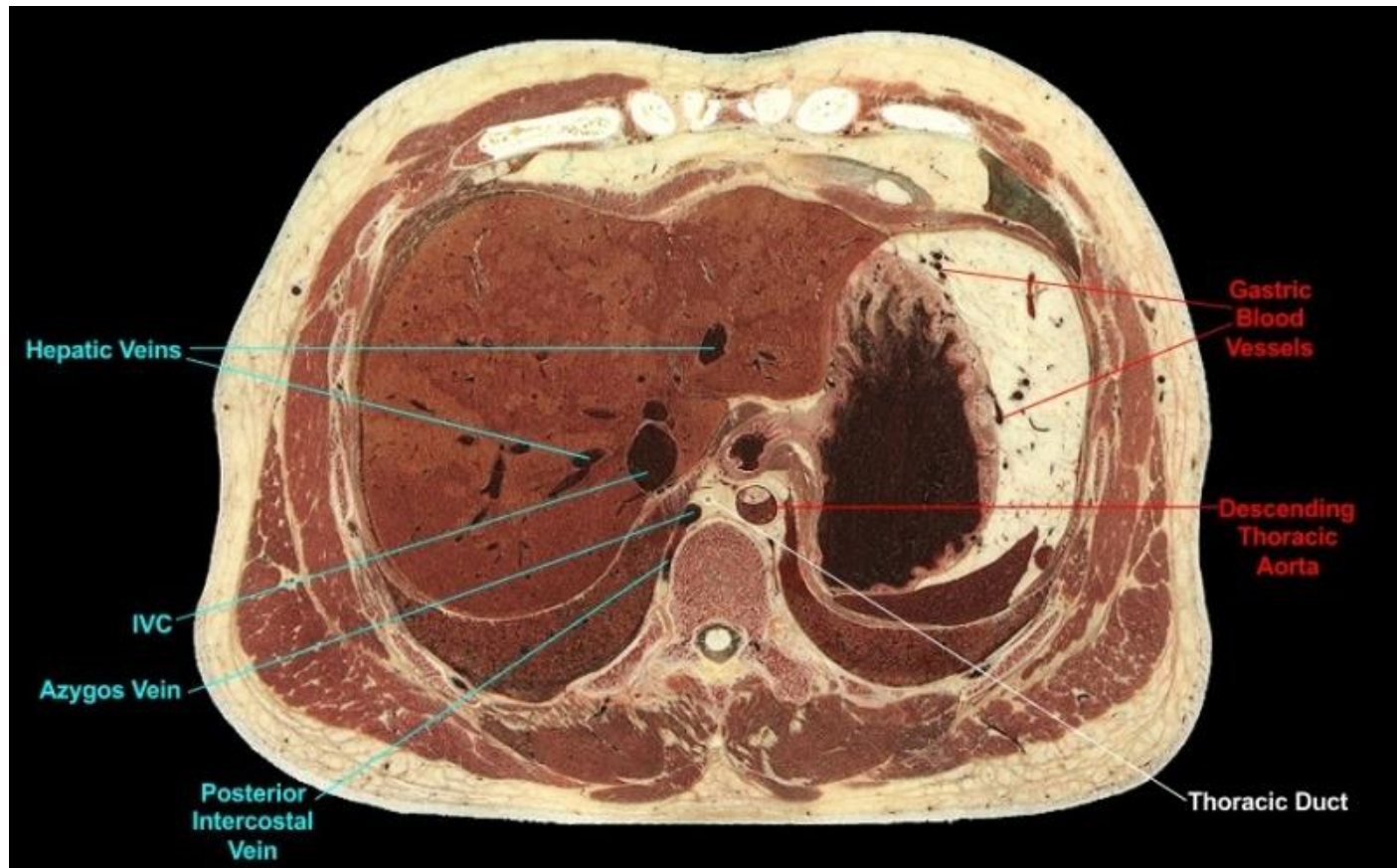
Level 2 (T10)



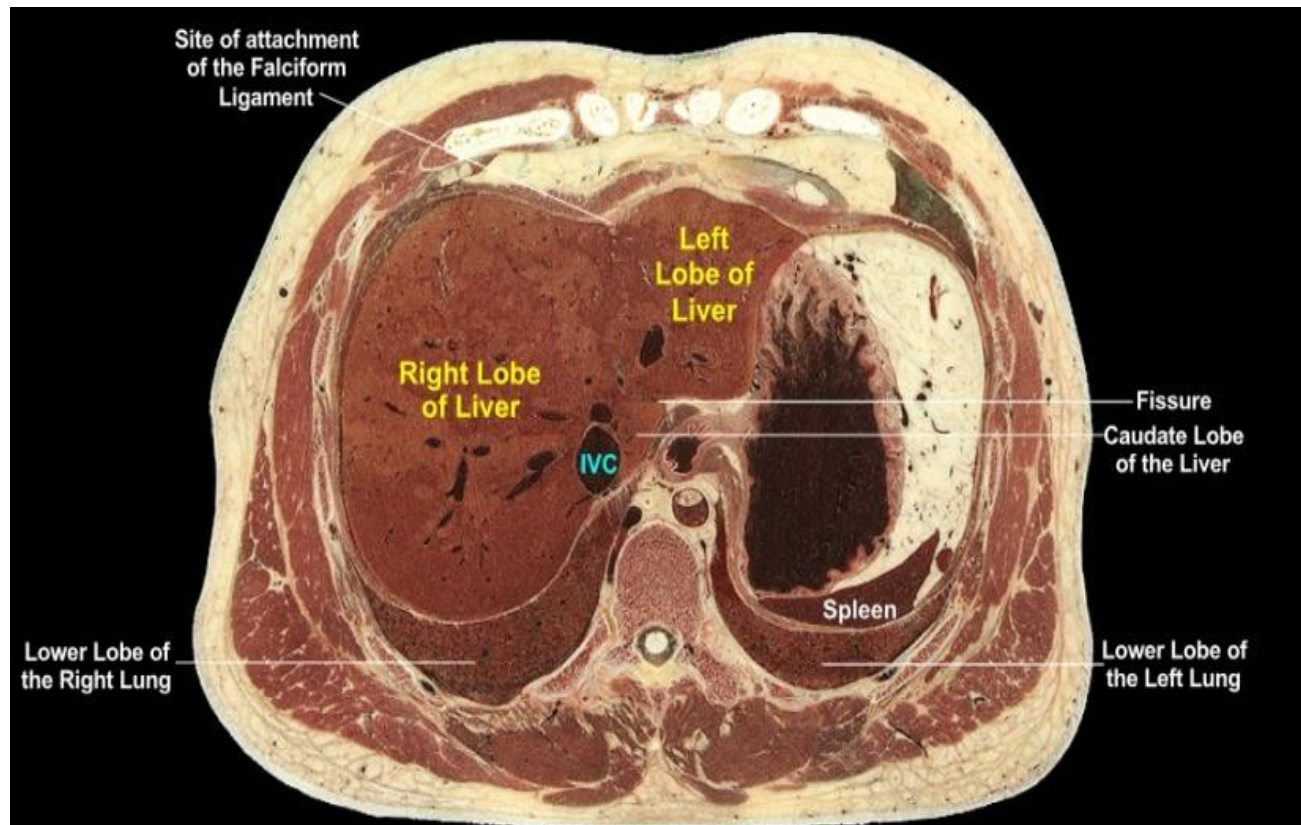
- Figura 7. Musculoskeletal aspect of the level 2.
- MUSCULOSKELETAL:
- Level of the T10 vertebra. We note the small cross-sectional area of the sternum and the costal cartilages of the 7th ribs; the 7th ribs are the last true ribs, i.e. those whose costal cartilages articulate with the sternum. The costal cartilages of the 5th, 6th, and 7th ribs are aligned in a row close to the sternum. The 6th and 7th costal cartilages have actually ascended from more inferior levels (note the bodies of these ribs more laterally). Most of the musculature is that of the thorax and upper limb. We observe the diaphragm encircling the abdominal cavity, which at this level still lies deep to the thoracic wall.



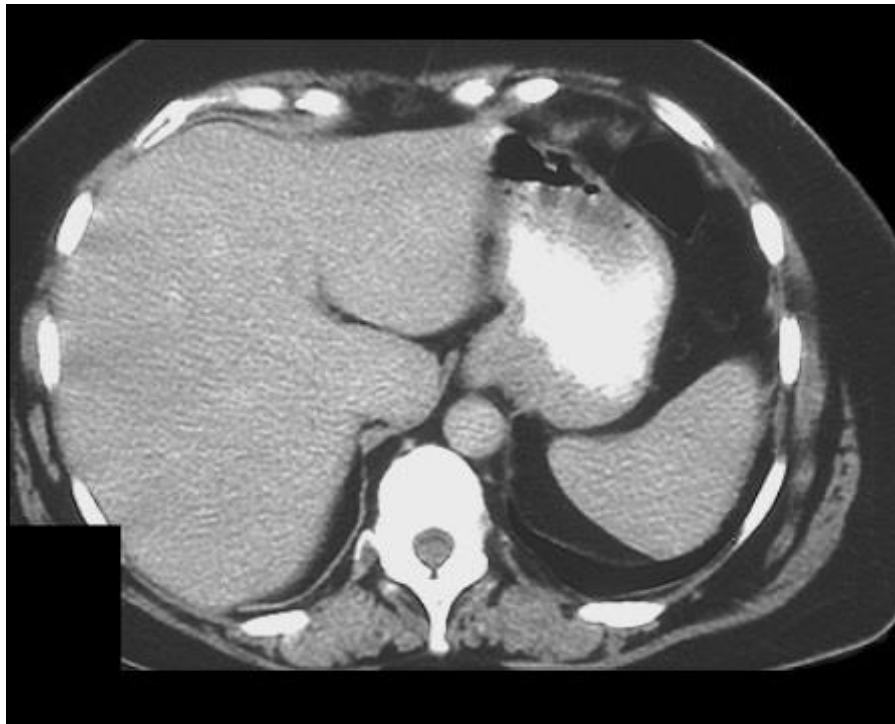- Figura 8. Gastrointestinal aspect of the level 2.
- GASTROINTESTINAL:
- At the T10 level the esophagus passes through the diaphragm, traveling a very short distance within the abdomen before becoming continuous with the stomach at the cardiac orifice. We note that the esophagus lies slightly to the left of midline and that it is encircled by the crura of the diaphragm. The region of the stomach at the esophagogastric junction is called the cardiac region, loosely named for the heart that lies above it in the thorax. The remainder of the stomach is near the transition between its fundus and its body. We note the structures neighboring the stomach, i.e. the spleen posteriorly, the left lobe of the liver to the right and anterior, and adipose tissue (including the greater omentum) predominately to the left but also anterior.



- Figura 9. Vascular aspect of the level 2.
- VASCULAR:
- At this level the descending aorta, azygos vein, and thoracic duct reside within the thorax; these structures enter or exit the abdomen posterior to the diaphragm at the level of T12. Observe the profiles of gastric blood vessels adjacent to the stomach in the adipose tissue. While the inferior vena cava (IVC), positioned slightly to the right of midline, is surrounded on most of its circumference by liver it actually resides in a groove or fissure on the postero-medial side of the organ.

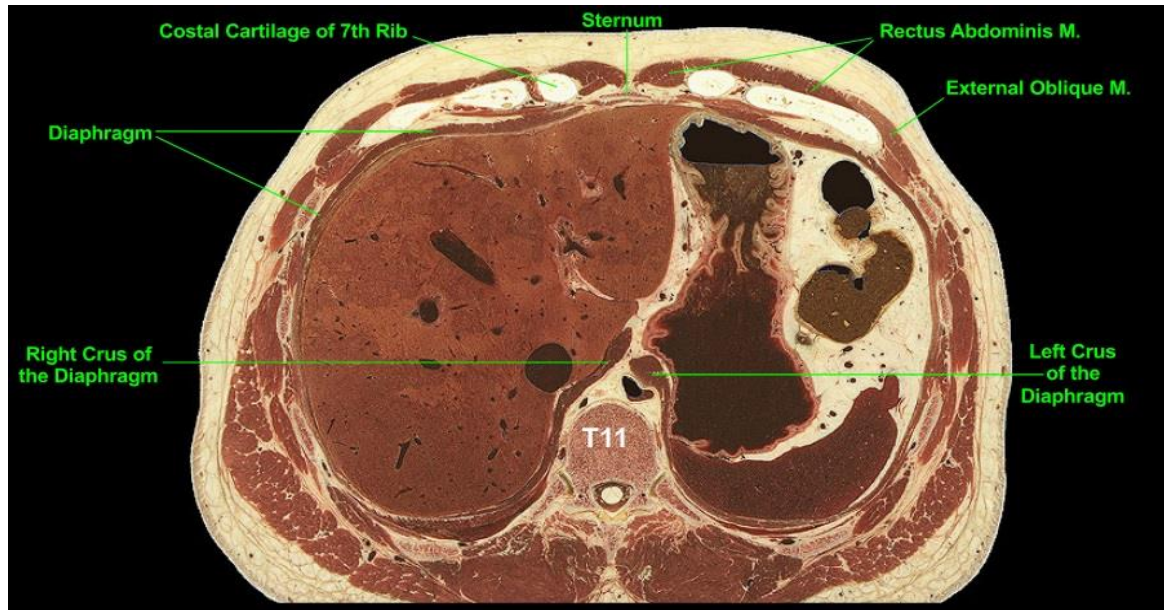


- Figura 10. Other organs of the level 2.
- OTHER:
- Closely on the postero-medial side of the liver for a fissure that anatomically separates the caudate lobe of the liver (which lies between the fissure and the inferior vena cava (IVC) from the left lobe of the liver. The slight depression on the anterior surface of the liver is the site of attachment of the falciform ligament. We observe the large profiles of hepatic veins within the substance of the liver. We note the spleen, positioned posteriorly on the left and lying immediately adjacent to the diaphragm and the stomach. The spleen lies deep to the thoracic wall.

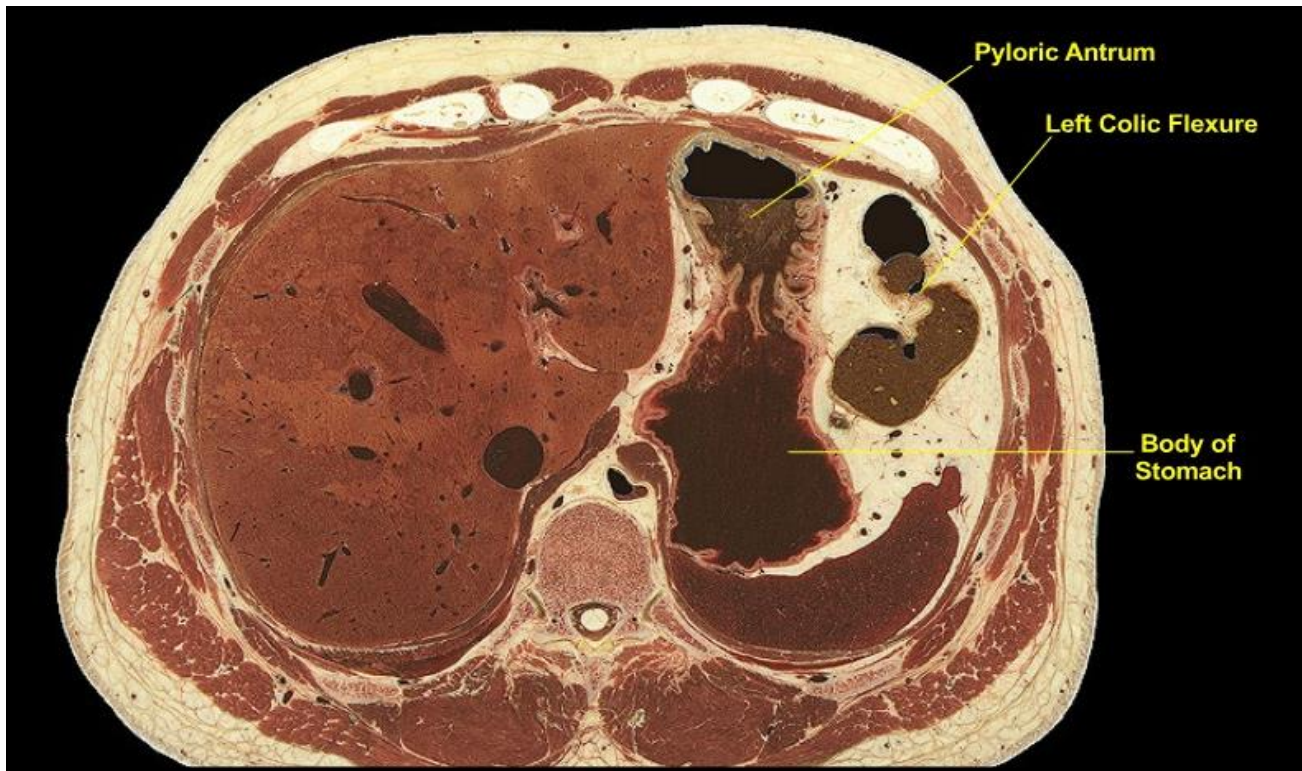

- Figura 11. CT view of the level 2.
- CT scan of the upper abdomen following the administration of oral contrast. The plane-of-section passes through the body and pyloric antrum of the stomach, the demarcation between the two not evident. The patient was in the supine position (on their back) and as such the barium accumulates in the posterior aspect of the stomach while air is displaced anteriorly to the pyloric antrum. We note that the orientation of the long axis of the stomach positions the posterior aspect of the body of the stomach adjacent to the spleen while the pyloric region lies anteriorly adjacent to the anterior abdominal wall. Comparing the positions of the stomach, left colic flexure, spleen, and liver with the cadaveric cross-section the air-filled lungs lie directly behind the liver and spleen. The intervening diaphragm is of the same radiodensity as the organs and thus in some areas is not distinguishable from them, although the crura of the diaphragm are prominent. The inferior vena cava, lying in a groove on the posterior side of the liver, is indistinguishable from the liver and as such its position is approximated.

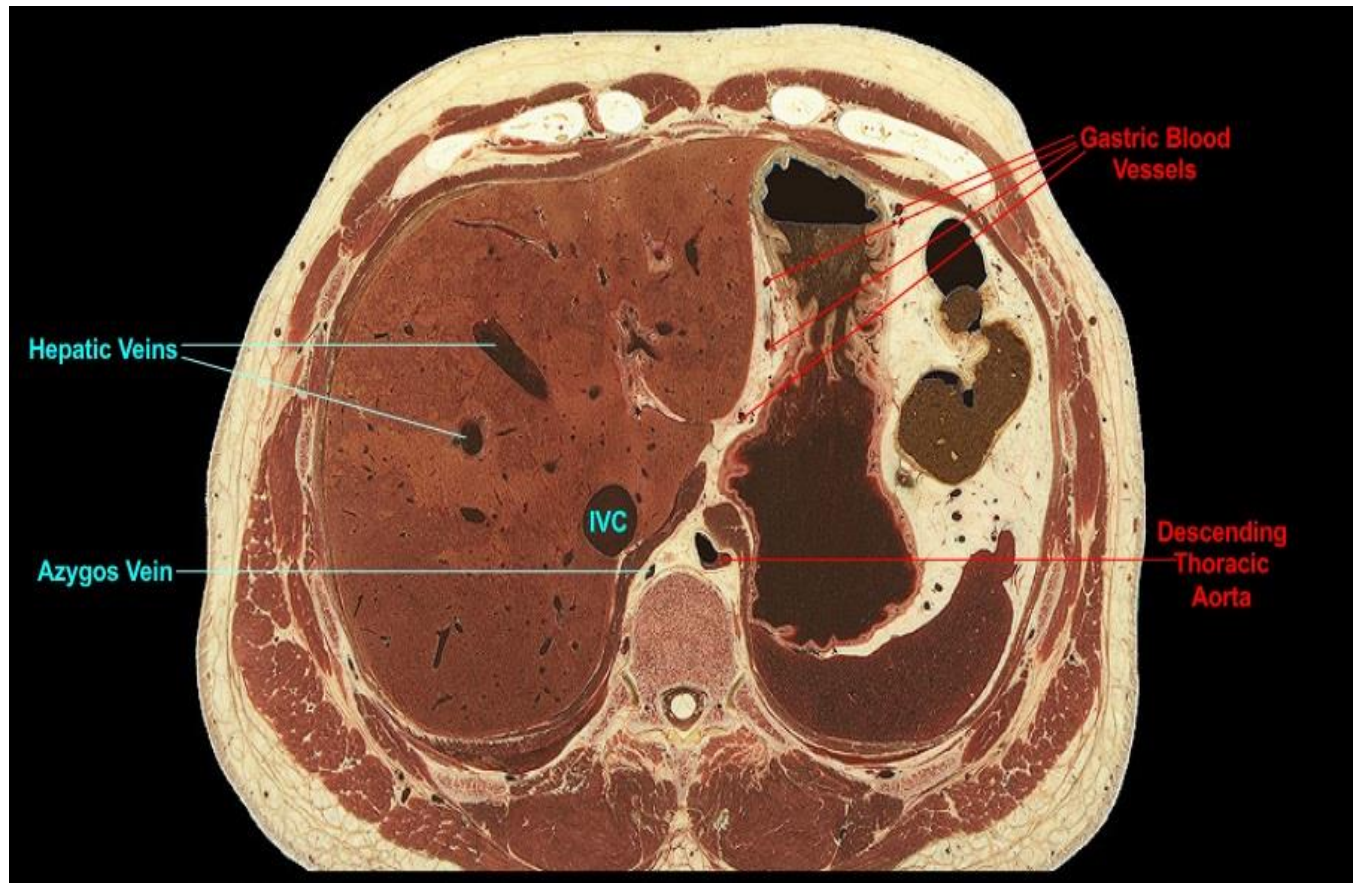Level 3 (T11)



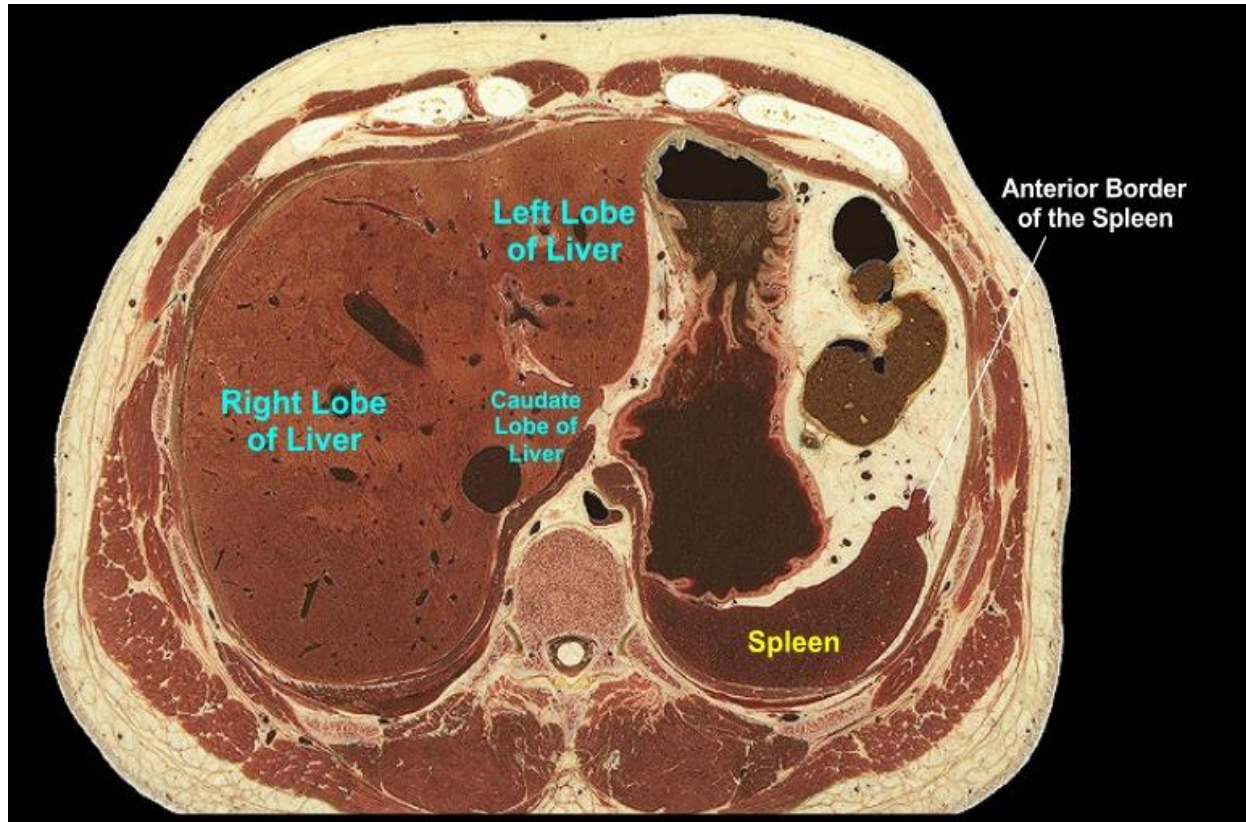
- Figura 12. Musculoskeletal aspect of the level 3.
- MUSCULOSKELETAL:
- Level of the T 11 vertebra. At this upper level the diaphragm forms the peripheral boundary of the abdominal cavity. The musculature of the anterolateral abdominal wall originates in part from the thoracic cage; note origins of the rectus abdominus (originating anteriorly near the midline from costal cartilages and sternum) and external oblique muscles (originating anterolaterally from ribs and costal cartilages). As the plane-of-section descends, observe the increase in mass of the abdominal wall muscles. While abdominal musculature is emerging, appreciate that the abdominal organs viewed at this level still lie deep to the thoracic wall.



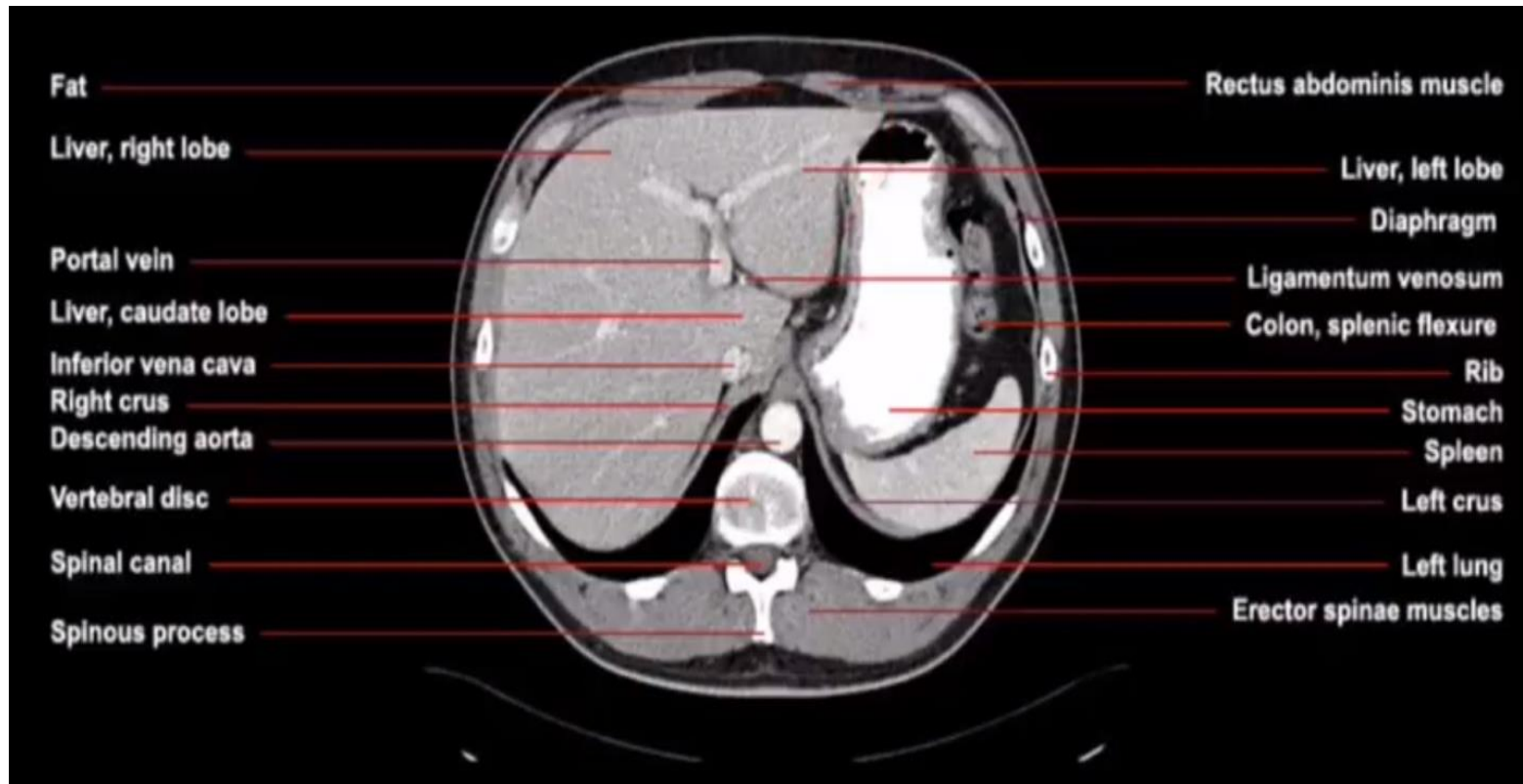
- Figura 13. Gastrointestinal aspect of the level 3.
- GASTROINTESTINAL:
- The plane passes through both the body of the stomach and the pyloric antrum (the expanded chamber of the pyloric portion of the stomach). There is no readily evident demarcation where body ends and pyloric antrum begins in the cross-sectional plane. Of particular note is the left colic flexure (splenic flexure) where transverse and descending colons are continuous with each other. At a slightly more inferior level the anterior portion of the flexure will become continuous with the transverse colon while the posterior portion of the flexure will become continuous with the descending colon.



- Figura 14. Vascular aspect of the level 3.
- VASCULAR:
- Level of the T11 vertebra and thus the descending aorta and azygos vein reside within the thorax. The left and right crura of the diaphragm extending around the aorta; the aorta passes from the thorax to the abdomen by passing posterior to the diaphragm. The inferior vena cava (IVC) lies within a groove on the posterior side of the liver immediately behind the caudate lobe. Large profiles of hepatic veins are evident within the substance of the liver. Although not readily identifiable by name, gastric blood vessels to the stomach course along the curvatures of the stomach and project through the adipose-rich peritoneum.

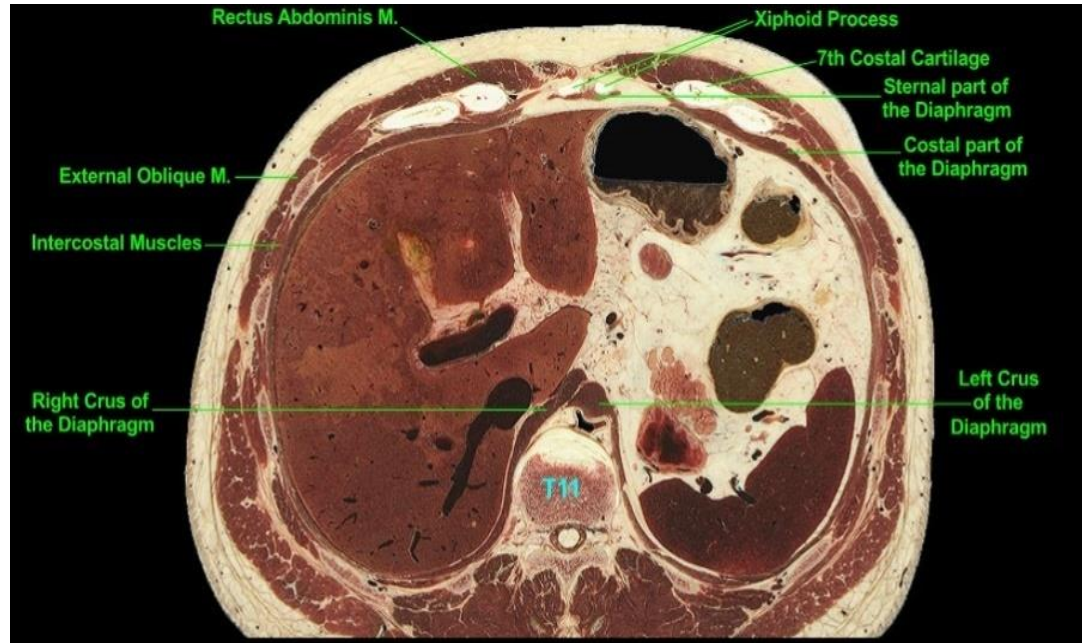

- Figura 15. Other organs of the level 3.
- OTHER:
- The fissure that separates the caudate and left lobes of the liver is prominent. The size of the liver as an organ cannot be overstated, occupying the entire right and center midline of the abdominal cavity at this level. The normal spleen is characterized by a "notched" anterior border and that irregularity is now evident in cross-section. Note the spleen's posterior convex surface (also called the diaphragmatic surface) fitting the contour of the adjacent diaphragm and thoracic cage while its concave anterior surface (called the visceral surface) abuts the body of the stomach at this level.

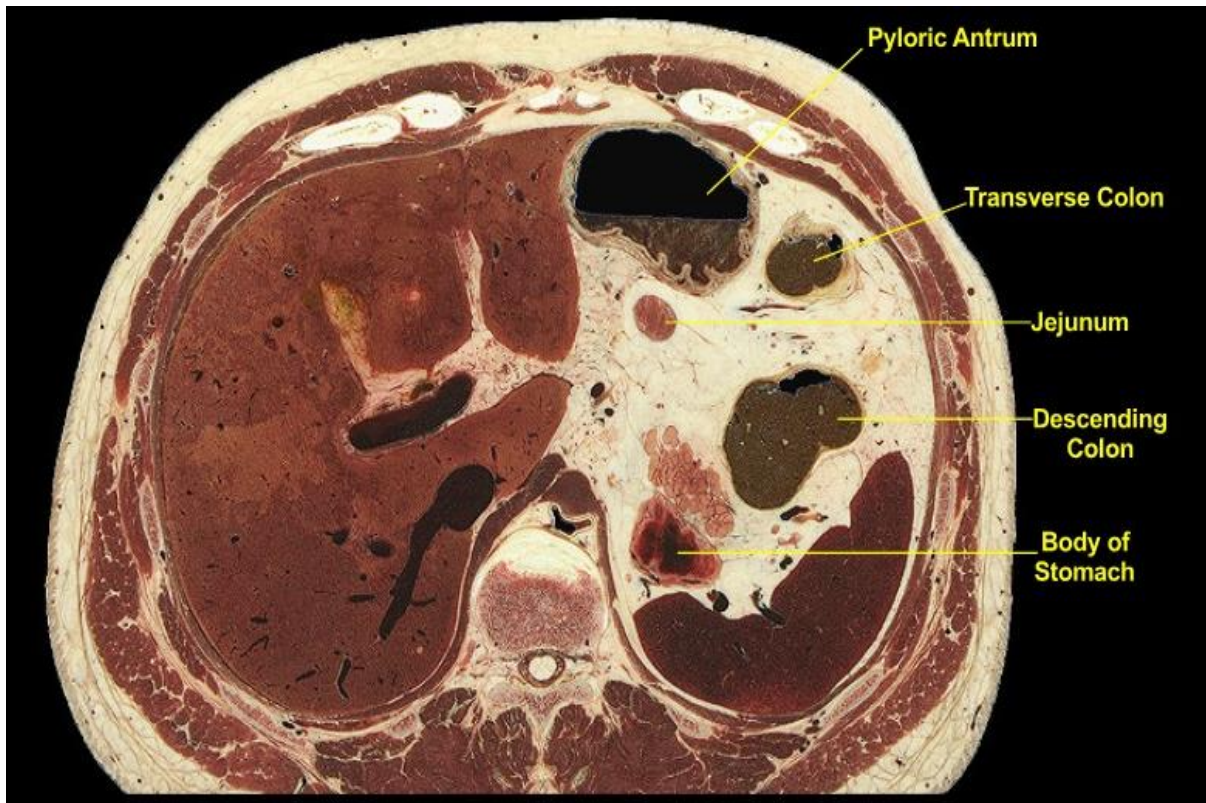


- Figura 16. CT view of the level 3.

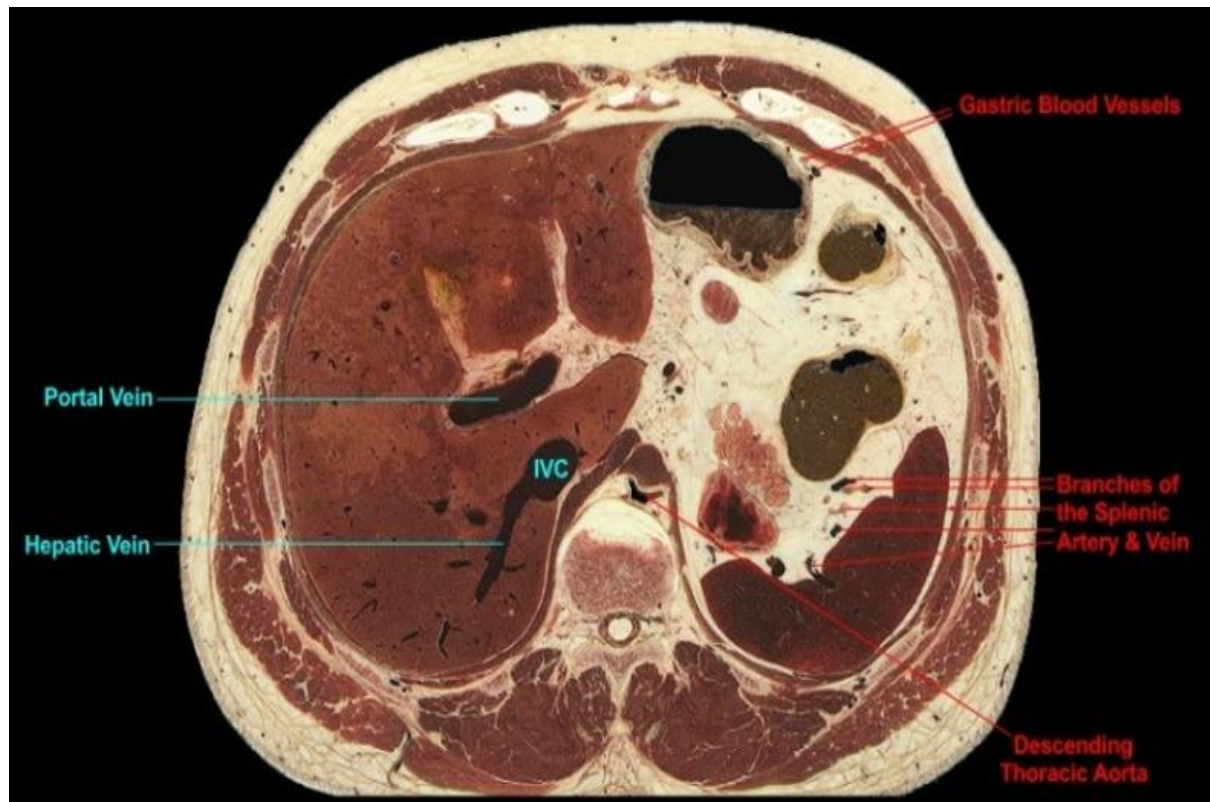
Level 4 (T11)



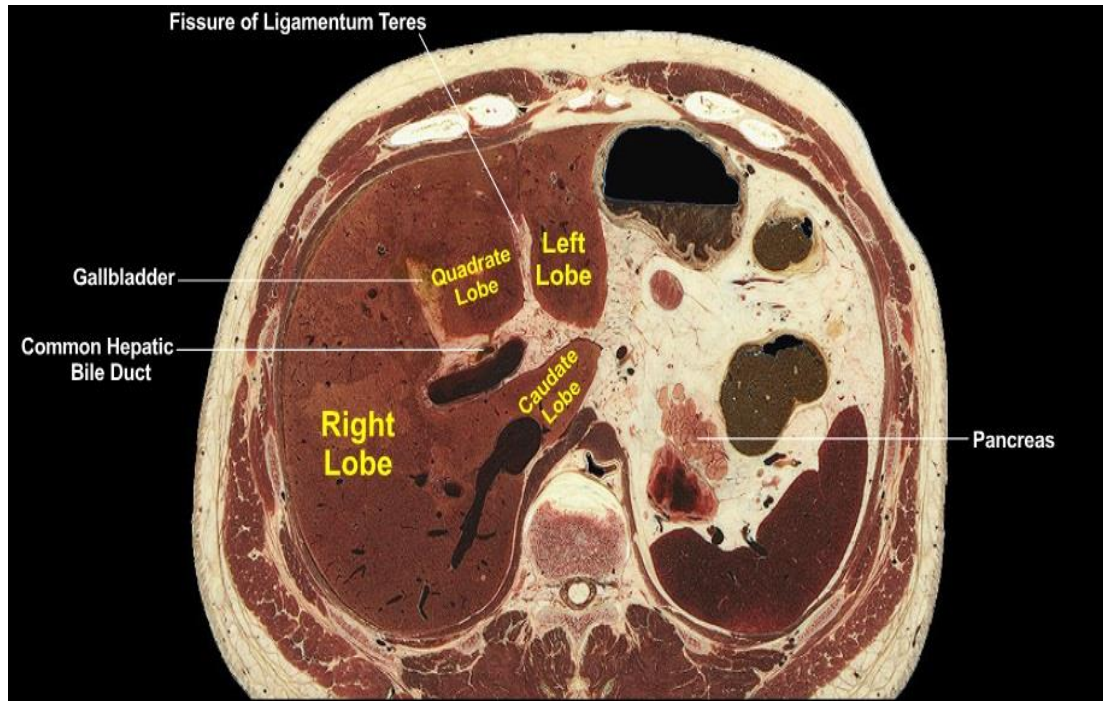
- Figura 17. Musculoskeletal aspect of the level 4.
- MUSCULOSKELETAL:
- Level of the body of T11. The sternum is sectioned through its xiphoid process, which based on age is still part cartilage in this individual. The sternal origin of the diaphragm from the xiphoid process is significantly more superior in the body than is the diaphragm's lumbar origin (not present) from lumbar vertebrae. Thus inferior to this level the diaphragm will no longer be present anteriorly and it will progressively decrease laterally as the plane descends through the costal margins, which contribute to the origin of the costal part of the diaphragm. We note the rectus abdominis muscles anteriorly and the externali oblique muscles anterolaterally taking origin from the lower thoracic cage.



- Figura 18. Gastrointestinal aspect of the level 4.
- GASTROINTESTINAL:
- The plane passes through the lower body and the pyloric antrum of the stomach but due to the curvature of the organ the continuity of the two parts is not evident. The plane also lies inferior to the left colic flexure and thus the continuity of transverse and descending colon is not evident. The descending colon is positioned in the abdominal cavity on the left posterior side; the transverse colon lies more anteriorly and as the plane descends further profiles of transverse colon will also appear on the right side of the abdominal cavity. A single profile of jejunum appears among the abdominal adipose tissue, which is a combination of mesentery of the small intestine, the greater omentum, and the transverse mesocolon.

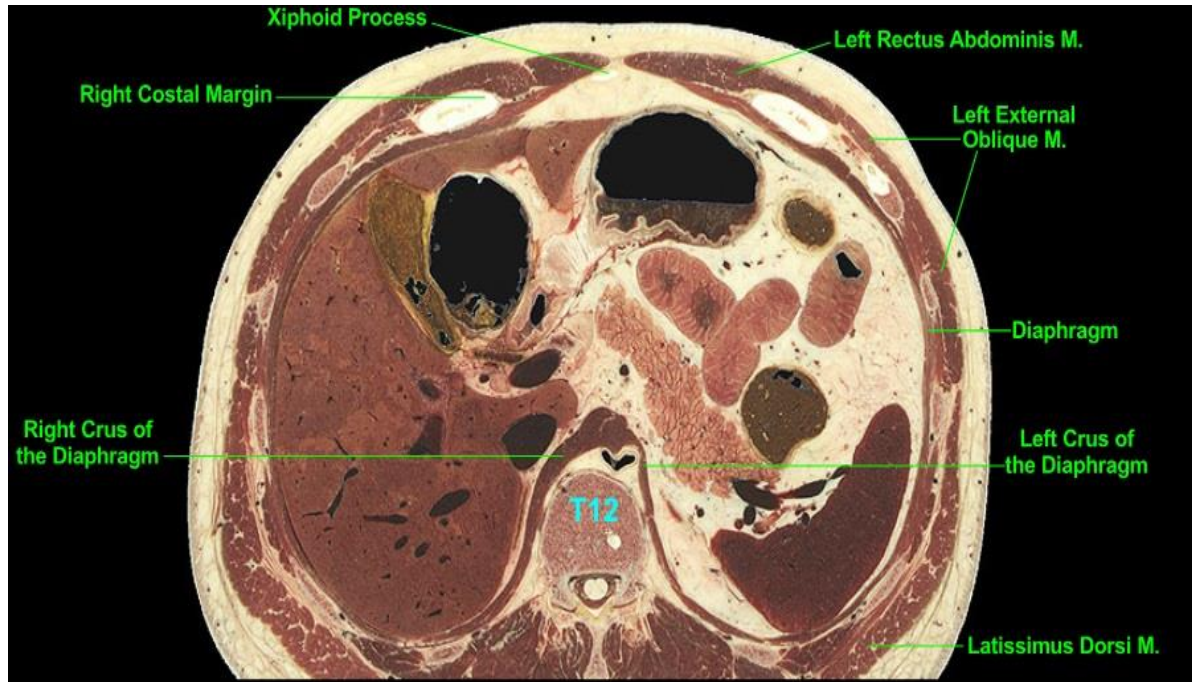


- Figura 19. Vascular aspect of the level 4.
- VASCULAR:
- The descending aorta lies within the thorax, being renamed the abdominal aorta (or abdominal part of the descending aorta) at the T12-L1 intervertebral disc. Gastric blood vessels are seen close to the pyloric antrum. We observe tributaries of the splenic vein and branches of the splenic artery on the visceral side (concave side) of the spleen. Of particular note is the appearance of the porta hepatis of the liver and the large portal vein lying within it.

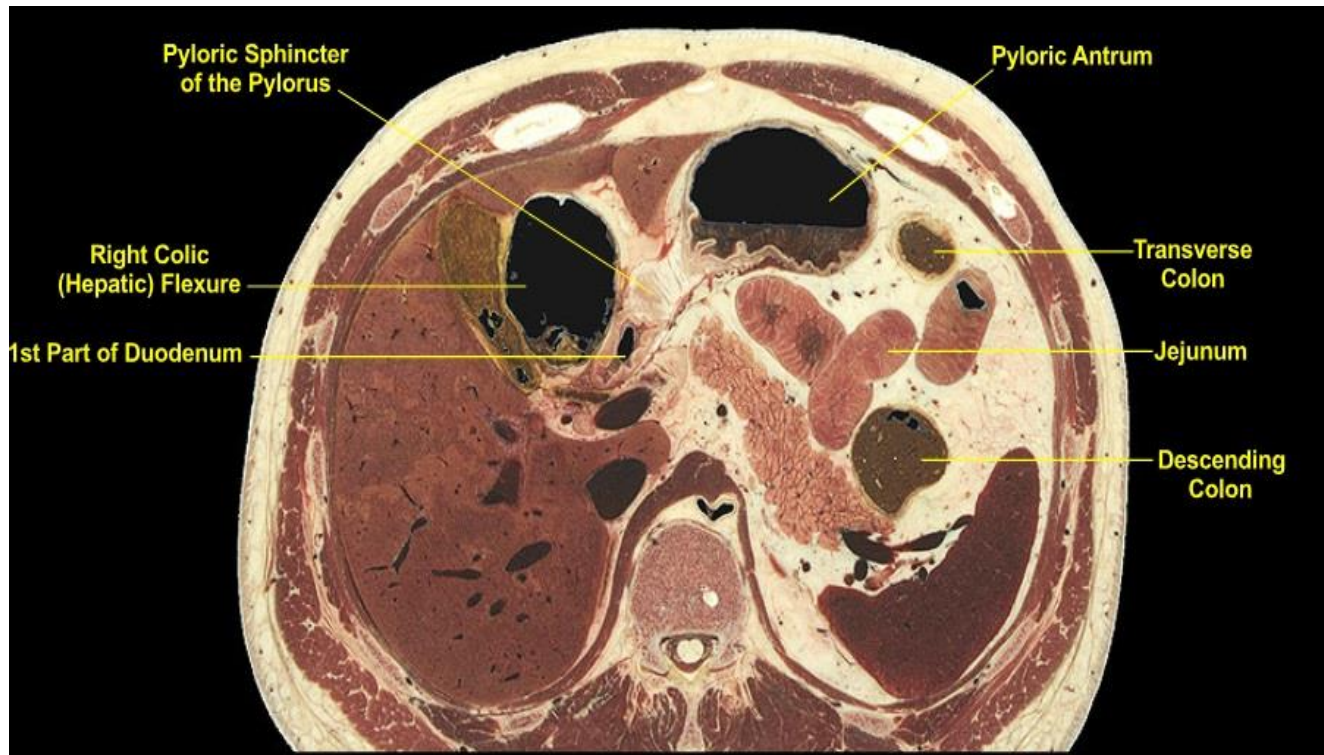


- Figura 20. Other organs of the level 4.
- OTHER:
- On the deep (visceral) surface of the liver resides the porta hepatis, the large fissure through which blood vessels, nerves, and bile ducts enter and/or exit the liver. The portal vein and the common hepatic bile duct are prominent. The wall of the gallbladder is barely visible; the gallbladder sits in a depression on the visceral surface of the liver. The fissure for the ligamentum teres (the embryonic remnant of the umbilical vein) parallels the fissure for the gallbladder and the two fissures anatomically separate the quadrate lobe from the left and right lobes. The left lobe has progressively become smaller as the plane descends and here it just barely extends across the midline. A small segment of pancreas points toward the spleen.

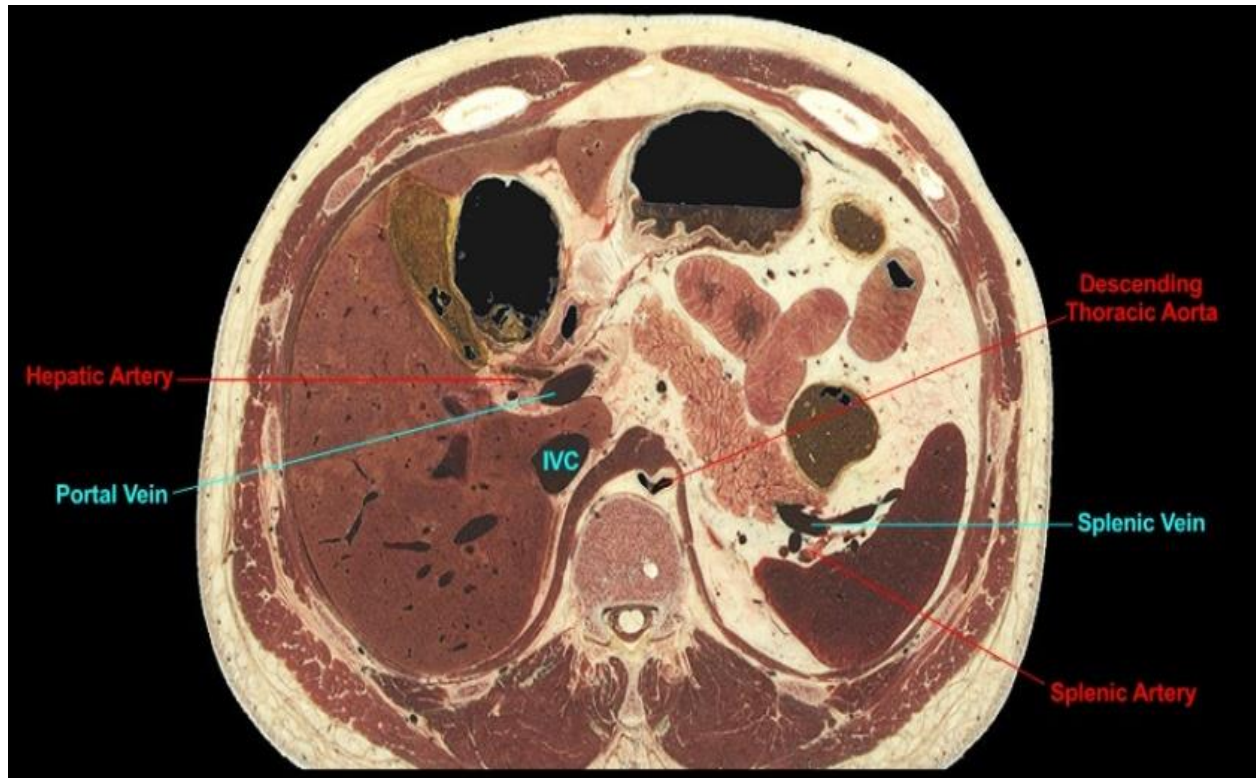
Level 5 (T12)



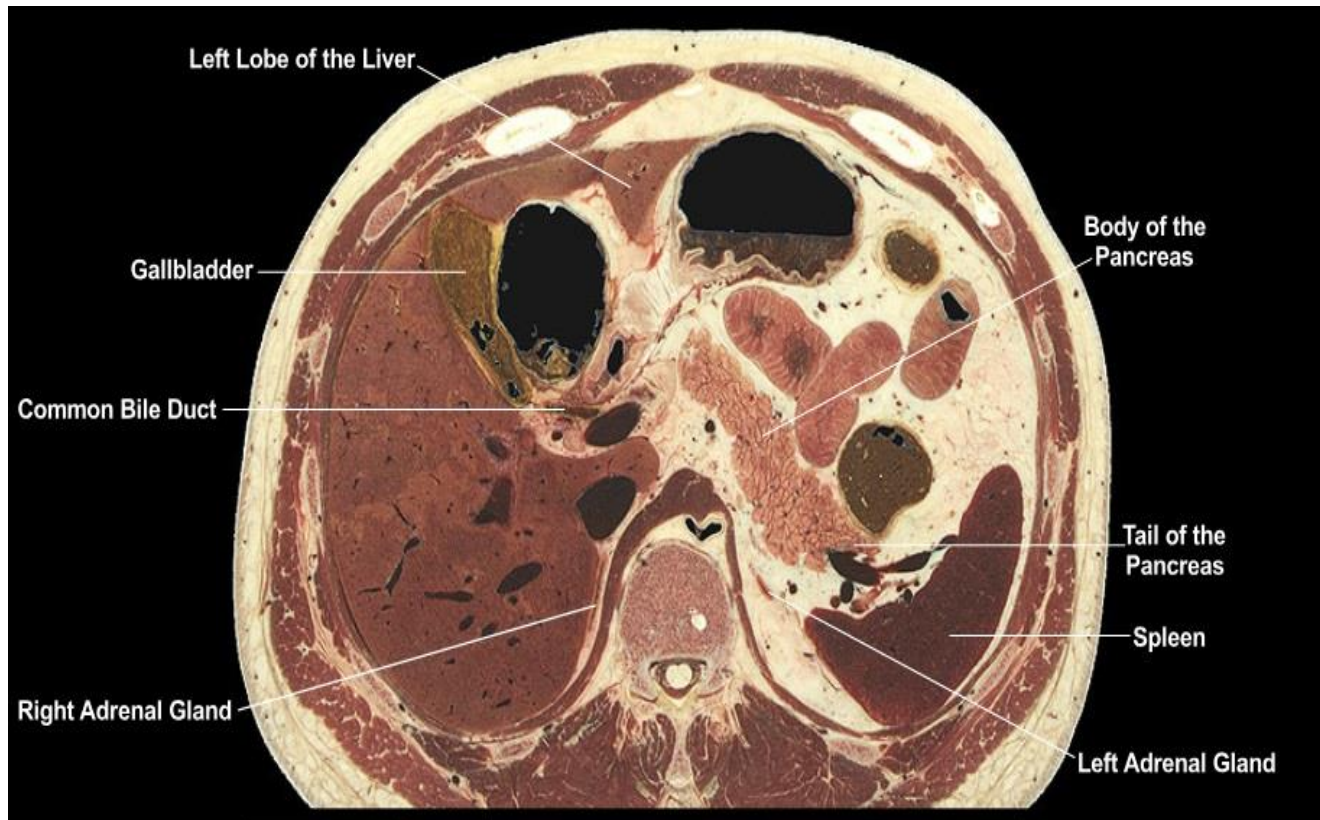- Figura 21. Musculoskeletal aspect of the level 5.
- MUSCULOSKELETAL:
- The plane passes through the lower tip of the xiphoid process; below this level the costal margins (comprised of the cartilages of the 7th to 10th ribs) will progressively move more laterally as the plane descends through them. The 12th thoracic vertebra is present and thus the plane lies near the lower limit of the posterior thoracic wall. The left and right rectus abdominis muscles of the anterior abdominal wall lie on either side of the midline, descending from origins on the 5th through 7th costal cartilages. The external oblique muscles contribute to the lateral walls of the abdomen, although at this level they are taking origin from the external surfaces of the ribs (full origin is 5th through 12th ribs) and thus here the muscles overlies the thoracic wall.



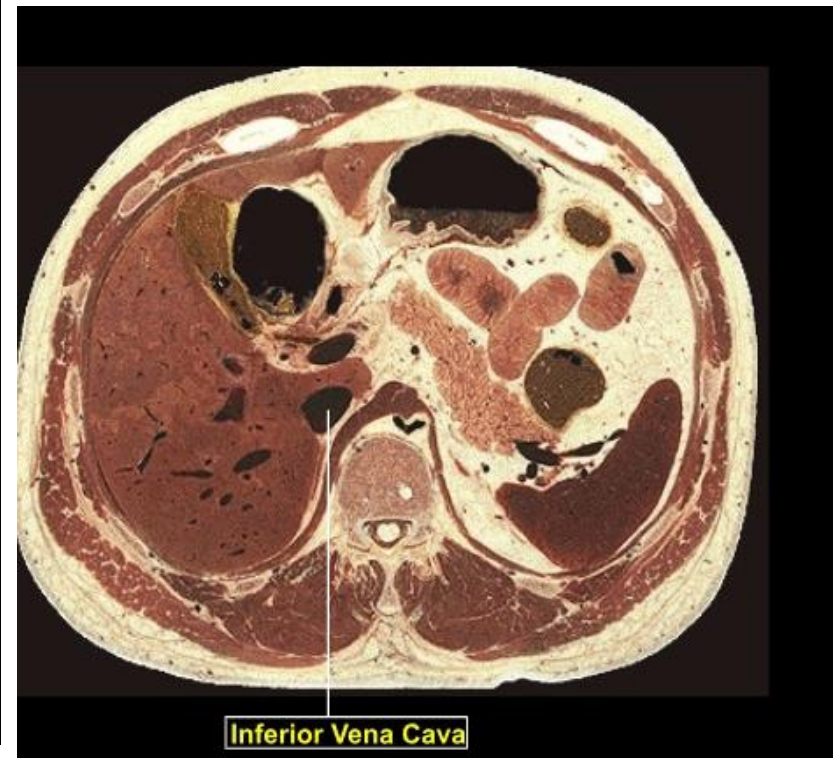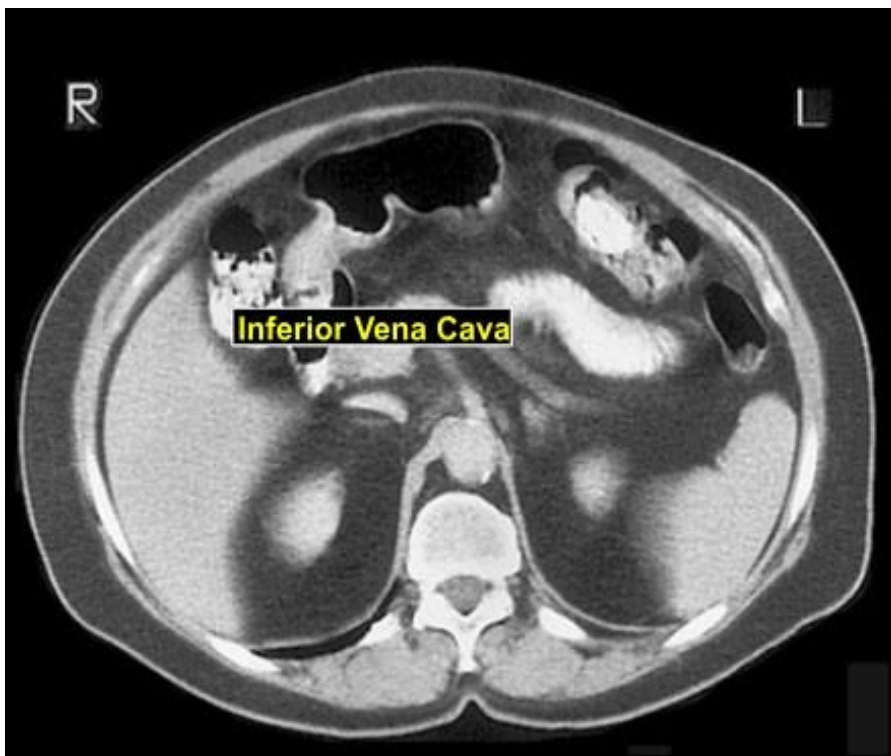
- Figura 22. Gastrointestinal aspect of the level 4.
- GASTROINTESTINAL:
- The pyloric antrum lies anteriorly adjacent to the left lobe of the liver. The pylorus of the stomach consists of the thick-walled pyloric sphincter surrounding the narrow pyloric canal (the canal is not visible); note the continuity of the pyloric antrum, pylorus, and 1st part of the duodenum. Also note the close proximity of the duodenum and the right colic (hepatic) flexure to the visceral surface of the liver. Distinguish profiles of colon (transverse, descending, and right colic flexure) from those of jejunum, the latter lying among the intra-abdominal fat in the mesentery of the small intestine. As the plane descends, remember that jejunum of the small intestine lies more superiorly in the abdominal cavity than does the ileum of the small intestine.



- Figura 23. Vascular aspect of the level 5.
- VASCULAR:
- The plane passes through the body of T12 and thus the descending thoracic aorta will soon be renamed the abdominal aorta. The splenic vein and its tributaries are prominent as is a segment of the splenic artery near the hilus of the spleen. As the plane descends note that the splenic vein follows the course of the pancreas to the right side of the abdomen. Observe at this level the close proximity of the portal vein, hepatic artery, and common bile duct to the 1st part of the duodenum. The inferior vena cava (IVC) lies in its deep fissure on the posterior side of the liver and against the right crus of the diaphragm.

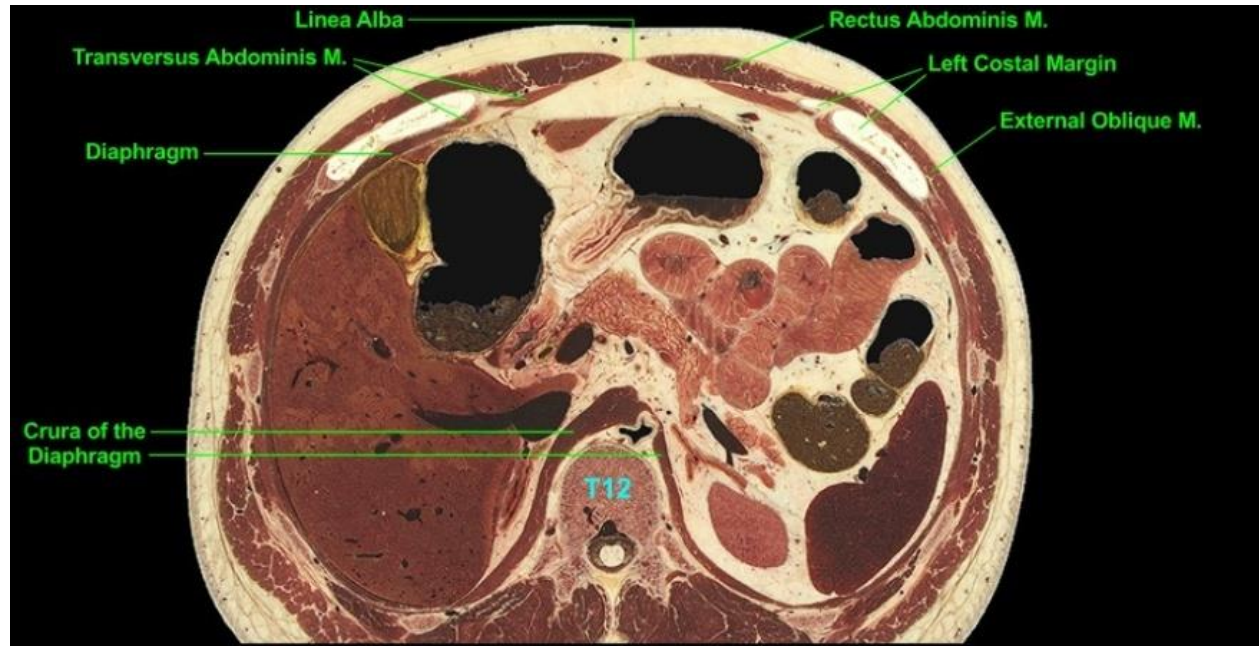


- Figura 24. Other organs of the level 5.
- OTHER:
- The left lobe of the liver is very small as the plane lies near its inferior extreme. Note the common bile duct passing posterior to the 1st part of the duodenum in close proximity to the portal vein. The body of the pancreas lies primarily on the left side of the abdominal cavity immediately in front of the posterior abdominal wall while the tail of the pancreas projects toward the hilus of the spleen. The spleen lies adjacent to the diaphragm, on the left side and posterior to the midaxillary line. Near the crura of the diaphragm note the thin wedges of tissue surrounded by fat; these are the superior most aspects of the adrenal glands.

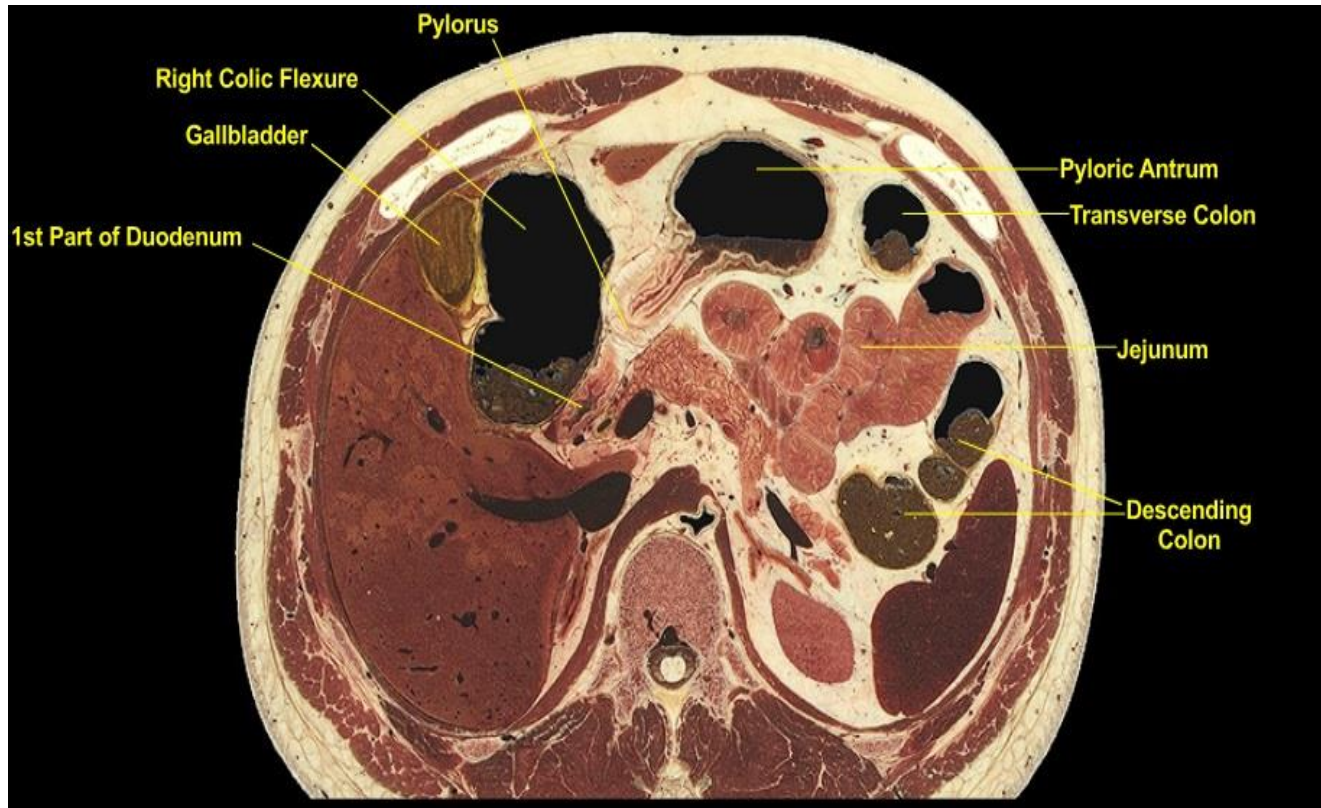


- Figura 25. CT view of the level 5.
- CT scan at the level of continuity of stomach and duodenum as seen in the cadaveric cross-section. However in the CT the continuity of stomach and duodenum lies medial to the ascending colon while in the the cadaveric section the continuity lies medial to the right colic flexure. Furthermore the major vascular profiles in the CT actually match better with cadaveric Level 7 (continuity of the splenic vein with the portal vein) and cadaveric Level 8 (origin of the superior mesenteric artery from the abdominal aorta). These anatomical variations between the CT and the cadaveric cross-sectional levels reflect normal human variation and must be appreciated in a study of cross-sectional anatomy. Also note the "flattened" profile of the inferior vena cava in the CT. The shape of the IVC in a living subject is influenced by the stage of respiration and cardiac cycle and is not always a wide oval image as often seen in cadavers.

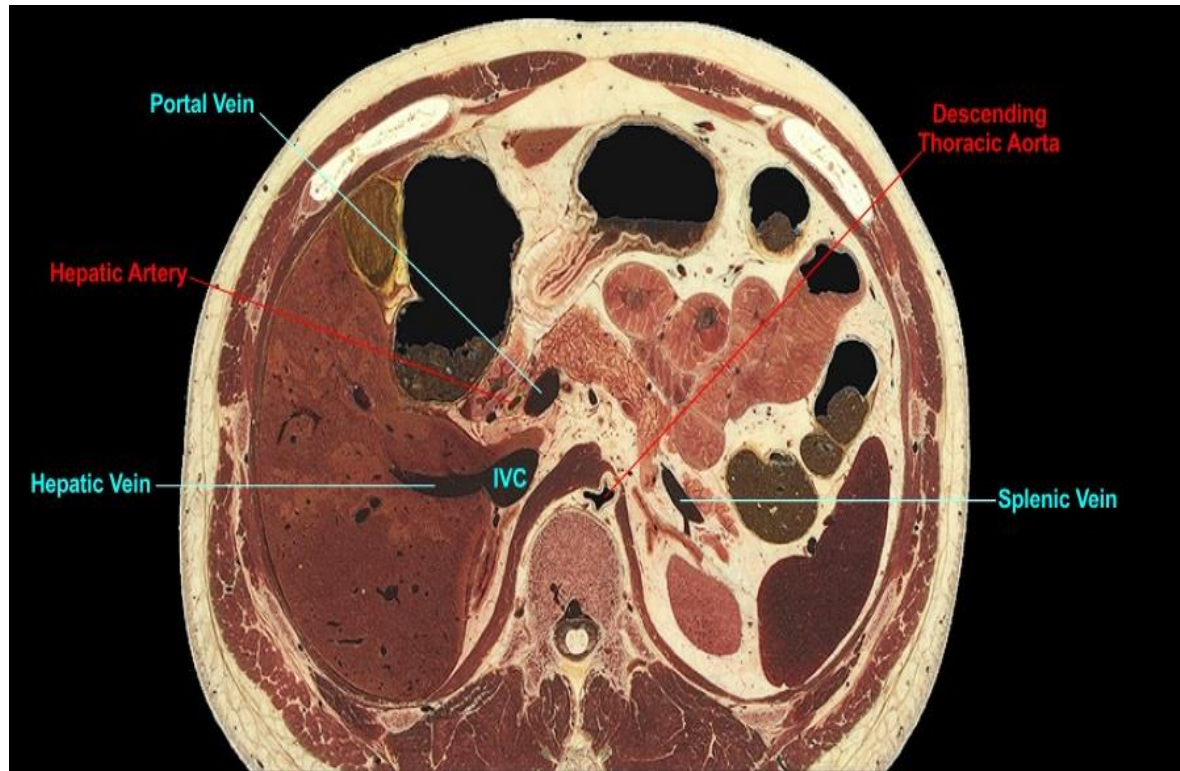
Level 6 (T12)



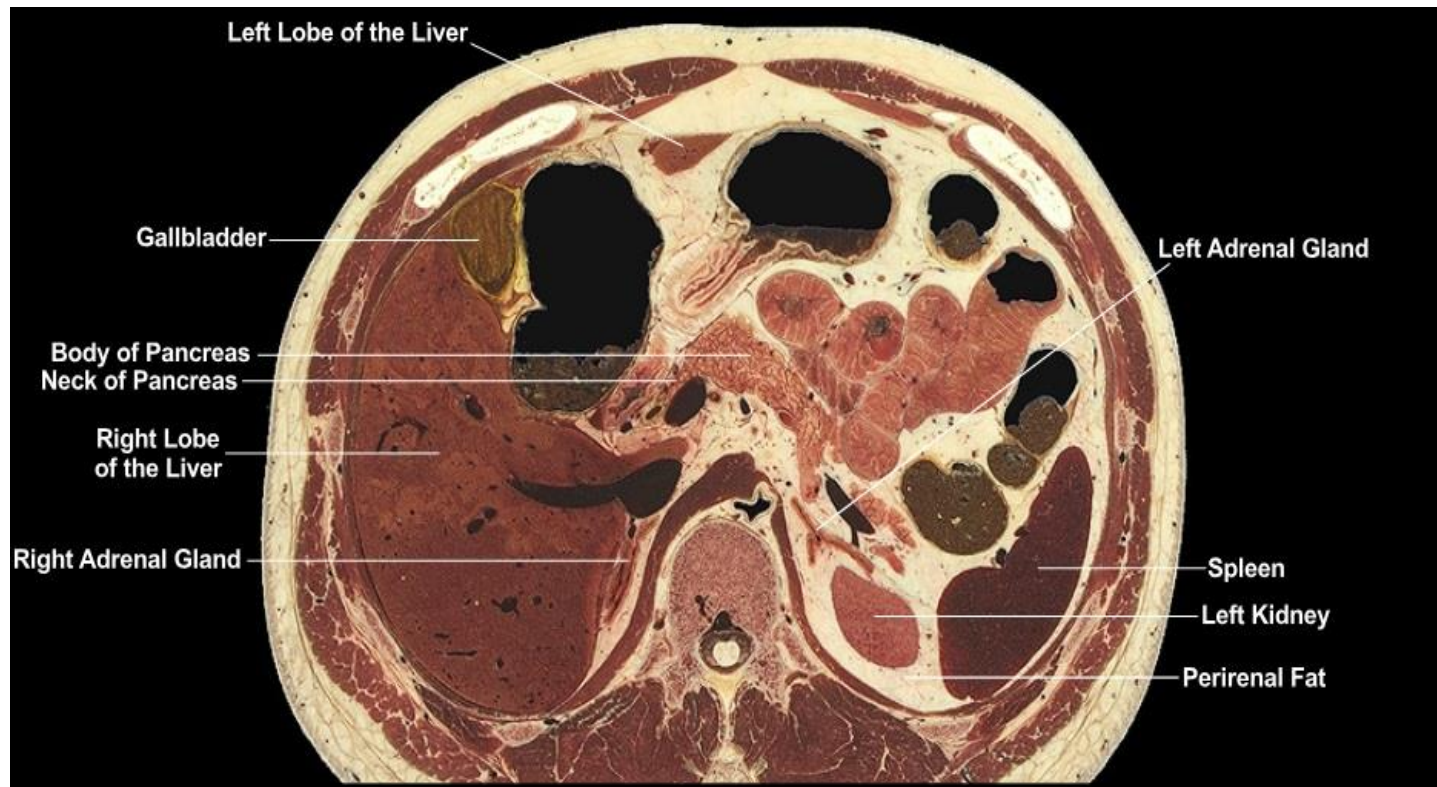
- Figura 26. Musculoskeletal aspect of the level 6.
- MUSCULOSKELETAL:
- Anteriorly the broad bars of costal cartilage are part of the costal margins whose medial edges will progressively move more laterally as the plane descends. We observe the separation of the two rectus abdominis muscles by the linea alba, a midline fusion of aponeuroses from the lateral abdominal wall muscles. The superior ends of the transversus abdominis (transverse abdominal) muscles are present taking origin from the deep surface of the thoracic wall; as the plane descends do not confuse these muscles with the anterior extreme of the diaphragm. The external oblique muscles lie on the superficial side of the thoracic wall and lateral to the rectus abdominis muscles. The crura of the diaphragm, which ascend from origins at lumbar levels, are prominent around the descending thoracic aorta.



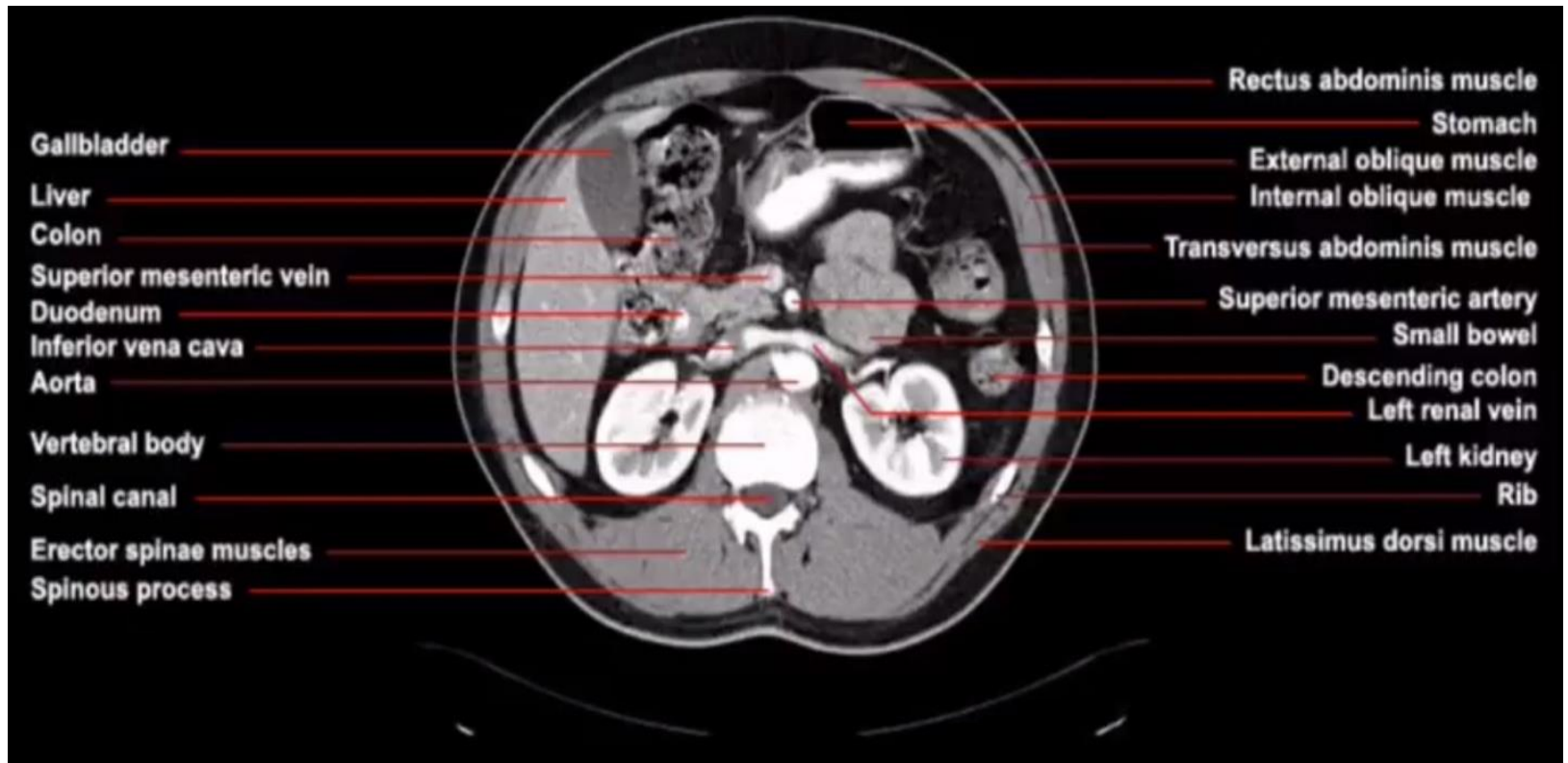
- Figura 27. Gastrointestinal aspect of the level 6.
- GASTROINTESTINAL:
- We observe the continuity of the pyloric antrum, pylorus, and 1st part of duodenum and note the close proximity of the duodenum to the visceral surface of the liver. The right colic (hepatic) flexure, which touches the visceral surface of the liver, will separate more inferiorly into transverse and ascending colons. We note separate profiles of transverse and descending colon, the left colic flexure residing more superiorly. The descending colon lies posteriorly near the spleen while the transverse colon is positioned more anteriorly. The coils of small intestine are those of jejunum (remember that in general jejunum lies in the upper intestinal region of the abdominal cavity while ileum resides more inferiorly).



- Figura 28. Vascular aspect of the level 6.
- VASCULAR:
- The splenic vein runs parallel to the pancreas as it projects medially toward its ultimate union with the portal vein. Observe the portal vein posterior to the pancreas, whose neck is defined as that portion of pancreas anterior to the portal vein. Close inspection reveals the hepatic artery immediately to the left of the portal vein and posterior to the pancreas; the hepatic artery is ascending from the celiac trunk (not present at this level) to reach the porta hepatis. The descending thoracic aorta lies slightly to the left of midline adjacent to the vertebral column and is surrounded anterolaterally by crura. The inferior vena cava (IVC) lies to the right of midline and is separated from the vertebral column by the intervening right crus of the diaphragm.

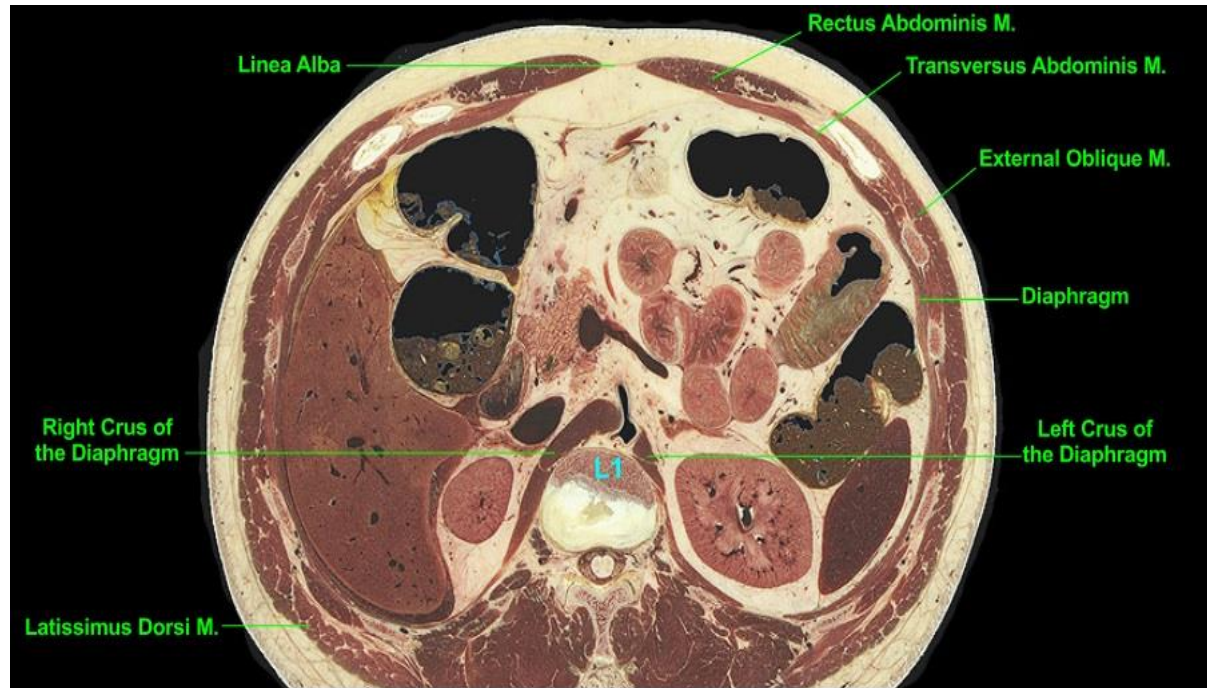

- Figura 29. Other organs of the level 6.
- OTHER:
- The right lobe of the liver occupies the right lateral and posterior portions of the abdominal cavity; it will progressively decrease in size as the plane descends. The superior aspect of the left kidney and the left adrenal gland lie near the posterior abdominal wall in the left paravertebral gutter. Note the large mass of adipose tissue, called perirenal or perinephric fat, surrounding the kidney and intervening between it and the adjacent adrenal gland. Due to the right lobe of the liver, the right kidney lies at a more inferior level than the left kidney and is not present at this level. However note the right adrenal gland between the liver and diaphragm. Observe the pancreas, whose neck lies anterior to the portal vein and whose body projects along the posterior abdominal wall toward the spleen.

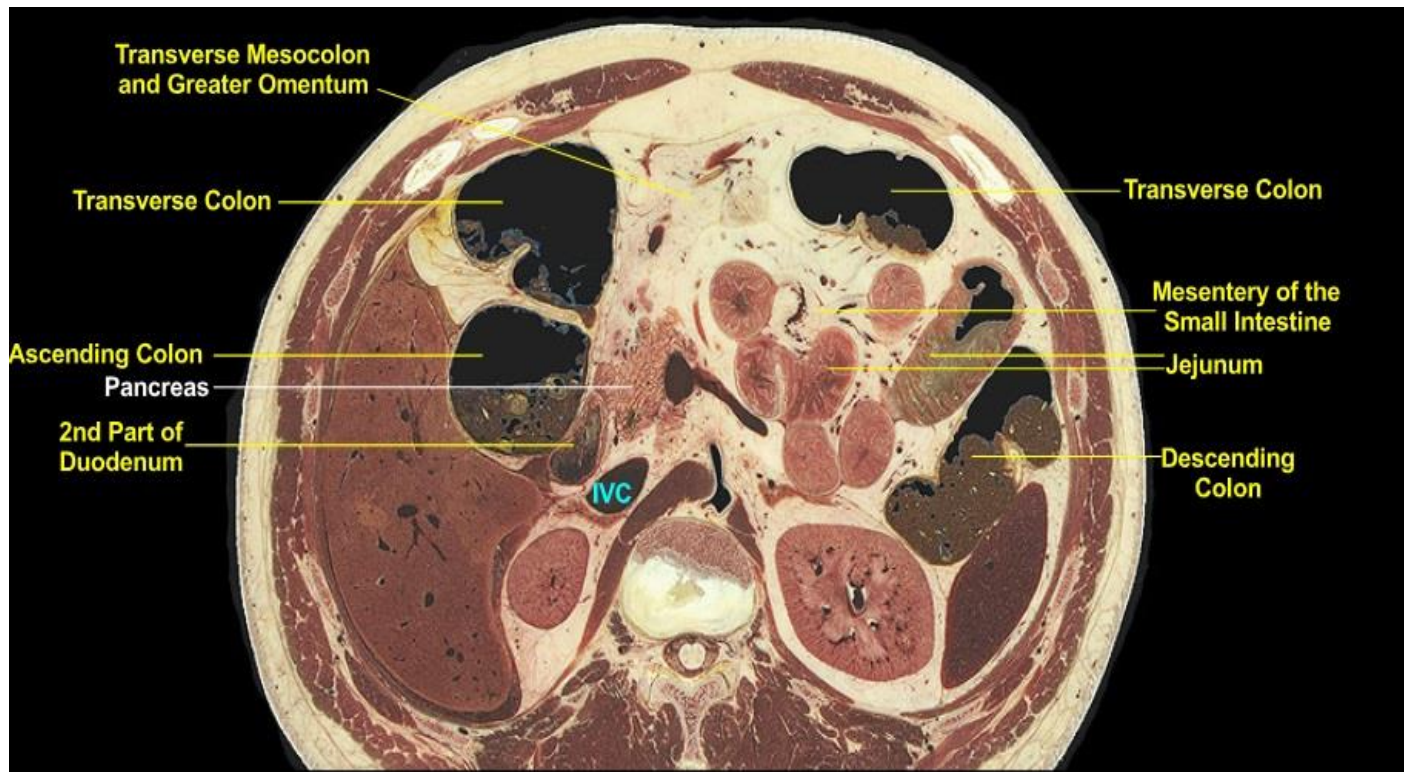


- Figura 30. CT view at the level 6.
- CT scan at the level of the origin of the celiac artery from the abdominal aorta. The patient was given both oral and intravenous contrast medium. Some anatomical features resemble those of the cadaveric section (e.g. origin of the celiac artery, positions and sizes of the kidneys and spleen) while others (e.g. size of the liver and presence of the stomach) are different than observed in the cadaveric specimen; this reflects normal human variation and needs to be appreciated when studying cross- sectional anatomy. The celiac artery divides into three branches of which the two larger, i.e. the common hepatic and splenic arteries, are evident in the CT scan.

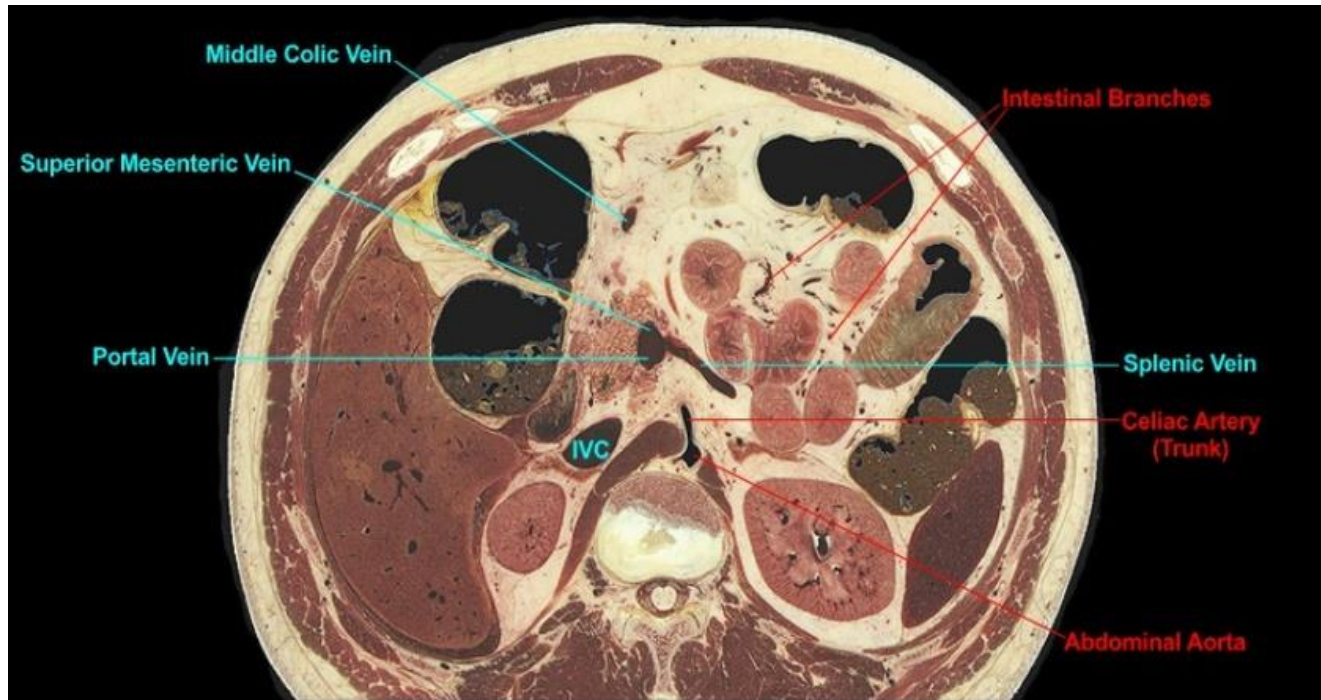
Level 7 (L1)



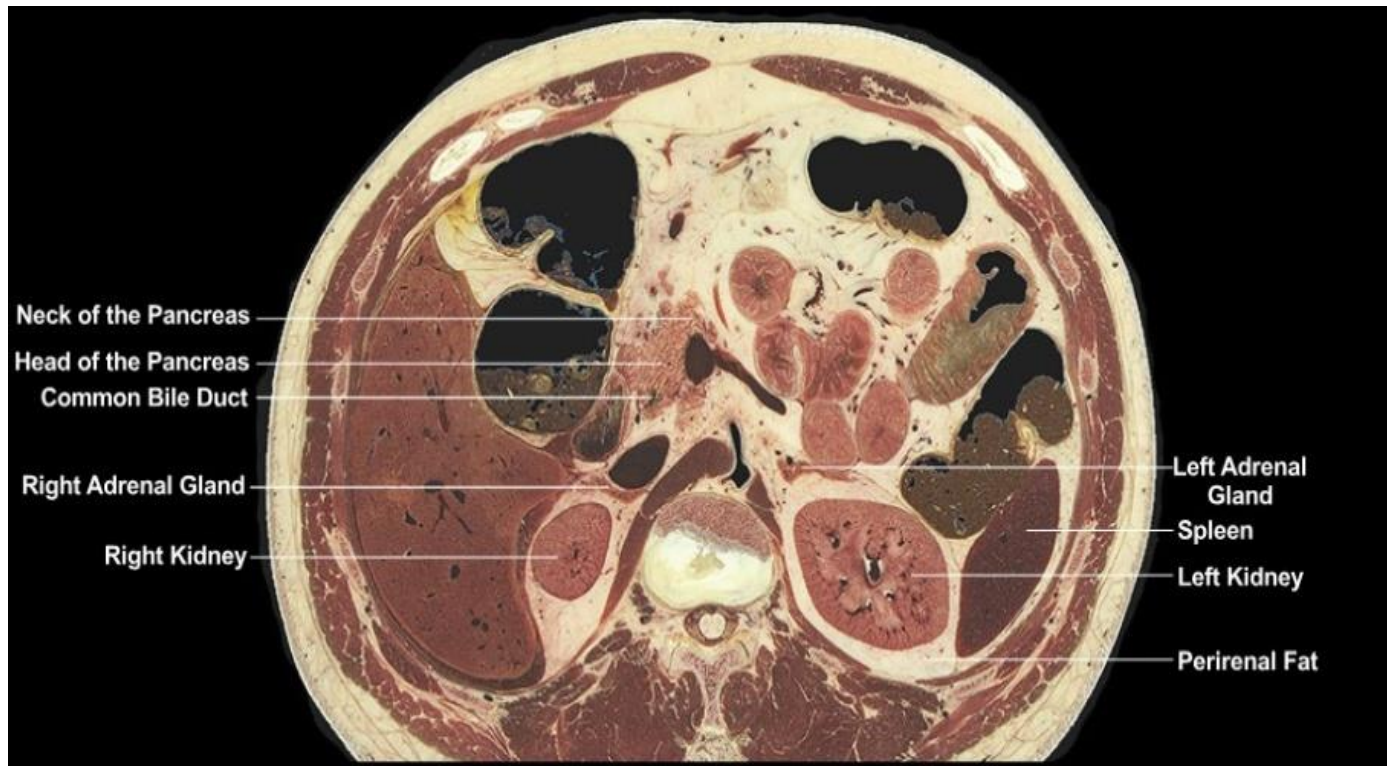- Figura 31. Musculoskeletal aspect of the level 7.
- MUSCULOSKELETAL:
- Level of the T12-L1 intervertebral disc. While most of the body cavity at this level is abdomen, the thoracic walls (ribs and intercostal muscles) remain; only the anterior aspect of the body wall, between the costal margins, is comprised solely of abdominal musculature. The rectus abdominis muscles comprise the anterior abdominal wall while the external oblique and transversus abdominis (transverse abdominal) muscles lie more laterally. We note that the latter two muscles take origin from opposite sides of the costal cartilages and ribs. Observe the prominent crura of the diaphragm that originate more inferiorly from lumbar vertebrae.



- Figura 32. Gastrointestinal aspect of the level 7.
- GASTROINTESTINAL:
- The plane lies inferior to the right colic (hepatic) flexure; thus transverse and ascending colon are viewed separately. We note the 2nd part (vertical part) of the duodenum on the right posterior abdominal wall; it is "surrounded" by major structures, including the head of the pancreas, the ascending colon, liver, and inferior vena cava (IVC). The transverse colon typically has a U-shape between the two colic flexures; as the plane descends the two profiles of transverse colon (opposite limbs of the U) will unite. The adipose-rich mass between the two profiles of transverse colon includes the greater omentum and transverse mesocolon; the demarcation between the two is not evident. The coils of small intestine are jejunum in the adipose-rich mesentery of the small intestine.

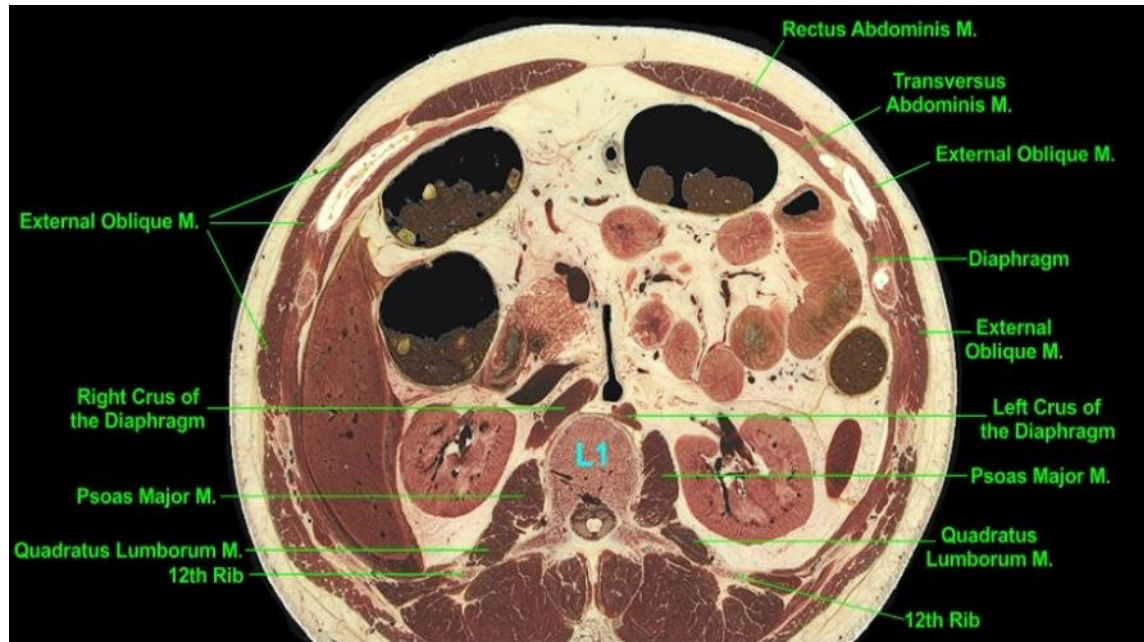


- Figura 33. Vascular aspect of the level 7.
- VASCULAR:
- At the T12-L1 intervertebral disc the descending thoracic aorta is renamed the abdominal aorta. Projecting anteriorly from it note the celiac artery (trunk), the first single midline branch of the abdominal aorta. Observe the splenic vein joining the superior mesenteric vein posterior to the neck of the pancreas to form the portal vein. Intestinal branches of the superior mesenteric artery (itself not evident) and tributaries of the superior mesenteric vein are evident within the mesentery of the small intestine. Part of the adipose- rich mass between the two profiles of the transverse colon is the transverse mesocolon, which contains the middle colic vein. Note the inferior vena cava (IVC) adjacent to the right crus of the diaphragm and no longer in contact with the liver as seen at more superior levels.

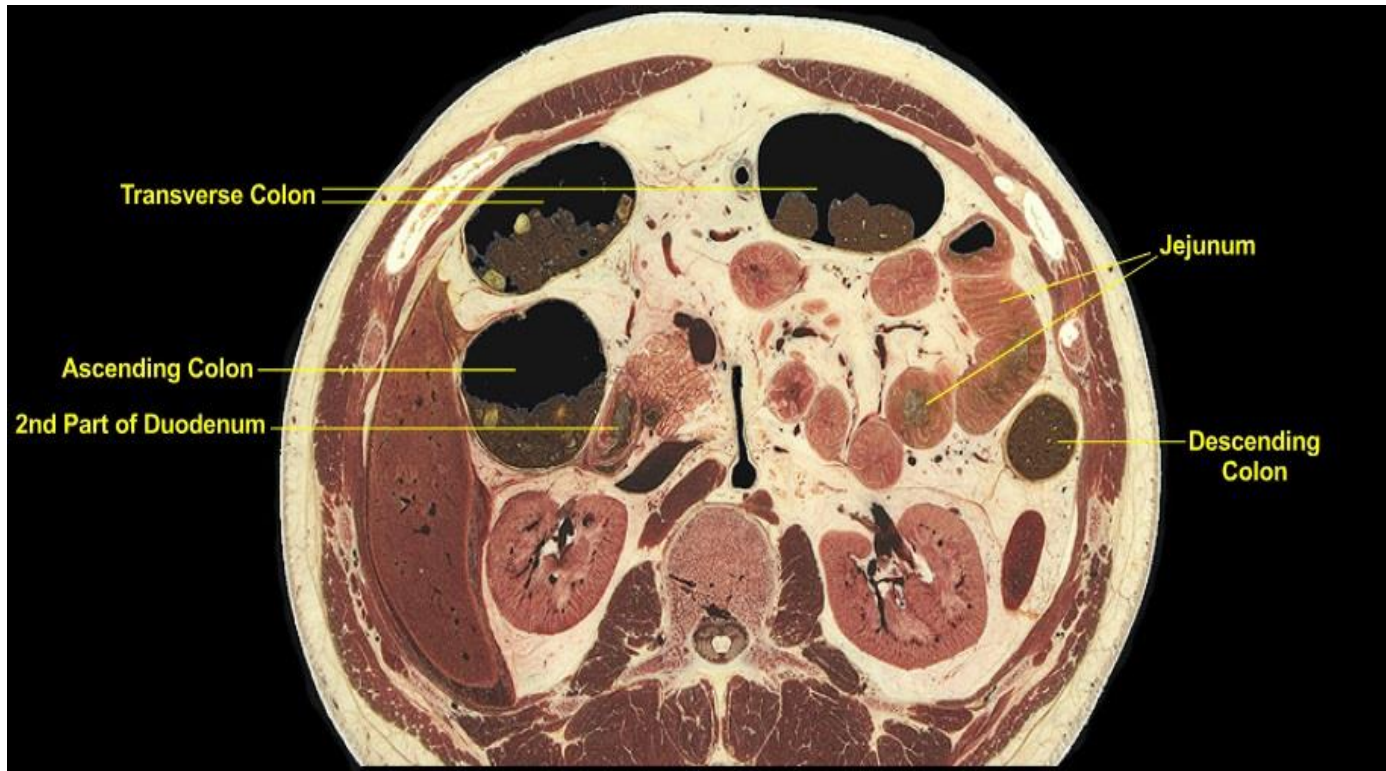

- Figura 34. Other organs of the level 7.
- OTHER:
- Observe the head of the pancreas immediately to the left of the 2nd part of the duodenum and look closely for the common bile duct on the posterior side of the head of the pancreas. The neck of the pancreas is defined as that portion of the pancreas anterior to the formation of the portal vein from the splenic and superior mesenteric veins. Note the two kidneys and neighboring adrenal glands lying within the paravertebral gutters. Observe the perirenal fat surrounding the kidneys. The spleen occupies its characteristic left postero-lateral position in the abdominal cavity, sectioned here near its inferior region.

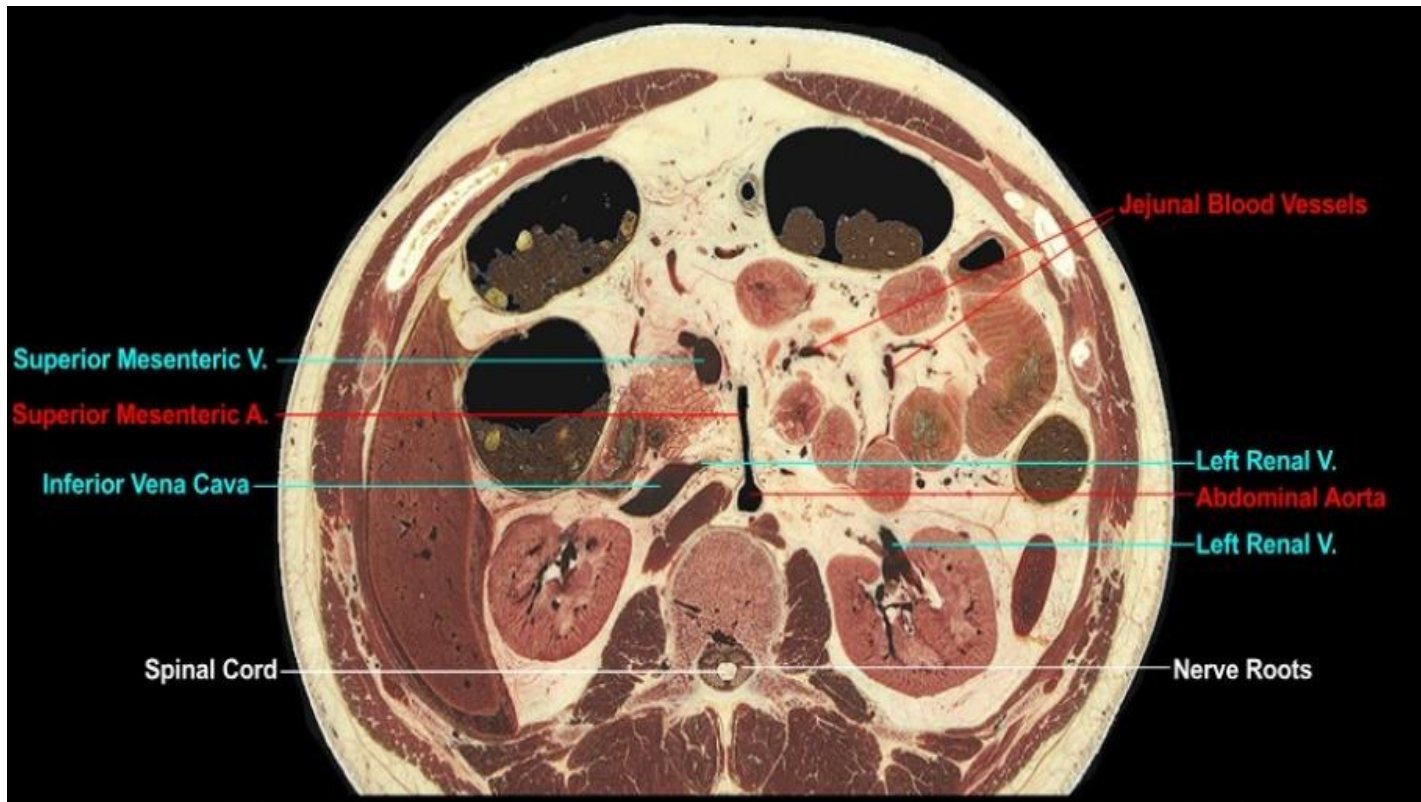Level 8 (L1)



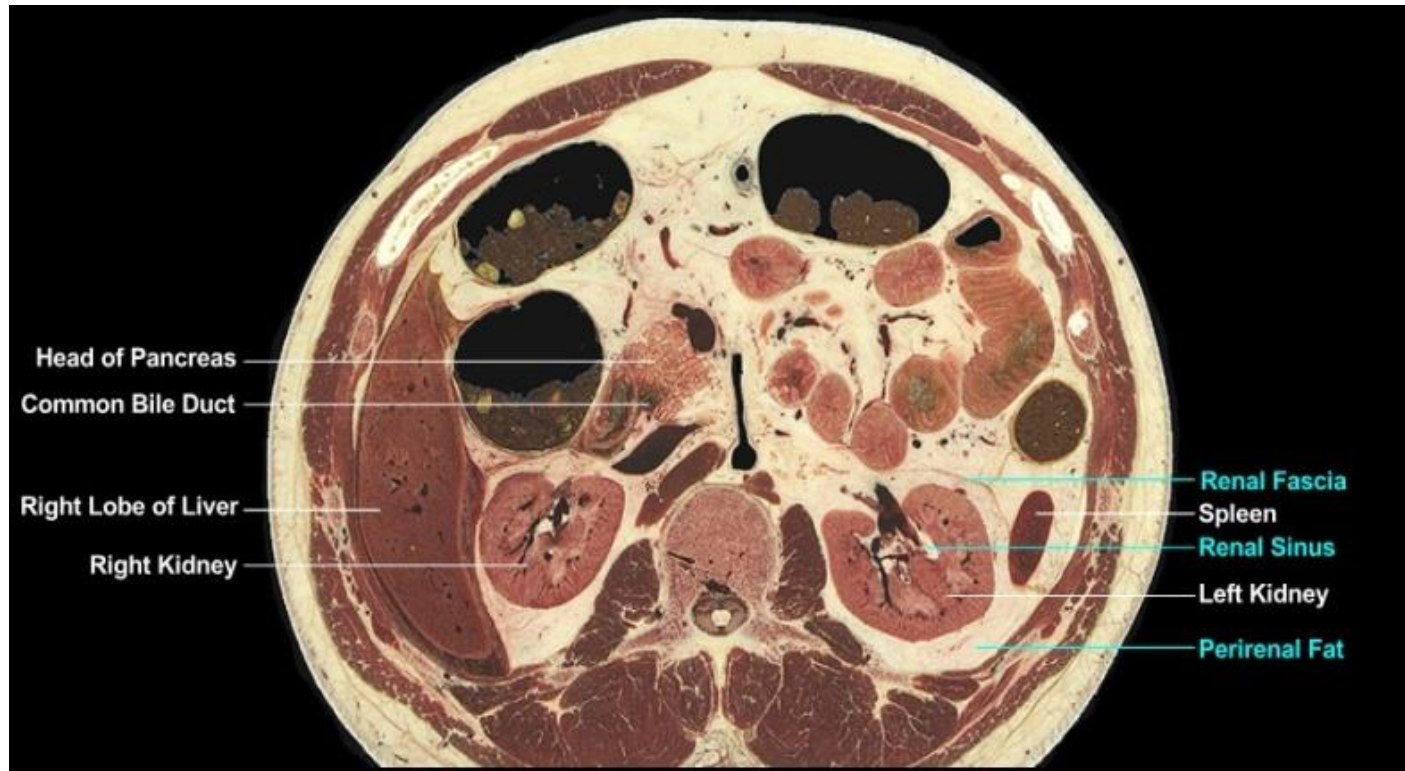
- Figura 36. Musculoskeletal aspect of the level 8.
- MUSCULOSKELETAL:
- Level of the L1 vertebra. We observe the psoas major muscles (which take origin from lumbar vertebrae) on either side of the vertebral column and the quadratus lumborum muscles (which take origin from the 12th ribs and the transverse processes of lumbar vertebra) slightly behind and lateral to the psoas muscles. The psoas major and quadratus lumborum muscles are the principle muscles of the posterior abdominal wall from this level to the false pelvis. Note the rectus abdominis, external oblique, and transversus abdominis (transverse abdominal) muscles contributing to the anterolateral abdominal walls. The lowermost ribs, their intercostal muscles, and the diaphragm still border the abdominal cavity at this level.



- Figura 37. Gastrointestinal aspect of the level 8.
- GASTROINTESTINAL:
- The positions of the colonic profiles, i.e. descending colon on the left lateral wall anterior to the spleen, ascending colon on the right side abutting the liver and duodenum, and two profiles of the transverse colon (that are continuous at a more inferior level) immediately deep to the anterior abdominal wall and costal margins. The caliber of the descending colon is typically considerably smaller than that of the ascending colon, as evident in this section. The duodenum is sectioned through its 2nd part (the vertical or descending segment) with the head of the pancreas to its immediate left. The coils of small intestine are those of jejunum embedded in the adipose-rich mesentery of the small intestine.

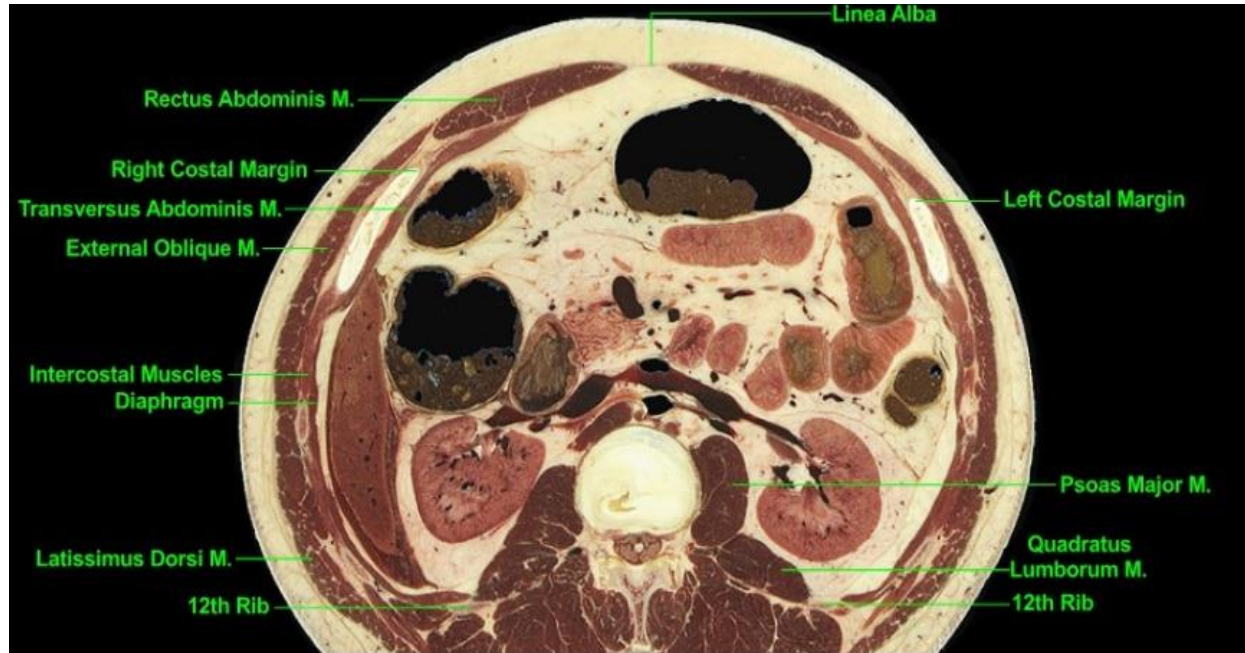


- Figura 38. Vascular aspect of the level 8.
- VASCULAR:
- Of particular note is the superior mesenteric artery (SMA) projecting anteriorly from the abdominal aorta into the mesentery of the small intestine. The superior mesenteric vein lies nearby and both vessels lie close to the pancreas. Profiles of jejunal blood vessels lie in the mesentery of the small intestine. The inferior vena cava (IVC) lies to the right of midline and anterior to the right crus of the diaphragm; its elongated shape in part reflects its union with the renal veins. The left renal vein is seen at its origin in the hilus of the left kidney and a small profile of it is uniting with the IVC. We note that the spinal cord, which ends at the lower margin of L2, is smaller than viewed at higher levels; here spinal nerve roots surround the cord as they descend to lower levels of the vertebral canal.

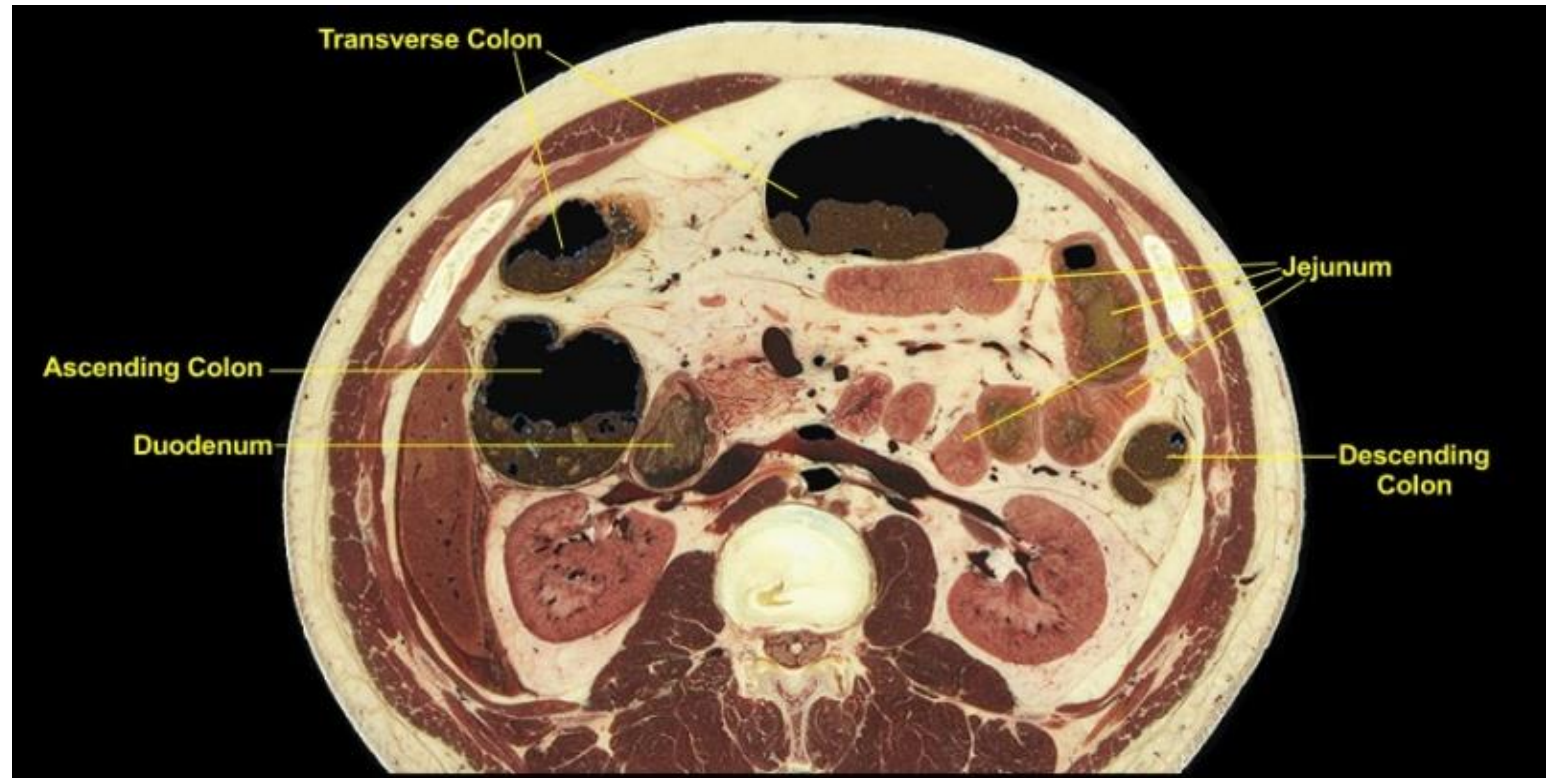


- Figura 39. Other organs of the level 8.
-
- OTHER:
- The right lobe of the liver and the spleen are near their inferior limits; small profiles that still lie deep to the thoracic cage. The kidneys, bordered medially by the psoas major and quadratus lumborum muscles and laterally by either spleen or liver, lie in the paravertebral gutters. Close examination reveals the renal fascia that surrounds a kidney, its perirenal (perinephric) fat, and its neighboring adrenal gland (the latter not present at this level). The kidneys are retroperitoneal organs; a parietal layer of peritoneum lies immediately anterior to the anterior side of the renal fascia. Note the renal sinuses, i.e. the fat-filled cavities within the kidneys where larger blood vessels branch and the collecting ducts coalesce into the ureters.

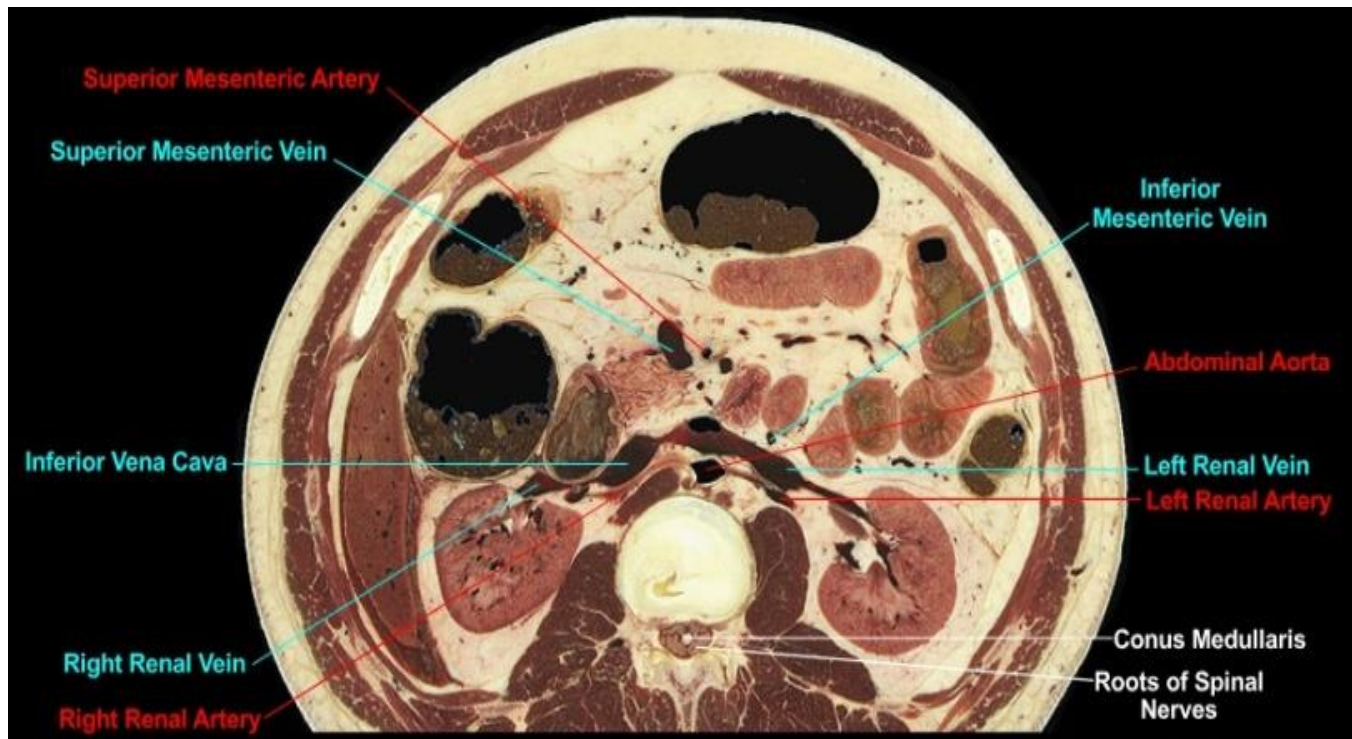
Level 9 (L2)



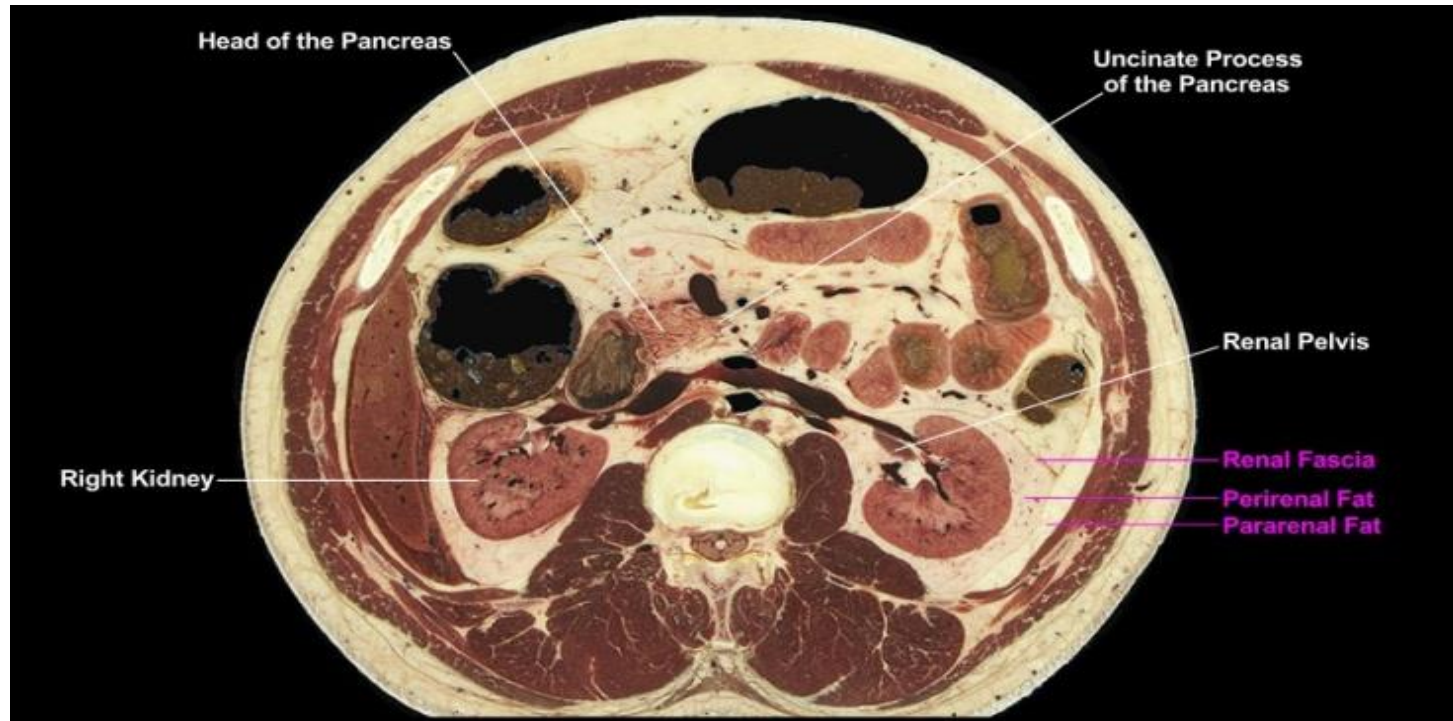
- Figura 41. Musculoskeletal aspect of the level 9.
- MUSCULOSKELETAL:
- Level of the L1-L2 intervertebral disc. The lower limit of the thoracic cage is evident by the presence of the 12th ribs and the large distance between the two costal margins. The positions of the psoas major and quadratus lumborum muscles of the posterior abdominal wall reflect their principle origins (psoas major mostly from lumbar vertebral bodies, quadratus lumborum from the 12th ribs). The musculature of the anterolateral abdominal wall is prominent. Note the very broad extent of the external oblique muscles and be careful to demarcate them from the latissimus dorsi muscles of the upper limbs that lie more posteriorly. Observe the thoracic wall intervening between the external oblique and the transversus abdominis (transverse abdominal) muscles, i.e. external oblique taking origin from the superficial side of the thoracic wall, transverse abdominal from the deep side.



- Figura 42. Gastrointestinal aspect of the level 9.
- GASTROINTESTINAL:
- We observe the various profiles of colon, noting their positions on the periphery of the abdominal cavity. The adipose tissue between the two profiles of transverse colon includes the greater omentum (which extends inferiorly from the stomach to the transverse colon) and the transverse mesocolon (which extends from the transverse colon to the posterior abdominal wall). The 2nd part (vertical segment) of the duodenum lies immediately to the right of the head of the pancreas and directly anterior to renal blood vessels of the right kidney. We note as well the close proximity of the duodenum to the ascending colon. The coils of small intestine are jejunum in the adipose-rich mesentery of the small intestine that contains jejunal branches of the superior mesenteric blood vessels.



- Figura 43. Vascular aspect of the level 9.
- VASCULAR:
- The renal vasculature typically originates at the level of the L1-L2 intervertebral disc. The renal arteries arise from the aorta and project laterally, anterior to the crura of the diaphragm and psoas major muscles, toward the hila of the kidneys. We note that 1) the renal veins lie anterior to the renal arteries, 2) the left renal vein is significantly longer than the right renal vein since it must join the IVC to the right of midline, and 3) the left renal vein passes anterior to the aorta. The inferior mesenteric vein is ascending the left side of the posterior abdominal wall en route to the splenic vein at a higher level; note that it ascends anterior to the left renal vein. Observe the small cross-sectional area of the spinal cord (called the conus medullaris at this level) as it approaches its termination at the lower end of the L2 vertebra. The spinal cord is surrounded by spinal nerve roots of the forming cauda equina.



- Figura 44. Other organs of the level 9.
- OTHER:
- A mass of retroperitoneal fat called the pararenal fat lies outside and postero-lateral to the renal fascia. Perirenal fat lies deep to the renal fascia and directly surrounds the kidneys. A segment of the left renal pelvis is prominent as it projects from the left kidney. We note the head of the pancreas and its elongated uncinate process that lies posterior to the superior mesenteric blood vessels.

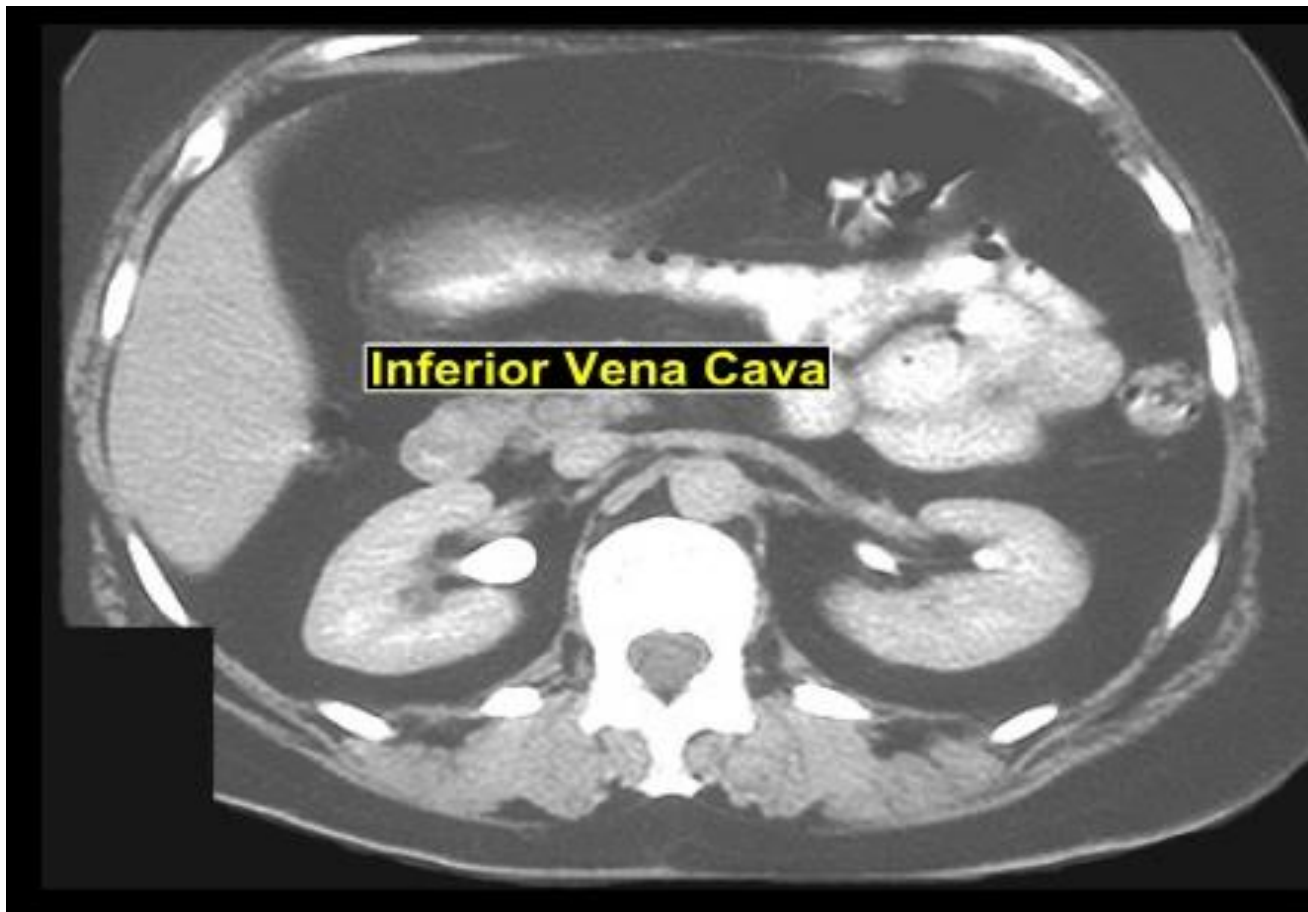
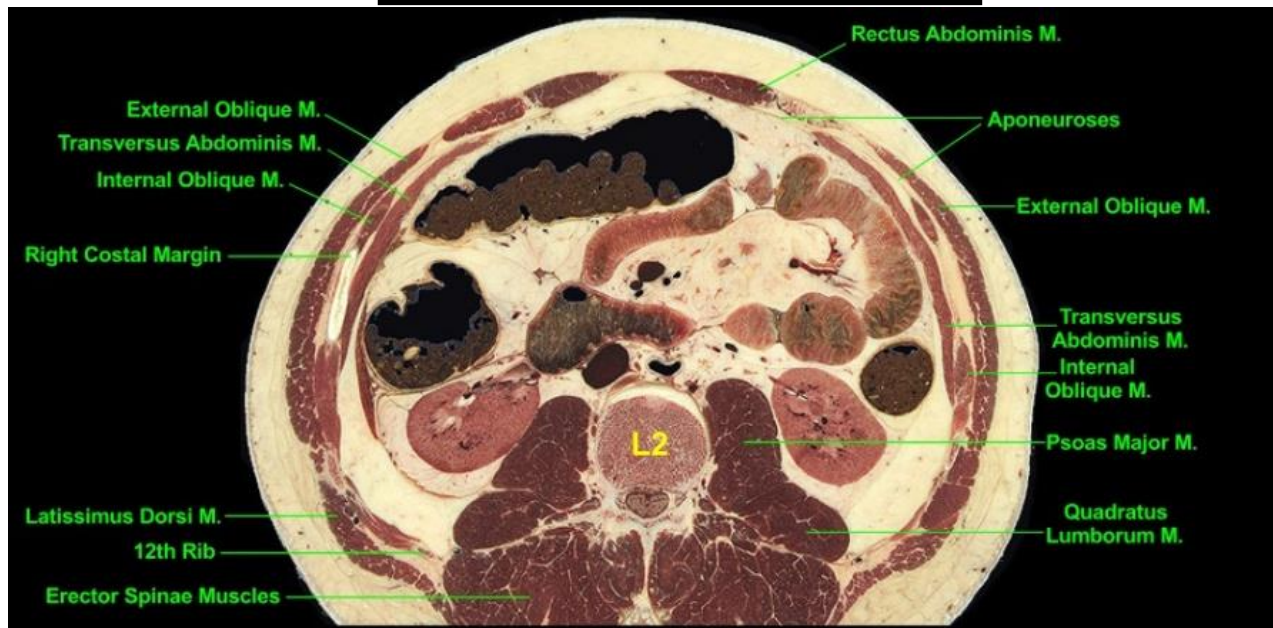


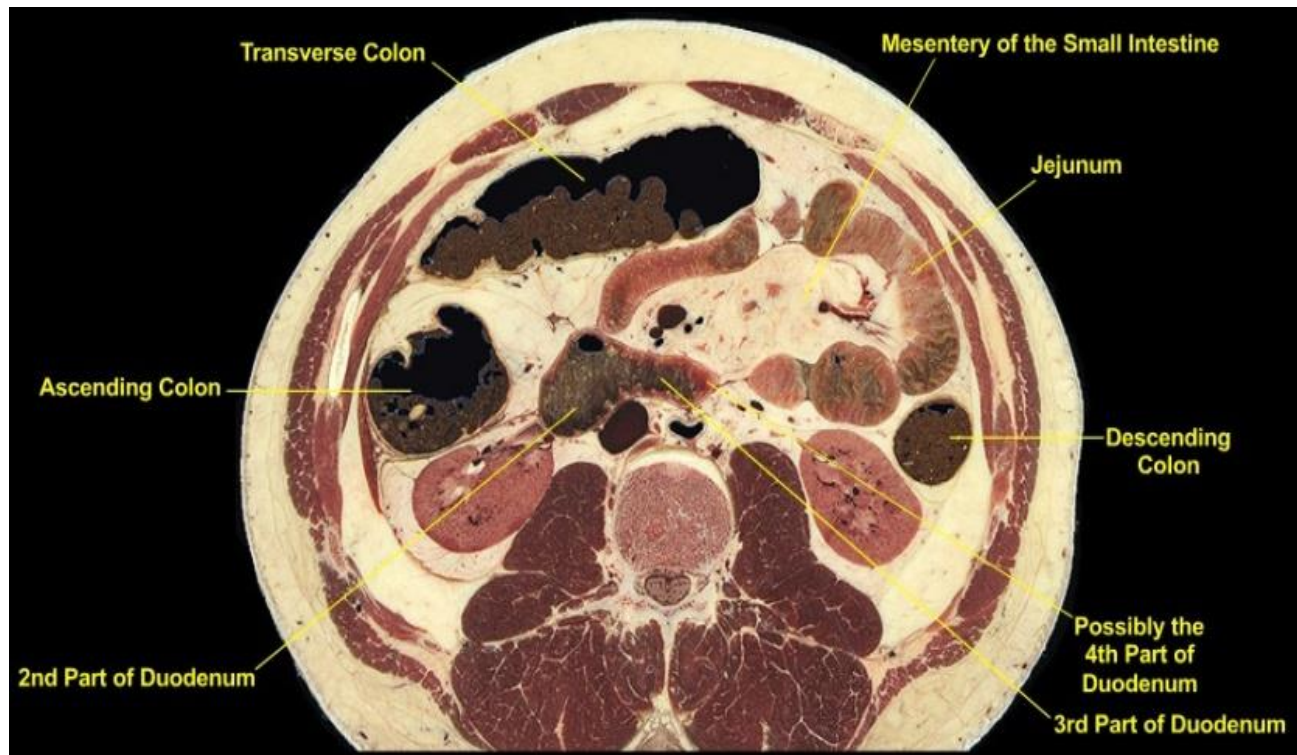
Figura 45. CT view of the level 9.

CT scan at the level of the renal vasculature. The patient had received both oral and intravenous contrast materials, the latter of which accumulated in the kidneys and highlights the renal pelvises. Compare the renal veins and arteries of the CT scan with those seen in the cadaveric cross-section of Level 9. We take particular note of 1) the renal veins anterior to the renal arteries and 2) the left renal vein crossing the midline anterior to the abdominal aorta.

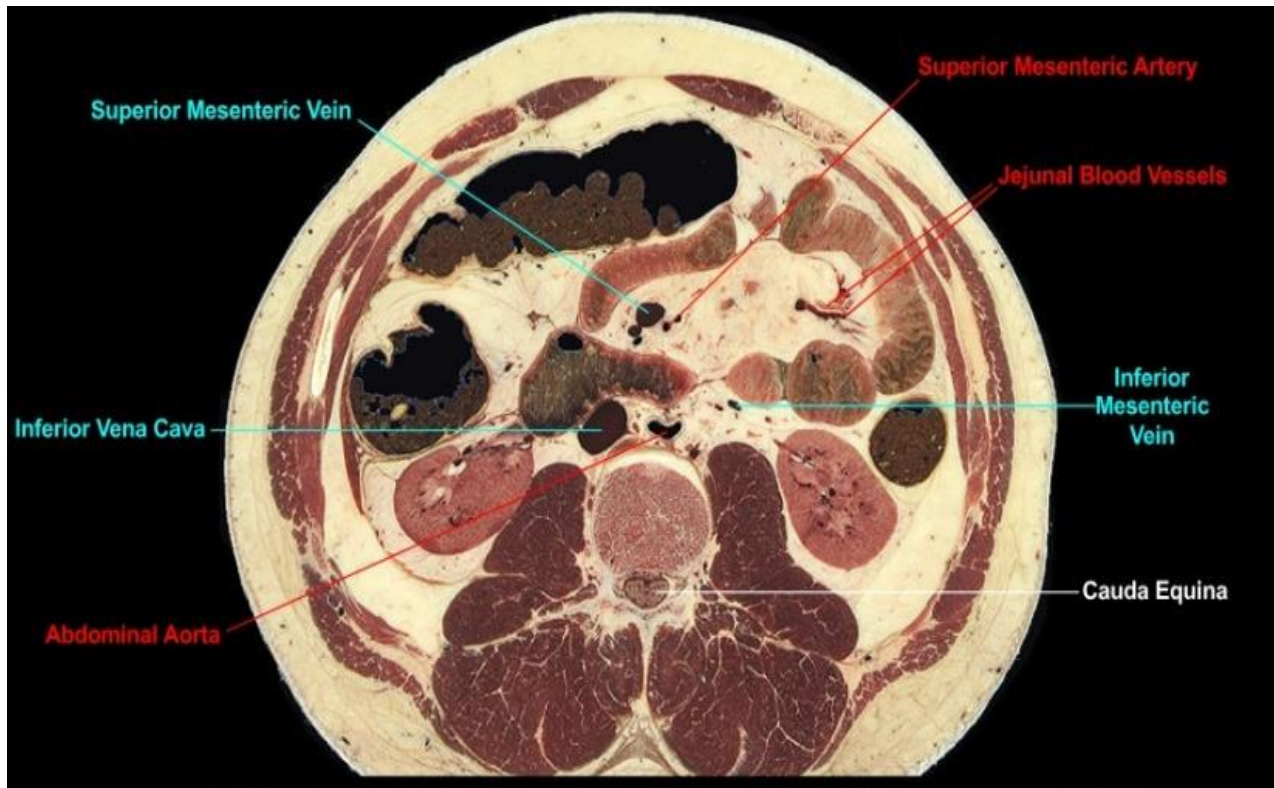
Level 10 (L2)



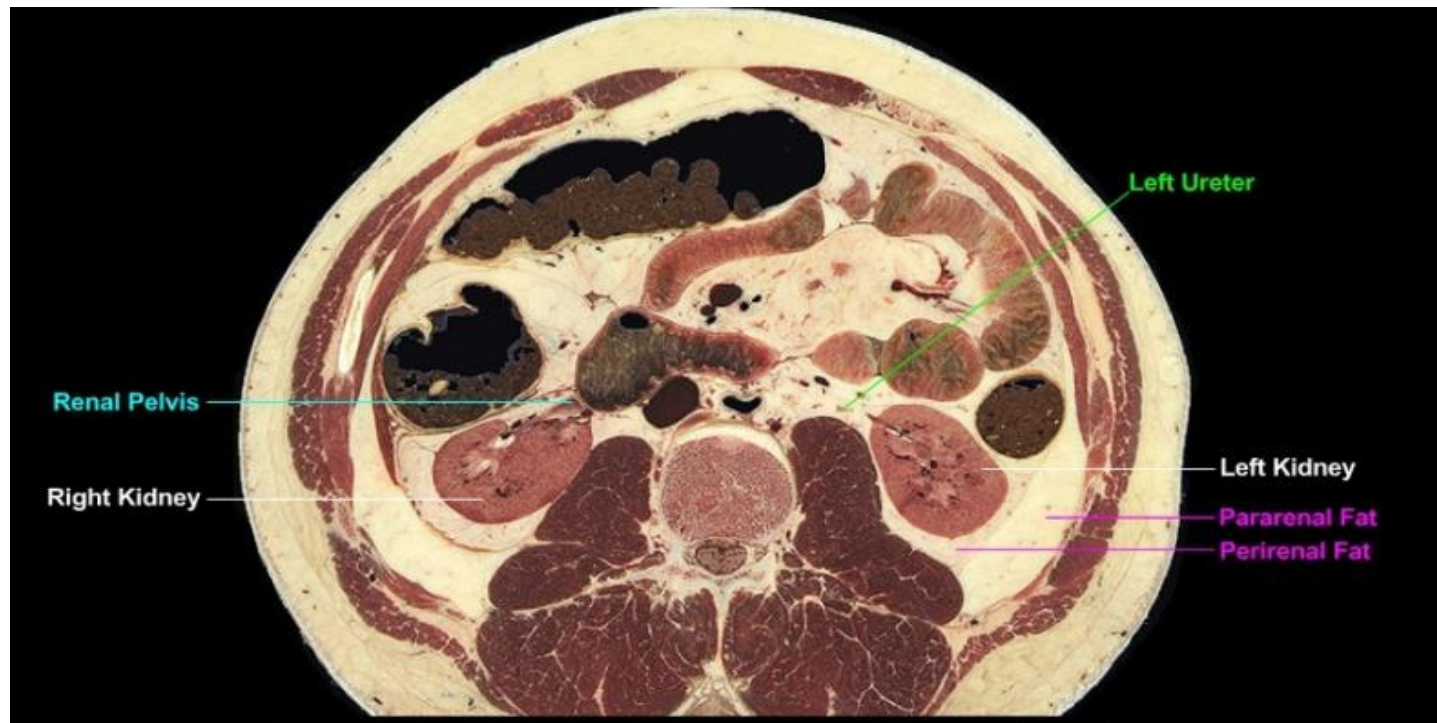
- Figura 46. Musculoskeletal aspect of the level 10.
- MUSCULOSKELETAL:
- Level of the L2 vertebra. The psoas major and quadratus lumborum muscles of the posterior abdominal wall have neighboring origins; the muscles become more distinct from each other as they approach their insertions inferiorly. We note the well developed external oblique and transversus abdominis (transverse abdominal) muscles taking origin from different sides of the rib cage; a small segment of the internal oblique muscle intervenes between them. Close examination reveals some of the aponeuroses (the broad, thin tendons) of these muscles. Only the lowermost components of the thoracic cage remain. The postvertebral muscles of the back (the erector spinae muscles) form a thick column on either side of the spinous processes and posterior to the transverse processes of the vertebral column; these muscles are particularly well developed in the region of the lumbar vertebrae.



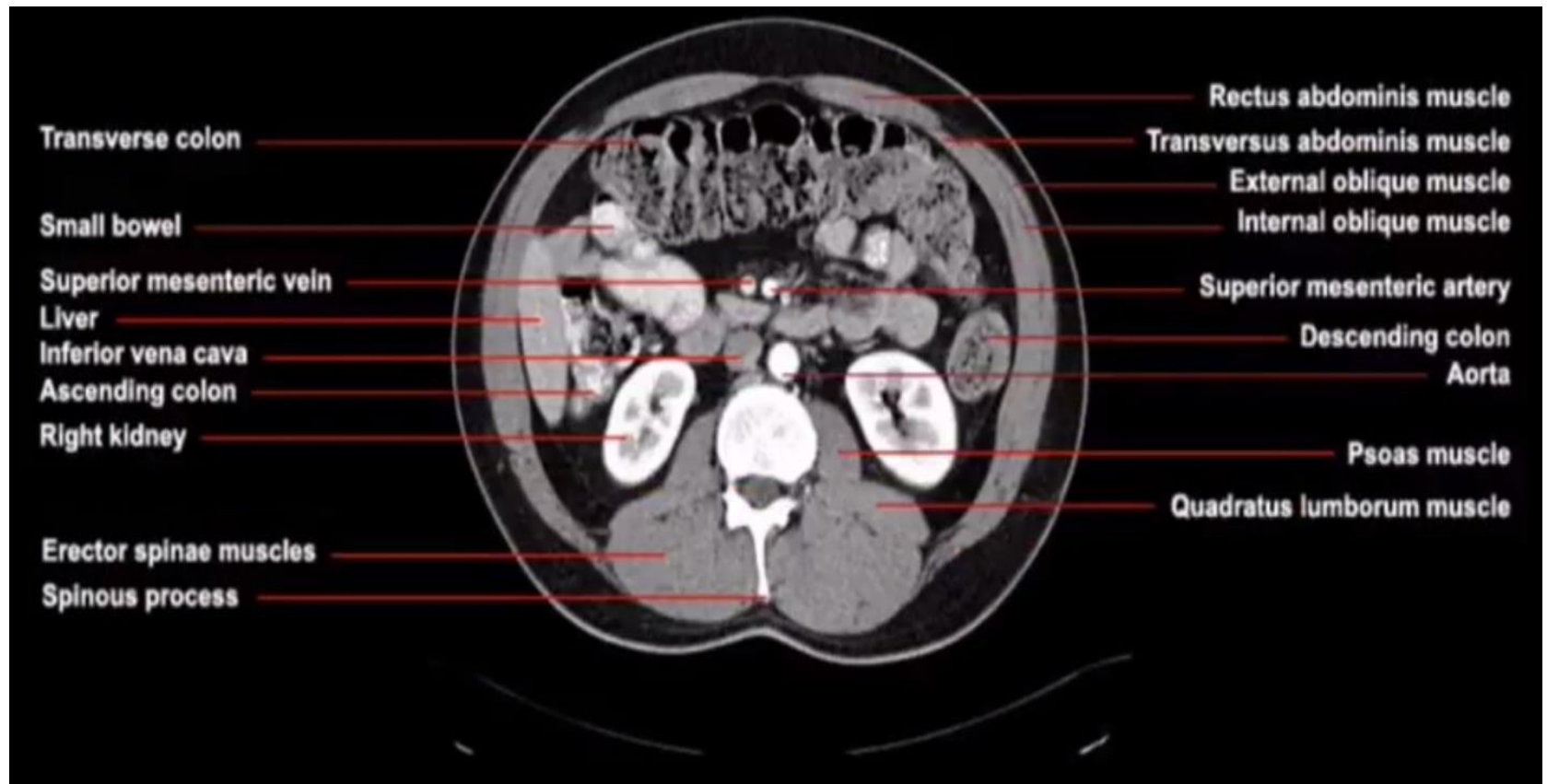
- Figura 47. Gastrointestinal aspect of the level 10.
- GASTROINTESTINAL:
- The two profiles of transverse colon viewed at higher levels are here united as the plane-of section now passes through the bottom of the U-shaped transverse colon. We observe the ascending and descending colons at the lateral extremes of the abdominal cavity and each immediately anterior to a kidney. We note the union of the 2nd (vertical) part of the duodenum with the 3rd (horizontal) part of the duodenum; the 3rd part projects to the left across the midline where it will become continuous with the 4th part of the duodenum (which may in fact be the extreme end of the duodenal profile above). The coils of small intestine are jejunum suspended within the adipose-rich mesentery of the small intestine.



- Figura 48. Vascular aspect of the level 10.
- VASCULAR:
- We observe the superior mesenteric artery and vein within the mesentery of the small intestine. The vein typically lies anterior and to the right of the artery. Profiles of jejunal blood vessels in the mesentery of the small intestine project toward the jejunum. Note the profile of the inferior mesenteric vein on the left posterior abdominal wall as it ascends to join the splenic vein at a higher level. We observe the positions of the inferior vena cava (IVC) and the abdominal aorta relative to the vertebral column.
- We note that no spinal cord exists at this level (lower end of L2) but rather the vertebral canal contains the cauda equina.

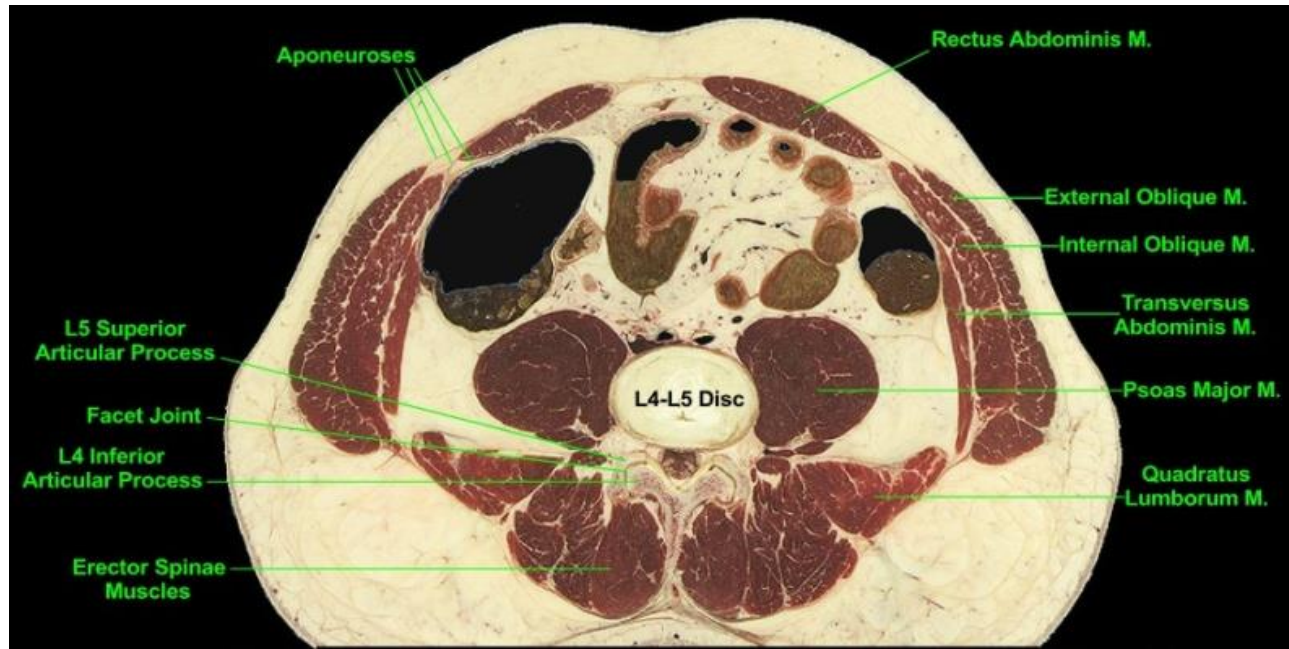


- Figura 49. Other organs of the level 10.
- OTHER:
- We note the positions of the kidneys relative to the musculature of the posterior abdominal wall, i.e. the lower halves of the kidneys (and their surrounding perirenal fat) "rest" obliquely upon the psoas major and quadratus lumborum muscles. In contrast the upper halves of the kidneys rest upon the diaphragm (Levels 6 and 7). The plane passes inferior to the hila of the kidneys. On the right side of the body a portion of the renal pelvis (the proximal end of the ureter) is visible while on the left the plane-of-section passes through a segment of the left ureter. The ureters descend the posterior abdominal wall embedded among the adipose tissue that lies anterior to the psoas major muscles.

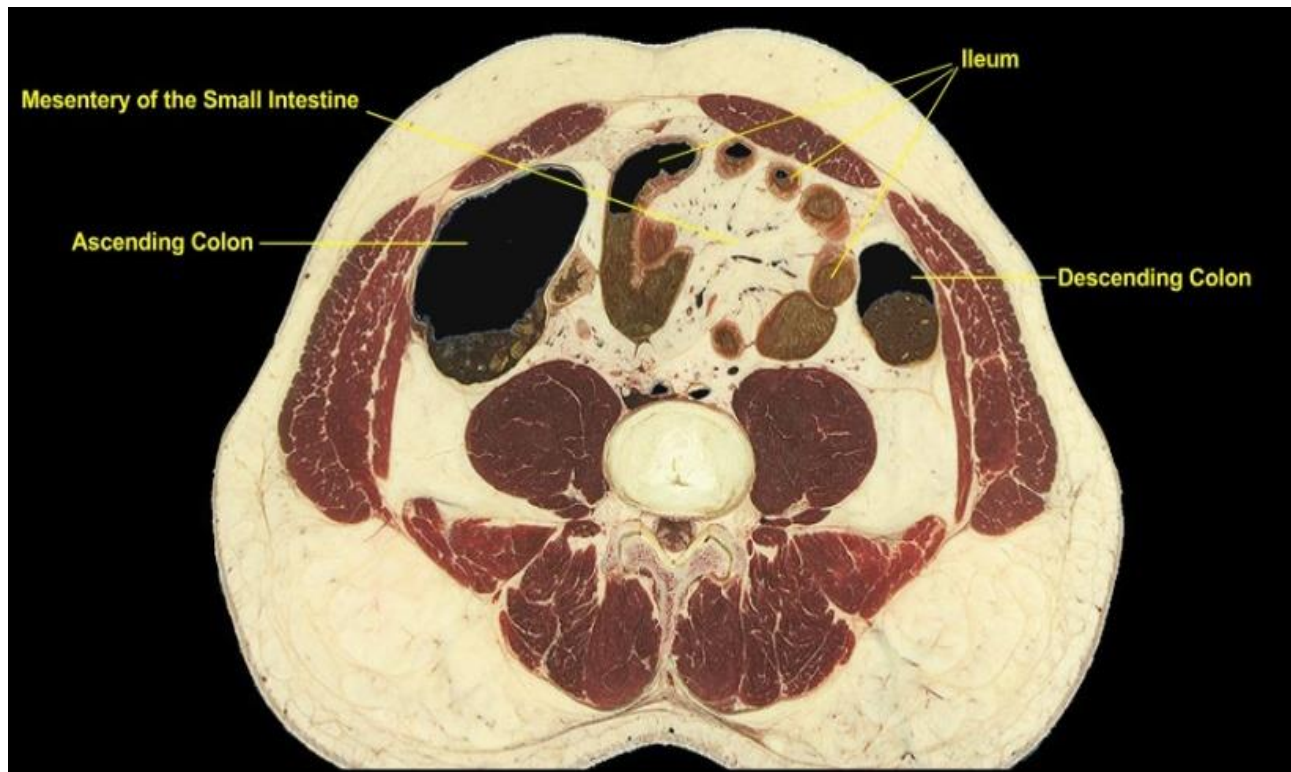


- Figura 50. CT view of the level 10.

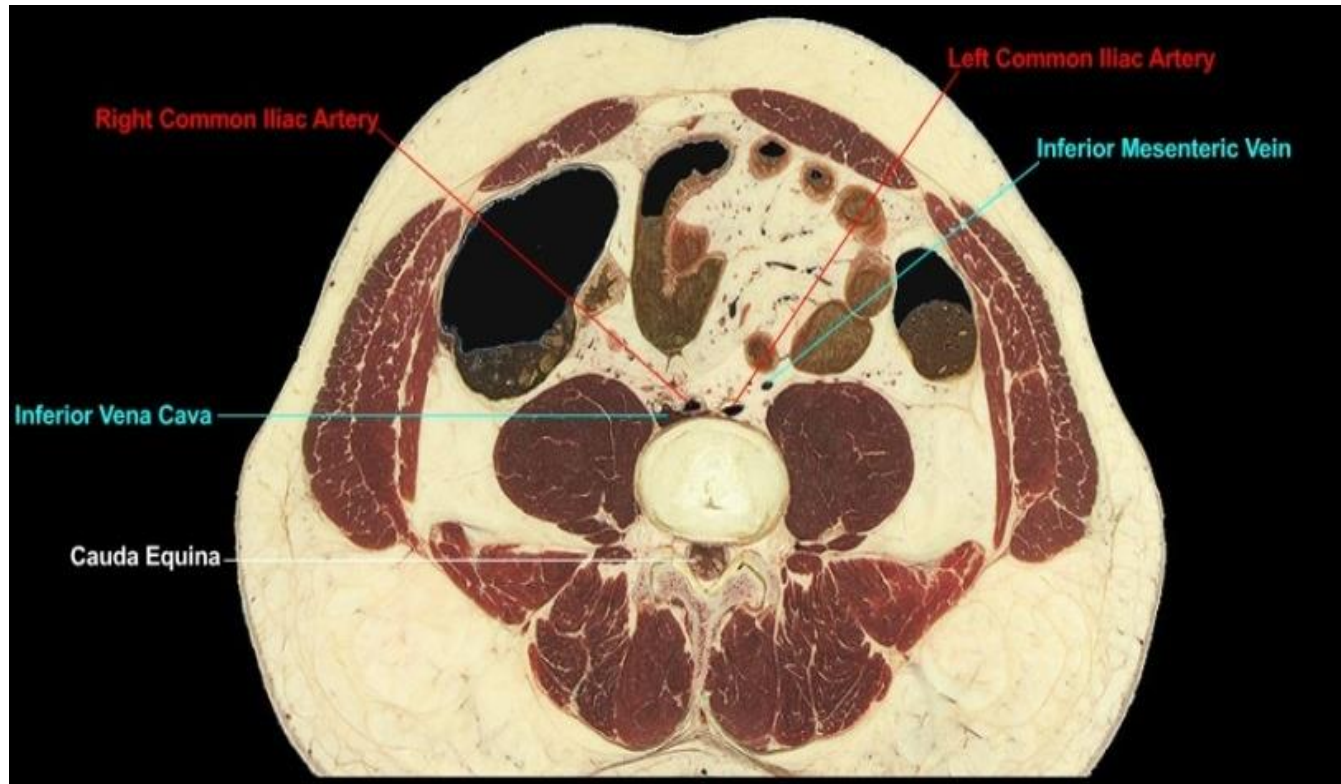
Level 11 (L4)



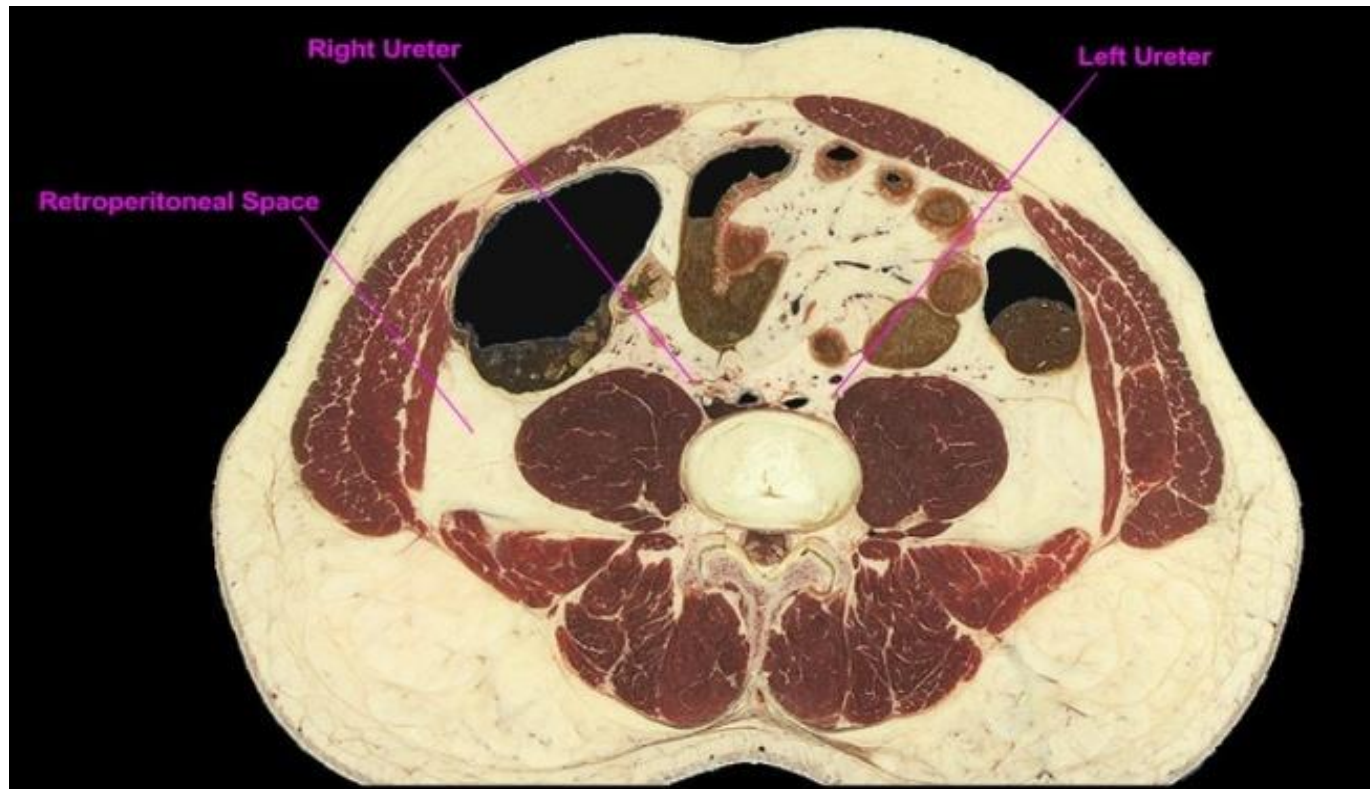
- Figura 51. Musculoskeletal aspect of the level 11.
- MUSCULOSKELETAL:
- Level of the L4-L5 intervertebral disc. The plane-of-section lies entirely below the thoracic cage and thus the abdominal cavity has no neighboring thoracic wall. We note the layering from superficial to deep of the very prominent external oblique, internal oblique, and transversus abdominis (transverse abdominal) muscles and their aponeuroses. Unlike at Level 10, there is a distinct demarcation between the quadratus lumborum and psoas major muscles of the posterior abdominal wall. The deep muscles of the back, the erector spinae, complete the musculature. From a skeletal perspective we note the articulations (called zygapophysial joints) between the L4 inferior articular processes and the L5 superior articular processes.



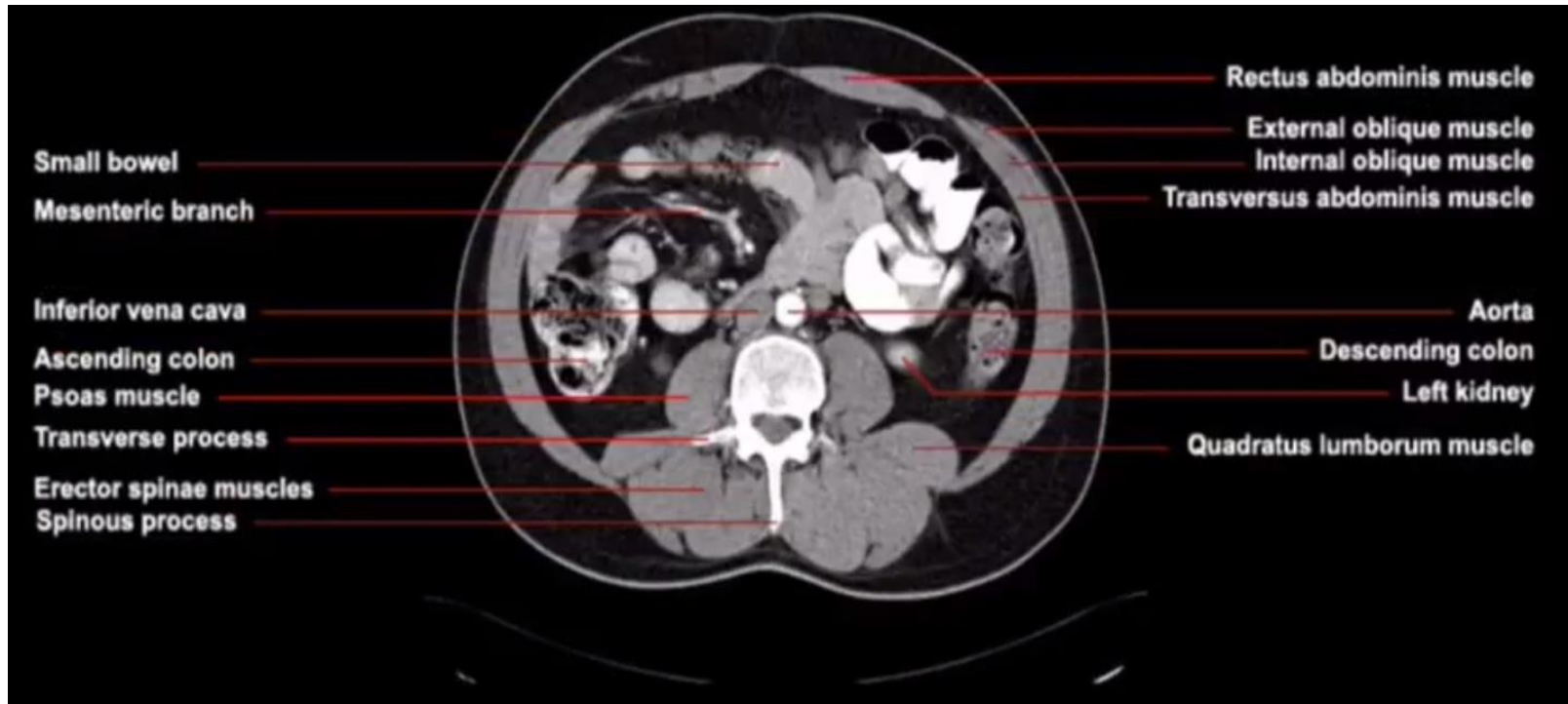
- Figura 52. Gastrointestinal aspect of the level 11.
- GASTROINTESTINAL:
- Only descending and ascending colon are present as the plane-of-section lies inferior to the transverse colon. The ascending and descending colons lie on the right and left sides of the abdomen respectively, with abdominal wall musculature on their lateral and antero-lateral sides and coils of small intestine medially and often anteriorly. The coils of small intestine are those of the ileum, which occupies the lower region of the abdominal cavity. The mesentery of the small intestine is prominent.



- Figura 53. Vascular aspect of the level 11.
- VASCULAR:
- A major structural change has occurred within the vasculature over that viewed at higher levels, i.e. the abdominal aorta divided at the level of the 4th lumbar vertebra into the now present left and right common iliac arteries. The inferior vena cava (IVC) maintains its position immediately anterior to the vertebral column and slightly to the right of midline. However the IVC is near its point of formation from the common iliac veins as evident by a narrow portion of the IVC extending behind the right common iliac artery. Also we note the inferior mesenteric vein on the left side of the posterior abdominal wall; the vein is sectioned as it ascends to join the splenic vein at a higher level.

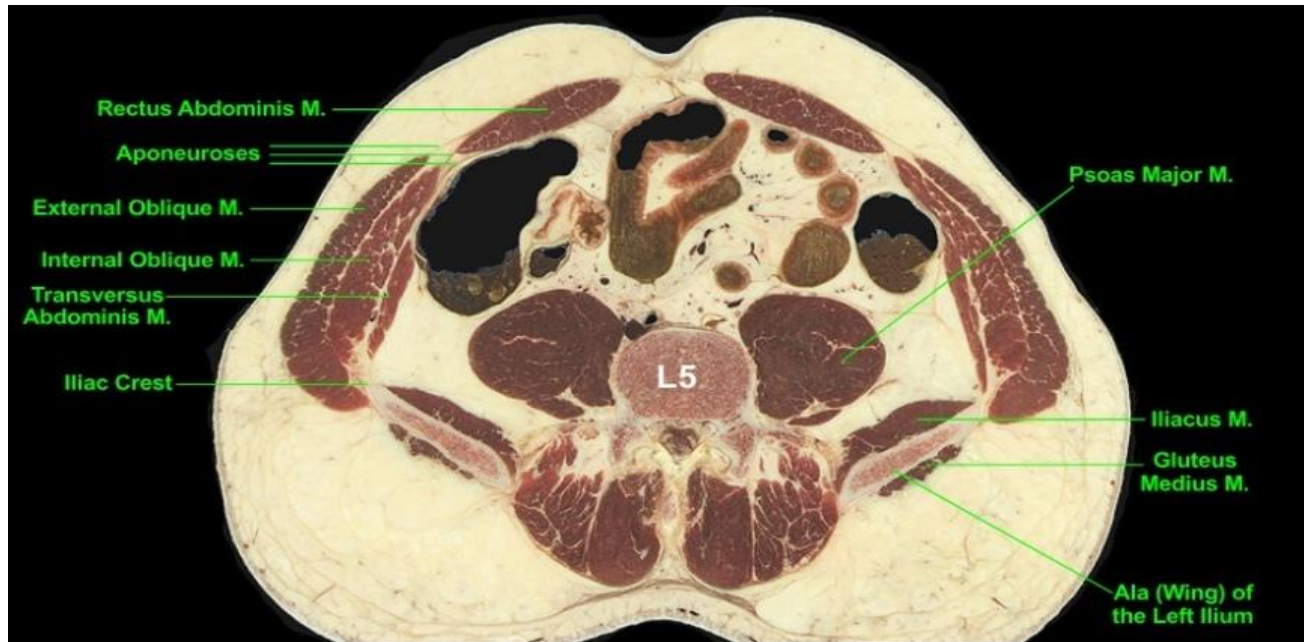


- Figura 54. Other organs of the level 11.
- OTHER:
- The ureters descend the posterior abdominal wall close to the antero-medial surfaces of the psoas major muscles. Their positions at this level lateral to the left and right common iliac arteries. We remember that the ureters are retroperitoneal structures. On the posterior abdominal wall note the fat-filled retroperitoneal spaces, which lie lateral to the psoas major muscles and anterior to the quadratus lumborum muscles.

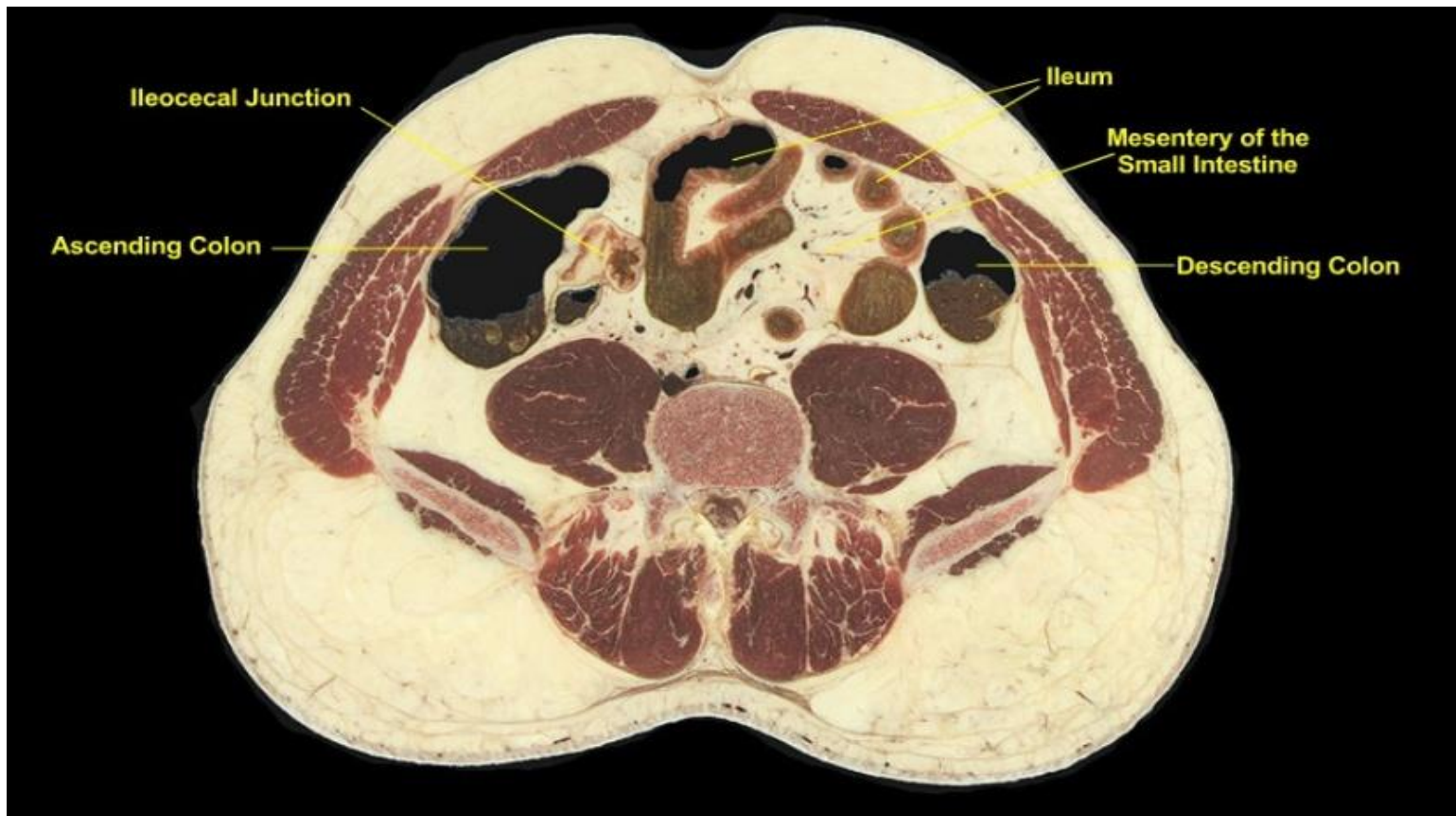


- Figura 55. CT view of the level 11.

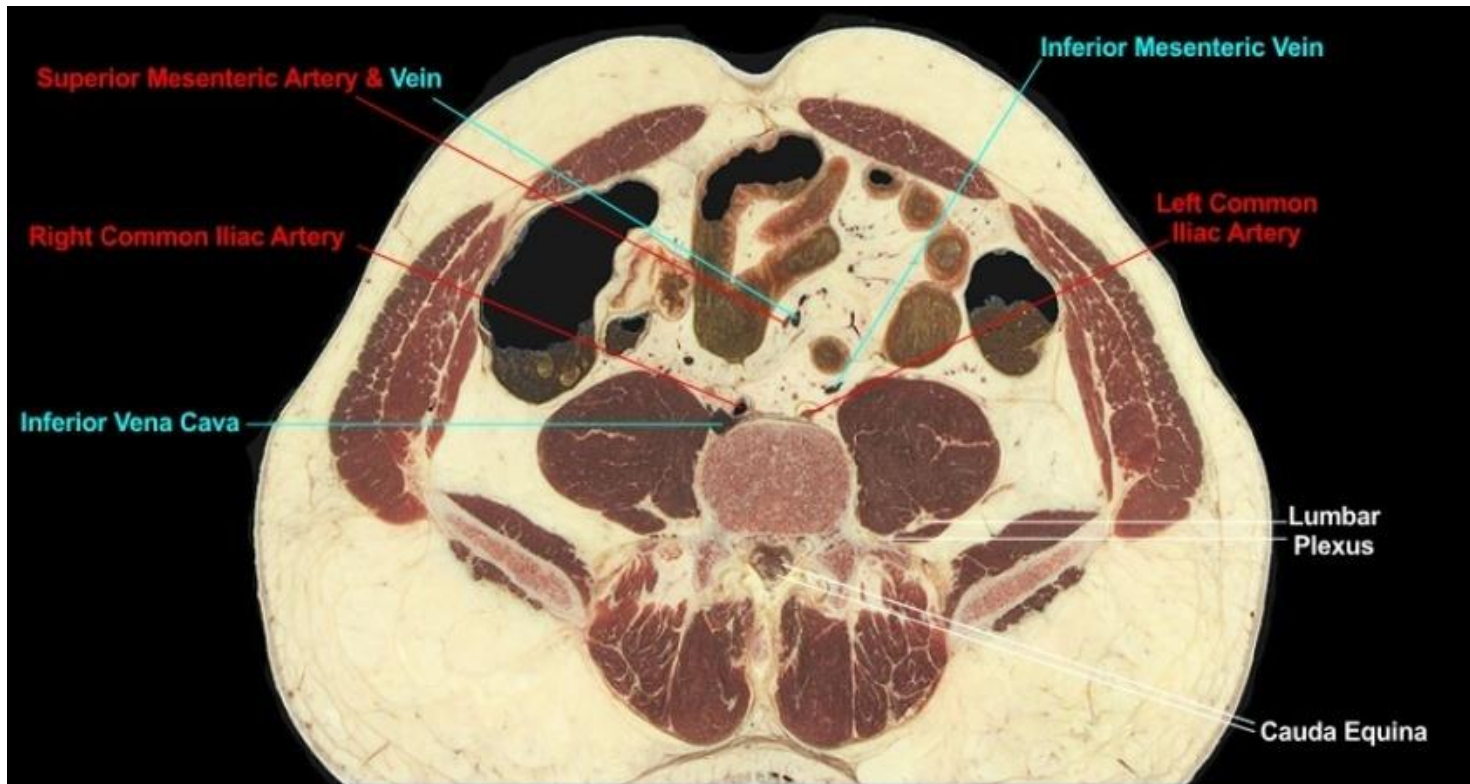
Level 12 (L5)



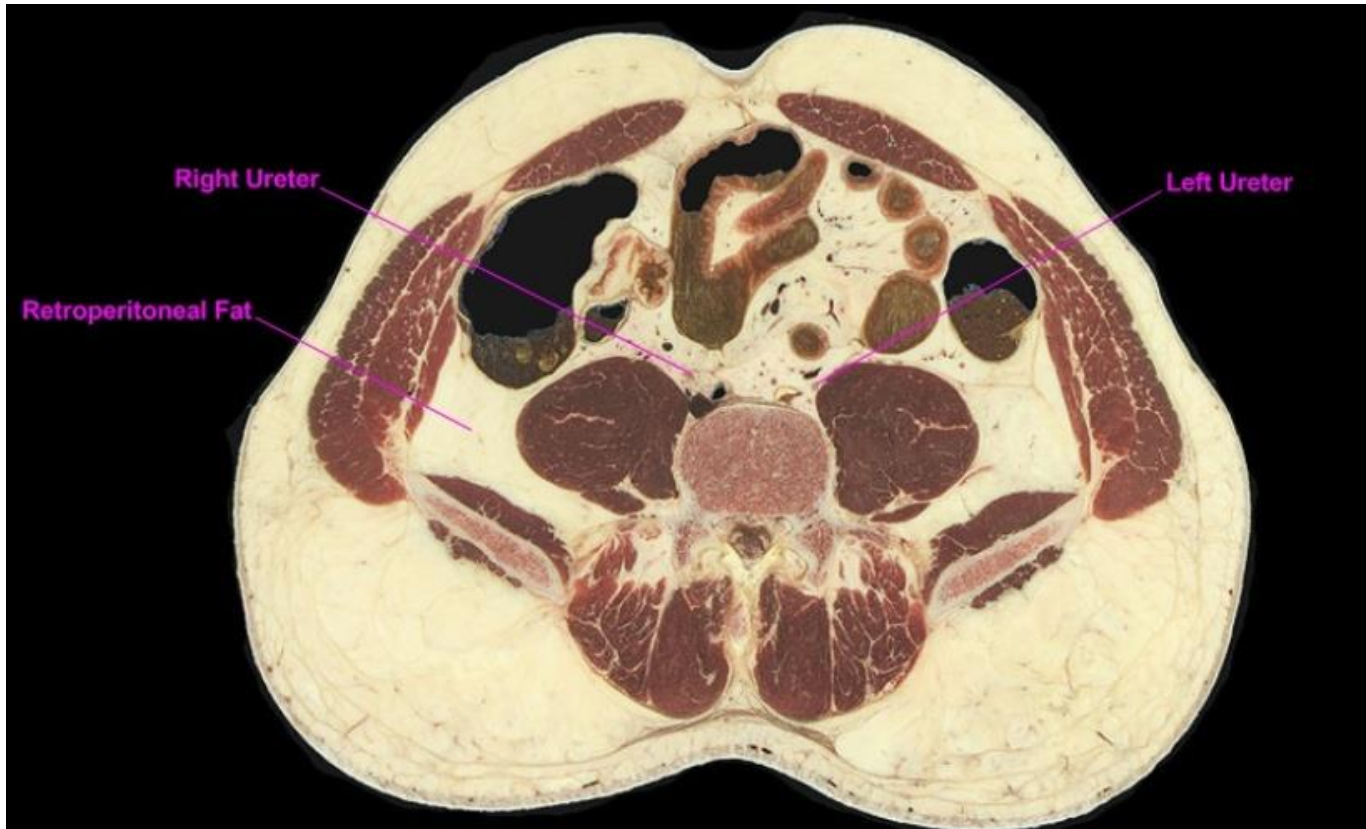- Figura 56. Musculoskeletal aspect of the level 12.
- MUSCULOSKELETAL:
- The plane lies at the level of the L5 vertebra and the wings of the iliac bone. The musculus quadratus lumborum that were prominent at the higher levels inserted onto iliac crests of the alae and are not present at this level. The iliacus muscle, that originate from the iliac fossae on the medial sides of the alae, now contribute to the posterior abdominal wall. The muscles of the lateral abdominal walls (external oblique, internal oblique and transversus muscles), all have origins or insertion on the iliac crests and their attachments to the ilia are obvious.



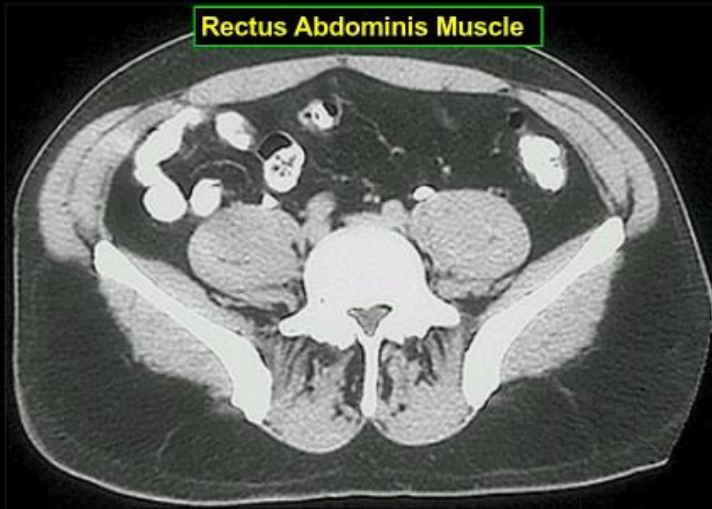
- Figura 57. Gastrointestinal aspect of the level 12.
- GASTROINTESTINAL:
- The descending and ascending colon are present as the plane-of-section lies inferior to the transverse colon. The ascending and descending colons lie on the right and left sides of the abdomen respectively, with abdominal wall musculature on their lateral and antero-lateral sides and coils of small intestine medially and often anteriorly. Very clearly is seen the ileocecal junction. The coils of small intestine occupy the lower region of the abdominal cavity. The mesentery of the small intestine is important.



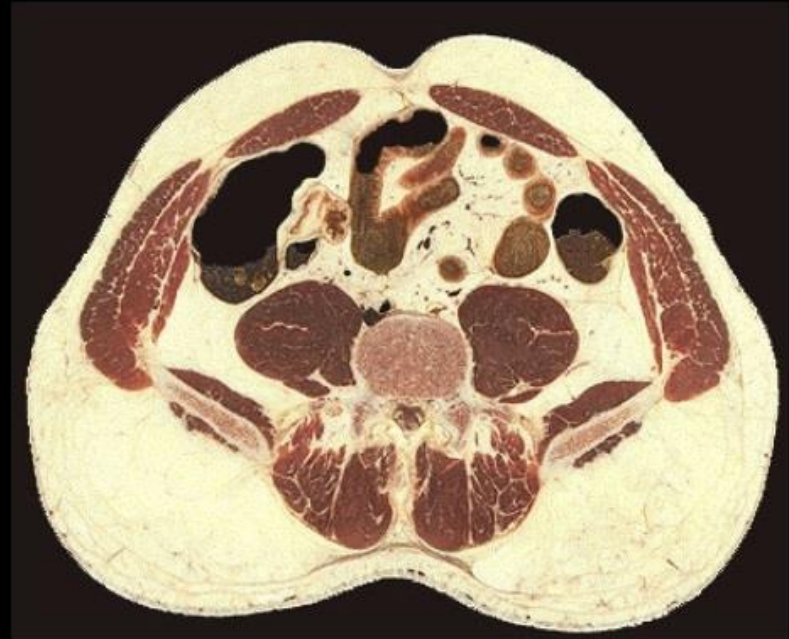- Figura 58. Vascular aspect of the level 12.
- VASCULAR:
- In the formation of the inferior vena cava (IVC) the left common iliac vein crosses the midline, posterior to the right common iliac artery, to join with the right common iliac vein; the union occurs anterior to the L5 vertebra. This section lies near the formation and close examination (seen better on High Power) reveals a small portion of the IVC collapsed behind the right common iliac artery. Note that the formation of the IVC occurs inferior to the bifurcation of the abdominal aorta. Nerves of the lumbar plexuses form within the substance of the psoas major muscles and some nerve profiles are evident on the posterior side of the muscles. Observe the spinal nerve roots comprising the cauda equina in the vertebral canal.



- Figura 59. Other organs of the level 11.
- OTHER:
- We note the positions of the ureters as they approach their descent from the abdomen into the pelvis. The ureters lie lateral to the common iliac arteries and on the antero-medial surfaces of the psoas major muscles. Remember that the ureters are retroperitoneal structures and thus would be covered anteriorly with parietal peritoneum.



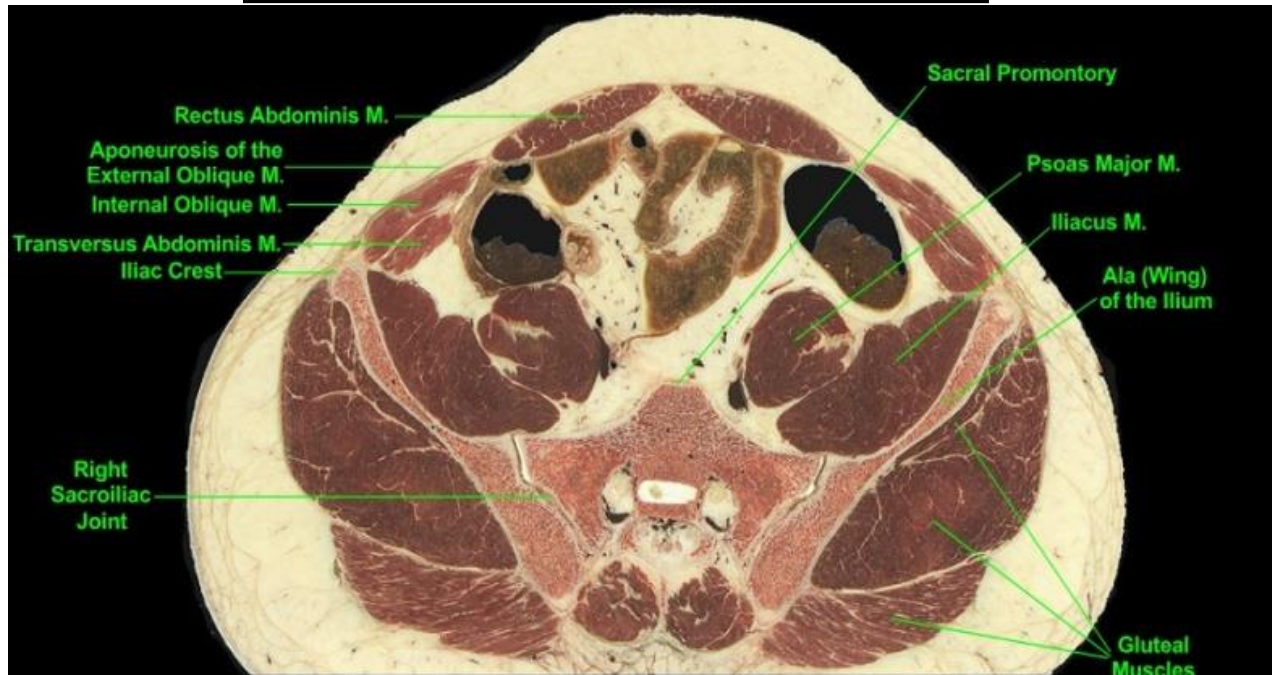
In the CT scan above select the structures highlighted in the paragraph below.



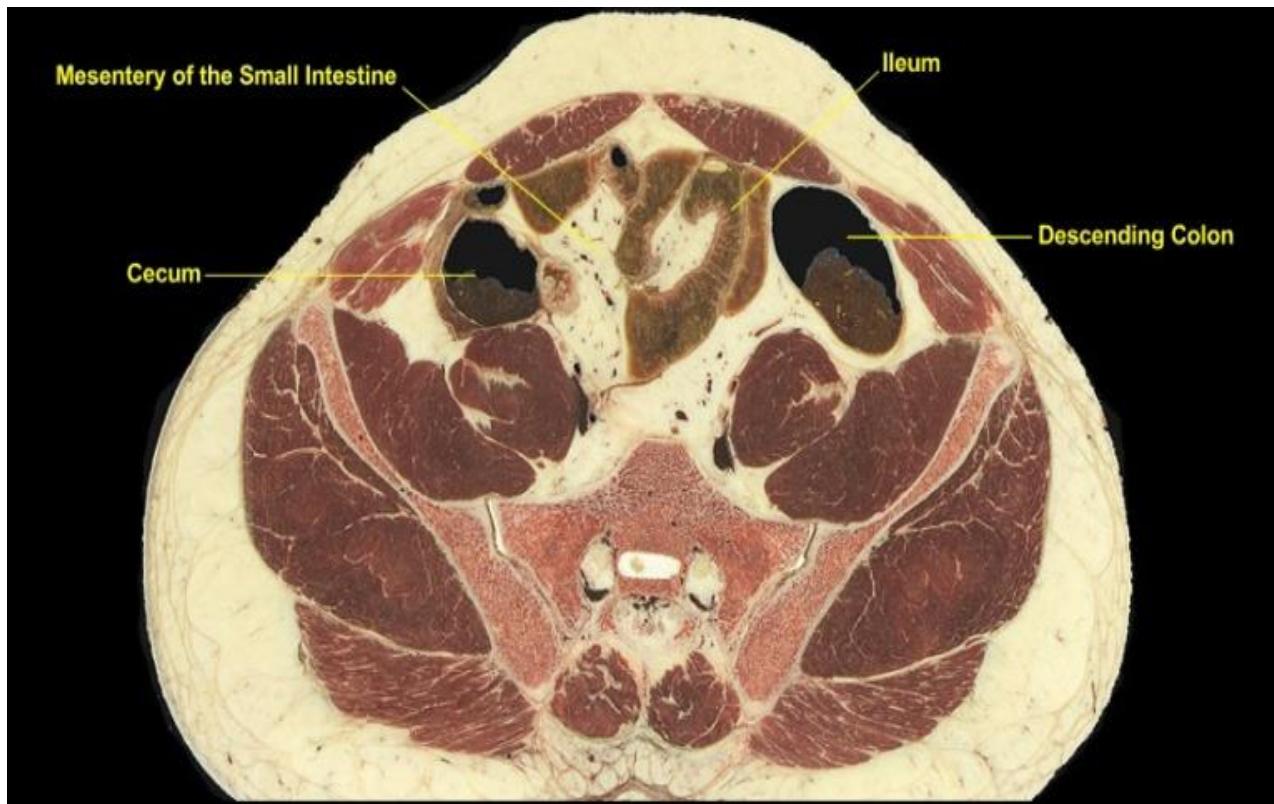
A CT scan from the region just slightly inferior to the ileocecal junction. The patient was given both oral and intravenous contrast materials, the former accumulating in the **ileum** and **colon** while the latter has been largely cleared from the blood by the kidneys and now highlights the **ureters**. As in the cadaveric section of Level 12, note the positions of the ureters on the anteromedial surfaces of the **psoas major muscles**. Compare the **musculature of the abdominal walls** seen in CT with that of the cadaveric cross-section.

- Figura 60.CT of the level 12.

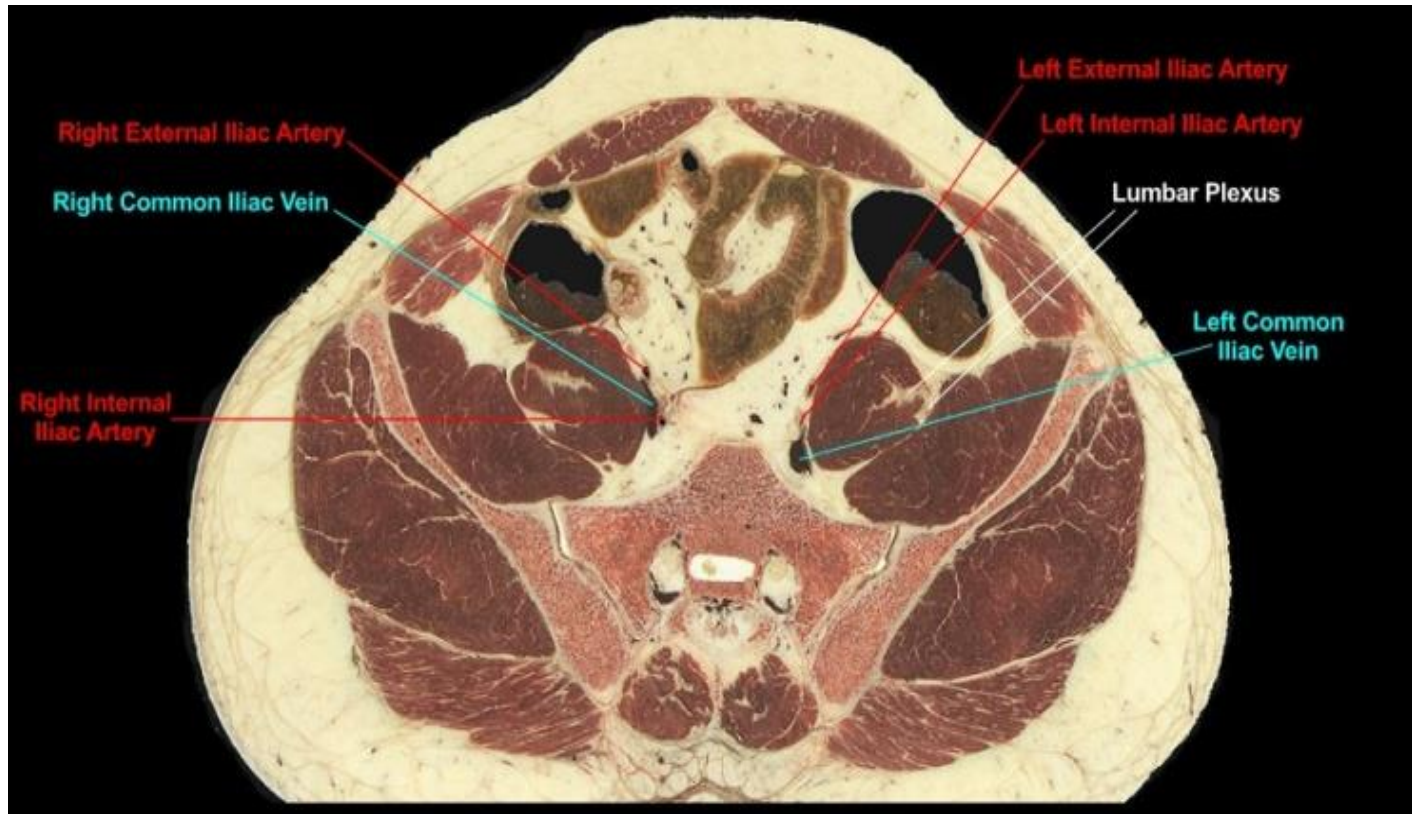
Level 13 (L5 S1)



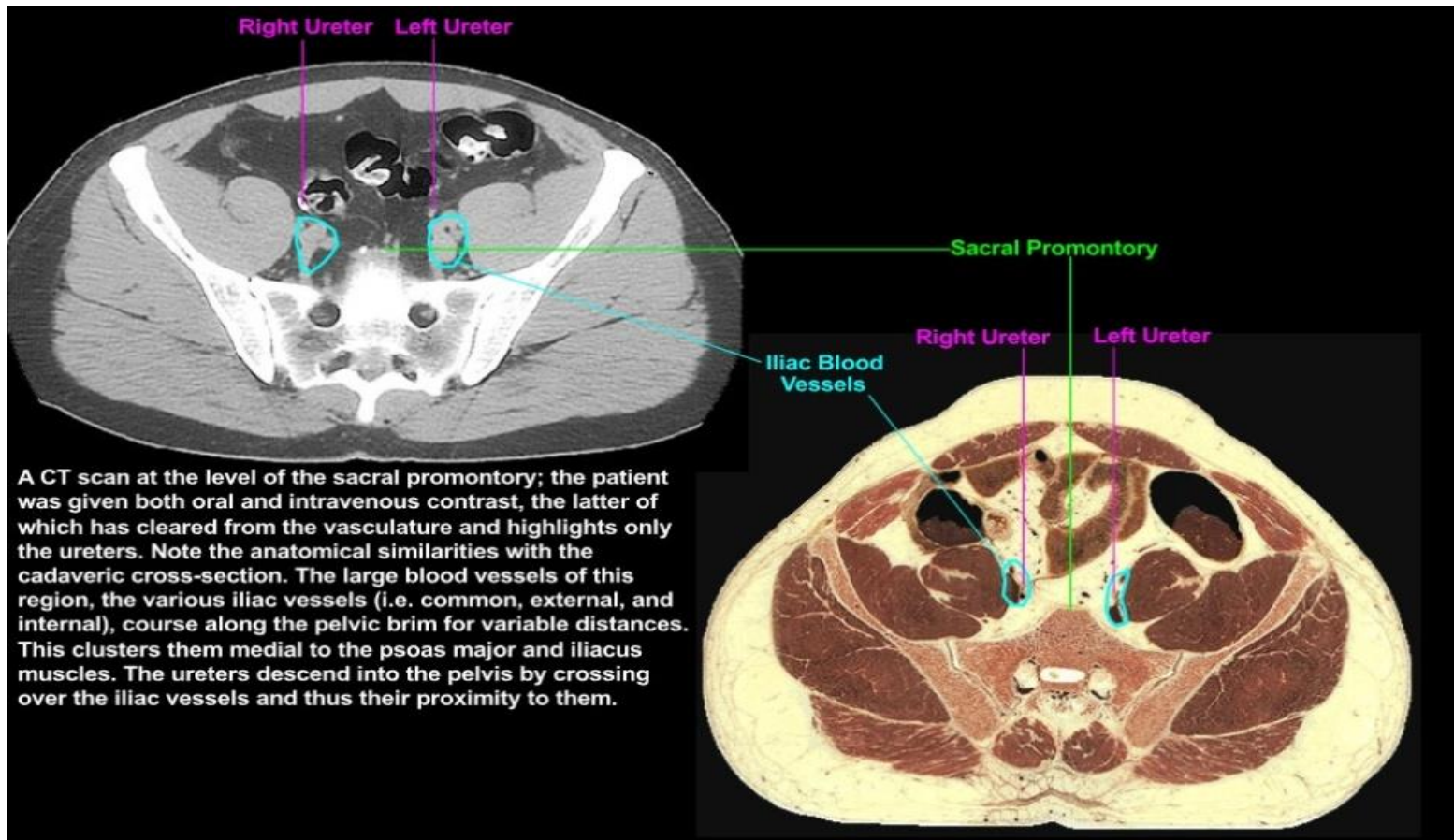
- Figura 61. Musculoskeletal of the level 13.
- MUSCULOSKELETAL:
- The plane passes through the sacral promontory, which forms the posterior margin of the pelvic brim and thus the posterior demarcation of abdomen from pelvis. Since the pelvic brim lies on an oblique plane, the abdominal cavity will be progressively replaced in the cross-sectional plane by the pelvic cavity as the plane-of- section descends further. The musculature of the lateral abdominal wall is significantly reduced over that at higher levels with expansion of the hip bones and the narrowing of the abdominal cavity anteriorly. At this level the external oblique is largely limited to its aponeurosis. Observe the sacroiliac joints between the lower limbs and the trunk of the body.



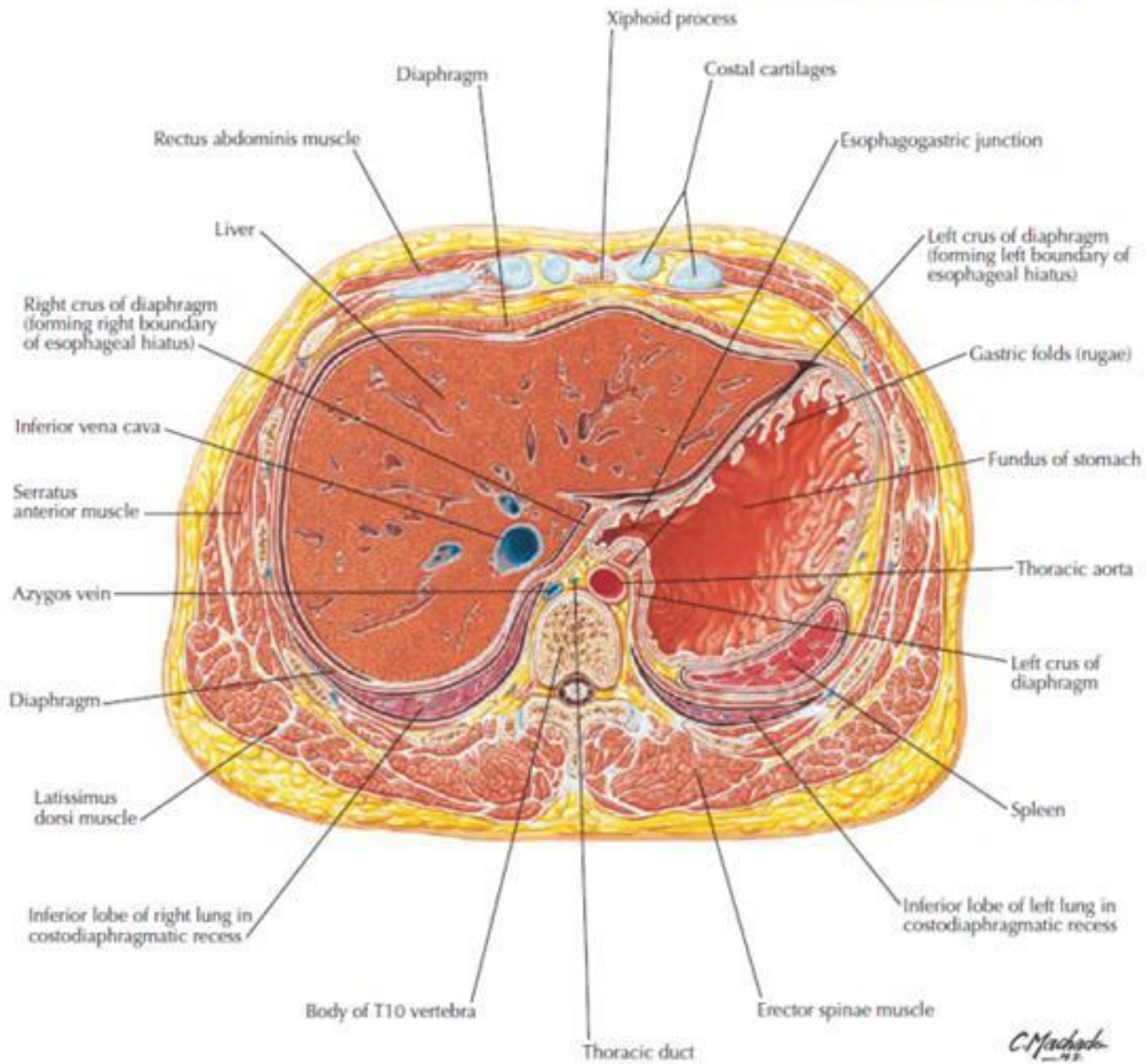
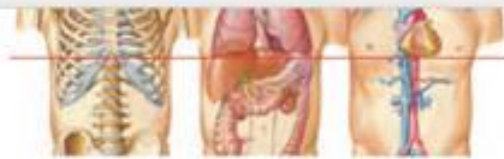- Figura 62. Gastrointestinal of the level 13.
- GASTROINTESTINAL:
- The section lies inferior to the ileocecal junction; ascending colon is no longer present while its position on the right side of the abdominal cavity has been replaced with the cecum. The descending colon is sectioned obliquely as it comes to lie more anteriorly, soon to be continuous with the sigmoid colon. The coils of small intestine are ileum; note their position immediately deep to the anterior abdominal wall and between the coecum and descending colon.



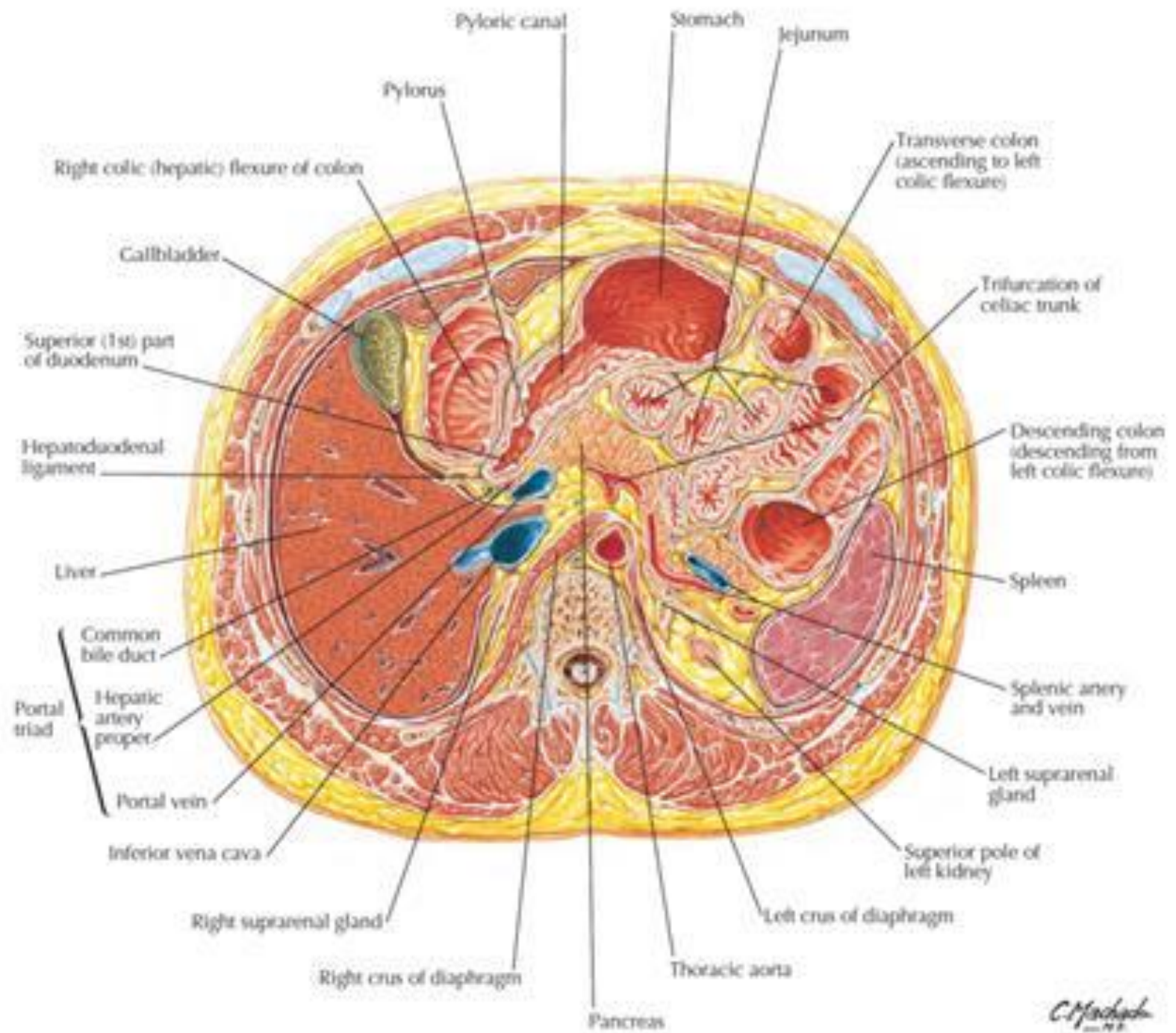
- Figura 63. Vascular of the level 13.
- VASCULAR:
- The left and right common iliac arteries viewed more superiorly have divided into internal iliac arteries (to the pelvis) and external iliac arteries (destined for the lower limbs). The corresponding internal and external iliac veins united slightly more inferiorly to form the common iliac veins. Nerves of the lumbar plexus are evident around the psoas major muscle.

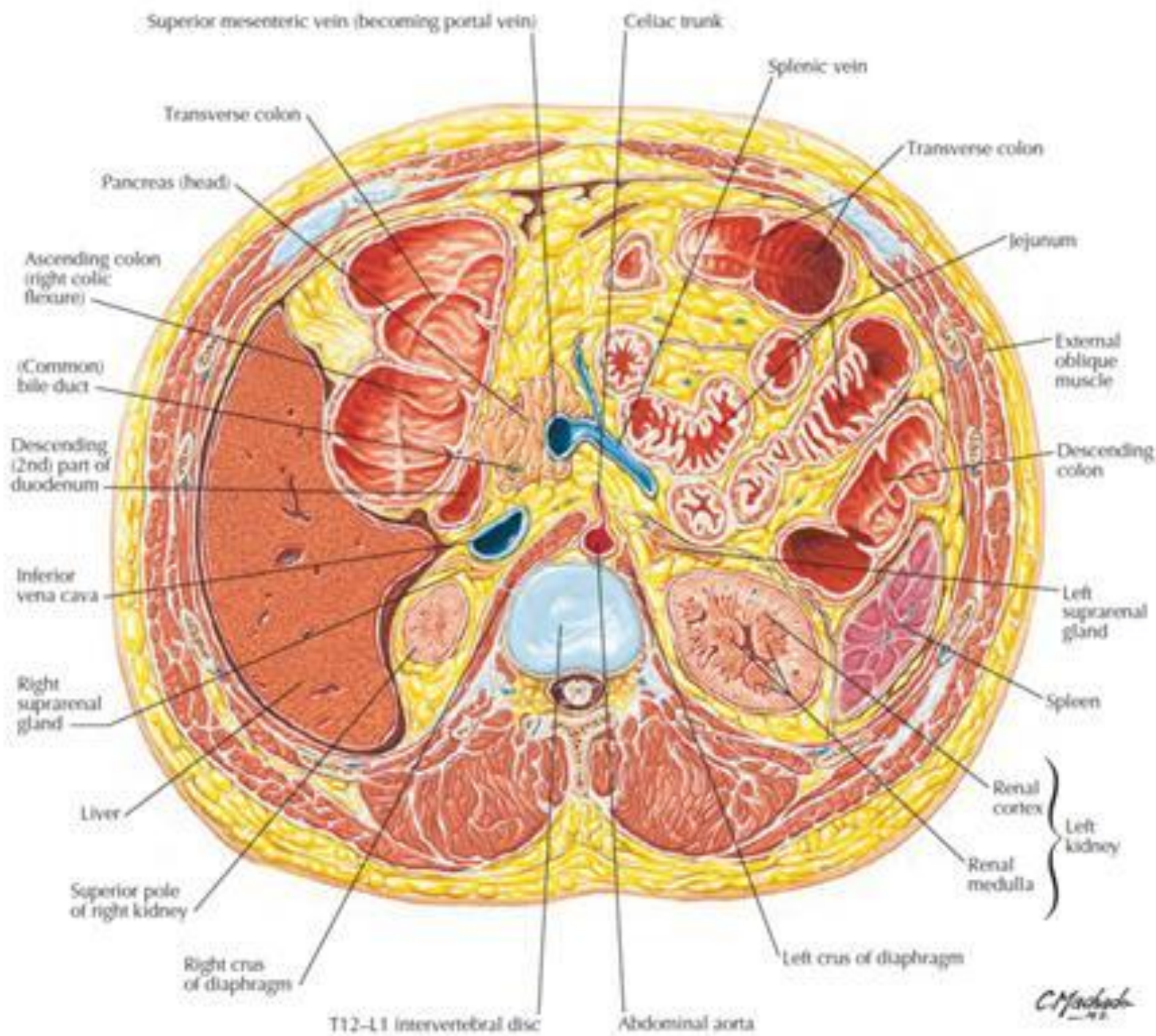


- Figura 64. CT of the level 13.
- **CT scan** at the level of the sacral promontory; the patient was given both oral and intravenous contrast, the latter of which has cleared from the vasculature and highlights only the ureters. Note the anatomical similarities with the cadaveric cross-section. The large blood vessels of this region, the various iliac vessels (i.e. common, external, and internal), course along the pelvic brim for variable distances. This clusters them medial to the psoas major and iliacus muscles. The ureters descend into the pelvis by Crossing over the iliac vessels and thus their proximity to them.

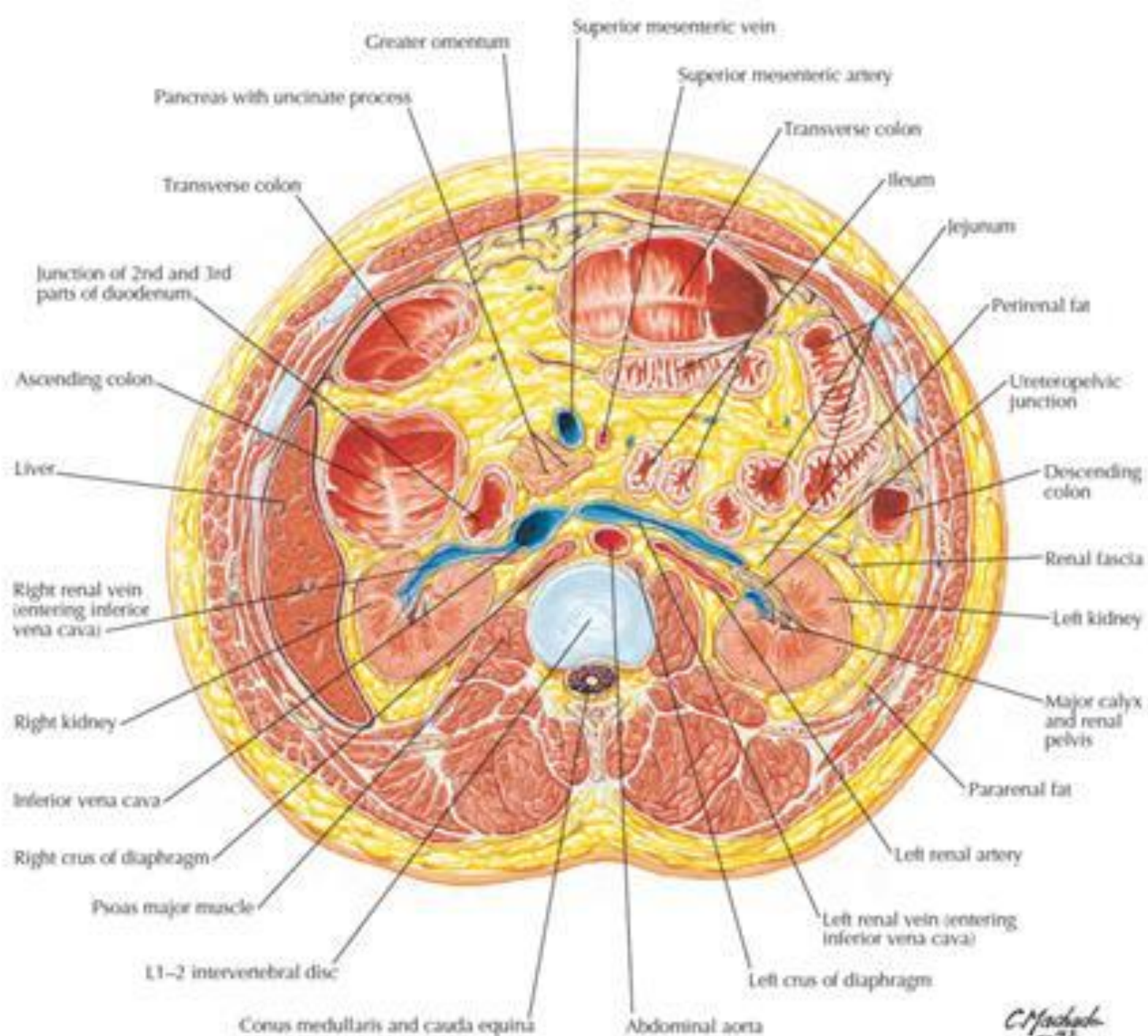


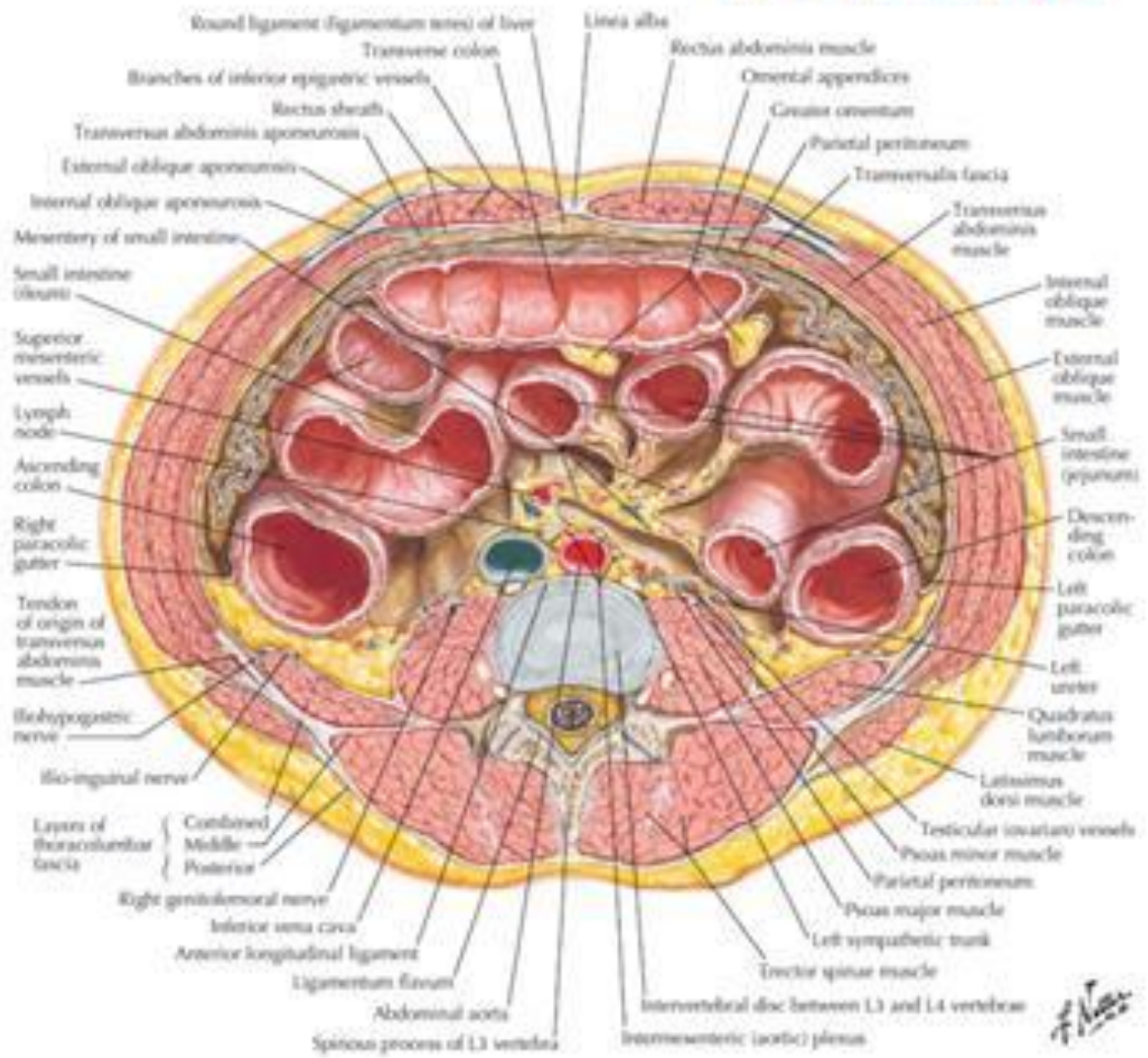
C. Machado





C. Machado
— 1982





F. Netter

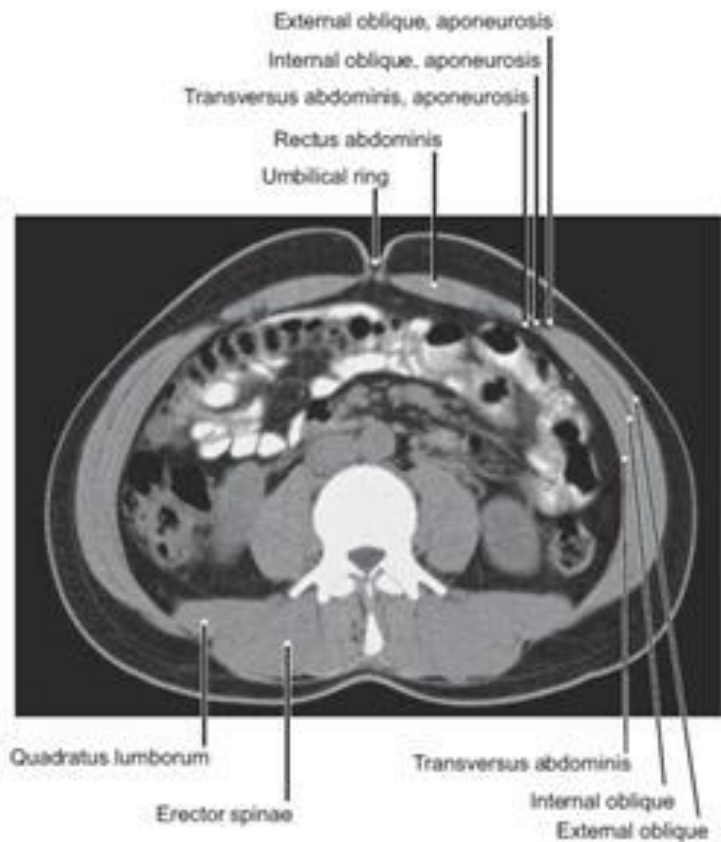


FIGURE 229.2 Computed Tomography (CT) of the Muscles of the Abdomen at the Level of the Umbilicus

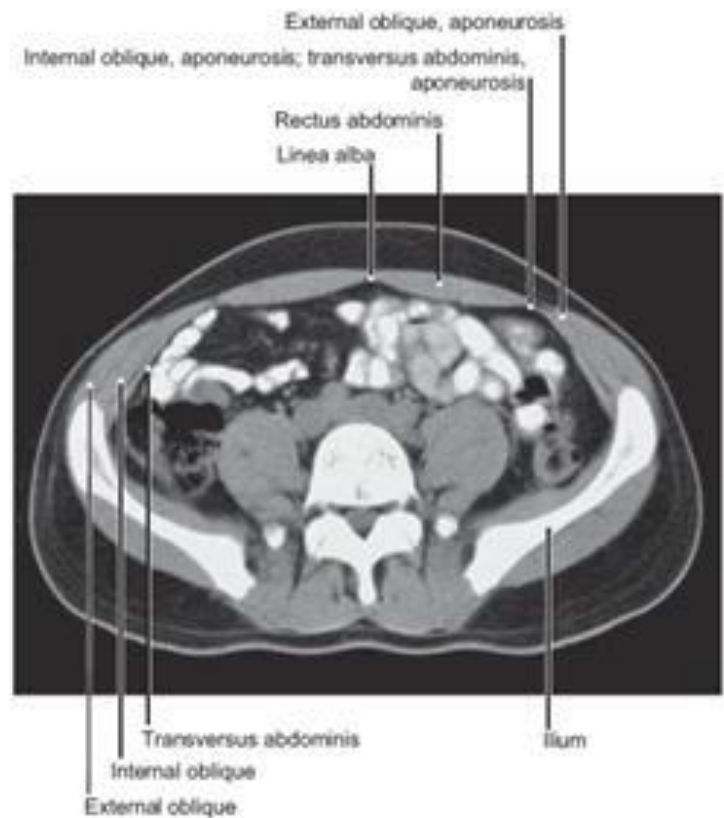


FIGURE 229.3 CT of the Muscles of the Abdomen at the Level of the Fifth Lumbar Vertebra