

Local Anesthesia Techniques in Oral and Maxillofacial Surgery

Sean M. Healy, D.D.S.

Oral and Maxillofacial Surgery

Francis B. Quinn, M.D., FACS

Otolaryngology – Head and Neck Surgery

The University of Texas Medical Branch

October 2004



Overview:

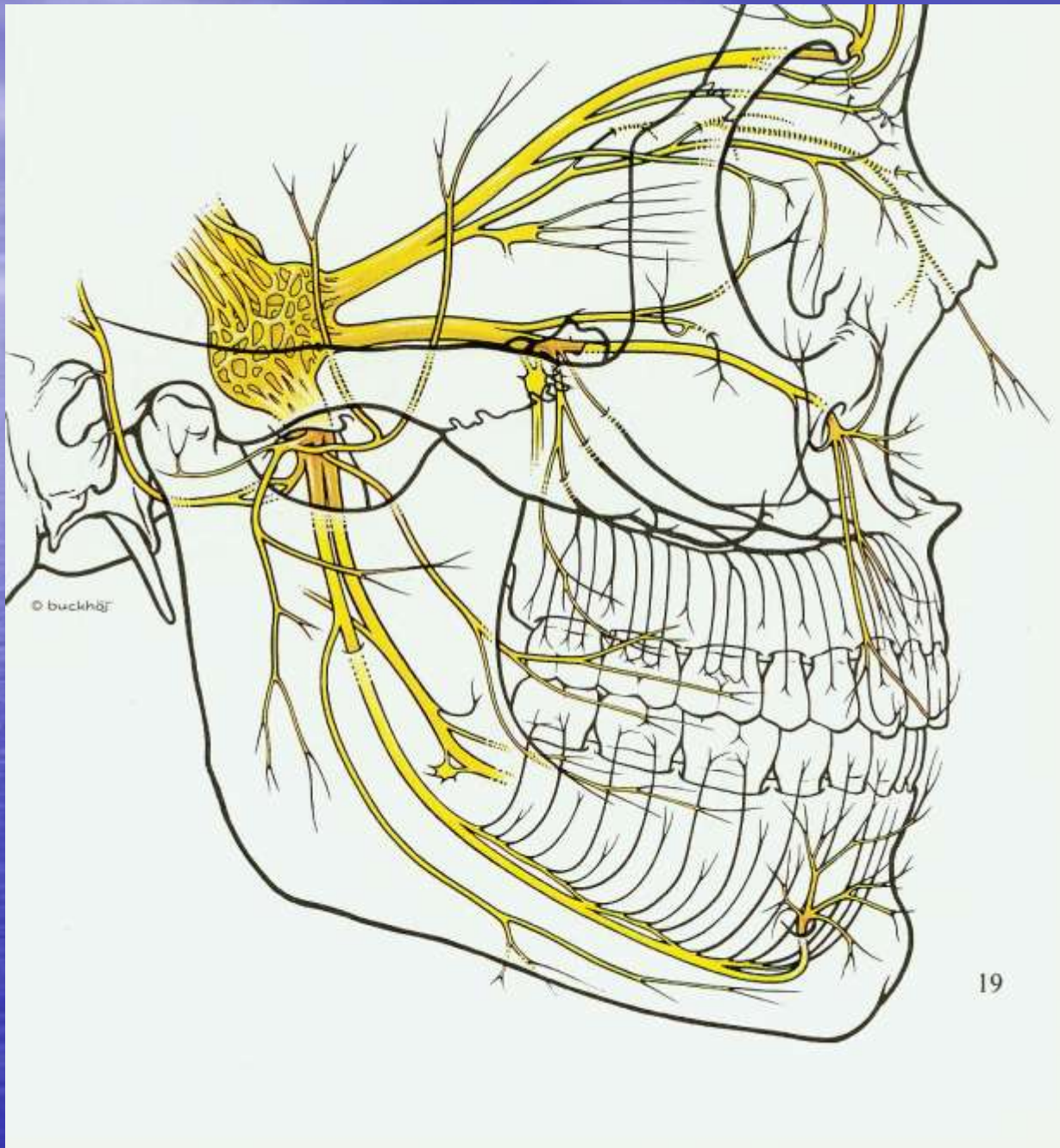
- Purpose of local anesthesia
- Anatomy of maxillary and mandibular nervous innervation
- Techniques of local anesthesia blocks
- Commonly used local anesthetics
- Complications with local anesthesia

Local Anesthetics:

- Role:
 - Decrease intraoperative and postoperative pain
 - Decrease amount of general anesthetics used in the OR
 - Increase patients cooperation
 - Diagnostic testing/examination

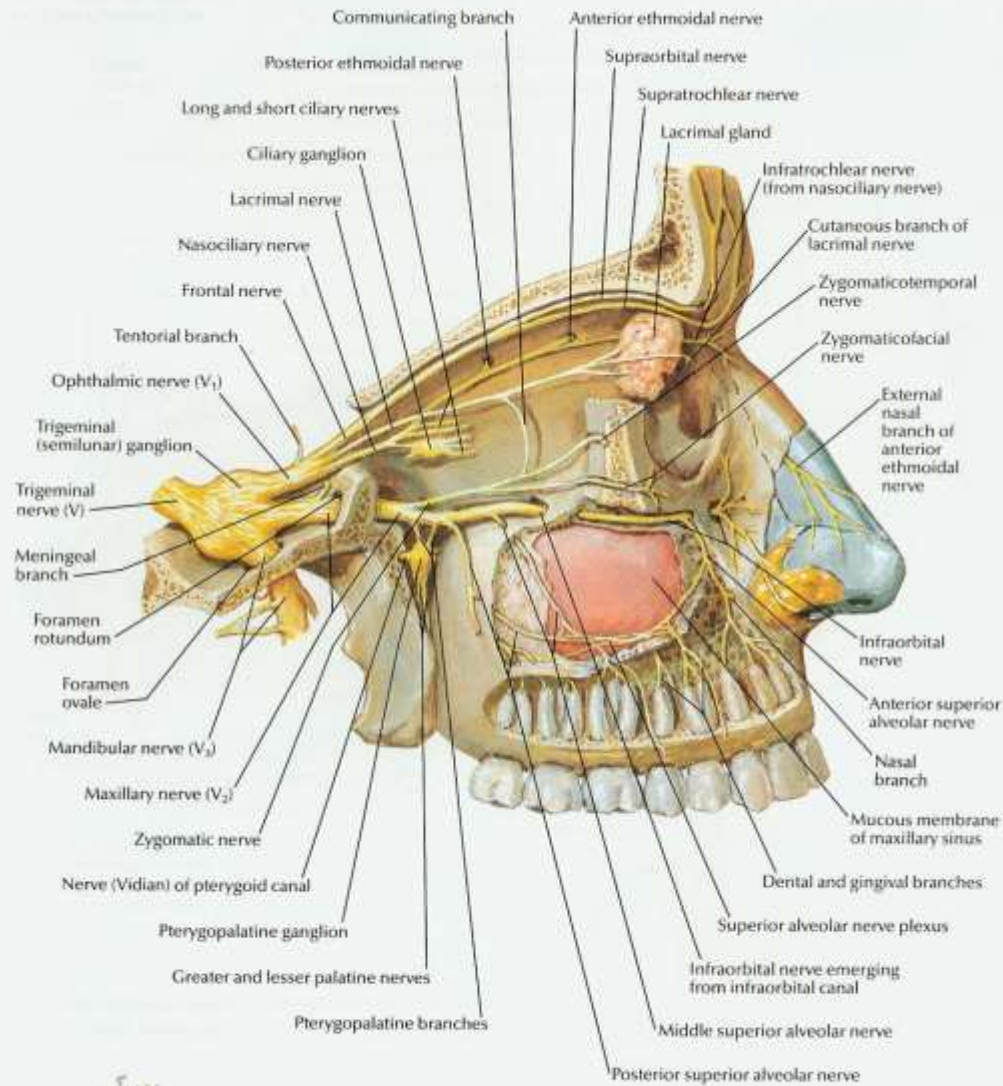
Anatomical considerations:

- Trigeminal nerve:
 - Sensory divisions:
 - Ophthalmic division V1
 - Maxillary division V2
 - Mandibular division V3
 - Motor division:
 - Masticatory- masseter, temporalis, medial and lateral pterygoids
 - Mylohyoid
 - Anterior belly of the digastric
 - Tensor tympani
 - Tensor veli palatini



Maxillary Division (V2):

- Exits the cranium via foramen rotundum of the greater wing of the sphenoid
- Travels at the superior most aspect of the pterygopalatine fossa just posterior to the maxilla
- Branches divided by location:
 - Inter-cranial
 - Pterygopalatine
 - Infraorbital
 - Facial



Maxillary Division (V2):

- Branches:
 - **Within the cranium-** middle meningeal nerve providing sensory innervation to the dura mater
 - **Within the pterygopalatine fossa-**
 - Zygomatic nerve
 - Pterygopalatine nerves
 - Posterior superior alveolar nerve

Maxillary Division (V2):

- **Within the pterygopalatine fossa-**
 - Zygomatic nerve:
 - Zygomaticofacial nerve- skin to cheek prominence
 - Zygomaticotemporal nerve- skin to lateral forehead
 - Pterygopalatine nerves:
 - Serves as communication for the pterygopalatine ganglion and the maxillary nerve
 - Carries postganglionic secretomotor fibers through the zygomatic branch to the lacrimal gland

Maxillary Division (V2):

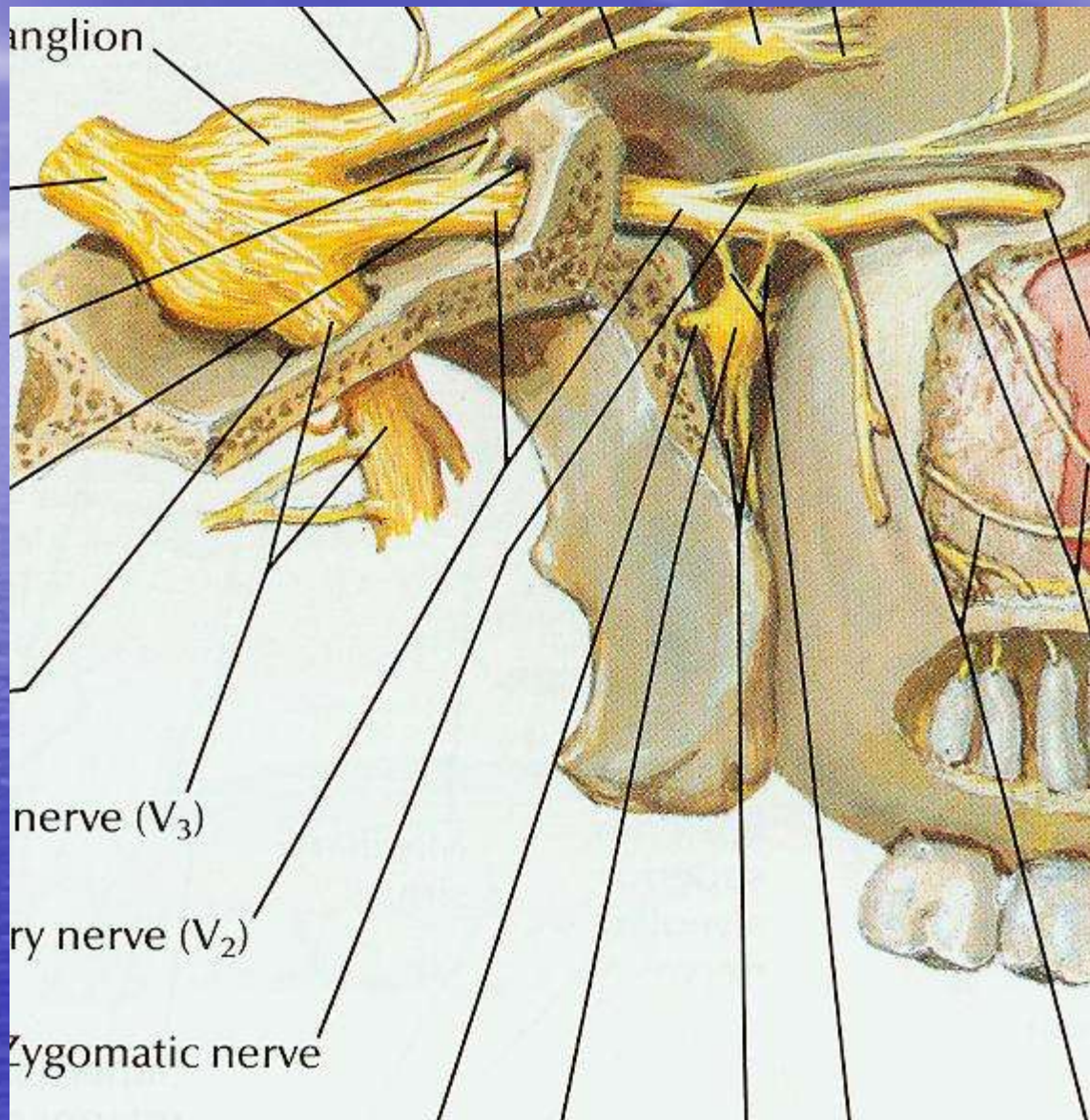
- **Within the pterygopalatine fossa-**
 - Pterygopalatine nerves:
 - Orbital branches- supplies periosteum of the orbits
 - Nasal branches- supplies mucous membranes of superior and middle conchae, lining of posterior ethmoid sinuses, and posterior nasal septum.
 - Nasopalatine nerve- travels across the roof of nasal cavity giving branches off to the anterior nasal septum and floor of nose. Enters incisive foramen and provides palatal gingival innervation to the premaxilla

Maxillary Division (V2):

- **Within the pterygopalatine fossa-**
 - Pterygopalatine nerves:
 - Palatine branches- greater (anterior) and lesser (middle or posterior) palatine nerves
 - Greater palatine: travels through the pterygopalatine canal and enters the palate via the greater palatine foramen. Innervates palatal tissue from premolars to soft palate. Lies 1cm medial from 2nd molar region
 - Lesser palatine: emerges from lesser palatine foramen and innervates the mucous membranes of the soft palate and parts of the tonsillar region

Maxillary Division (V2):

- **Within the pterygopalatine fossa-**
 - Pterygopalatine nerves:
 - Pharyngeal branch- exits the pterygopalatine ganglion and travels through the pharyngeal canal. Innervates mucosa of the portions of the nasal pharynx
 - Posterior superior alveolar nerve (PSA): branches from V2 prior to entrance into infraorbital groove. Innervates posterior maxillary alveolus, periodontal ligament, buccal gingiva, and pulpal tissue (only for 1st, 2nd, and 3rd molars)



Maxillary Division (V2):

- **Infraorbital canal branches:**

- Middle superior alveolar (MSA):

- Provides innervation to the maxillary alveolus, buccal gingiva, periodontal ligament, and pulpal tissue for the premolars only

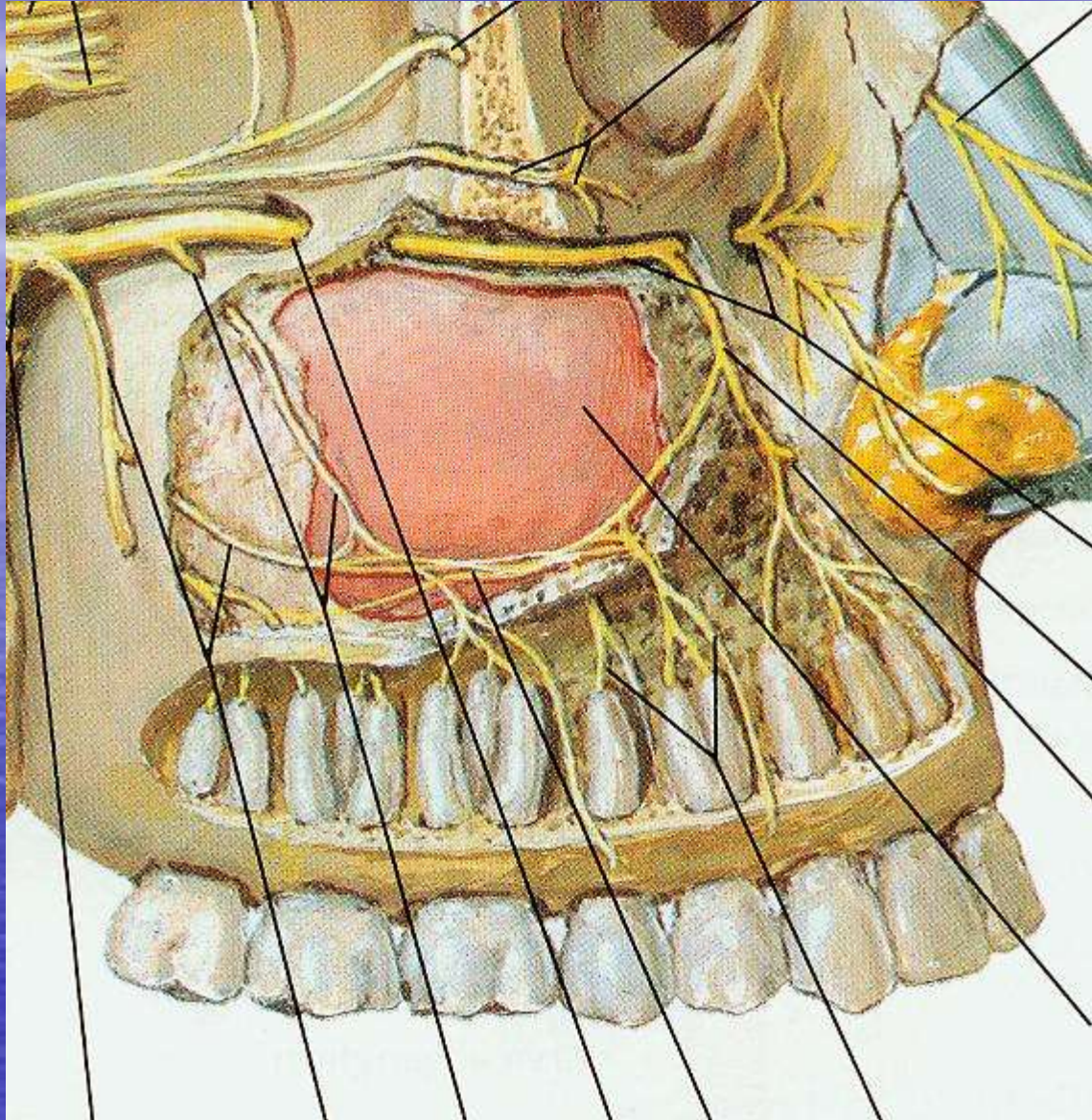
- Anterior superior alveolar (ASA):

- Provides innervation to the maxillary alveolus, buccal gingiva, periodontal ligament, and pulpal tissue for the canines, lateral and central incisors
- Branches 6-8mm posterior to the infraorbital nerve exit from infraorbital foramen

Maxillary Division (V2):

- **Facial branches:**

- Emerges from the infraorbital foramen
- Branches consist of:
 - Inferior palpebral- lower eyelid
 - External nasal- lateral skin of nose
 - Superior labial branch- upper lip skin and mucosa



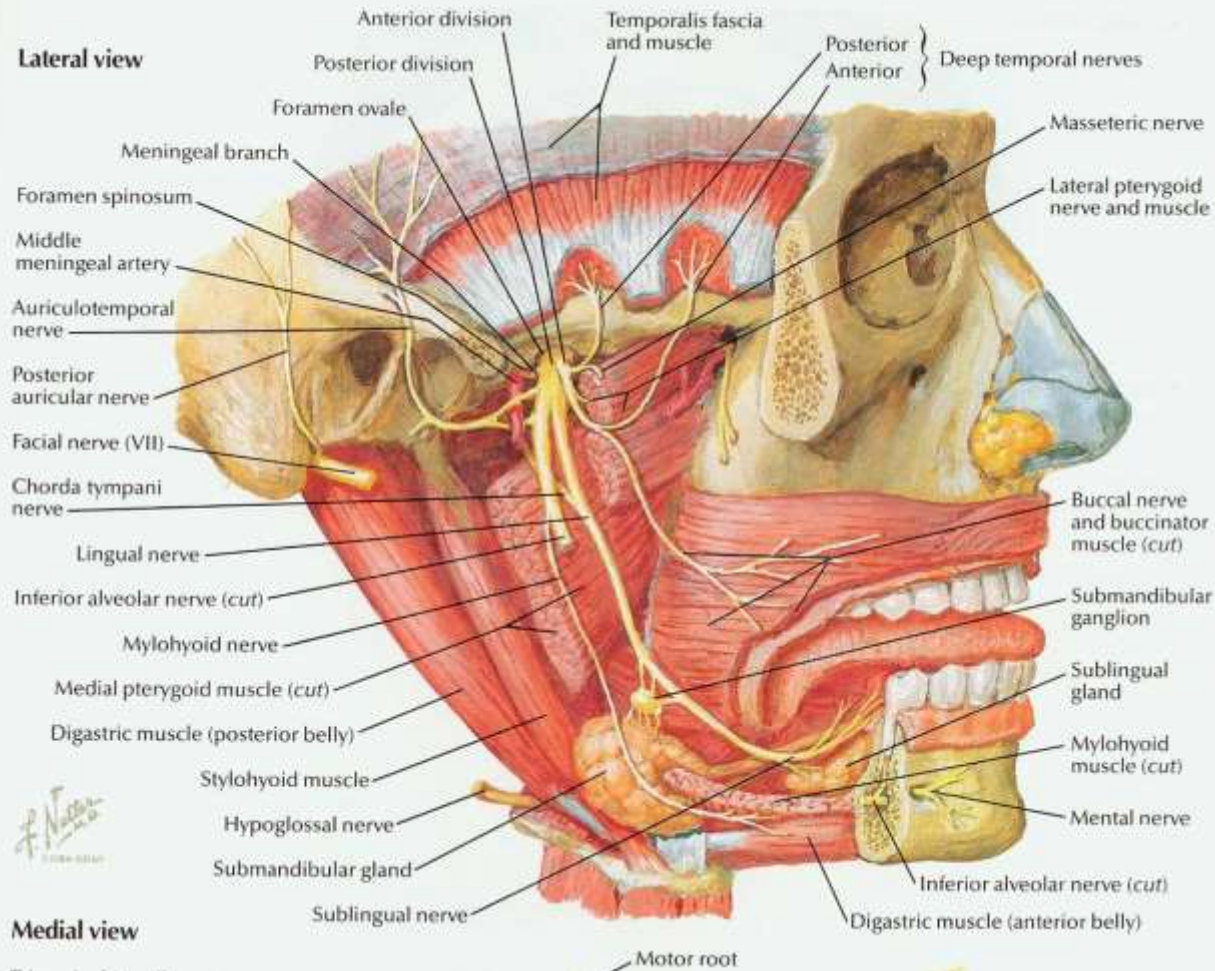
Mandibular division (V3):

- Largest branch of the trigeminal nerve
- Composed of sensory and motor roots
- Sensory root:
 - Originates at inferior border of trigeminal ganglion
- Motor root:
 - Arises in motor cells located in the pons and medulla
 - Lies medial to the sensory root

Mandibular division (V3):

- Branches:
 - The sensory and motor roots emerge from the foramen ovale of the greater wing of the sphenoid
 - Initially merge outside of the skull and divide about 2-3mm inferiorly
 - Branches:
 - Branches of the undivided nerve
 - Branches of the anterior division
 - Branches of the posterior division

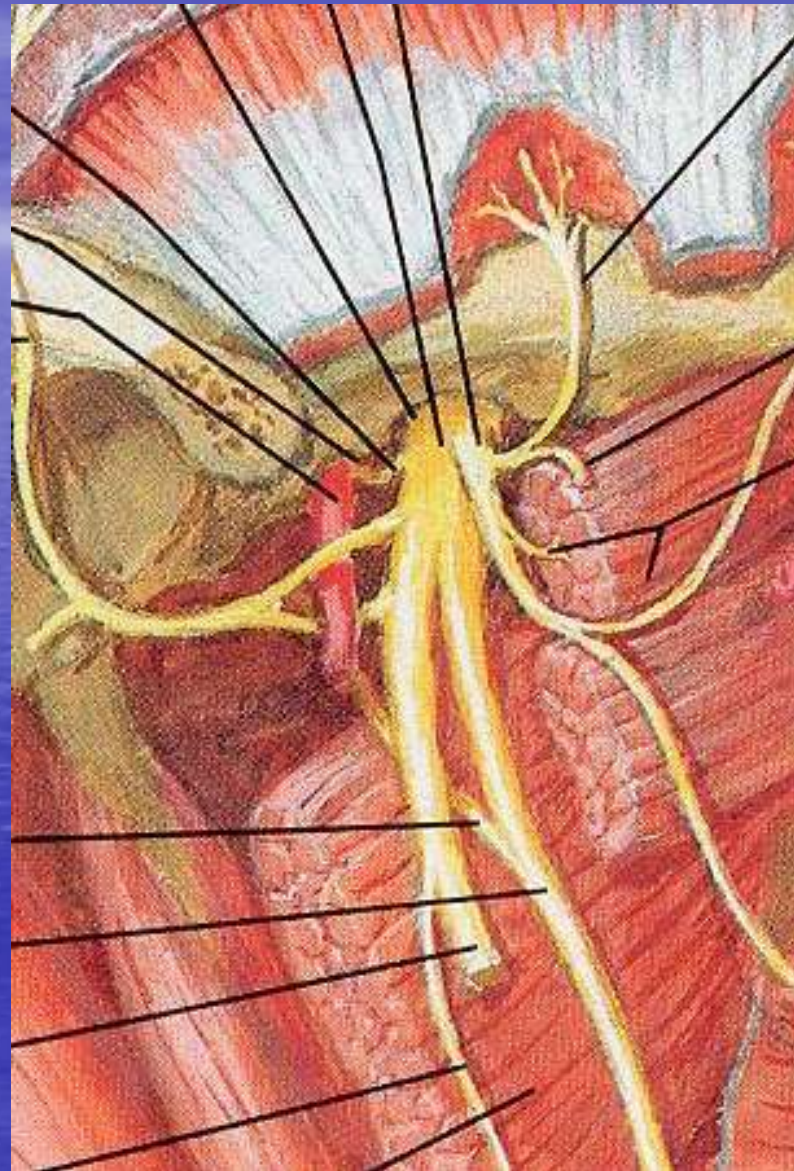
Lateral view



Medial view

Mandibular division (V3):

- **Branches of the undivided nerve:**
 - Nervus spinosus- innervates mastoids and dura
 - Medial pterygoid- innervates medial pterygoid muscle
 - Branches into
 - Tensor veli palatini
 - Tensor tympani



Mandibular division (V3):

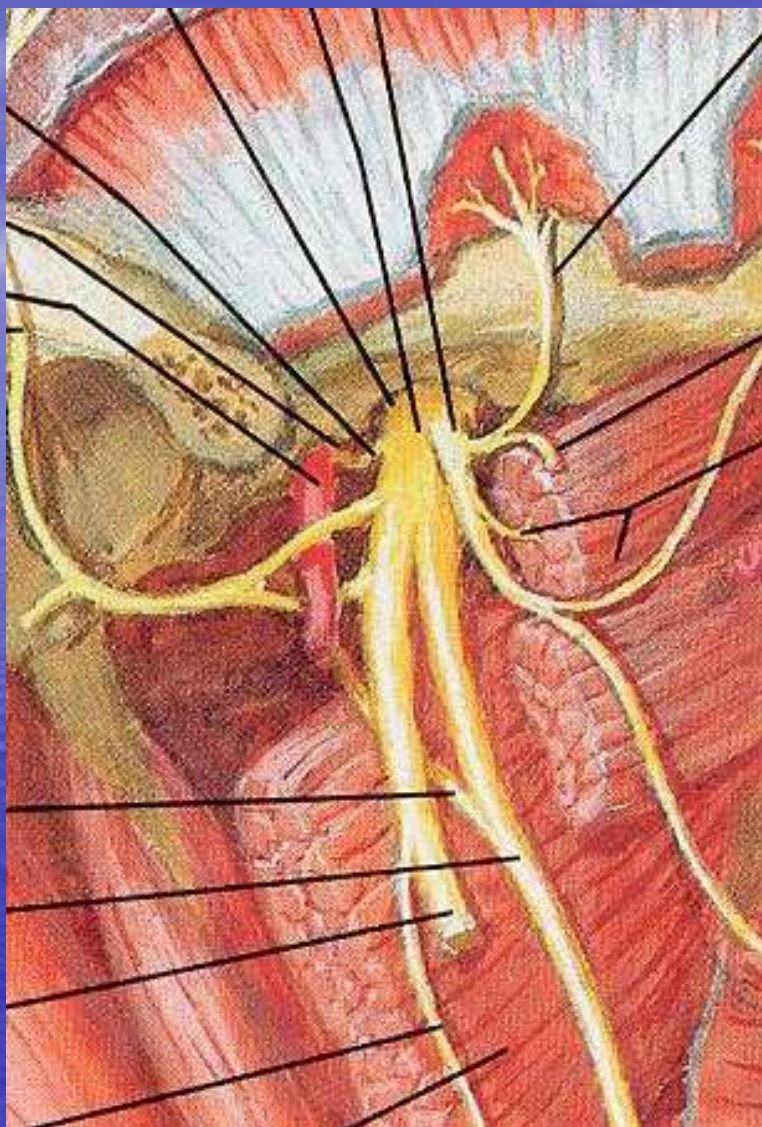
- **Branches of the anterior division:**
 - Buccal nerve (long buccal and buccinator):
 - Travels anteriorly and lateral to the lateral pterygoid muscle
 - Gives branches to the deep temporal (temporalis muscle), masseter, and lateral pterygoid muscle

Mandibular division (V3):

- **Branches of the anterior division:**

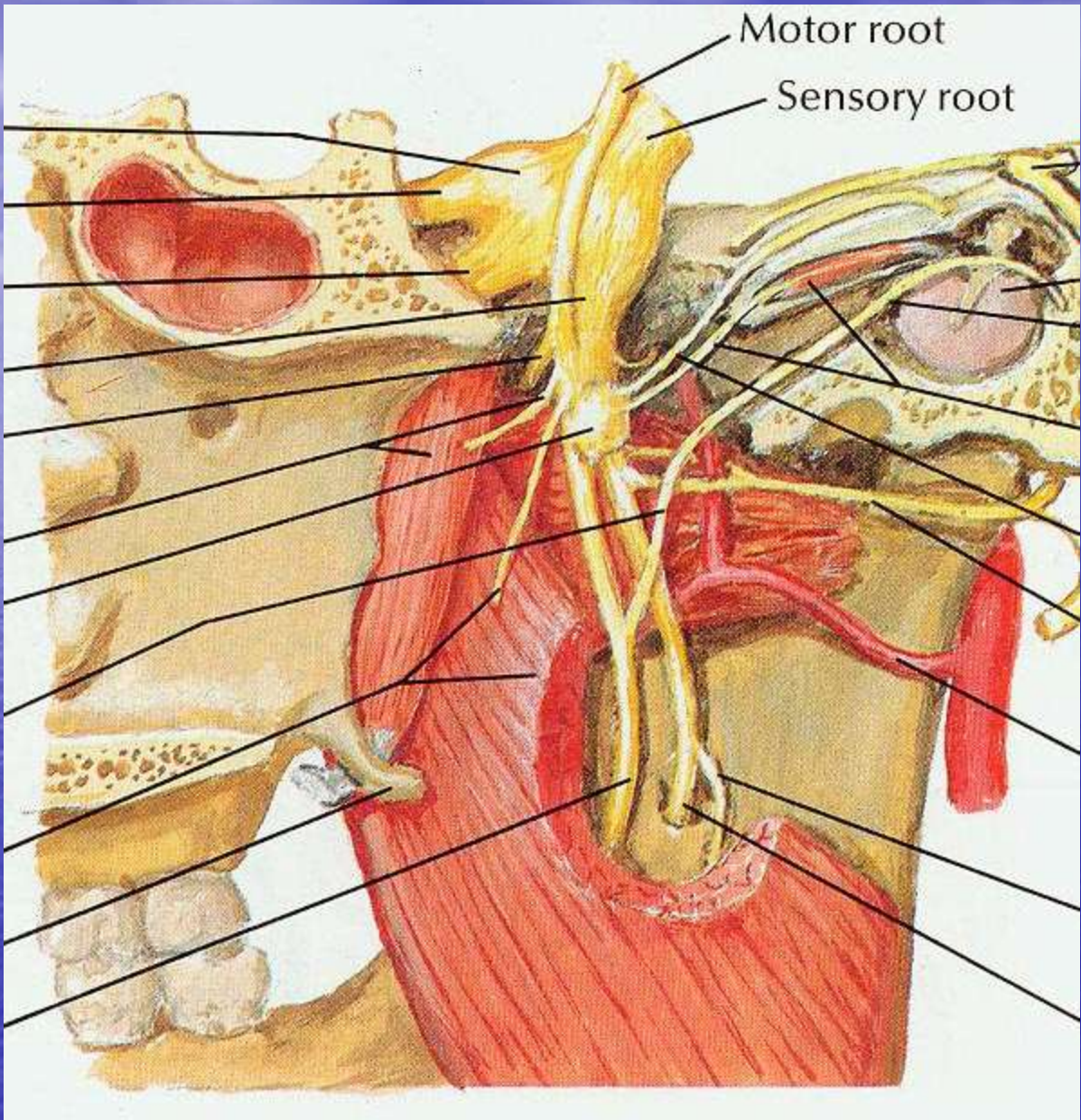
- Buccal nerve (long buccal and buccinator):

- Continues to travel in antero-lateral direction
- At level of the mandibular 3rd molar, branches exit through the buccinator and provide innervation to the skin of the cheek
- Branches also stay within the retromandibular triangle providing sensory innervation to the buccal gingiva of the mandibular molars and buccal vestibule



Mandibular division (V3):

- **Branches of the posterior division:**
 - Travels inferior and medial to the lateral pterygoid
 - Divisions:
 - Auriculotemporal
 - Lingual
 - Inferior alveolar



Mandibular division (V3):

- **Branches of the posterior division:**
 - Auriculotemporal: all sensory
 - Transverses the upper part of the parotid gland and posterior portion of the zygomatic arch
 - Branches:
 - Communicates with facial nerve to provide sensory innervation to the skin over areas of the zygomatic, buccal, and mandibular
 - Communicates with the otic ganglion for sensory, secretory, and vasomotor fibers to the parotid

Mandibular division (V3):

- **Branches of the posterior division:**
 - Auriculotemporal: all sensory
 - Branches:
 - Anterior auricular- skin over helix and tragus
 - External auditory meatus- skin over meatus and tympanic membrane
 - Articular- posterior TMJ
 - Superficial temporal- skin over temporal region

Mandibular division (V3):

- **Branches of the posterior division:**

- Lingual:

- Lies between ramus and medial pterygoid within the pterygomandibular raphe
- Lies inferior and medial to the mandibular 3rd molar alveolus
- Provides sensation to anterior 2/3rds of tongue, lingual gingiva, floor of mouth mucosa, and gustation (chorda tympani)

Mandibular division (V3):

- **Branches of the posterior division:**

- Inferior alveolar:

- Travels medial to the lateral pterygoid and latero-posterior to the lingual nerve
- Enters mandible at the lingula
- Accompanied by the inferior alveolar artery and vein (artery anterior to nerve)
- Travels within the inferior alveolar canal until the mental foramen
- Mylohyoid nerve- motor branch prior to entry into lingula

Mandibular division (V3):

- **Branches of the posterior division:**
 - Inferior alveolar:
 - Provides innervation to the mandibular alveolus, buccal gingiva from premolar teeth anteriorly, and the pulpal tissue of all mandibular teeth on side blocked
 - Terminal branches
 - Incisive nerve- remains within inferior alveolar canal from mental foramen to midline
 - Mental nerve- exits mental foramen and divides into 3 branches to innervate the skin of the chin, lower lip and labial mucosa

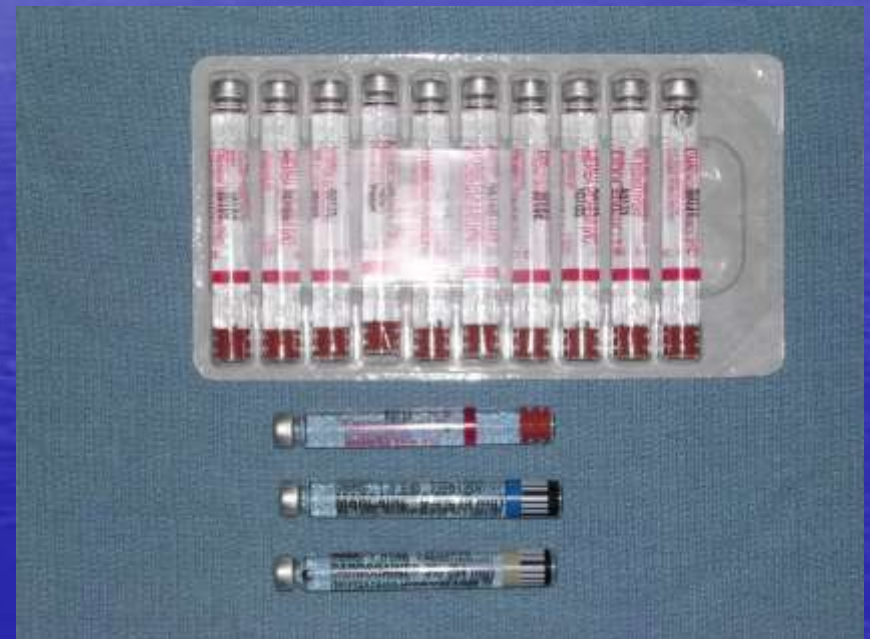

Local anesthetic instruments:

- Anesthetic carpules
- Syringe
- Needle
- Mouth props
- Retractors

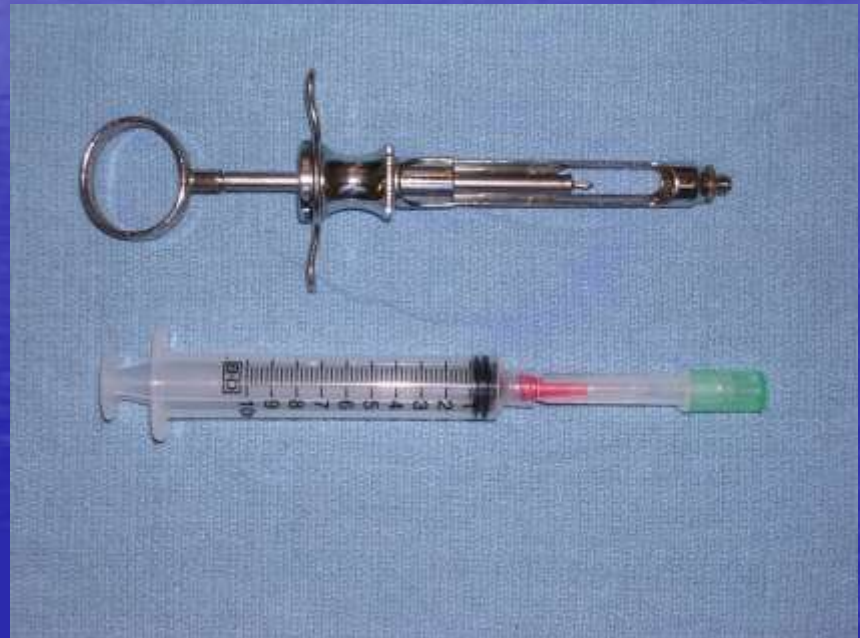Local anesthetic instruments:

- Carpules:
 - 1.7 or 1.8cc
 - Pre-made in blister packs or canisters
 - Contains preservatives for epinephrine and local anesthetics



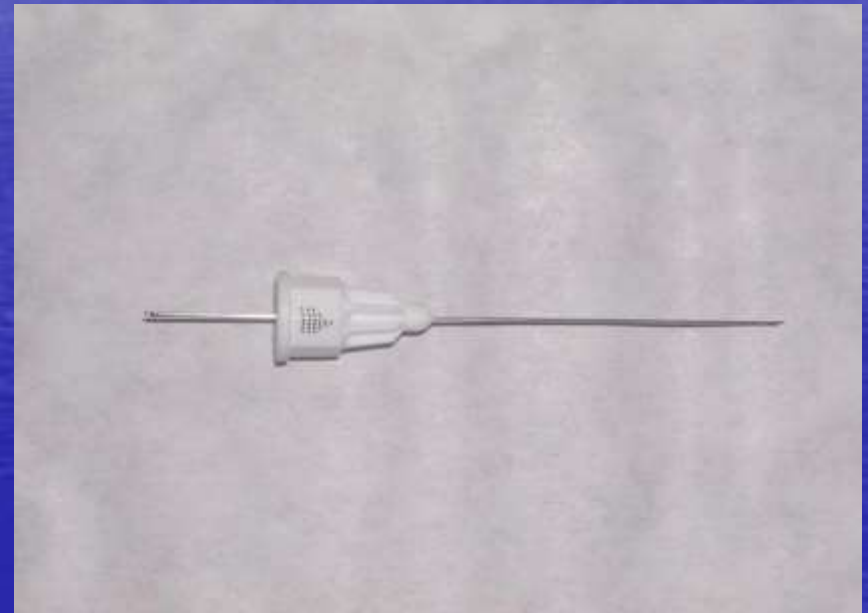
Local anesthetic instruments:

- Syringe
 - Aspirating type
 - Non-aspirating type



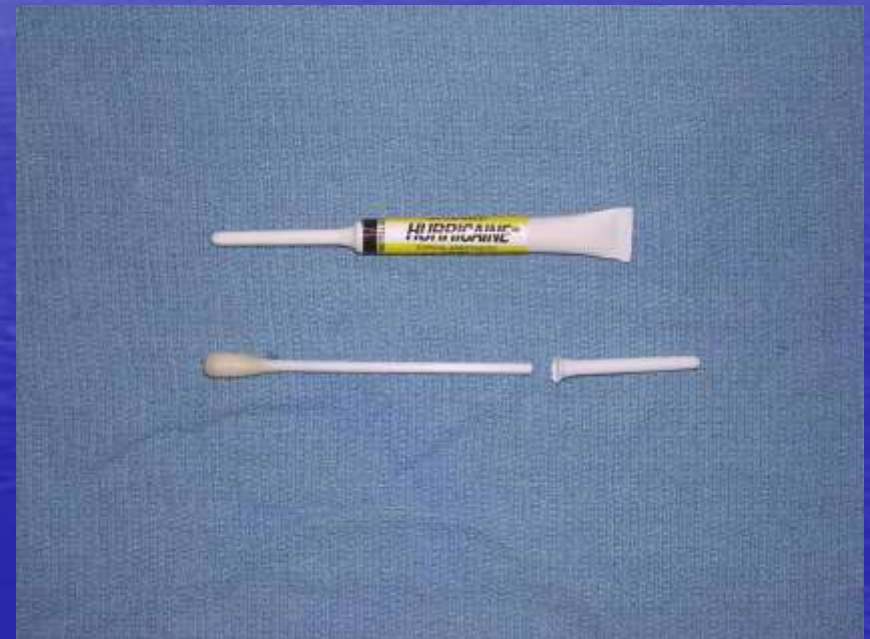Local anesthetic instruments:

- Needle:
 - Multiple gauges used
 - 25g
 - 27g *used at UTMB
 - 30g
 - Length:
 - Short- 26mm
 - Long- 36mm *used at UTMB
 - Monobeveled

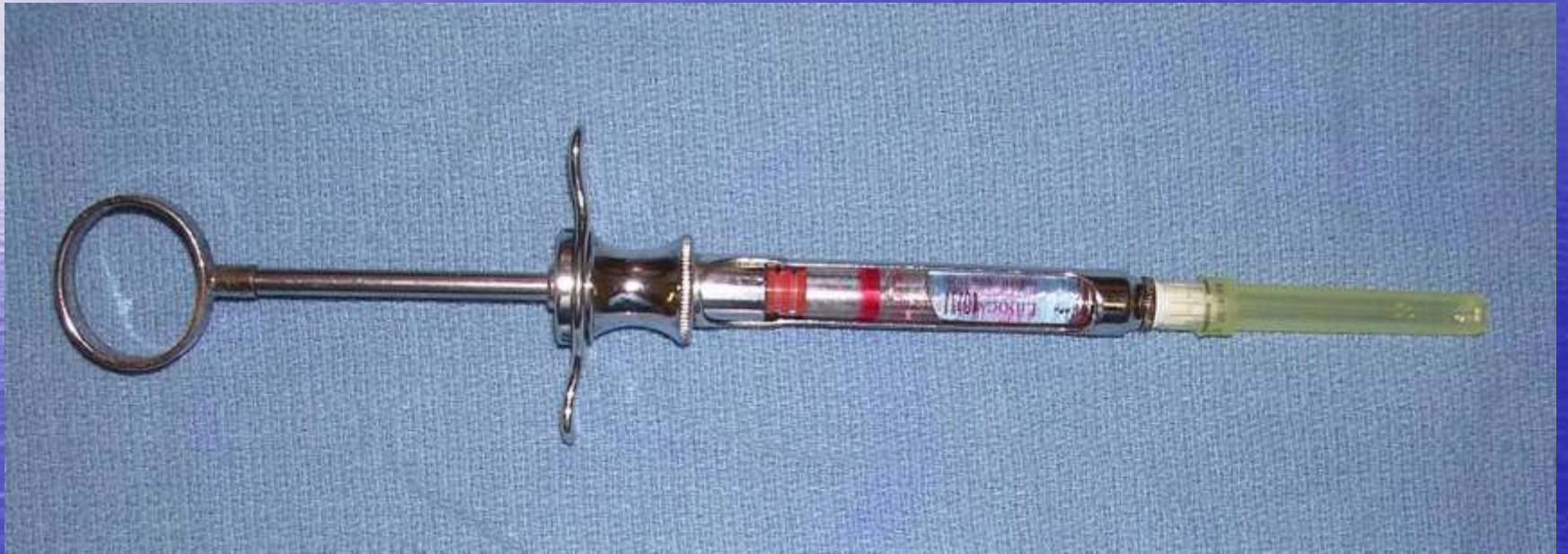

Local anesthetic instruments:

- Topical anesthetic:
 - Used prior to local anesthetic injection to decrease discomfort in non-sedated patients
 - Generally benzocaine (20%)



Local anesthetic instruments:



Maxillary anesthesia:

- 3 major types of injections can be performed in the maxilla for pain control
 - Local infiltration
 - Field block
 - Nerve block

Maxillary anesthesia:

- **Infiltration:**

- Able to be performed in the maxilla due to the thin cortical nature of the bone
- Involves injecting to tissue immediately around surgical site
 - Supraperiosteal injections
 - Intraseptal injections
 - Periodontal ligament injections

Maxillary anesthesia:

- **Field blocks:**
 - Local anesthetic deposited near a larger terminal branch of a nerve
 - Periapical injections-

Maxillary anesthesia:

- **Nerve blocks:**

- Local anesthetic deposited near main nerve trunk and is usually distant from operative site

- Posterior superior alveolar

- Infraorbital

- Middle superior alveolar

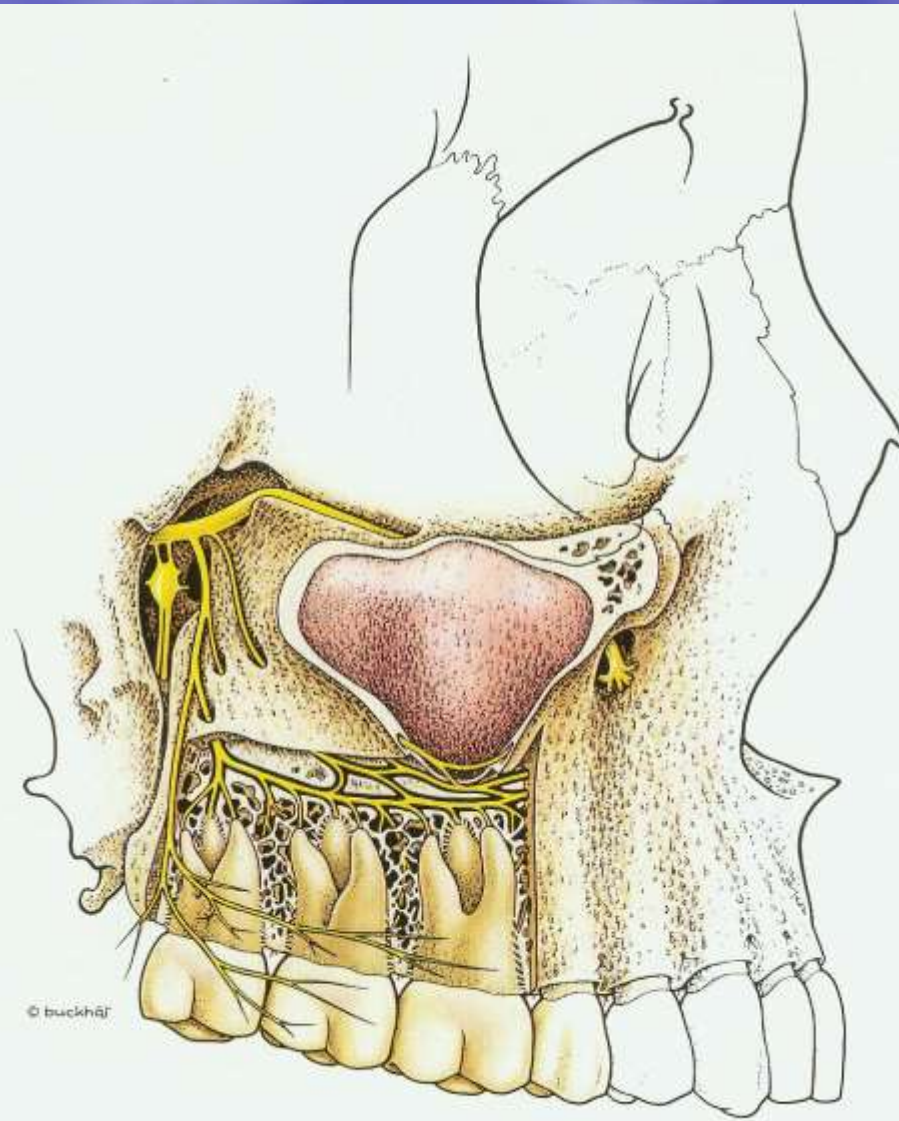
- Greater palatine

- Anterior superior alveolar

- Nasopalatine

Maxillary anesthesia:

- **Posterior superior alveolar nerve block:**
 - Used to anesthetize the pulpal tissue, corresponding alveolar bone, and buccal gingival tissue to the maxillary 1st, 2nd, and 3rd molars.



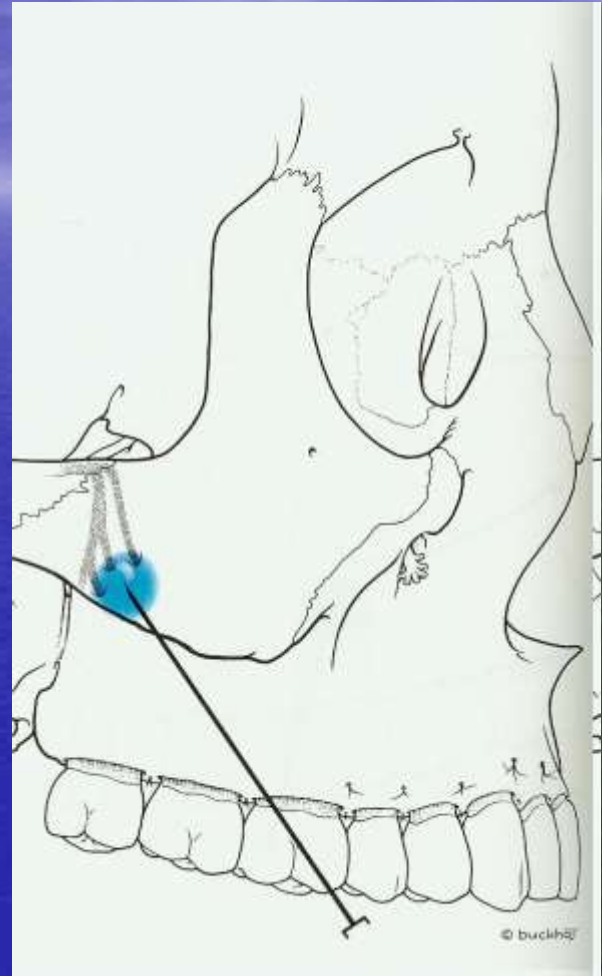
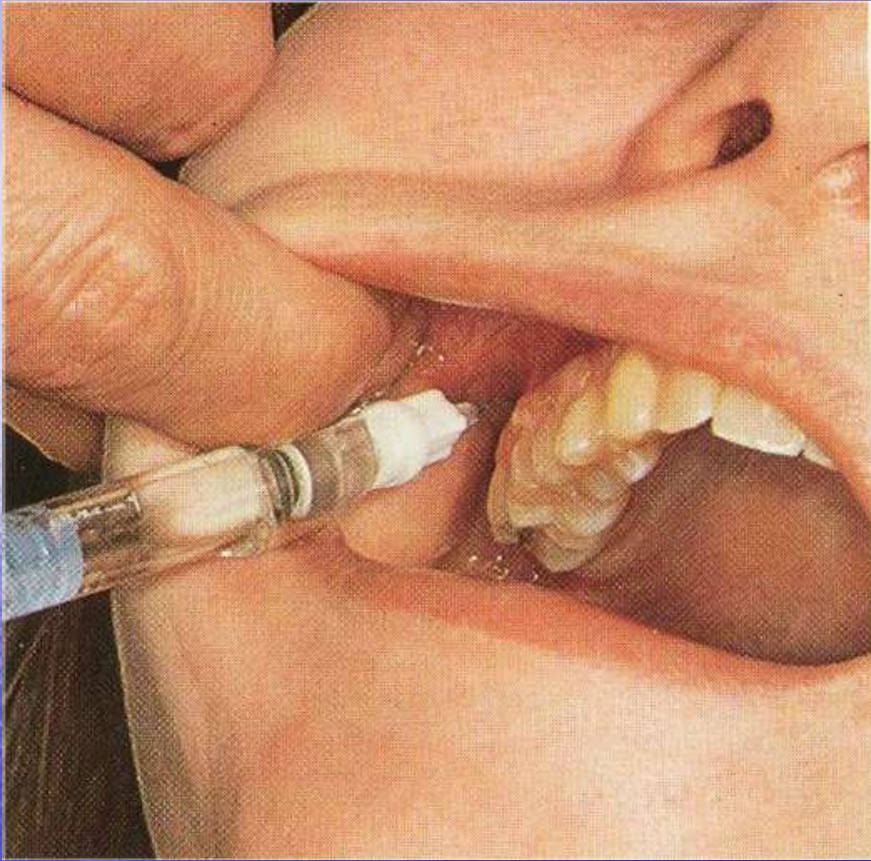
© buckhär

Maxillary anesthesia:

- **Posterior superior alveolar nerve block:**

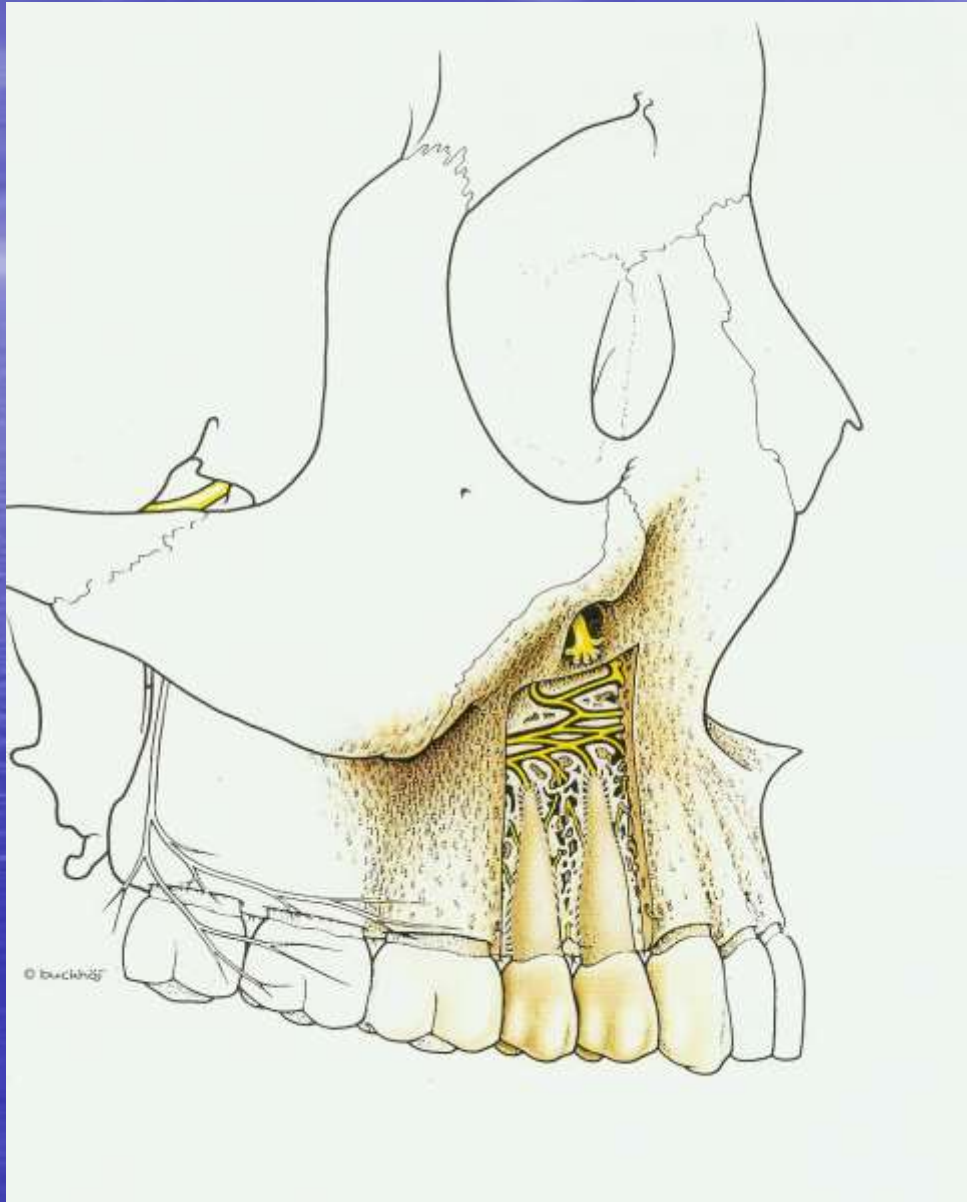
- Technique

- Area of insertion- height of mucobuccal fold between 1st and 2nd molar
- Angle at 45° superiorly and medially
- No resistance should be felt (if bony contact angle is to medial, reposition laterally)
- Insert about 15-20mm
- Aspirate then inject if negative



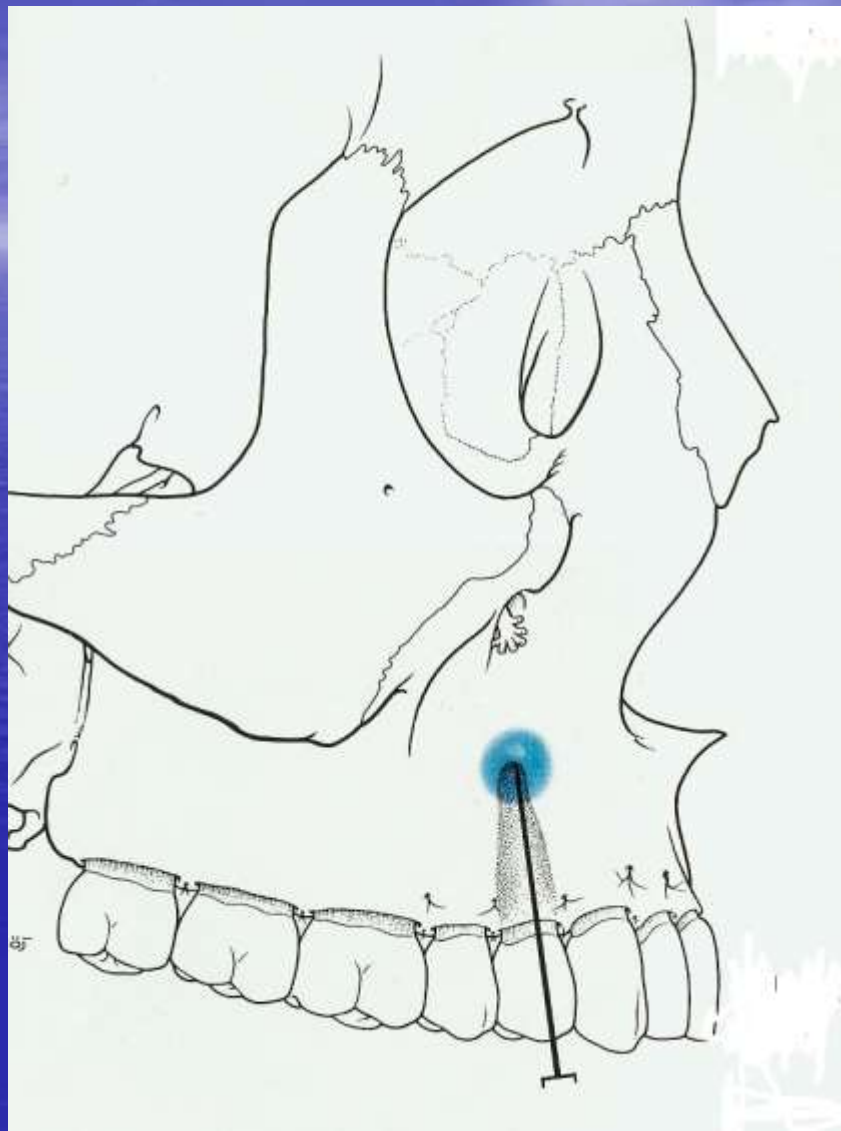
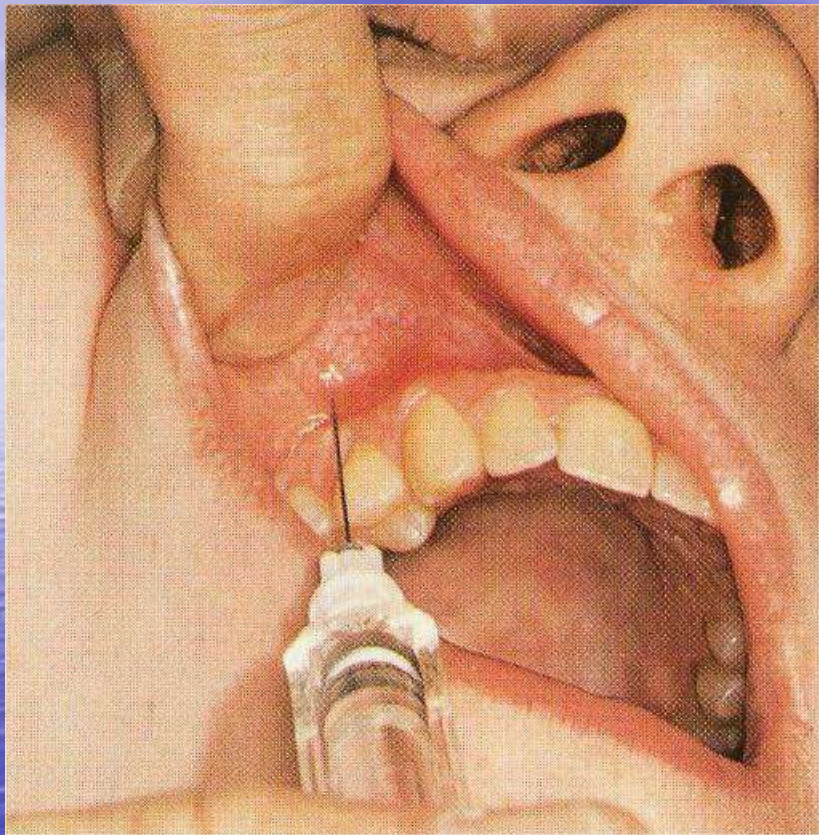
Maxillary anesthesia:

- **Middle superior alveolar nerve block:**
 - Used to anesthetize the maxillary premolars, corresponding alveolus, and buccal gingival tissue
 - Present in about 28% of the population
 - Used if the infraorbital block fails to anesthetize premolars



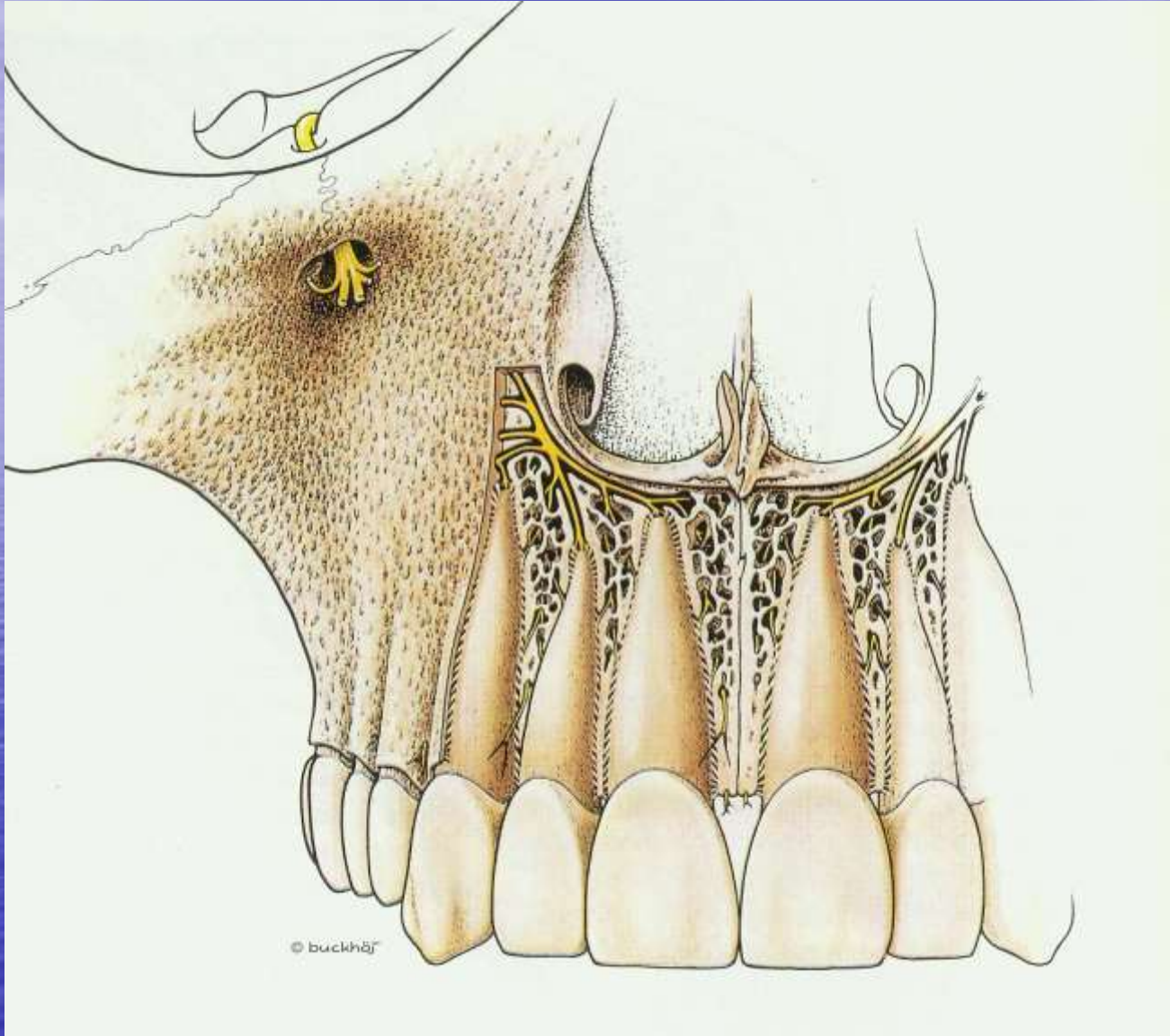
Maxillary anesthesia:

- Middle superior alveolar nerve block:
 - Technique:
 - Area of insertion is height of mucobuccal fold in area of 1st/2nd premolars
 - Insert around 10-15mm
 - Inject around 0.9-1.2cc



Maxillary anesthesia:

- **Anterior superior alveolar nerve block:**
 - Used to anesthetize the maxillary canine, lateral incisor, central incisor, alveolus, and buccal gingiva

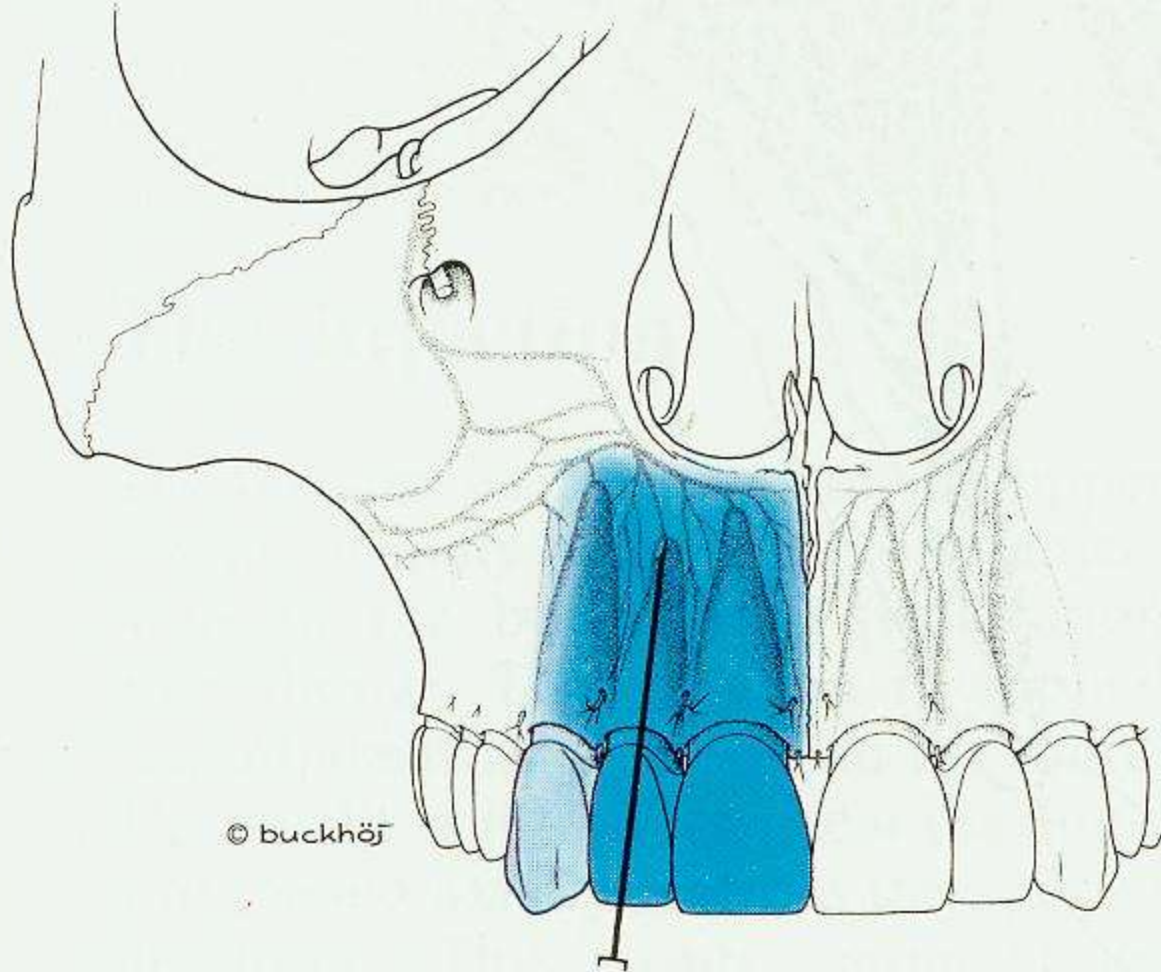


Maxillary anesthesia:

- Anterior superior alveolar nerve block:

- Technique:

- Area of insertion is height of mucobuccal fold in area of lateral incisor and canine
- Insert around 10-15mm
- Inject around 0.9-1.2cc

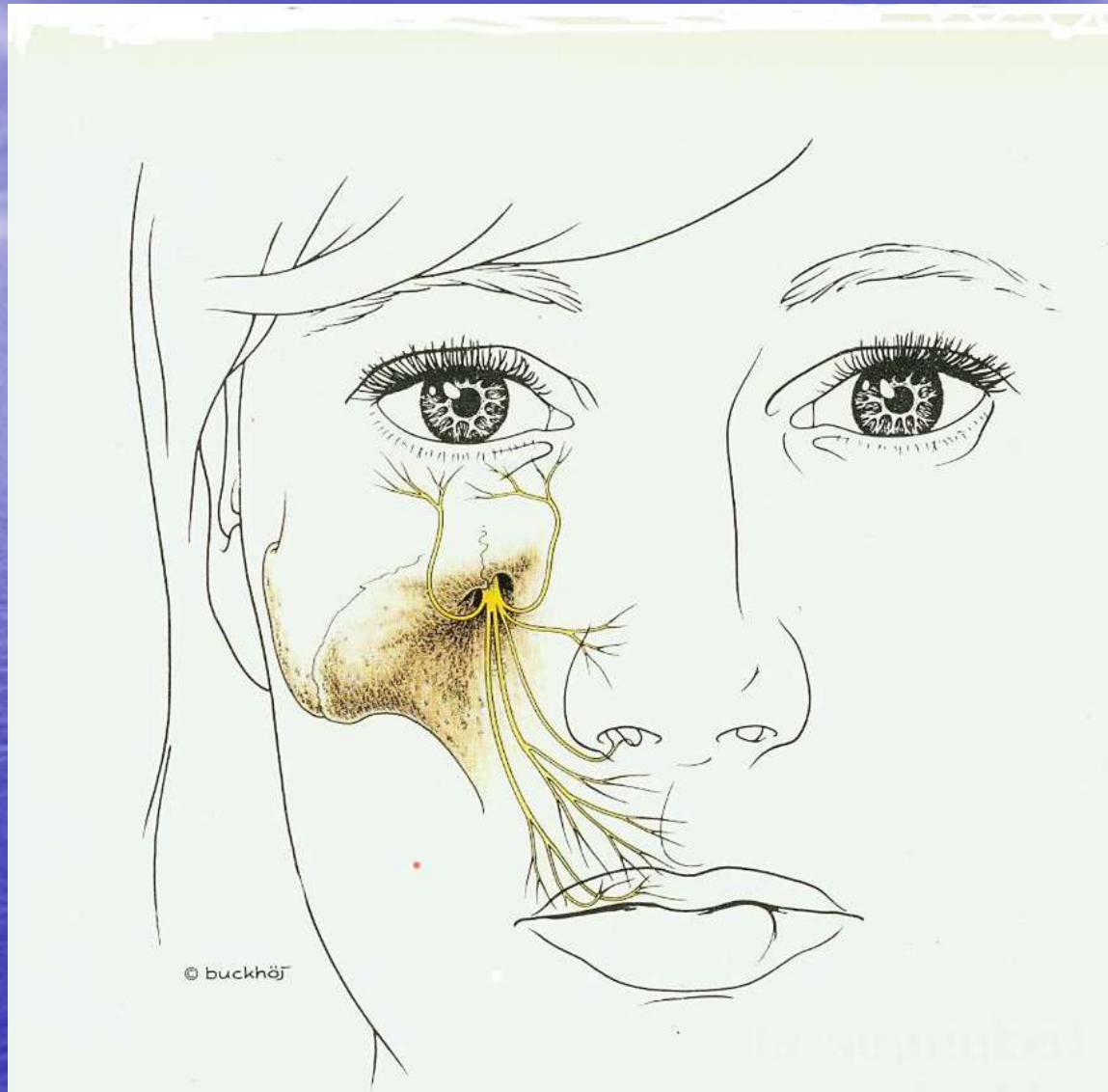

© buckhøj

Maxillary anesthesia:

- **Infraorbital nerve block:**

- Used to anesthetize the maxillary 1st and 2nd premolars, canine, lateral incisor, central incisor, corresponding alveolar bone, and buccal gingiva
- Combines MSA and ASA blocks
- Will also cause anesthesia to the lower eyelid, lateral aspect of nasal skin tissue, and skin of infraorbital region



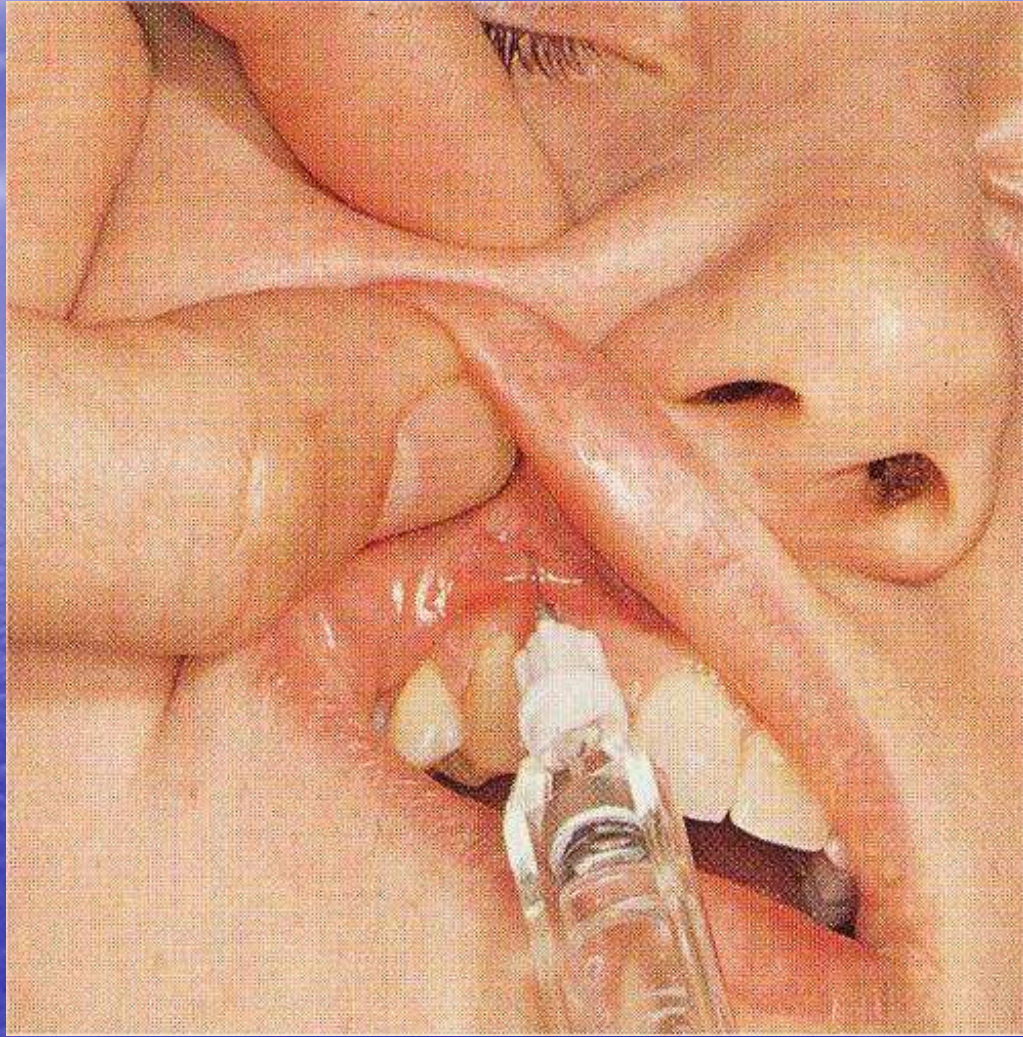
© buckhäj

Maxillary anesthesia:

- **Infraorbital nerve block:**

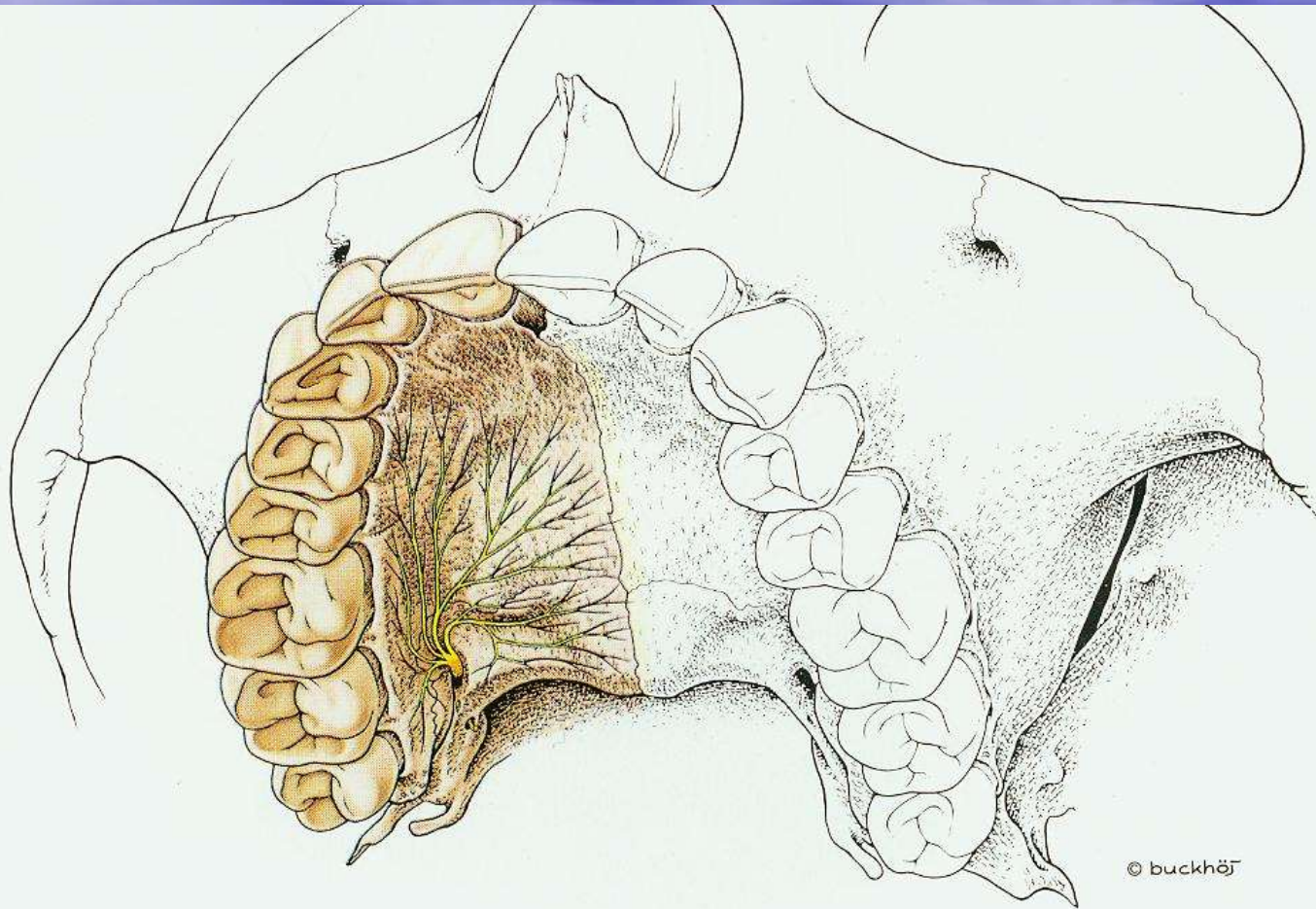
- Technique:

- Palpate infraorbital foramen extra-orally and place thumb or index finger on region
- Retract the upper lip and buccal mucosa
- Area of insertion is the mucobuccal fold of the 1st premolar/canine area
- Contact bone in infraorbital region
- Inject 0.9-1.2cc of local anesthetic



Maxillary anesthesia:

- **Greater palatine nerve block:**
 - Can be used to anesthetize the palatal soft tissue of the teeth posterior to the maxillary canine and corresponding alveolus/hard palate



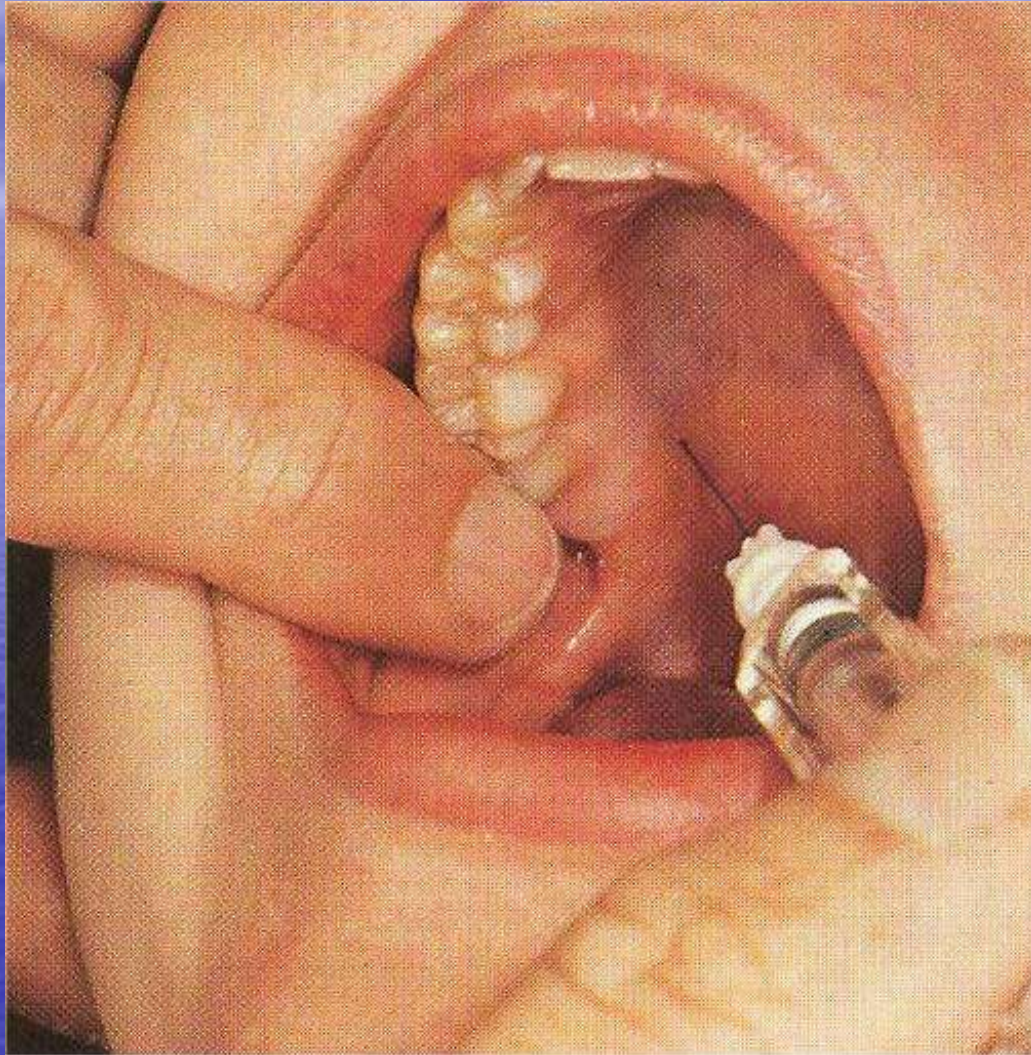
© buckhöt

Maxillary anesthesia:

- **Greater palatine nerve block:**

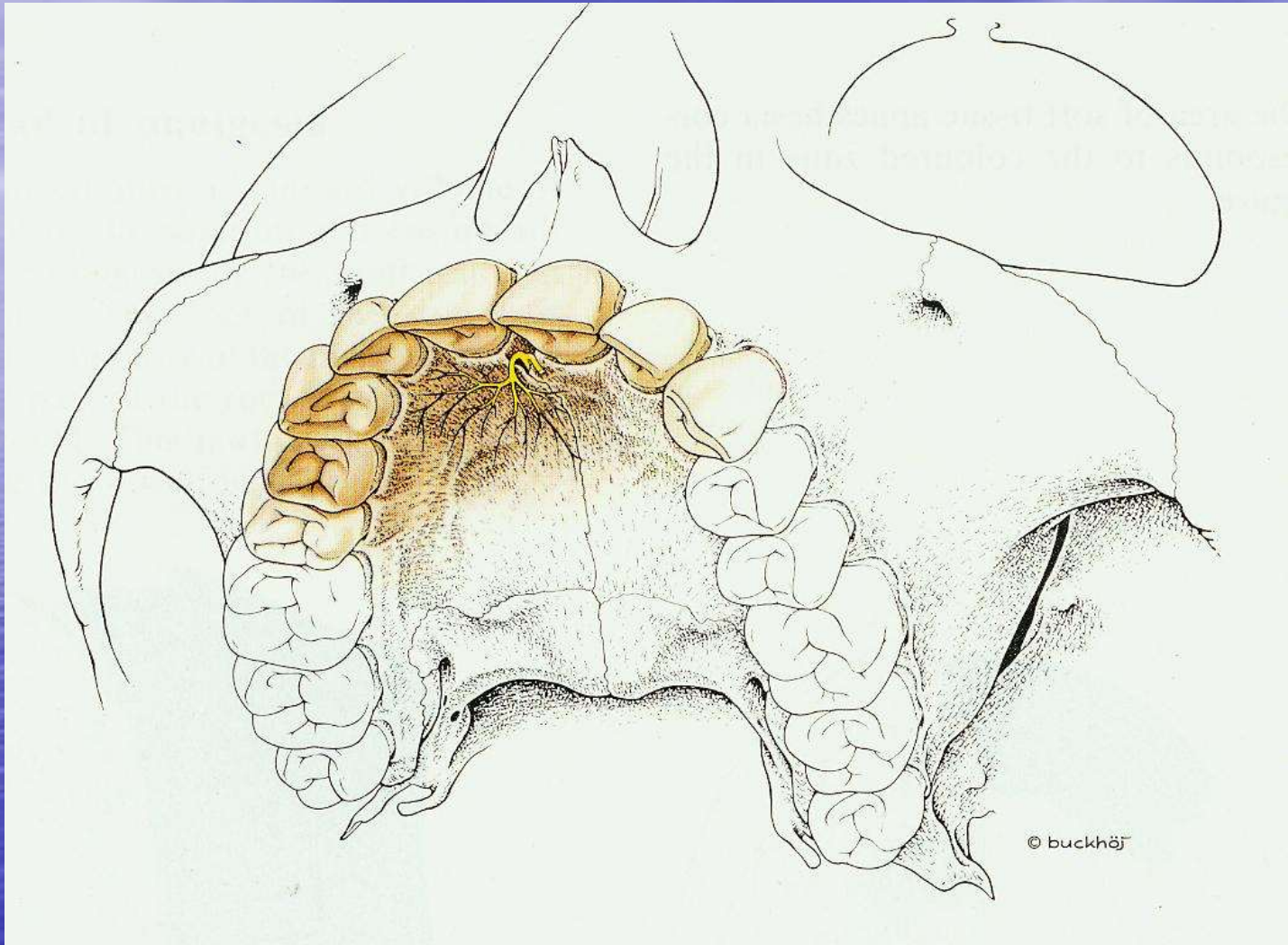
- Technique:

- Area of insertion is ~1cm medial from 1st/2nd maxillary molar on the hard palate
- Palpate with needle to find greater palatine foramen
- Depth is usually less than 10mm
- Utilize pressure with elevator/mirror handle to desensitize region at time of injection
- Inject 0.3-0.5cc of local anesthetic



Maxillary anesthesia:

- **Nasopalatine nerve block:**
 - Can be used to anesthetize the soft and hard tissue of the maxillary anterior palate from canine to canine

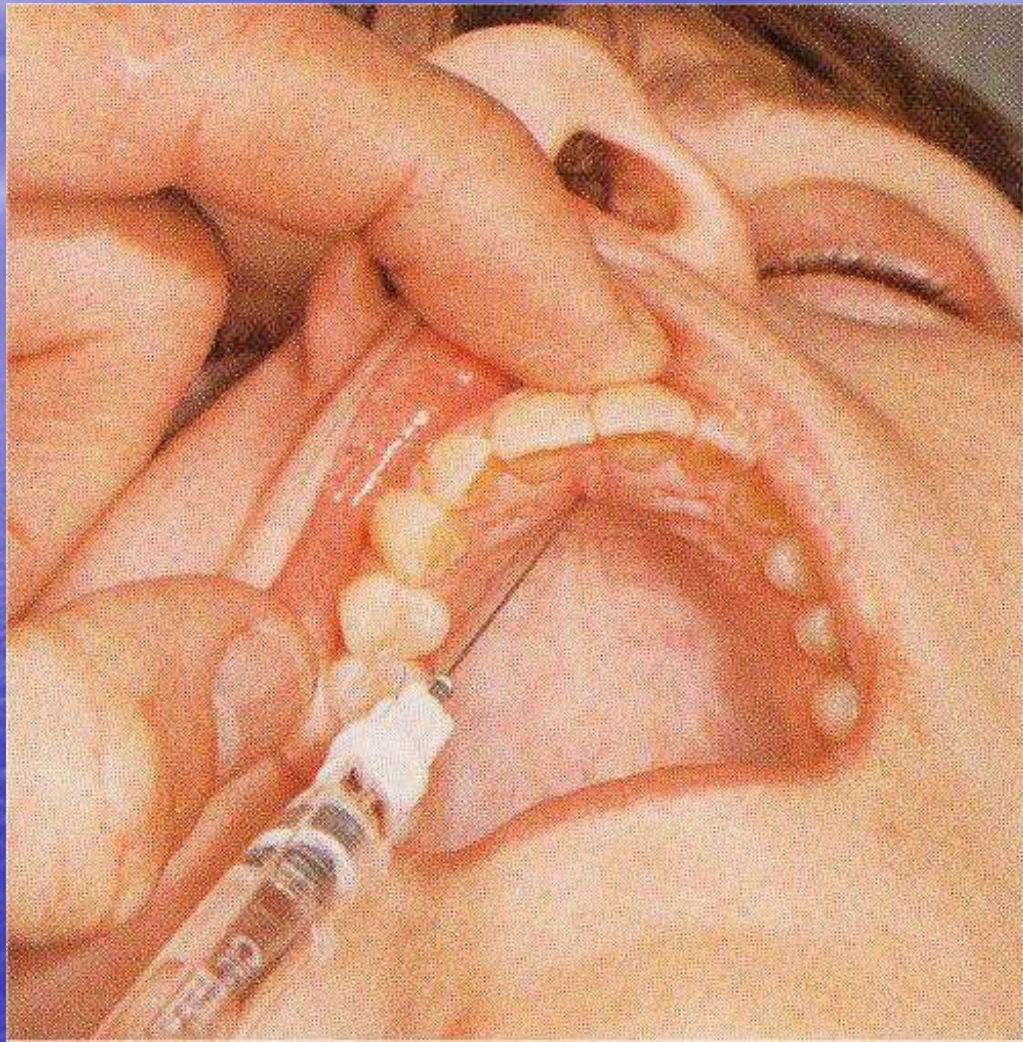


Maxillary anesthesia:

- **Nasopalatine nerve block:**

- Technique:

- Area of insertion is incisive papilla into incisive foramen
- Depth of penetration is less than 10mm
- Inject 0.3-0.5cc of local anesthetic
- Can use pressure over area at time of injection to decrease pain



Maxillary anesthesia:

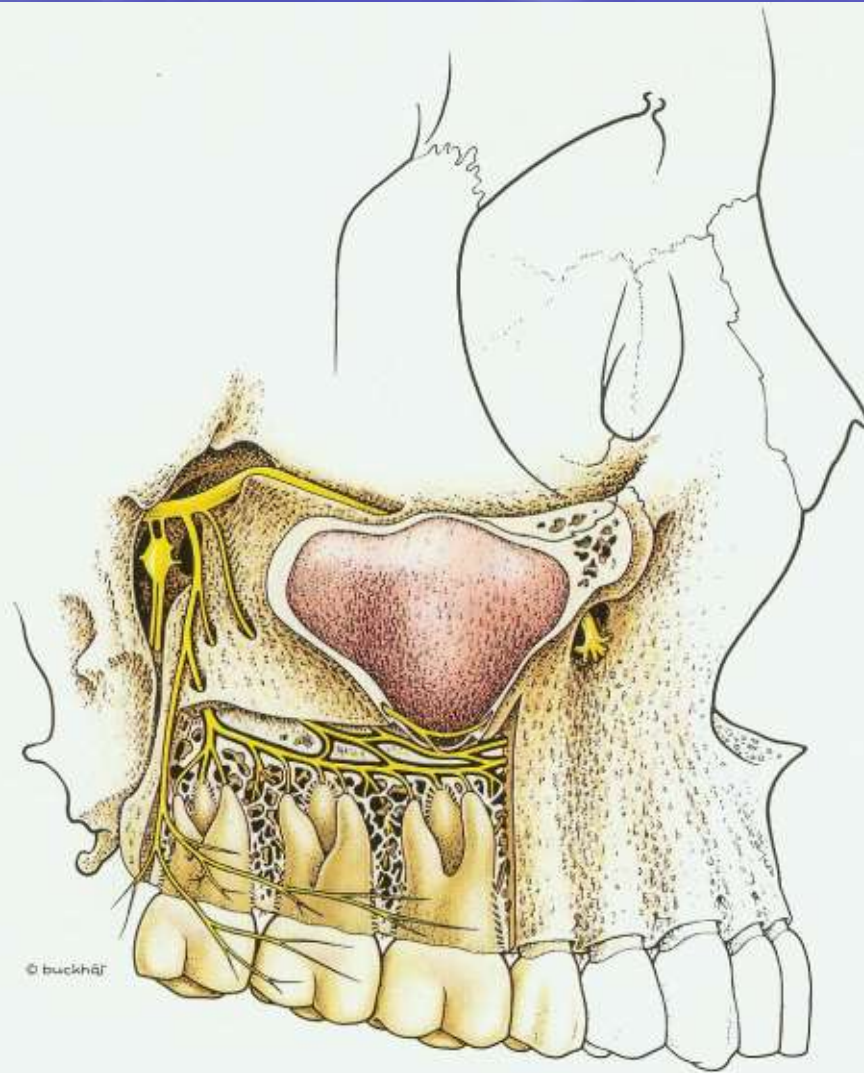
- **Maxillary nerve block (V2 block):**
 - Can be used to anesthetize maxillary teeth, alveolus, hard and soft tissue on the palate, gingiva, and skin of the lower eyelid, lateral aspect of nose, cheek, and upper lip skin and mucosa on side blocked

Maxillary anesthesia:

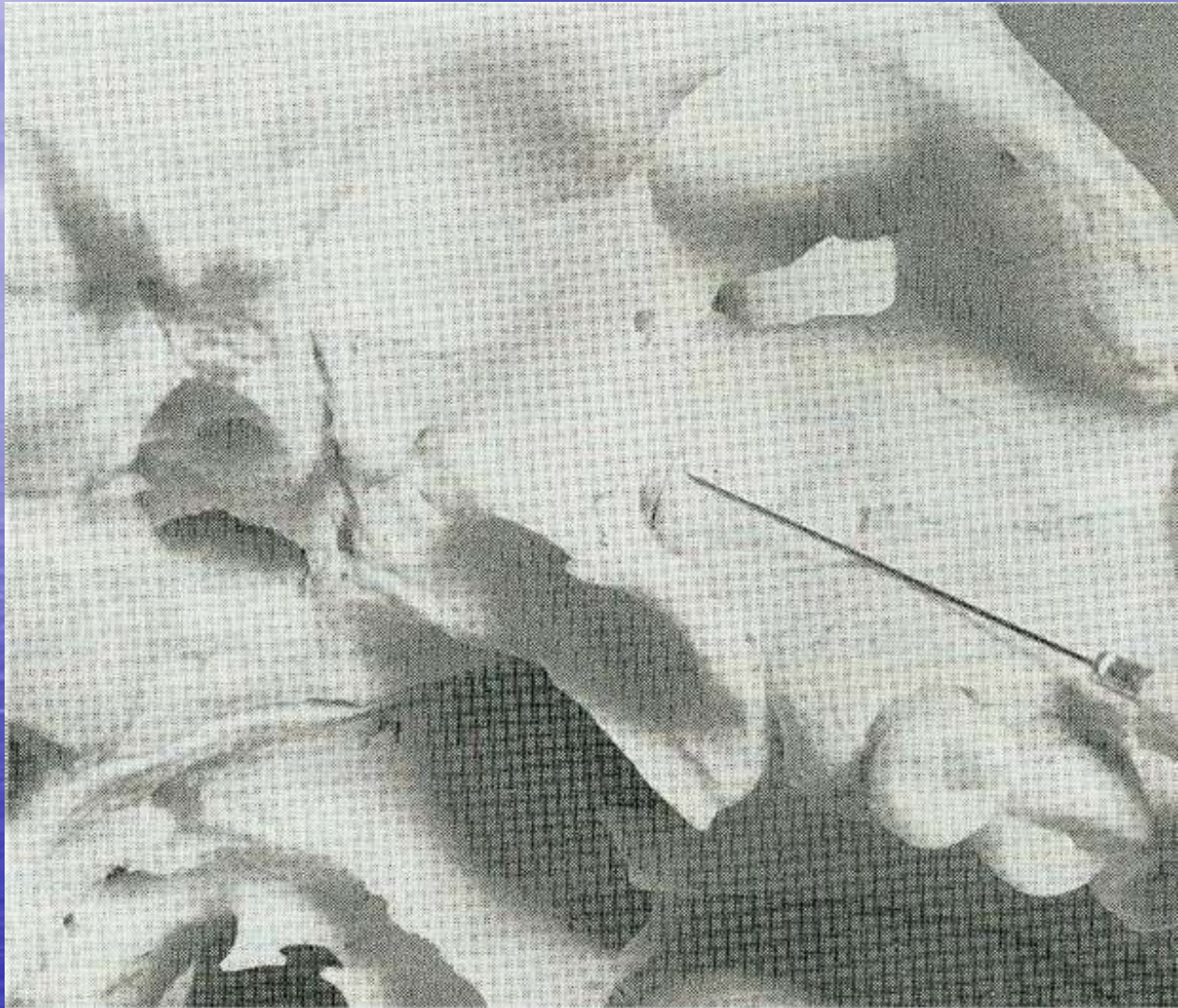
- Maxillary nerve block (V2 block):
 - Two techniques exist for blockade of V2
 - High tuberosity approach
 - Greater palatine canal approach

Maxillary anesthesia:

- **Maxillary nerve block (V2 block):**
 - High tuberosity approach technique:
 - Area of injection is height of mucobuccal fold of maxillary 2nd molar
 - Advance at 45° superior and medial same as in the PSA block
 - Insert needle ~30mm
 - Inject ~1.8cc of local anesthetic

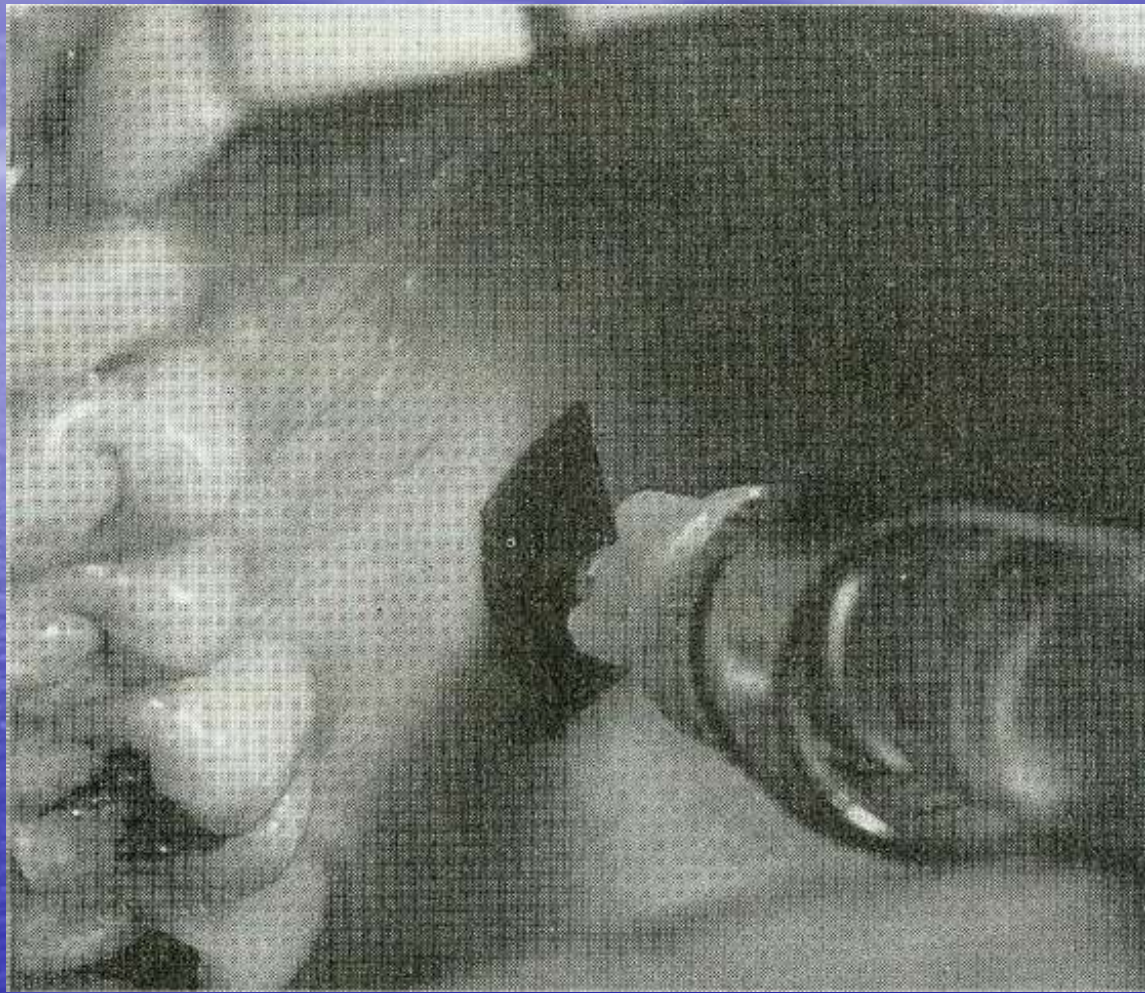

© buckhäf



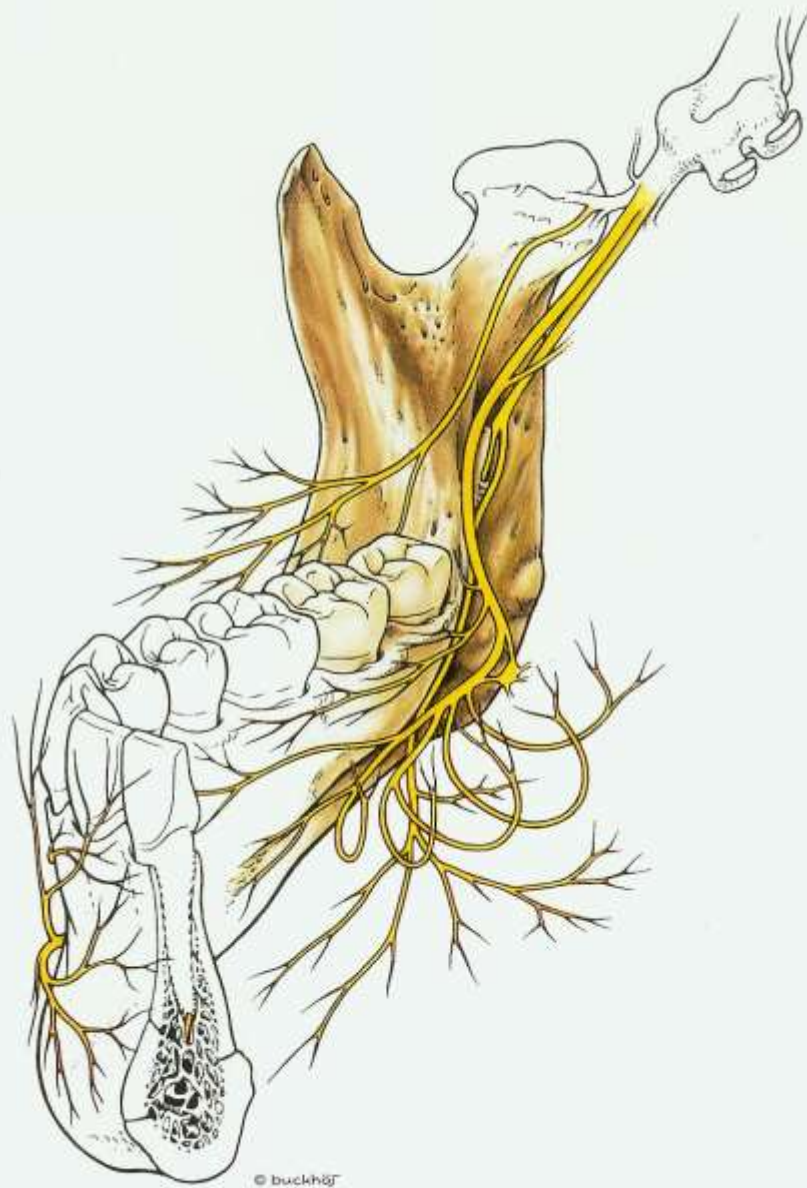
Maxillary anesthesia:

- **Maxillary nerve block (V2 block):**
 - Greater palatine canal technique:
 - Area of insertion is greater palatine canal
 - Target area is the maxillary nerve in the pterygopalatine fossa
 - Perform a greater palatine block and wait 3-5 mins
 - Then insert needle in previous area and walk into greater palatine foramen
 - Insert to depth of ~30mm
 - Inject 1.8cc of local anesthetic



Mandibular anesthesia:

- Infiltration techniques do not work in the adult mandible due to the dense cortical bone
- Nerve blocks are utilized to anesthetize the inferior alveolar, lingual, and buccal nerves
- Provides anesthesia to the pulpal, alveolar, lingual and buccal gingival tissue, and skin of lower lip and medial aspect of chin on side injected



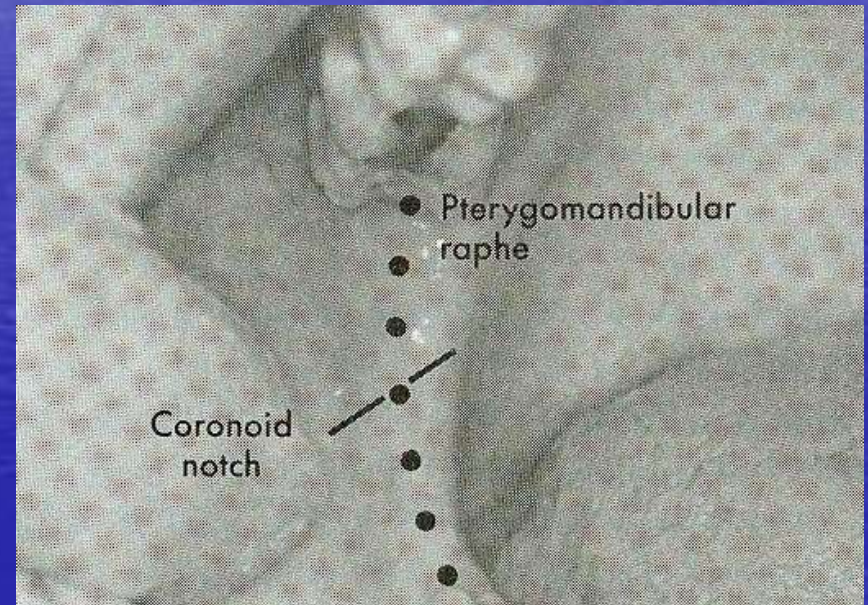
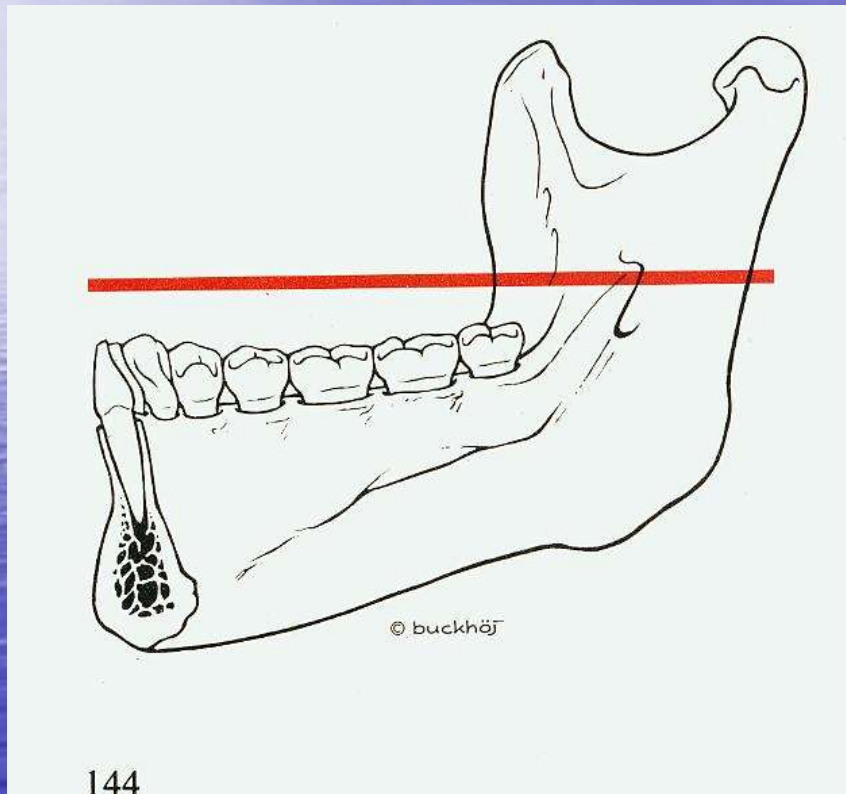
Mandibular anesthesia:

- **Inferior alveolar nerve block (IAN):**
 - Technique involves blocking the inferior alveolar nerve prior to entry into the mandibular lingula on the medial aspect of the mandibular ramus
 - Multiple techniques can be used for the IAN nerve block
 - IAN
 - Akinosi
 - Gow-Gates

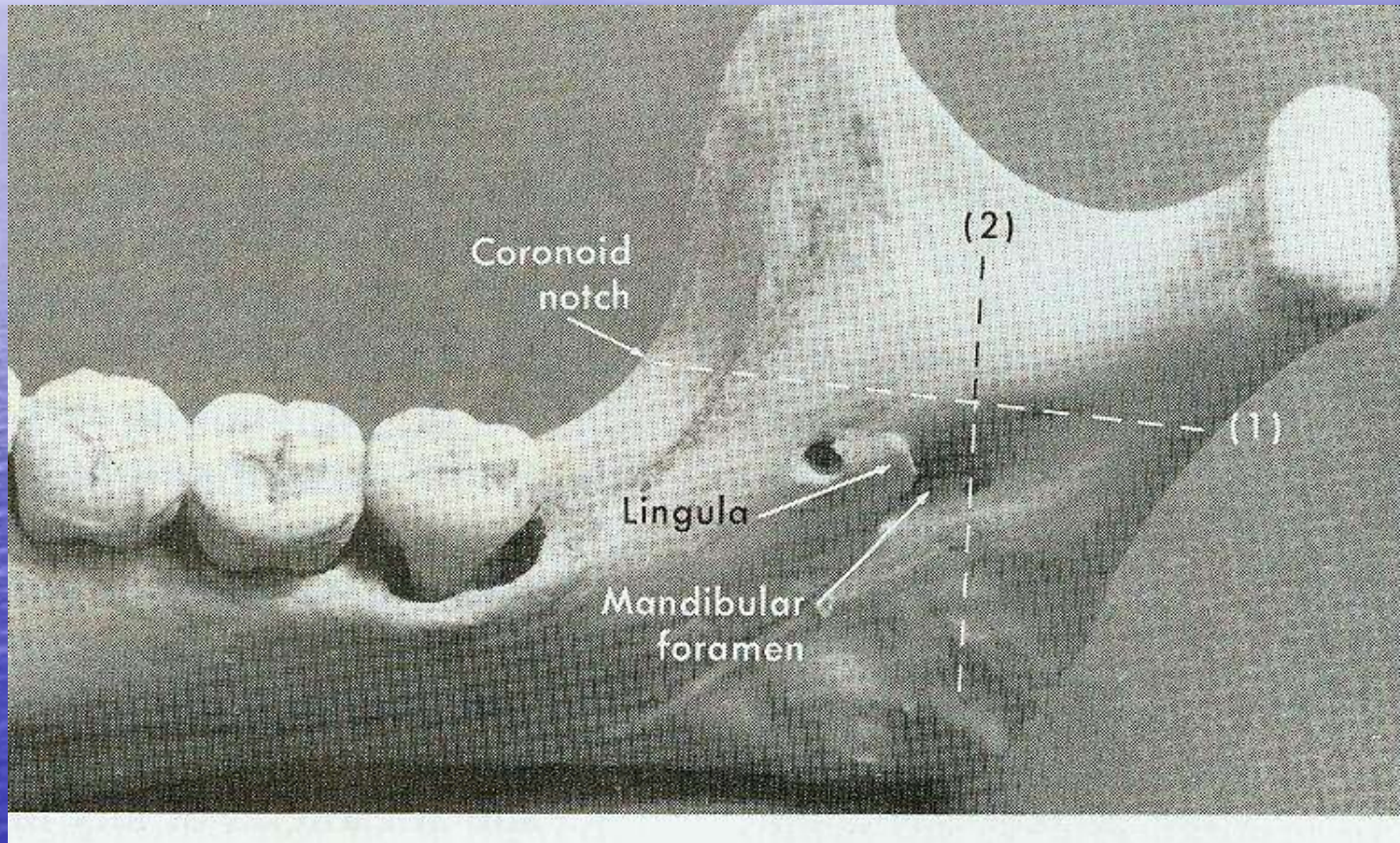
Mandibular anesthesia:

- **Inferior alveolar nerve block (IAN):**
 - Technique:
 - Area of insertion is the mucous membrane on the medial border of the mandibular ramus at the intersection of a horizontal line (height of injection) and vertical line (anteroposterior plane)
 - Height of injection- 6-10 mm above the occlusal table of the mandibular teeth
 - Anteroposterior plane- just lateral to the pterygomandibular raphe

Mandibular anesthesia:

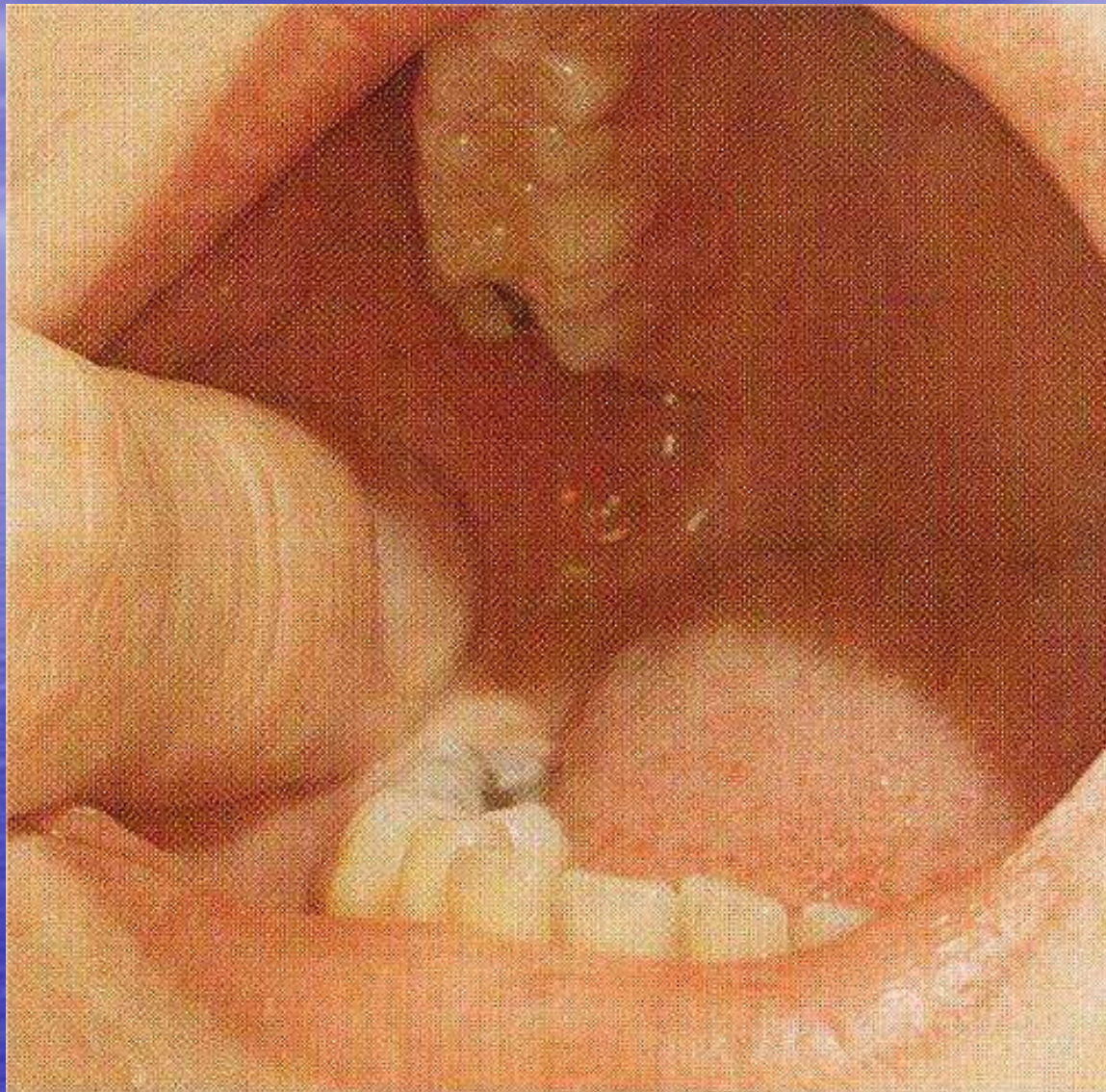


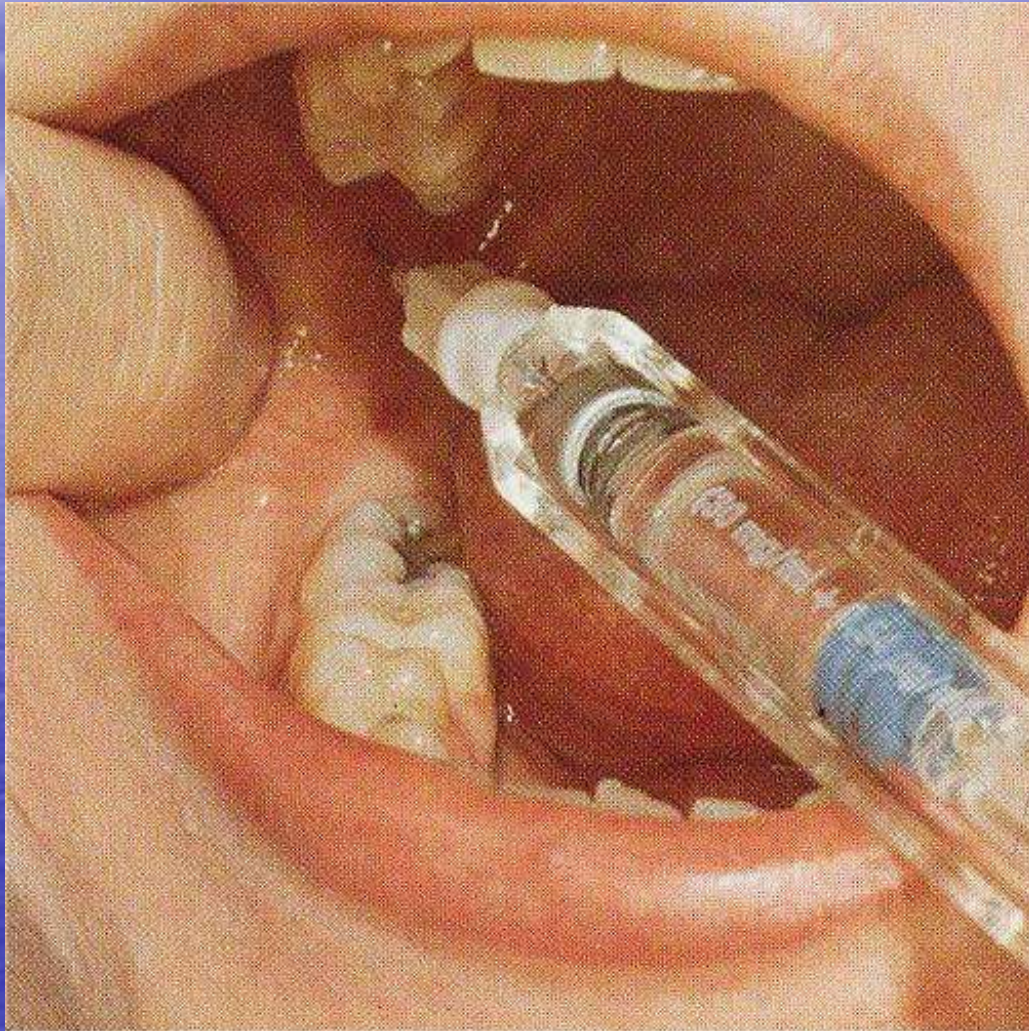
Mandibular anesthesia:



Mandibular anesthesia:

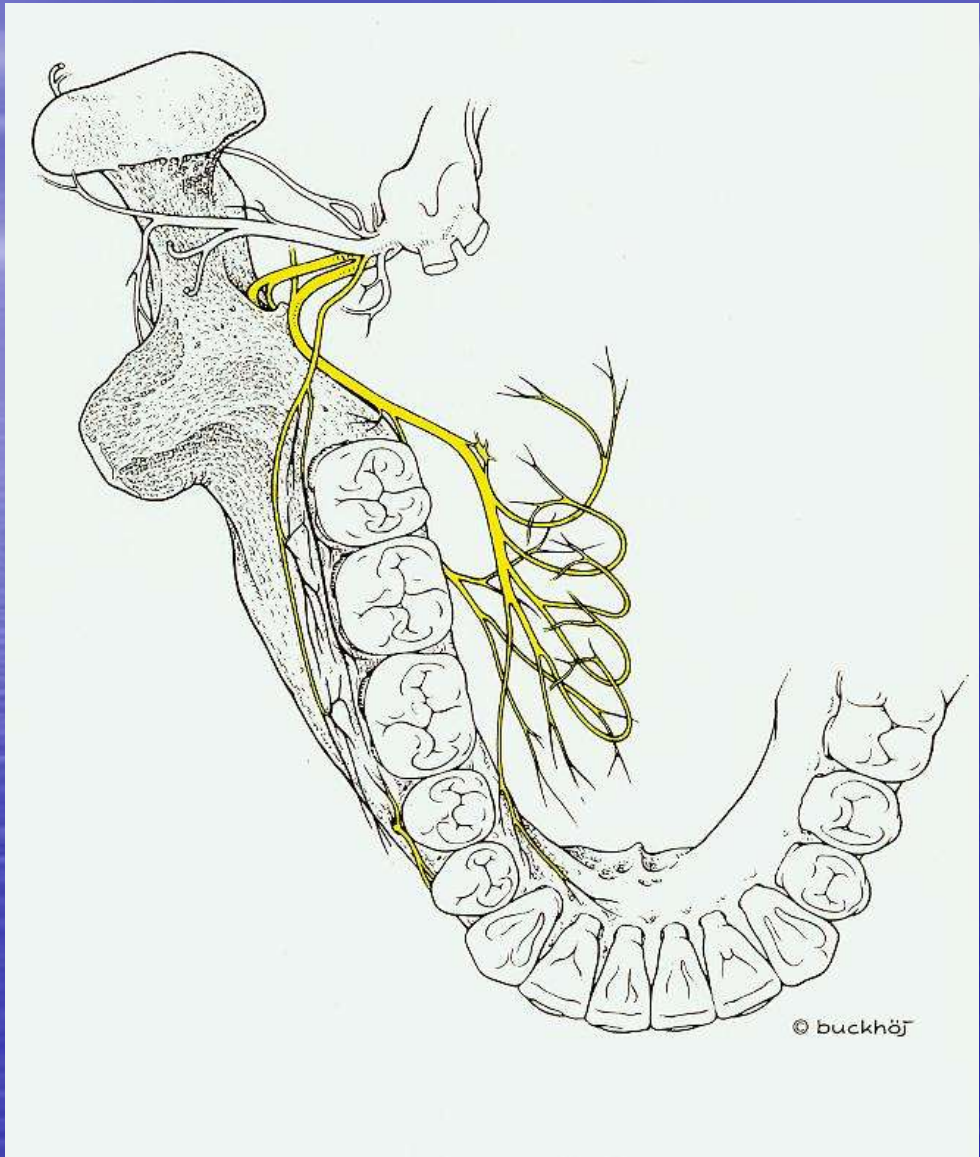
- **Inferior alveolar nerve block (IAN):**
 - Mouth must be open for this technique, best to utilize mouth prop
 - Depth of injection: 25mm
 - Approach area of injection from contralateral premolar region
 - Use the non-dominant hand to retract the buccal soft tissue (thumb in coronoid notch of mandible; index finger on posterior border of extraoral mandible)



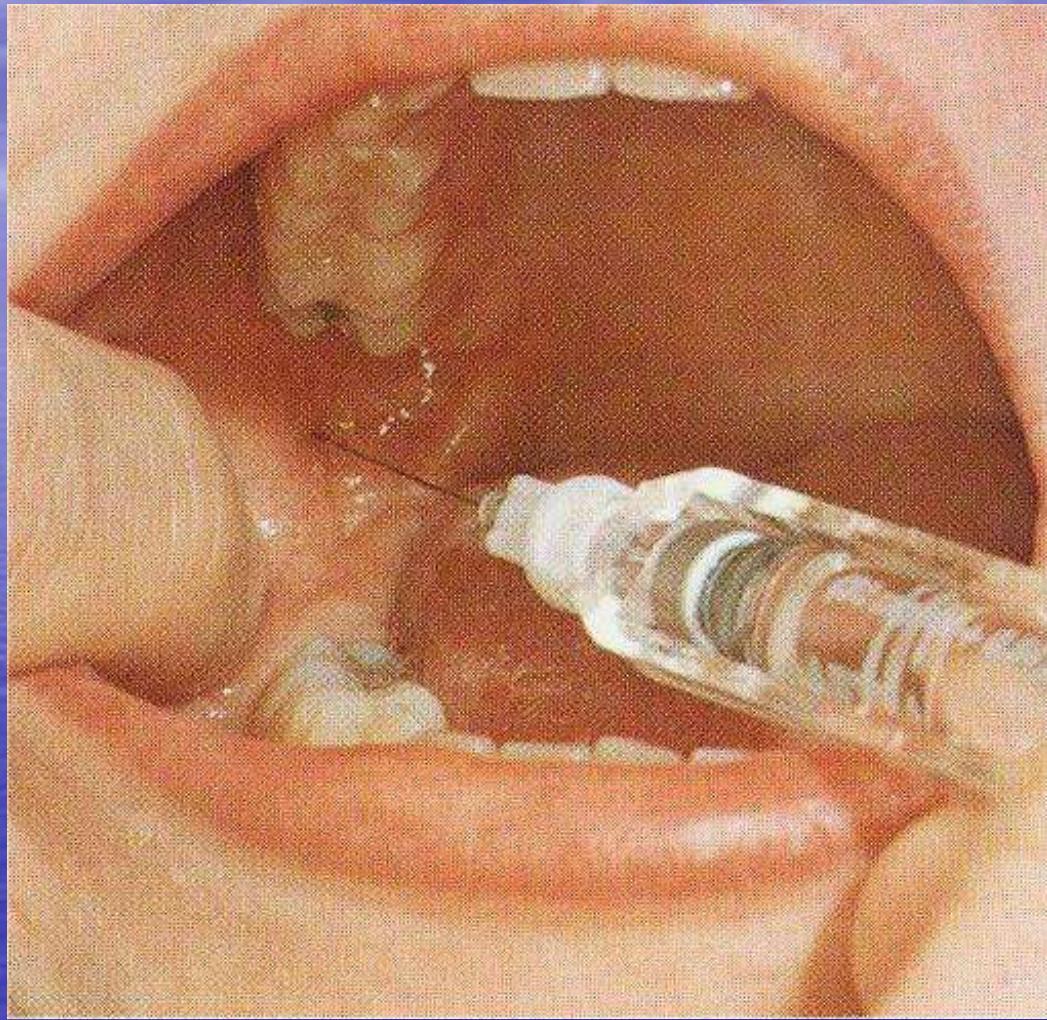


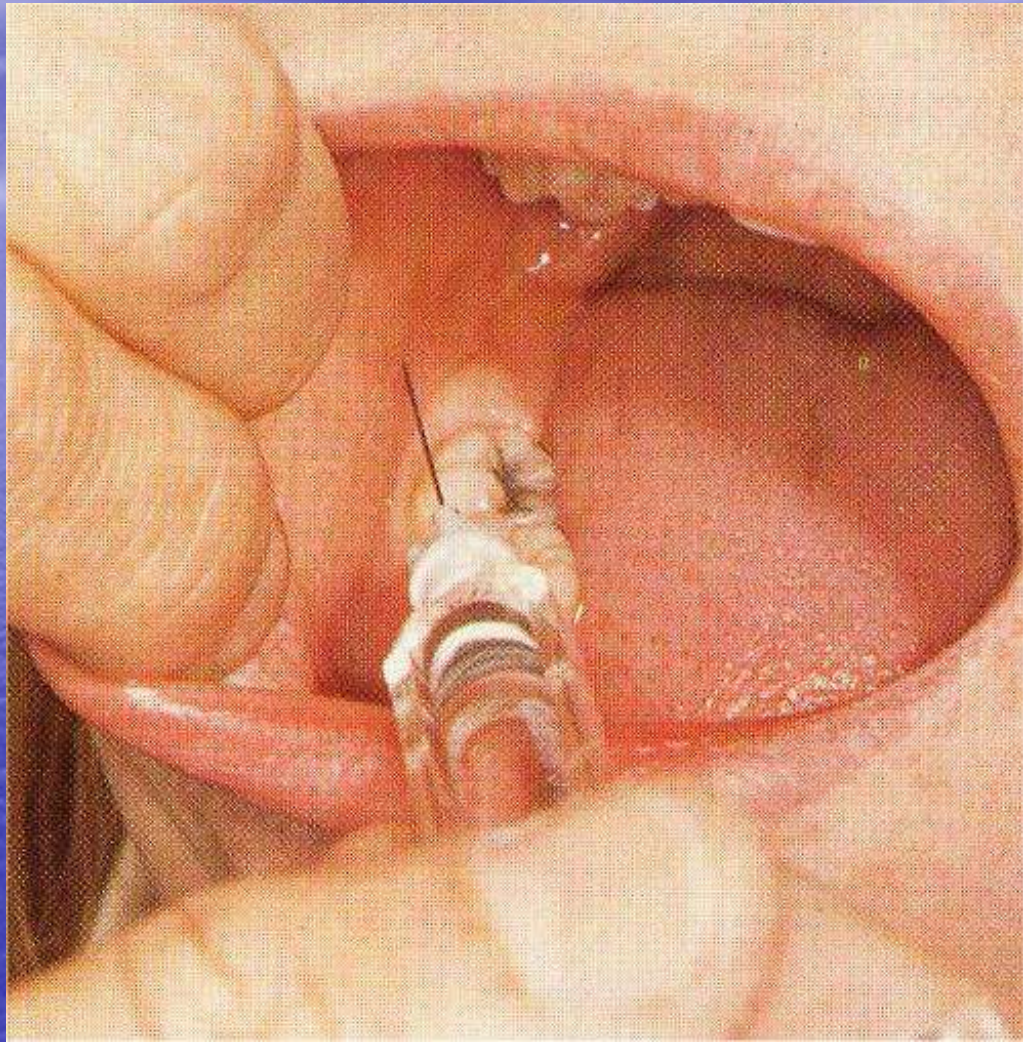Mandibular anesthesia:

- **Inferior alveolar nerve block (IAN):**
 - Inject ~0.5-1.0cc of local anesthetic
 - Continue to inject ~0.5cc on removal from injection site to anesthetize the lingual branch
 - Inject remaining anesthetic into coronoid notch region of the mandible in the mucous membrane distal and buccal to most distal molar to perform a long buccal nerve block



© buckhøj



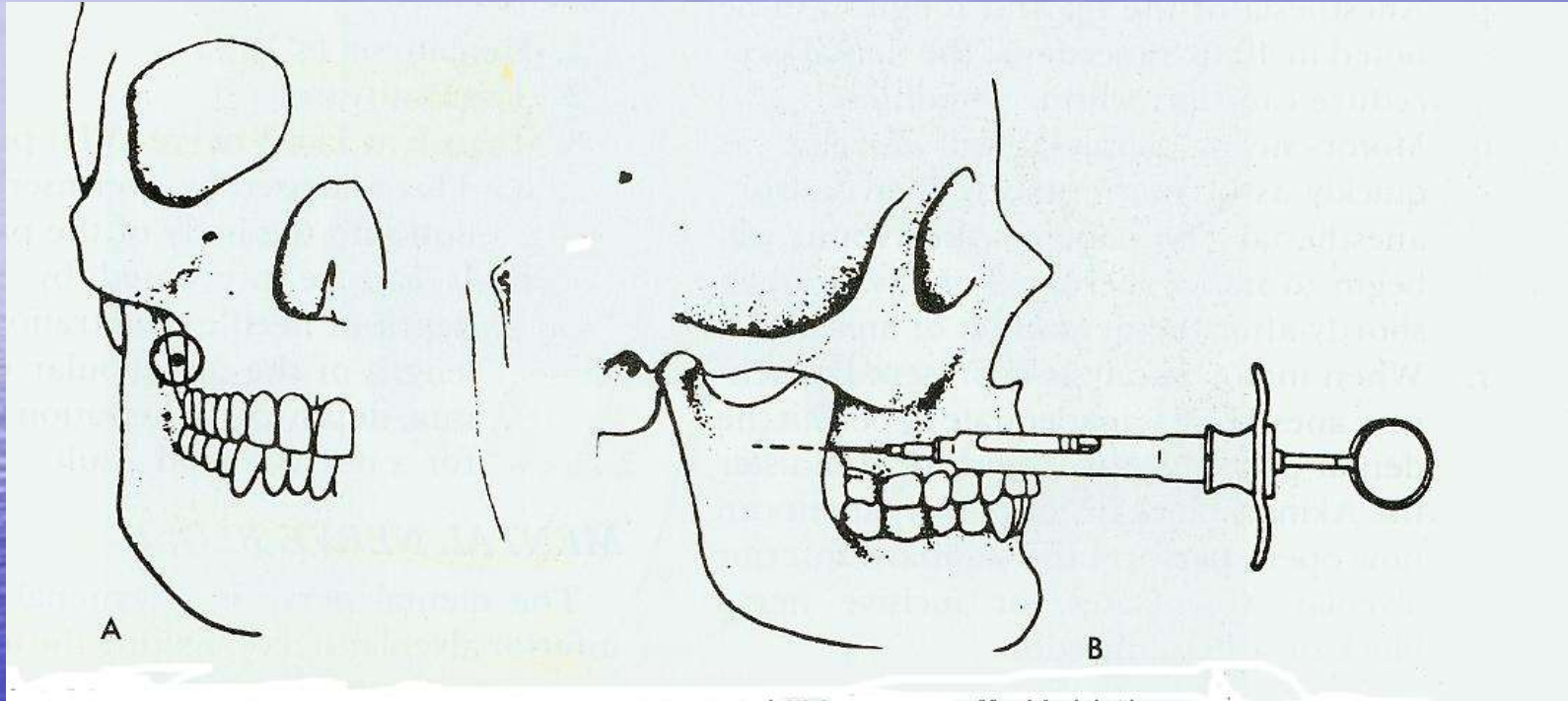


Mandibular anesthesia:

- **Akinosi closed-mouth mandibular block:**
 - Useful technique for infected patients with trismus, fractured mandibles, mentally handicapped individuals, children
 - Provides same areas of anesthesia as the IAN nerve block

Mandibular anesthesia:

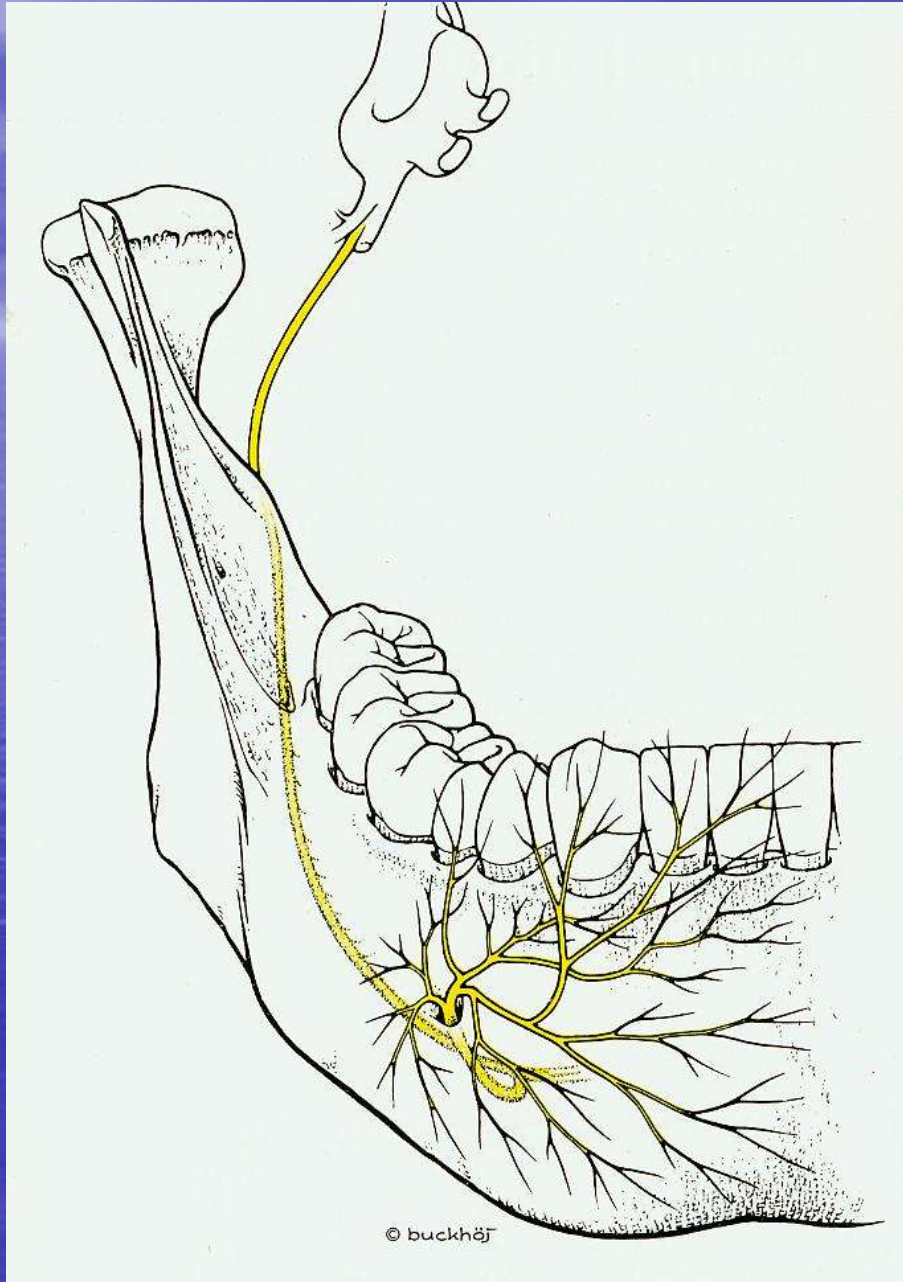
- **Akinosi closed-mouth mandibular block:**
 - Area of insertion: soft tissue overlying the medial border of the mandibular ramus directly adjacent to maxillary tuberosity
 - Inject to depth of 25mm
 - Inject ~1.0-1.5cc of local anesthetic as in the IAN
 - Inject remaining anesthetic in area of long buccal nerve



Mandibular anesthesia:

- **Mental nerve block:**

- Mental and incisive nerves are the terminal branches for the inferior alveolar nerve
- Provides sensory input for the lower lip skin, mucous membrane, pulpal/alveolar tissue for the premolars, canine, and incisors on side blocked

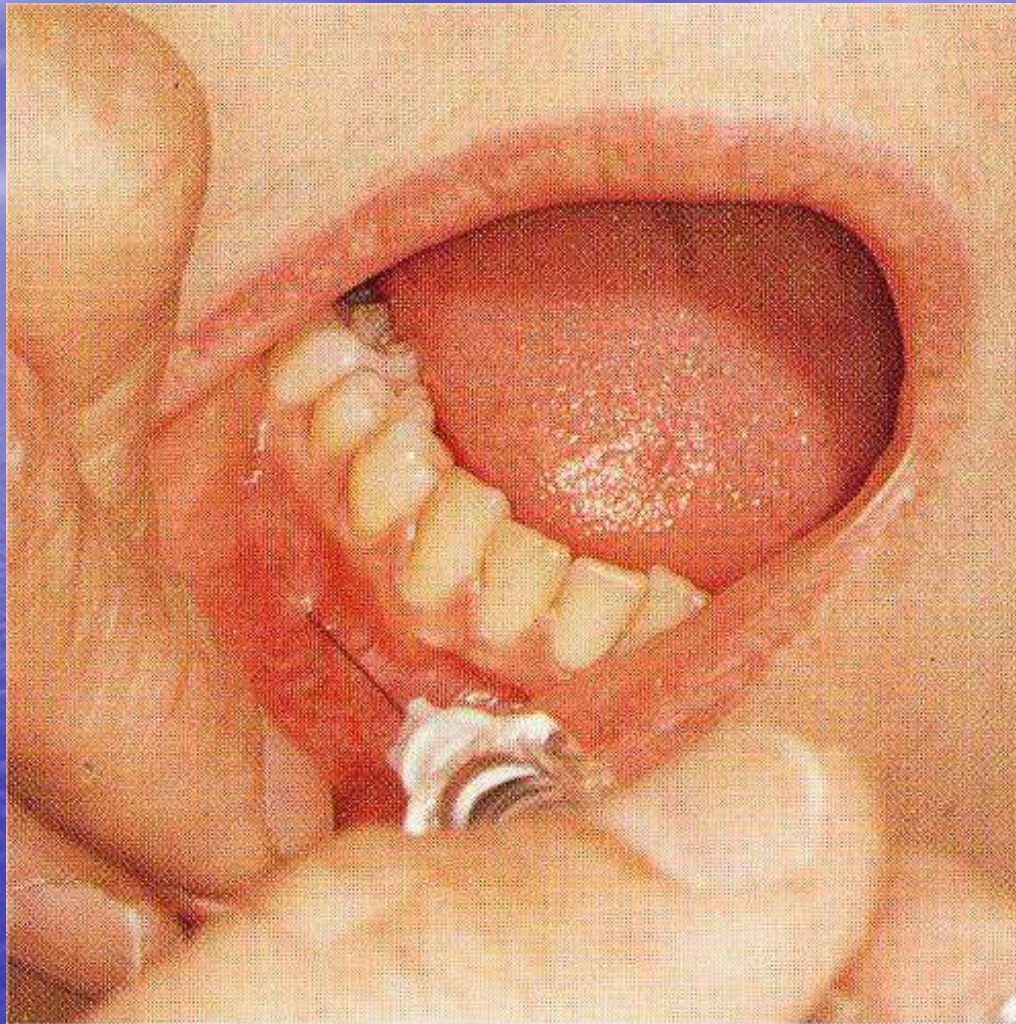


Mandibular anesthesia:

- **Mental nerve block:**

- Technique:

- Area of injection mucobuccal fold at or anterior to the mental foramen. This lies between the mandibular premolars
- Depth of injection ~5-6mm
- Inject 0.5-1.0cc of local anesthesia
- Massage local anesthesia into tissue to manipulate into mental foramen to anesthetize the incisive branch



Local anesthetics:

- Types:
 - Esters- plasma pseudocholinesterase
 - Amides- liver enzymes
- Duration of action:
 - Short
 - Medium
 - Long

Local anesthetics:

<u>Agent:</u>	<u>Dose:</u>	<u>Onset/Duration:</u>
● Lidocaine with epi (1 or 2%)	7mg/kg	Fast/medium
● Lidocaine without epi	4.5mg/kg	Fast/short
● Mepivacaine without epi (3%)	5.5mg/kg	Fast/short
● Bupivacaine with epi (0.5%)	1.3mg/kg	Long/long
● Articaine with epi (4.0%)	7mg/kg	Fast/medium

*ADULT DOSES IN PATIENTS WITHOUT CARDIAC HISTORY

Local anesthetics:

- Dosing considerations:
 - Patient with cardiac history:
 - Should limit dose of epinephrine to 0.04mg
 - Most local anesthesia uses 1:100,000 epinephrine concentration (0.01mg/ml)
 - Pediatric dosing:
 - Clark's rule:
 - Maximum dose = $(\text{weight child in lbs}/150) \times \text{max adult dose (mg)}$
 - Simple method = 1.8cc of 2% lidocaine/20lbs

Local anesthesia complications:

- Needle breakage
- Pain on injection
- Burning on injection
- Persistent anesthesia/parathesia
- Trismus
- Hematoma
- Infection

Local anesthesia complications:

- Edema
- Tissue sloughing
- Facial nerve paralysis
- Post-anesthetic intraoral lesion
 - Herpes simplex
 - Recurrent aphthous stomatitis

Local anesthesia complications:

- Toxicity
 - Clinical manifestations
 - Fear/anxiety
 - Restlessness
 - Throbbing headaches
 - Tremors
 - Weakness
 - Dizziness
 - Pallor
 - Respiratory difficulty/palpitations
 - Tachycardia (PVCs, V-tach, V-fib)

Local anesthesia complications:

- Allergic reaction:
 - More common with ester based local anesthetics
 - Most allergies are to preservatives in pre-made local anesthetic carpules
 - Methylparaben
 - Sodium bisulfite
 - metabisulfite

References:

- Evers, H and Haegerstam, G. *Handbook of Dental Local Anesthesia*. Schultz Medical Information. London. 1981.
- Malamed, S. *Handbook of Local Anesthesia*. 3rd edition. Mosby. St. Louis. 1990.
- Netter, F. *Atlas of Human Anatomy*. CIBA. 1989.