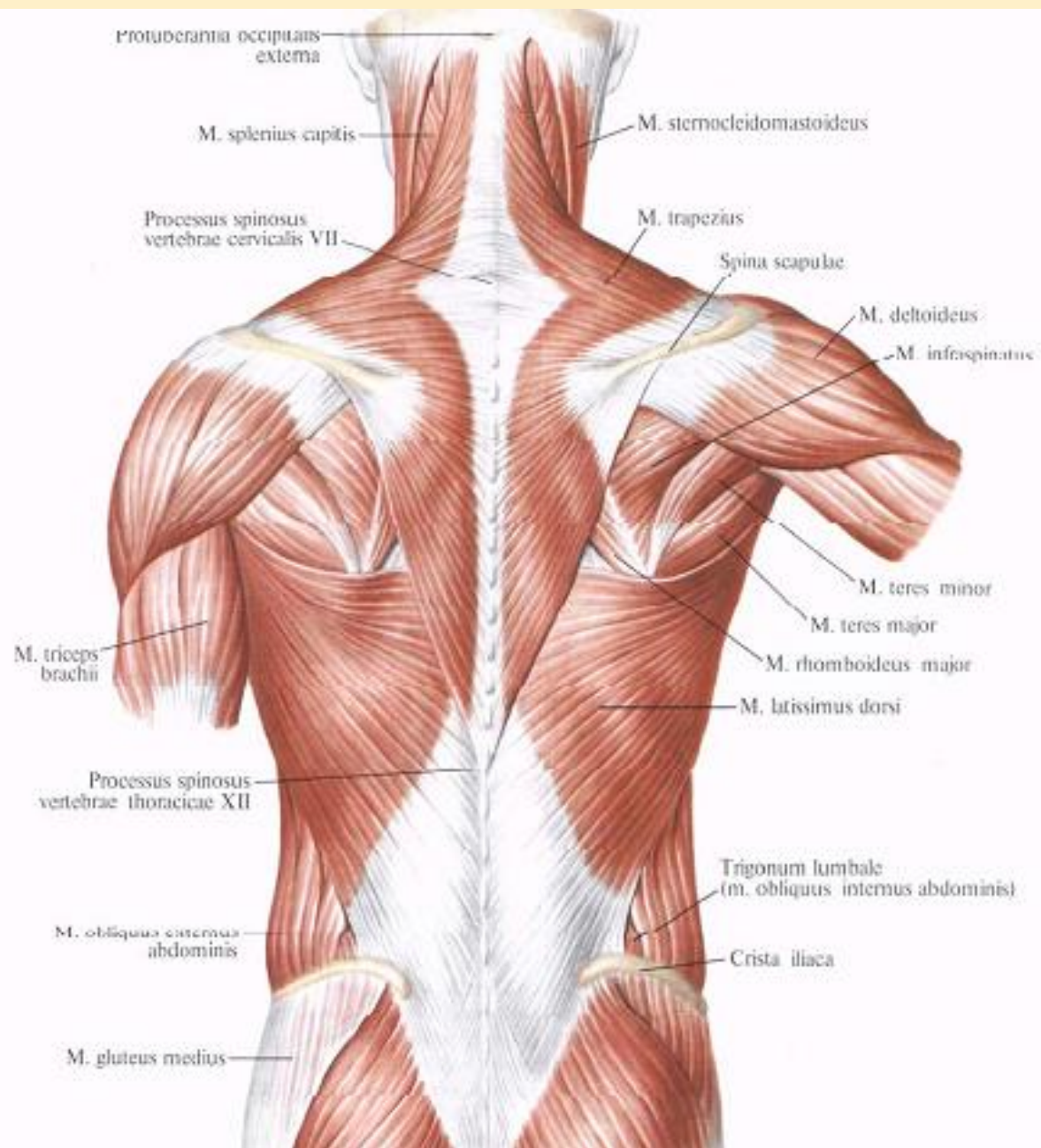


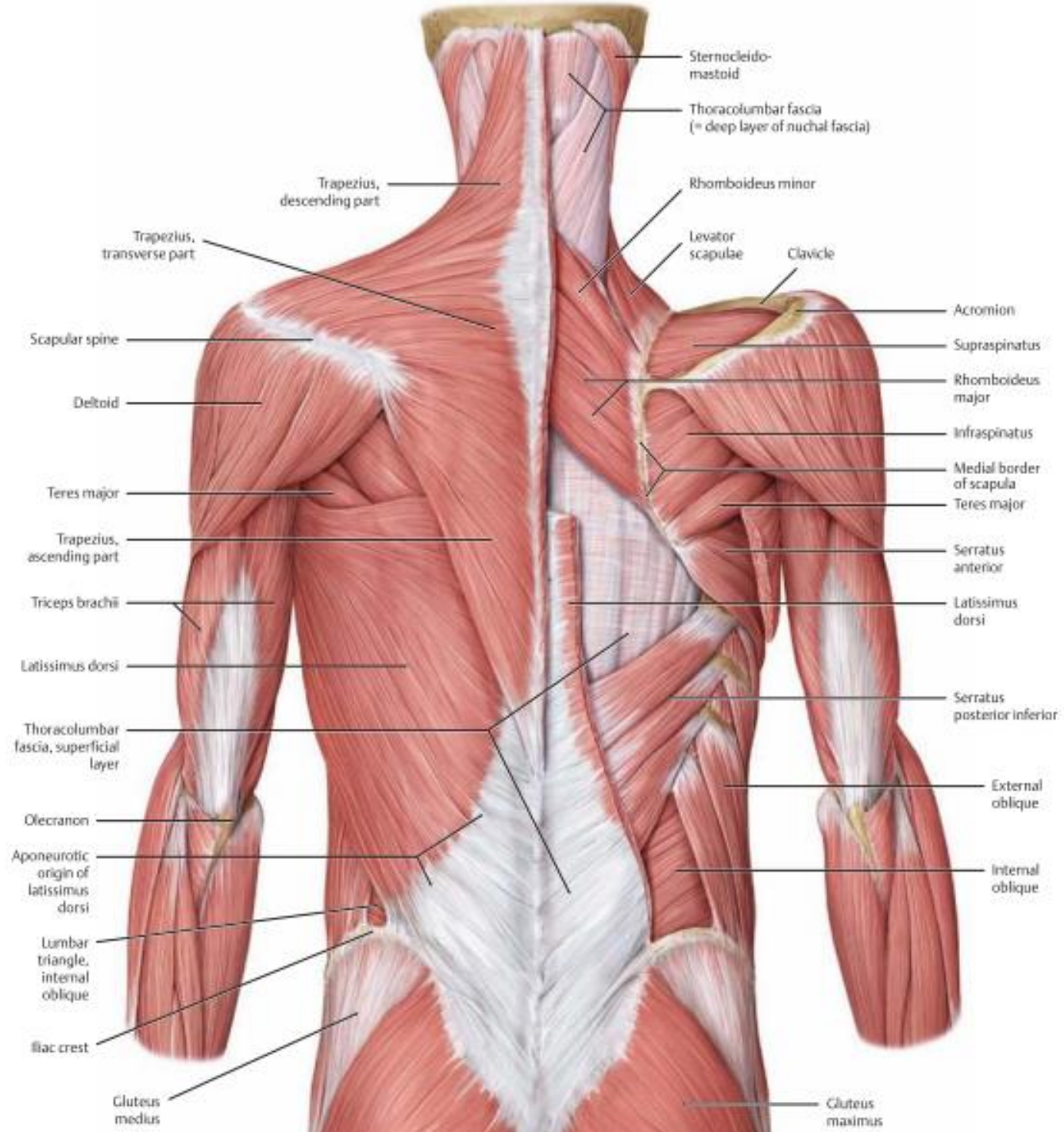
**STATE MEDICAL AND PHARMACEUTICAL  
UNIVERSITY “NICOLAE TESTEMITANU”  
ANATOMY DEPARTMENT**

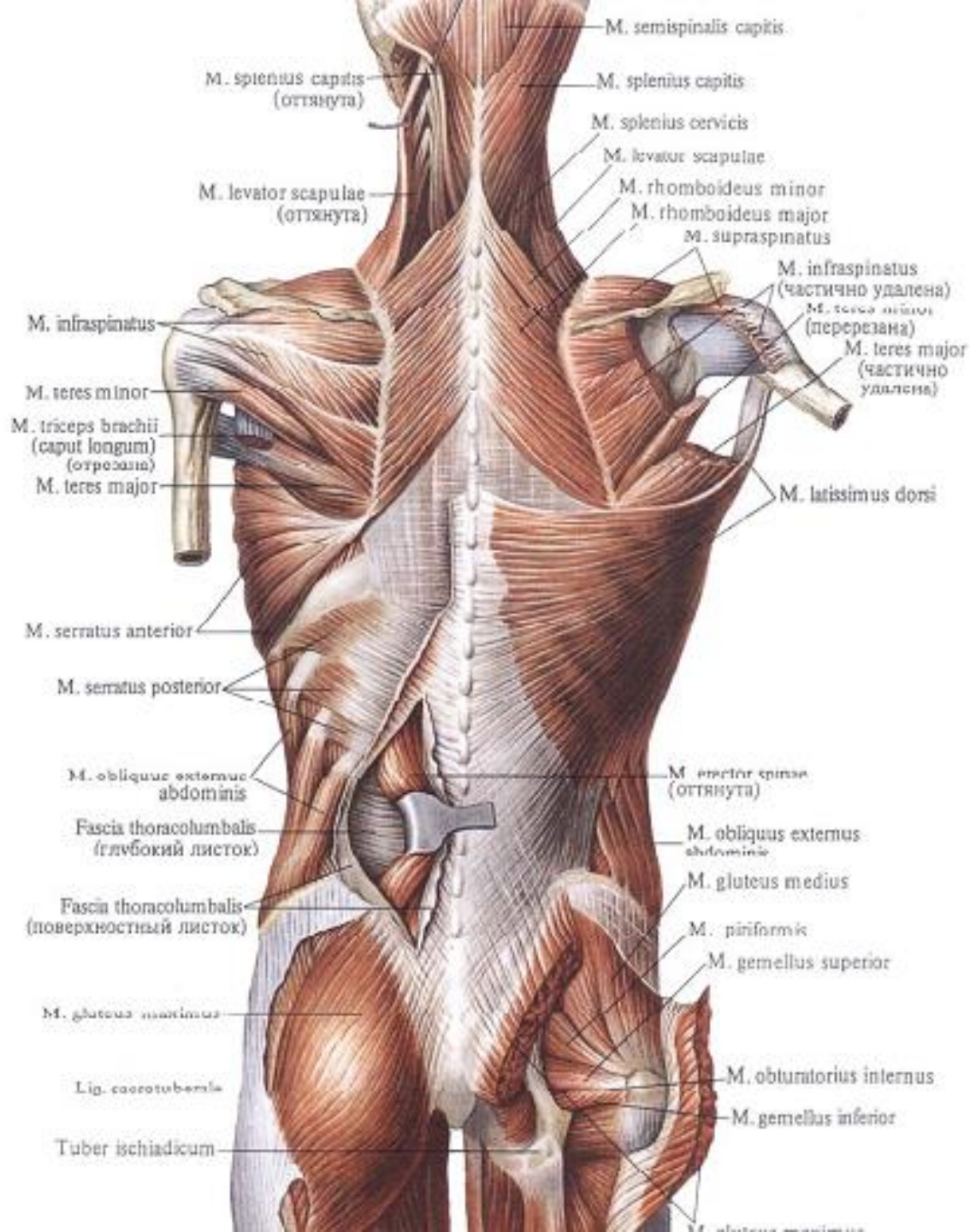
# **Functional Anatomy of Muscles of the Trunk**

**Lecturer Globa Lilian**

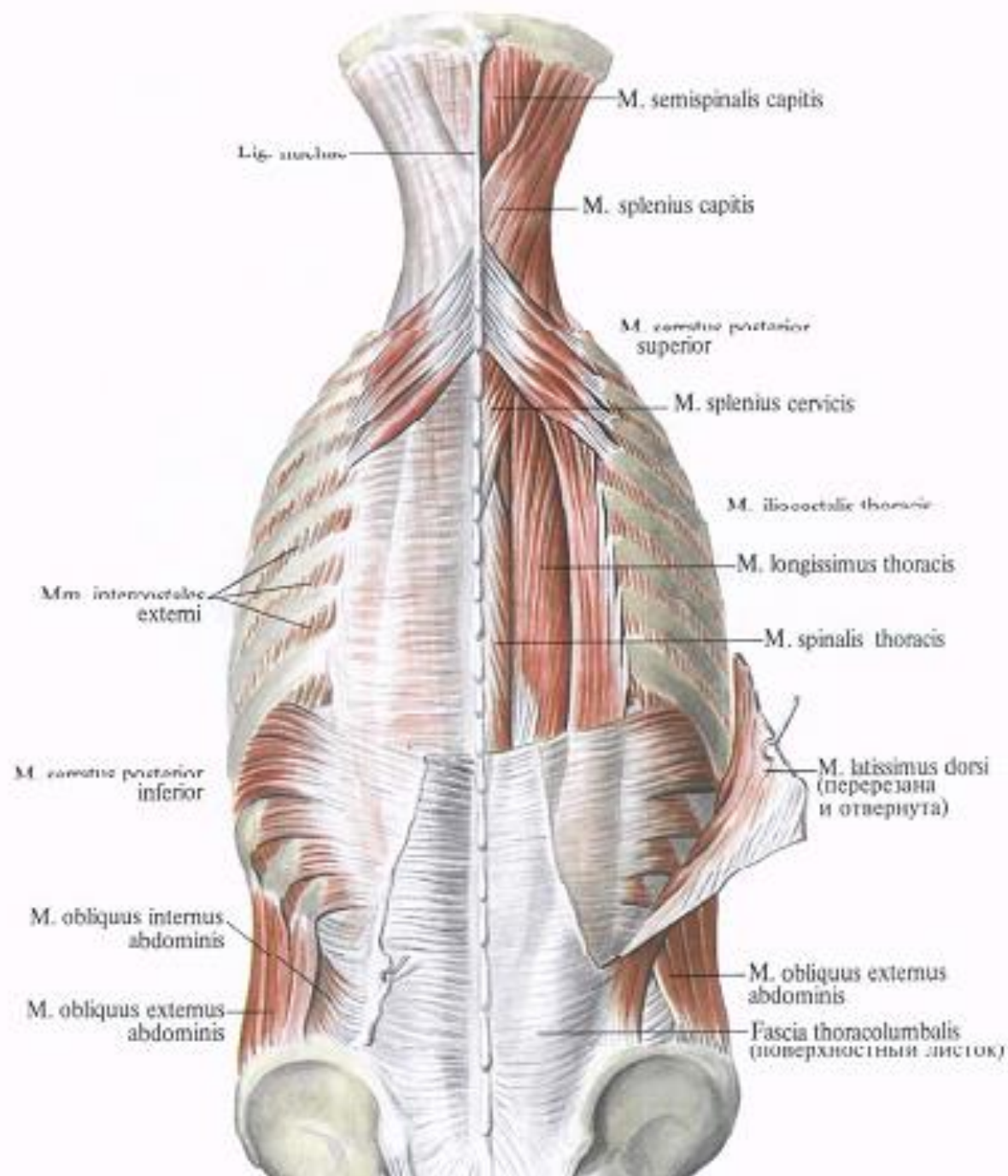


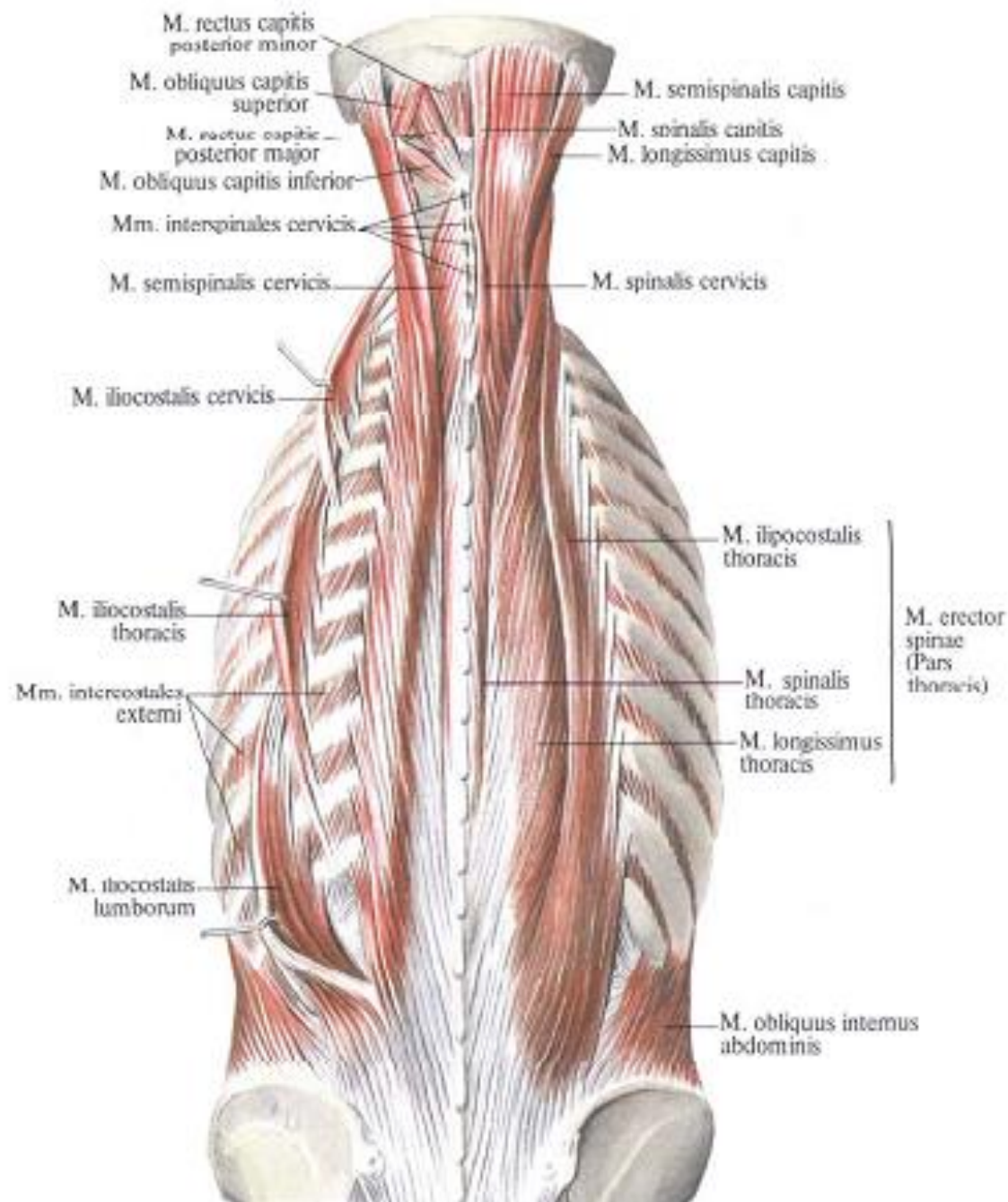




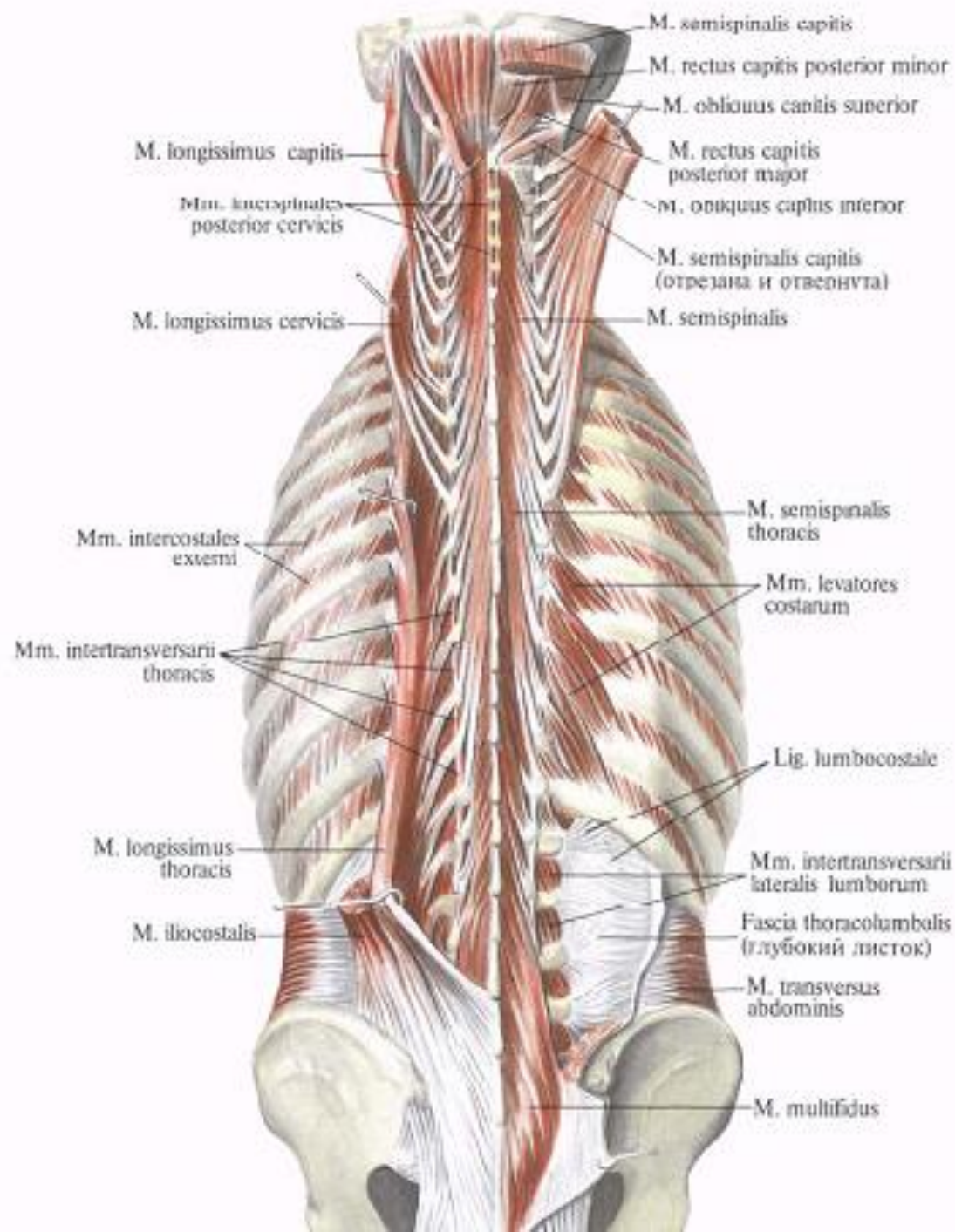


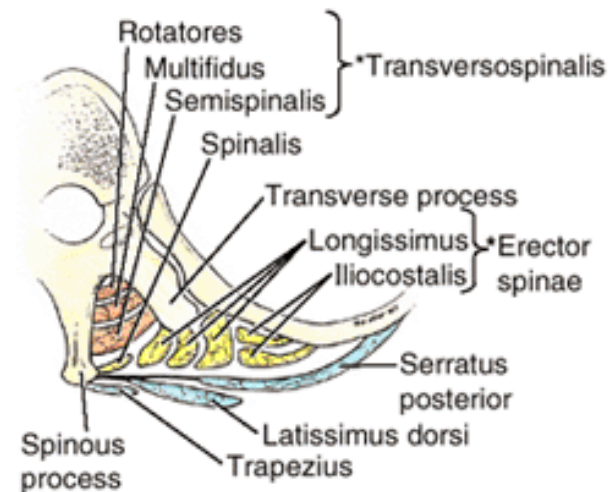
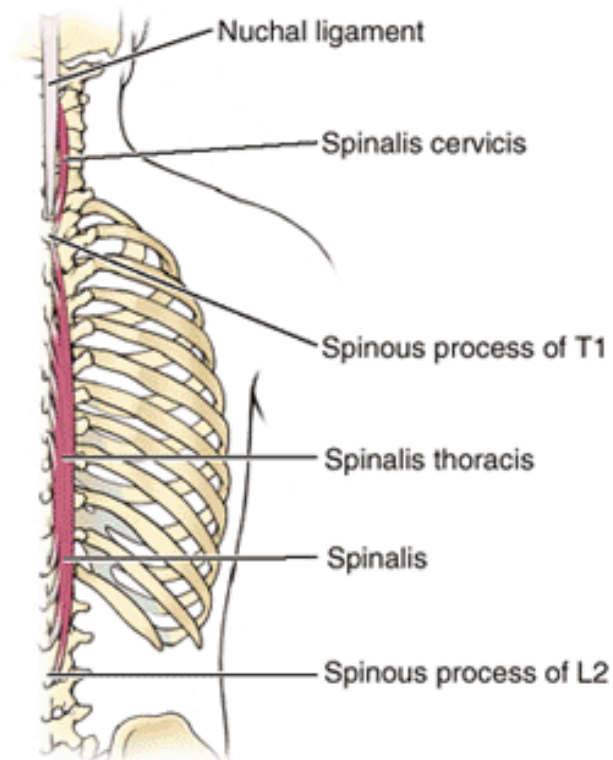
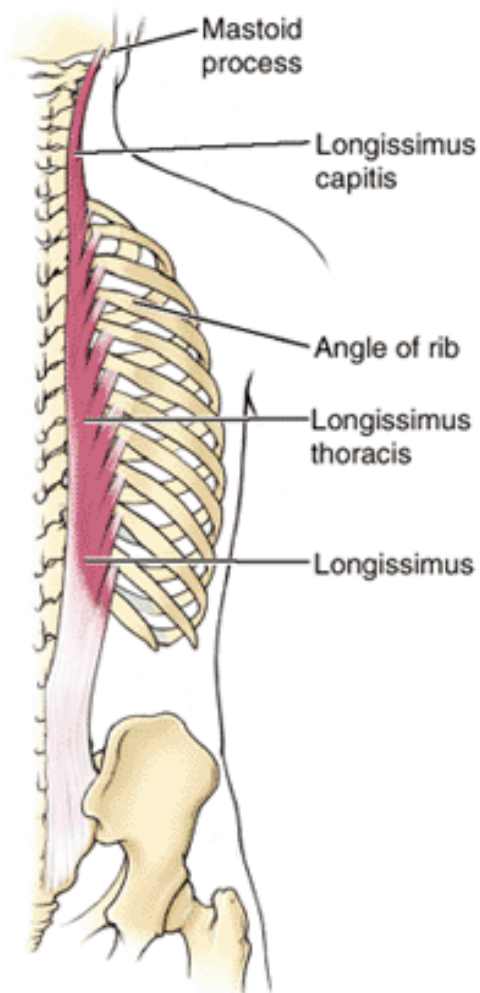
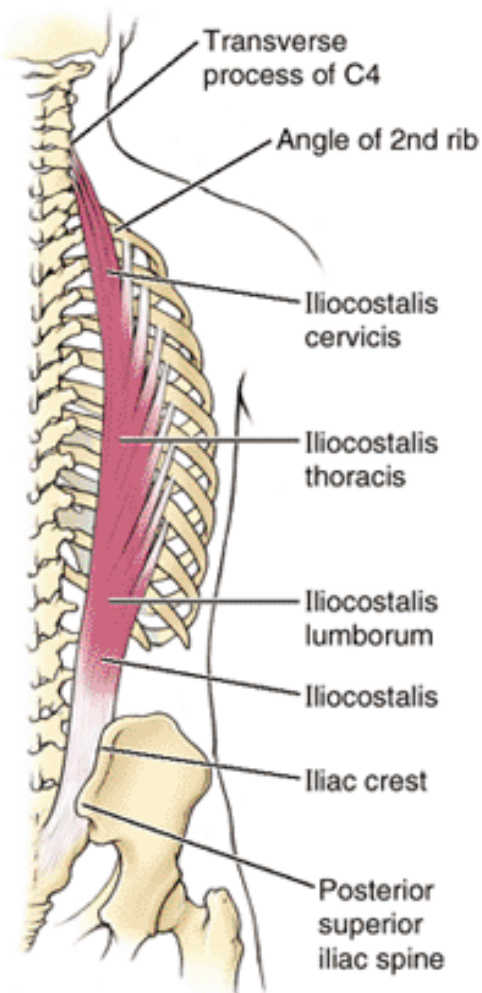




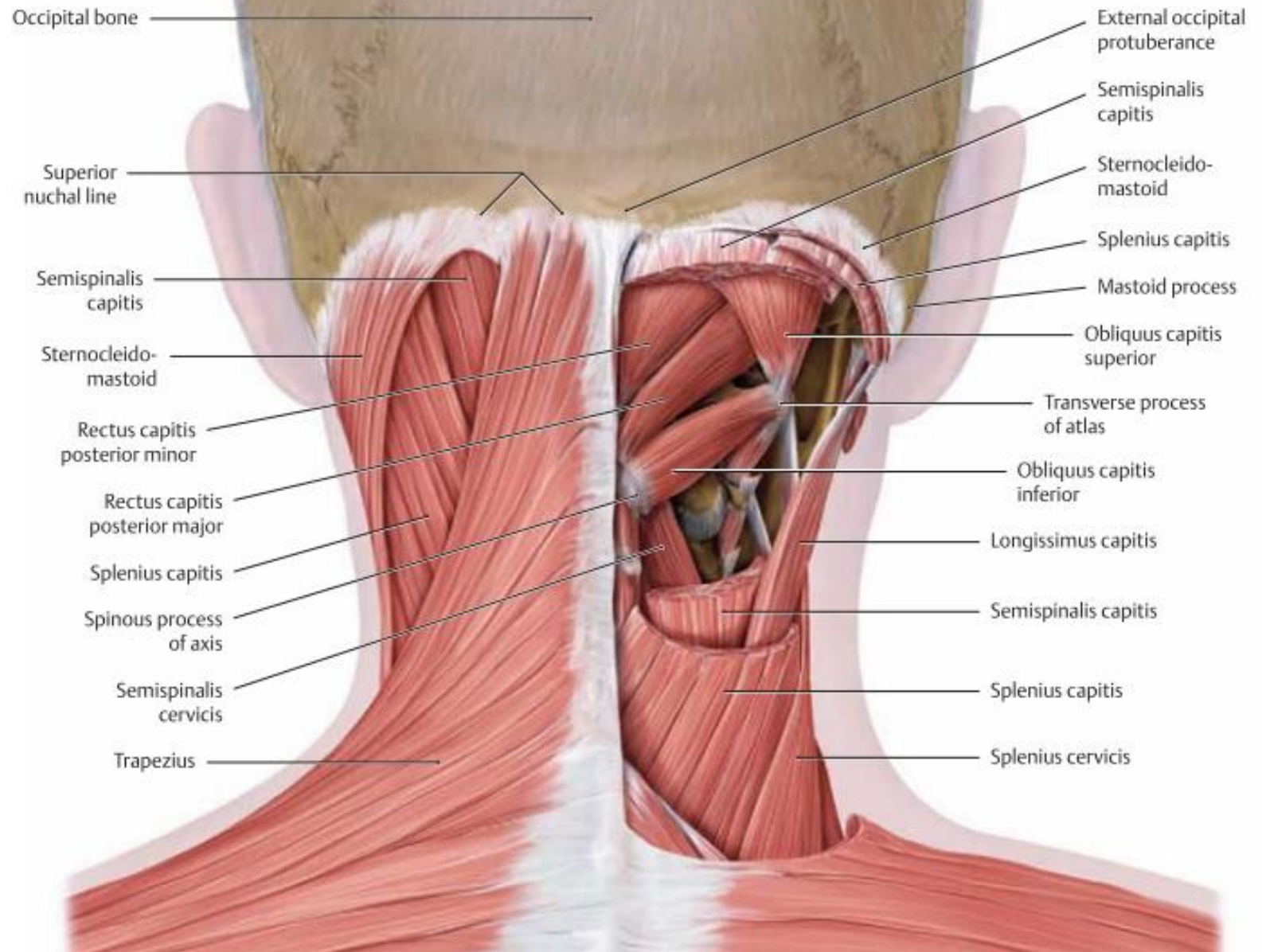


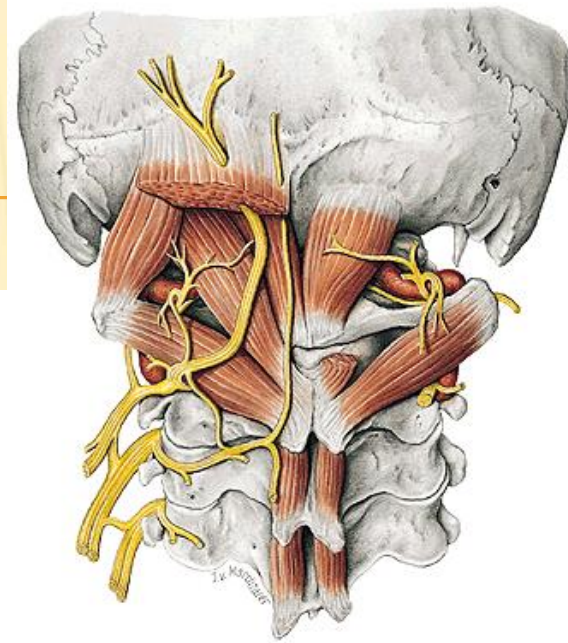
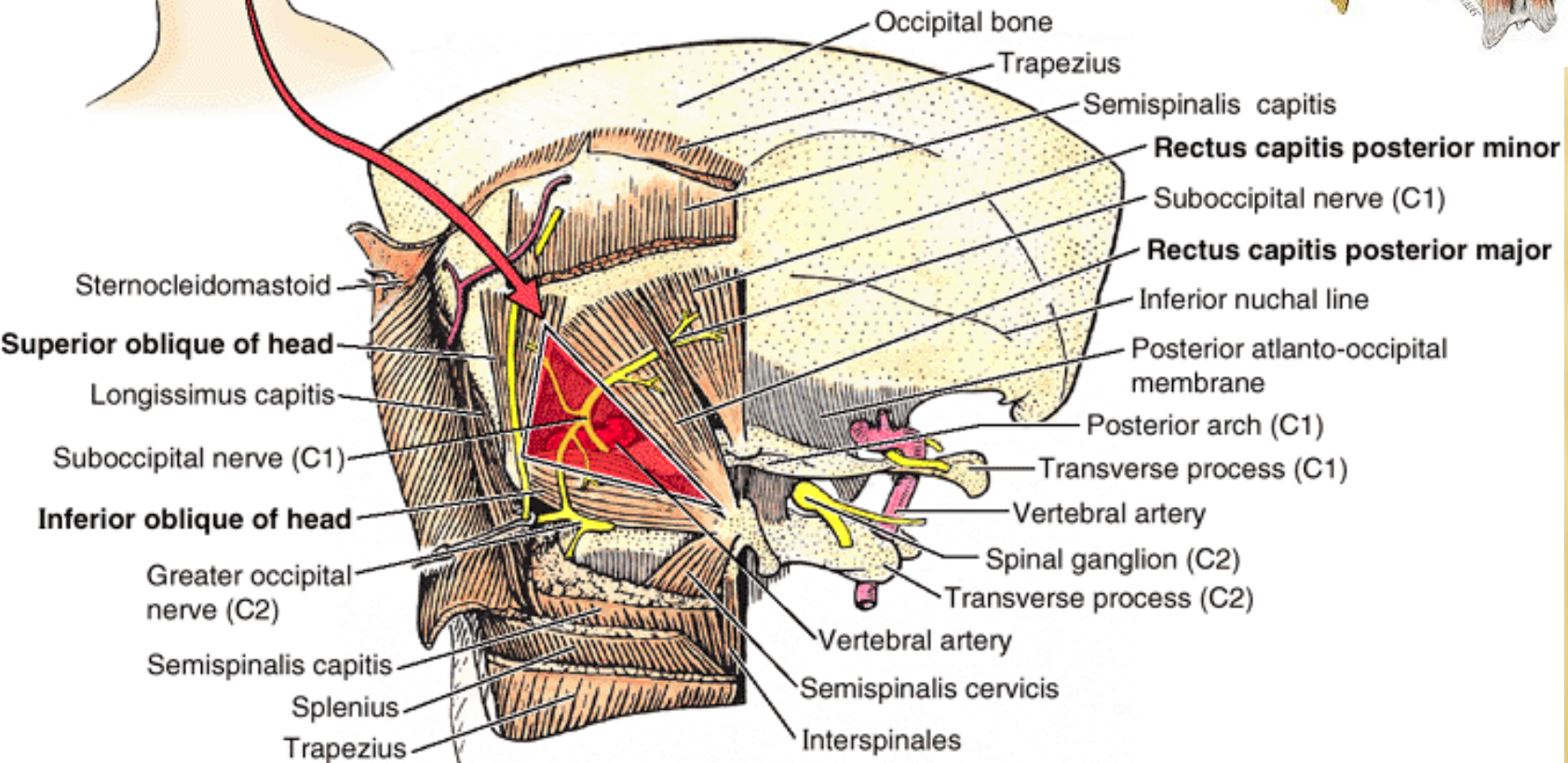
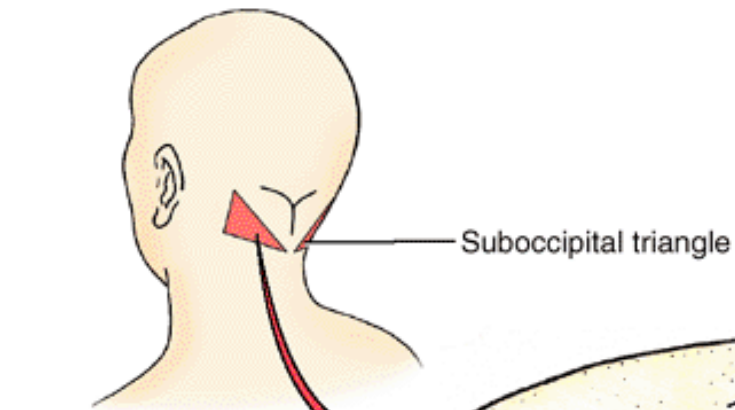




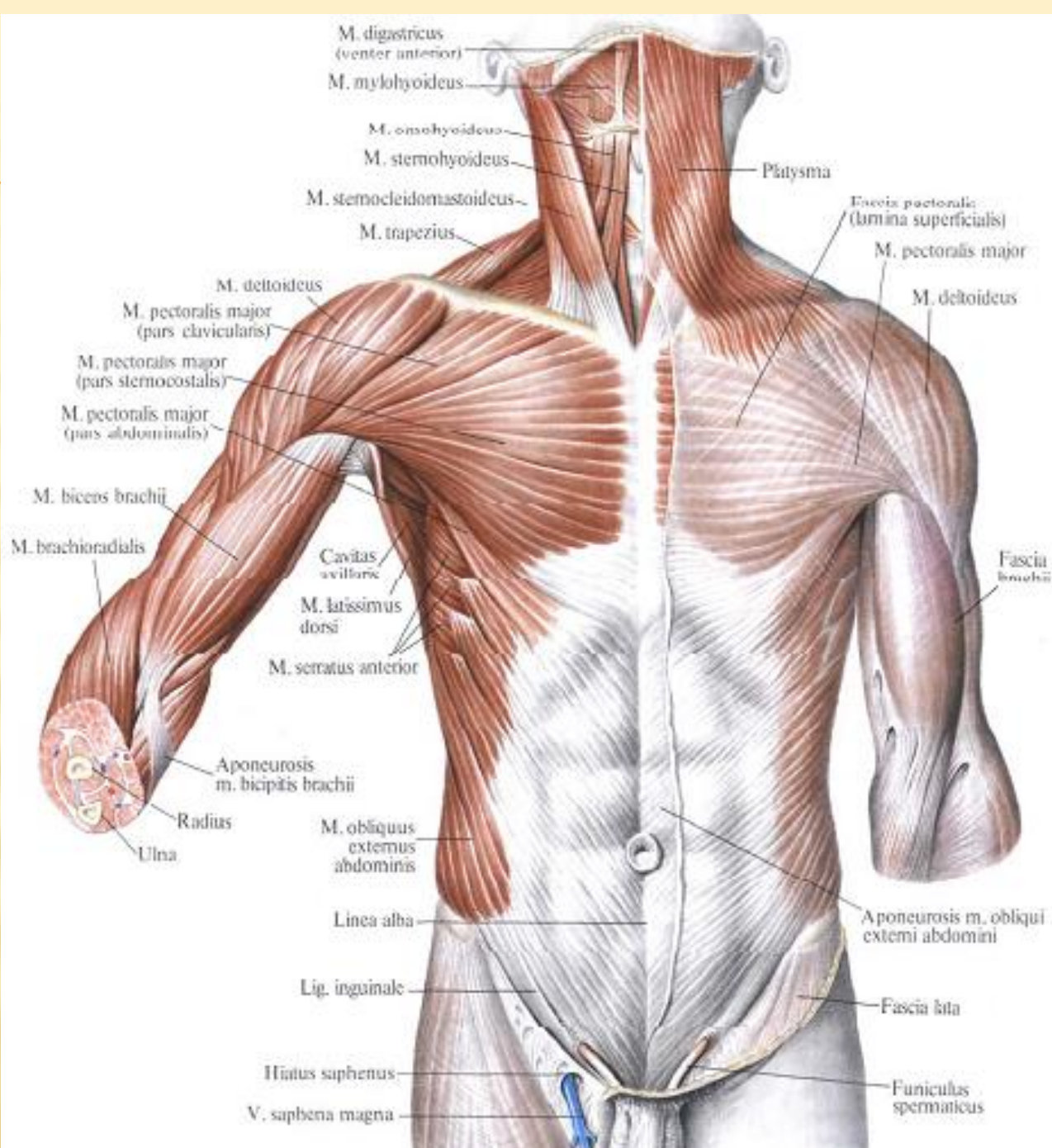


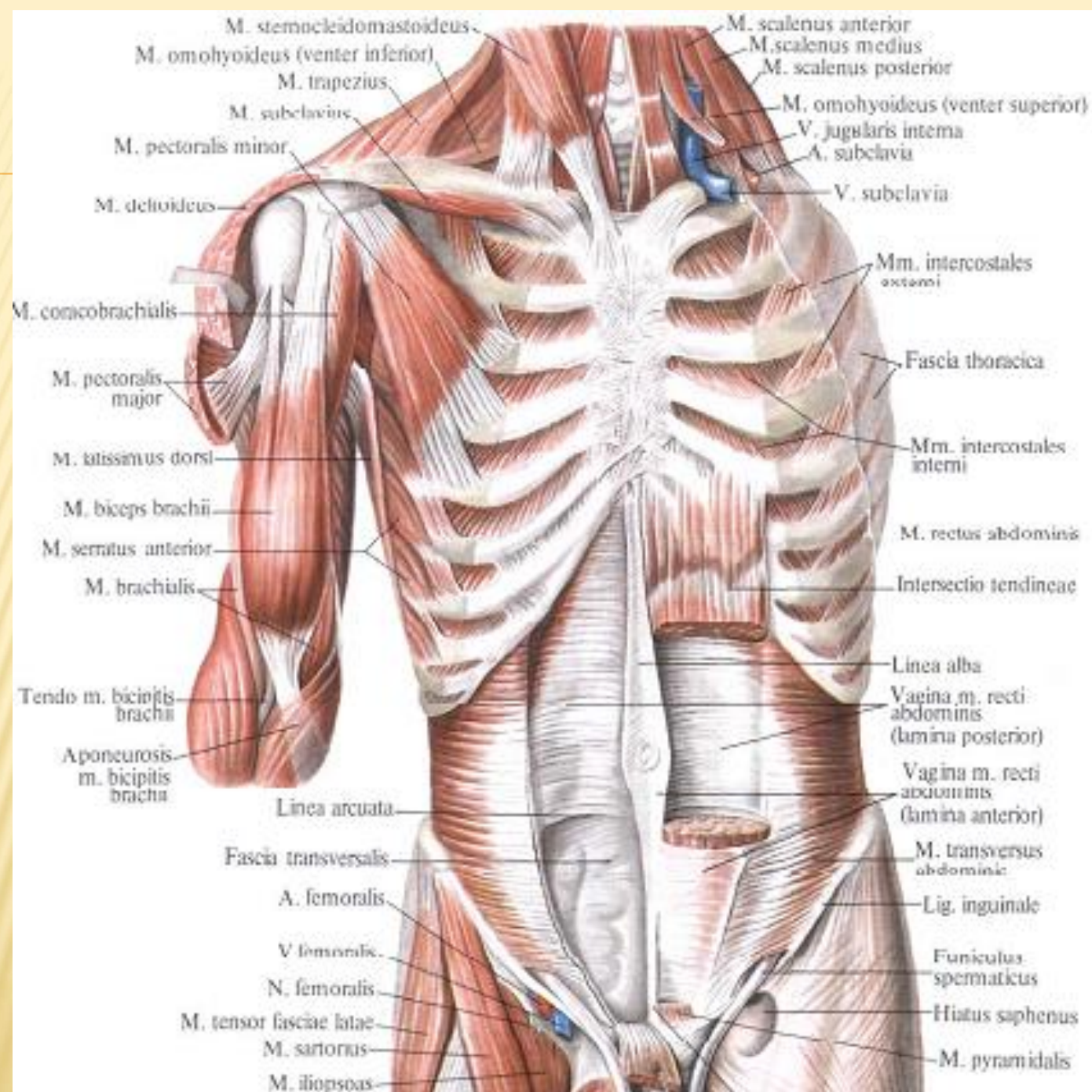




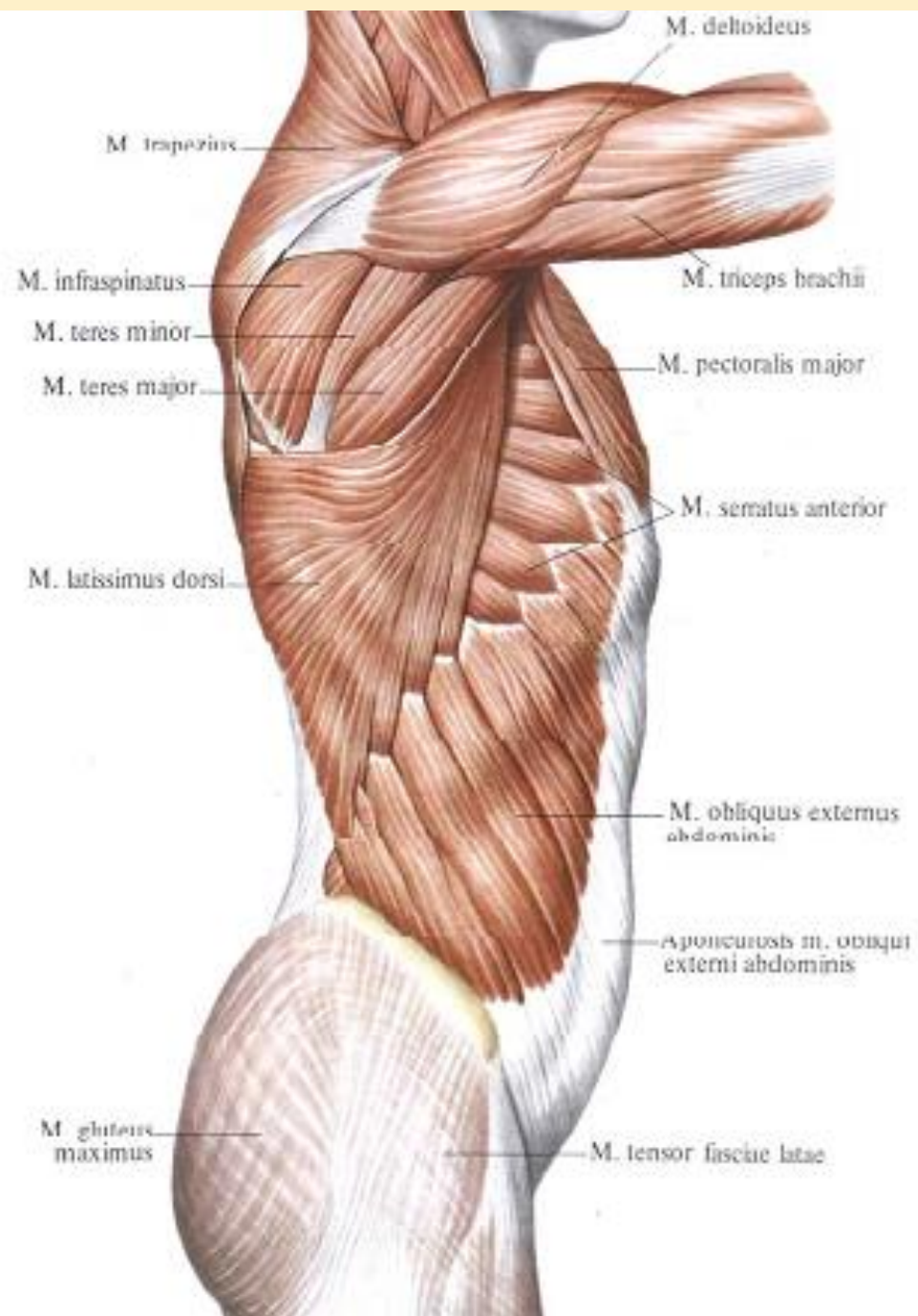


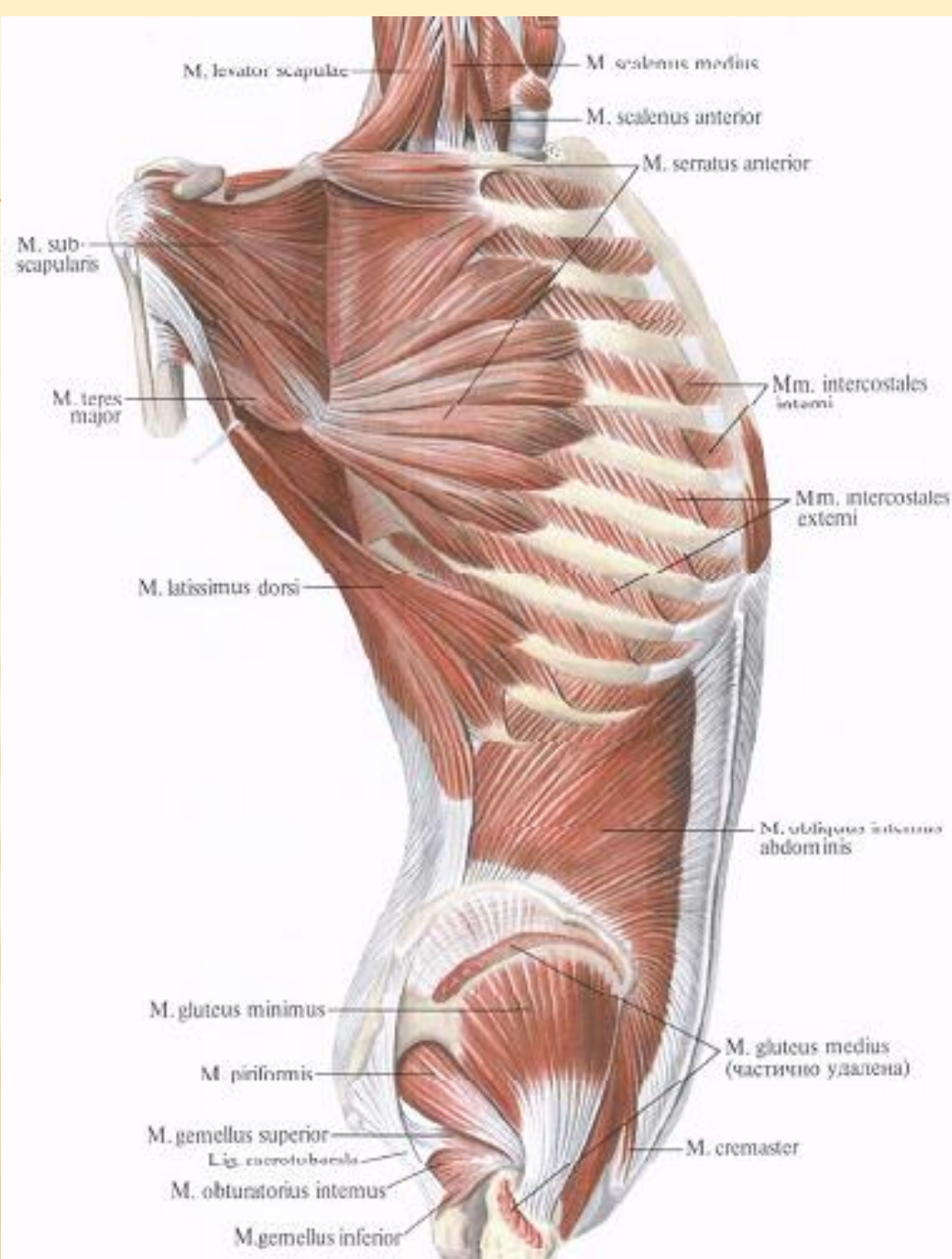




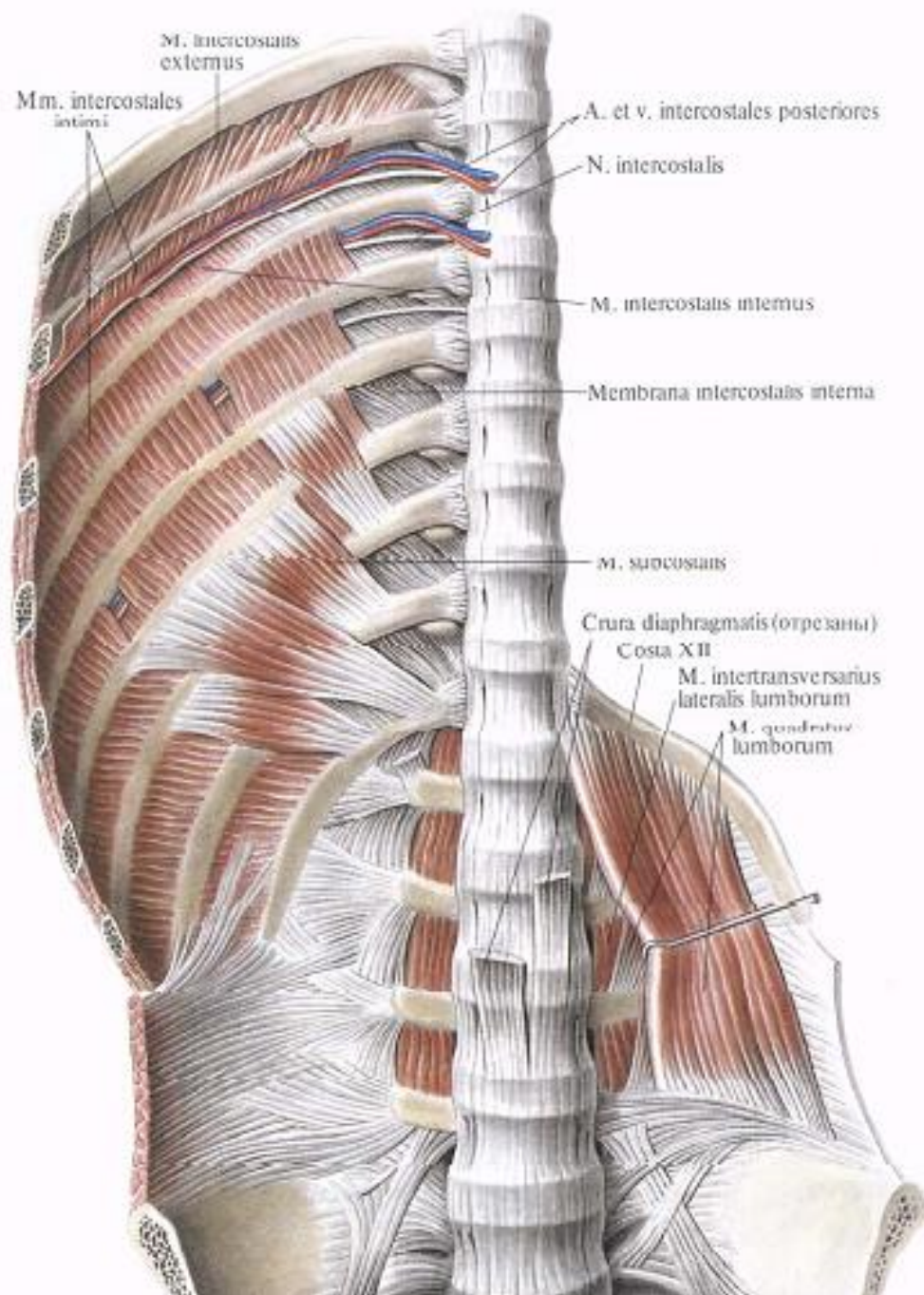


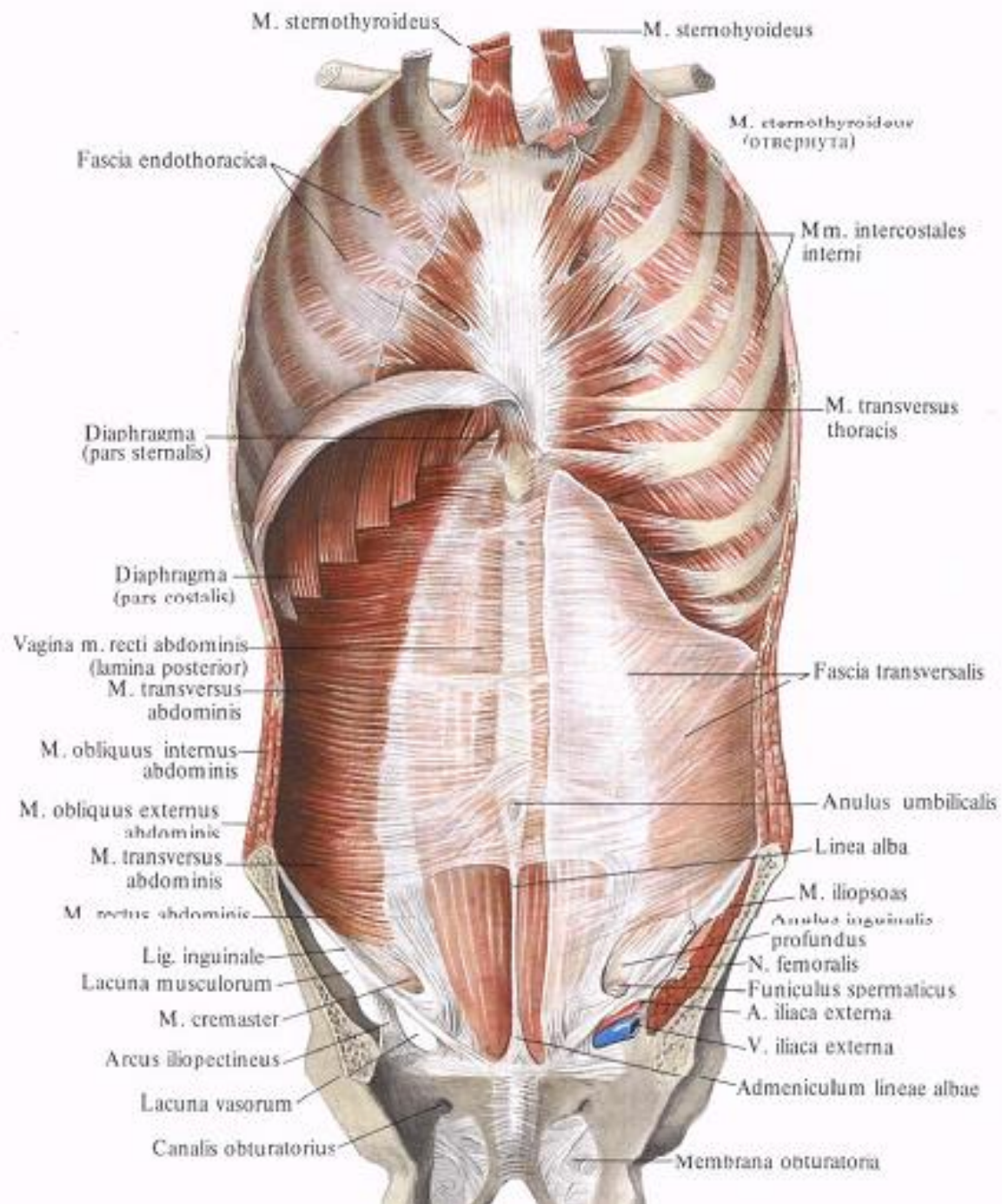




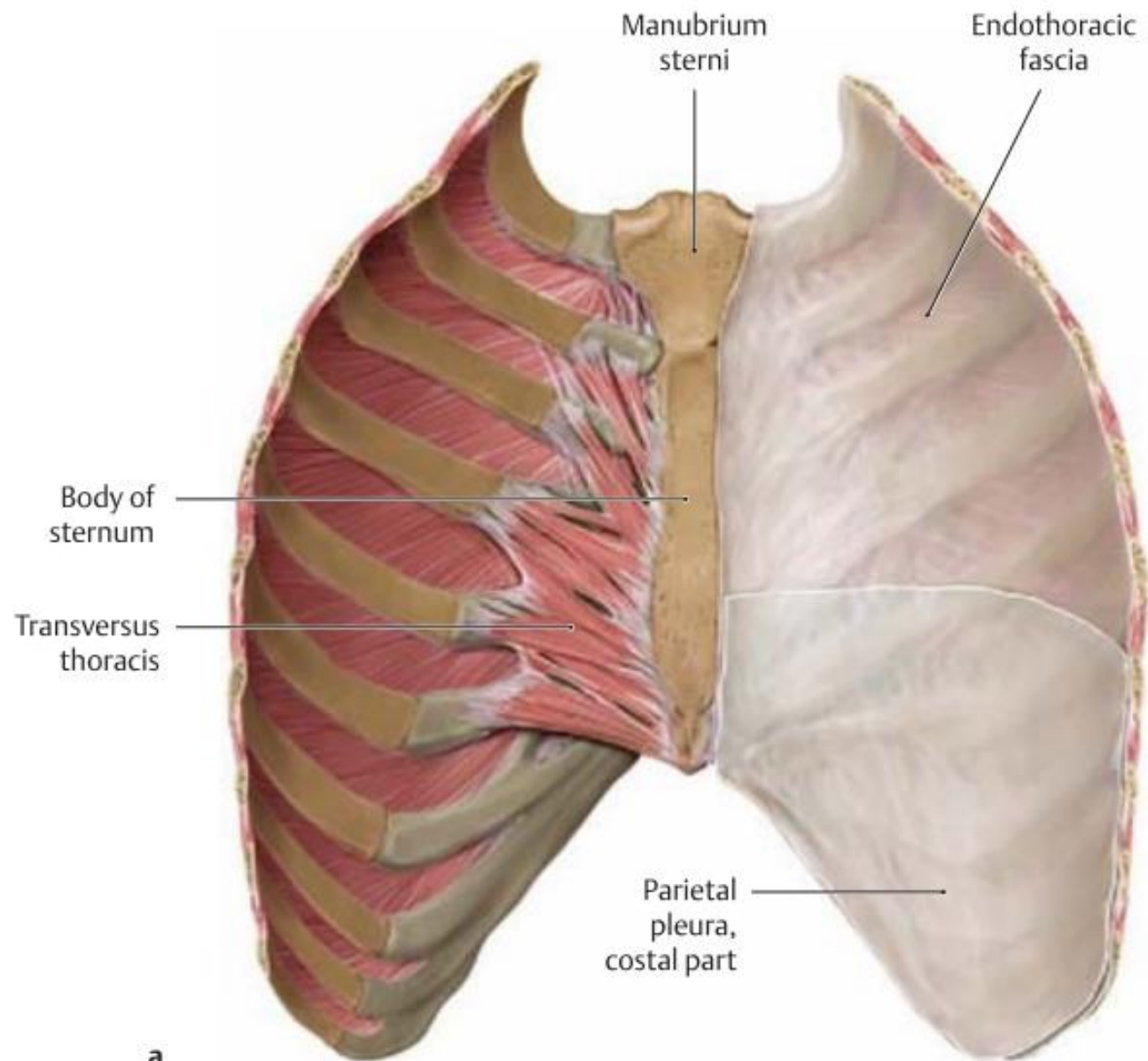




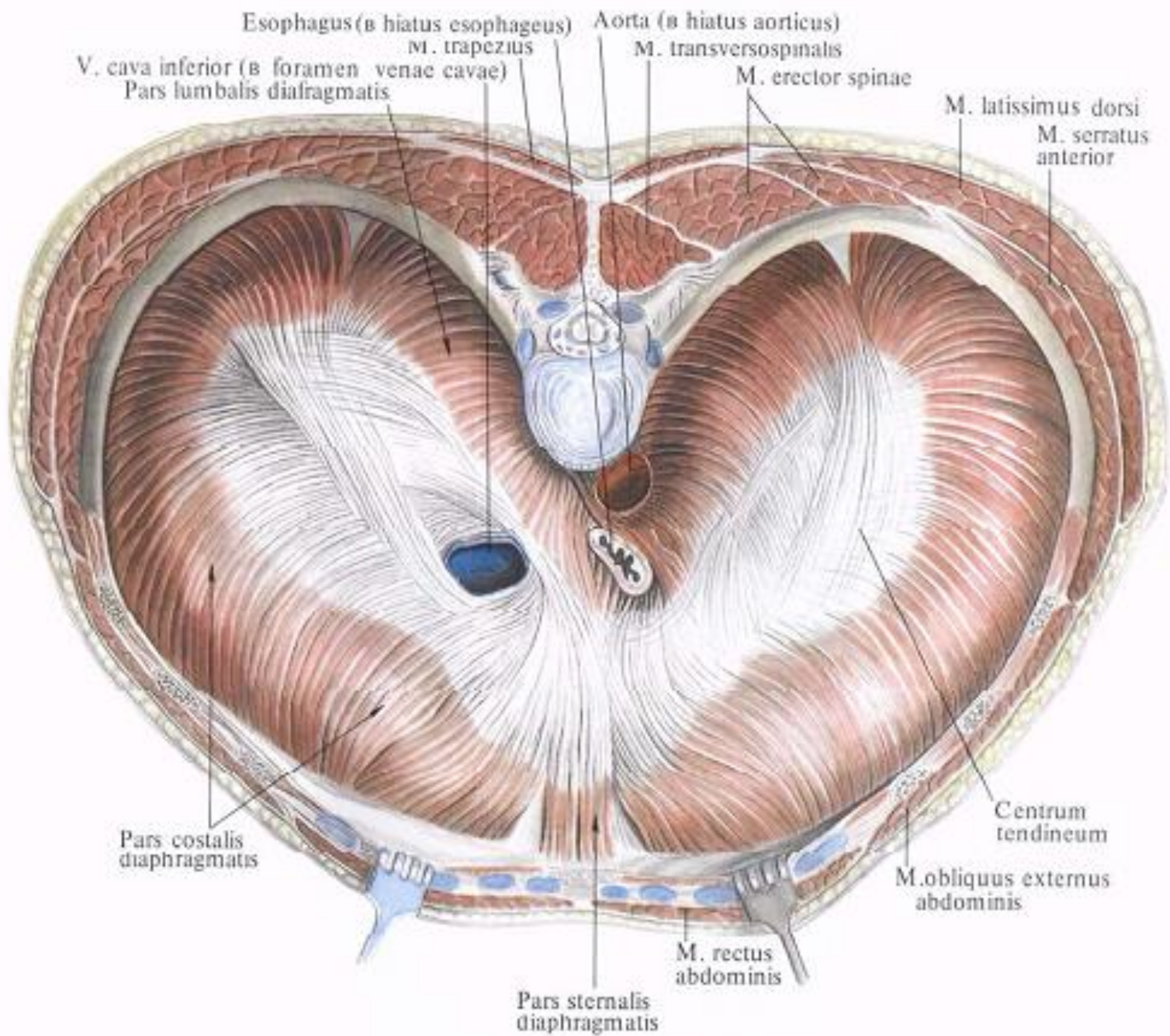




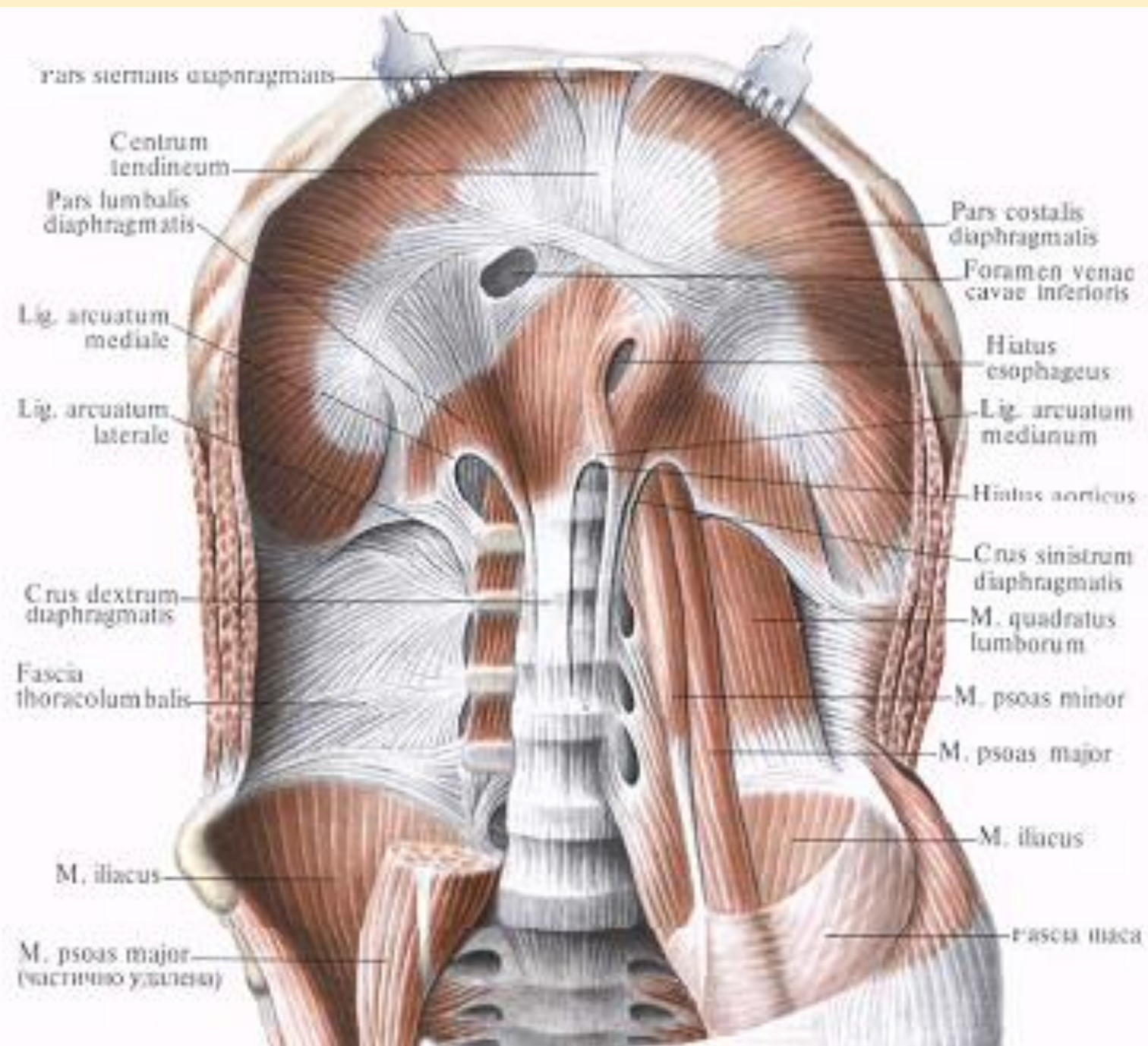


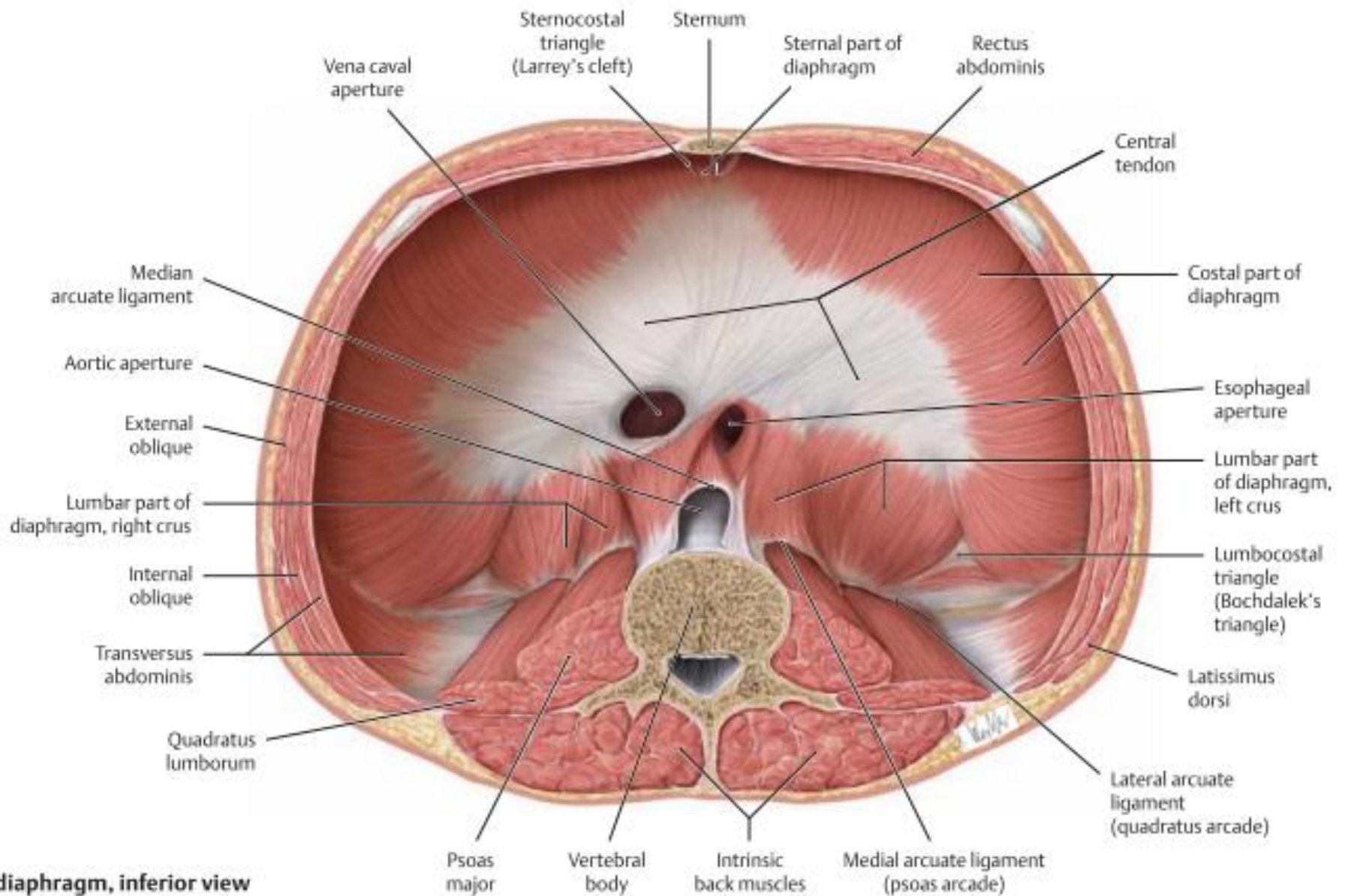


**a**



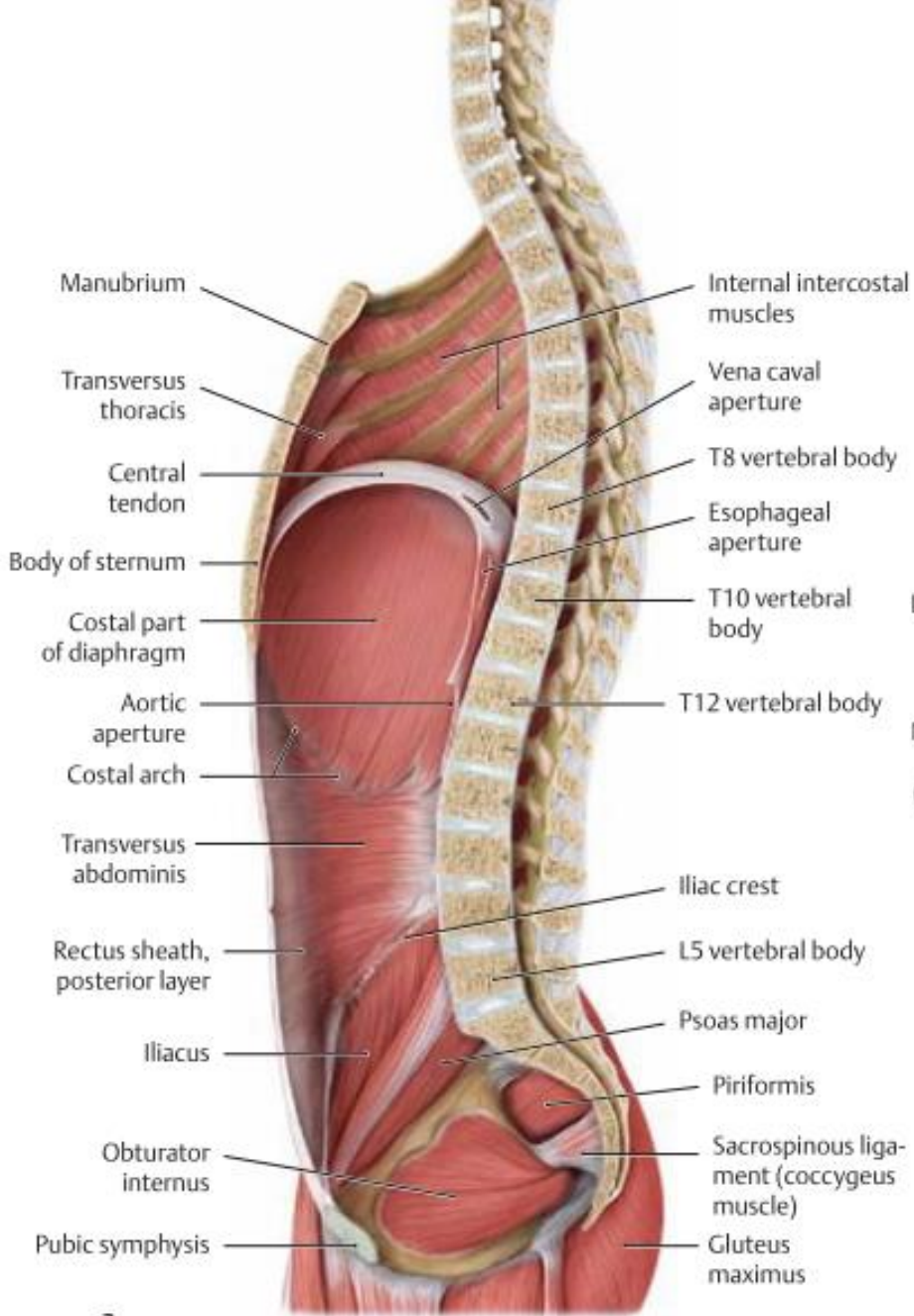




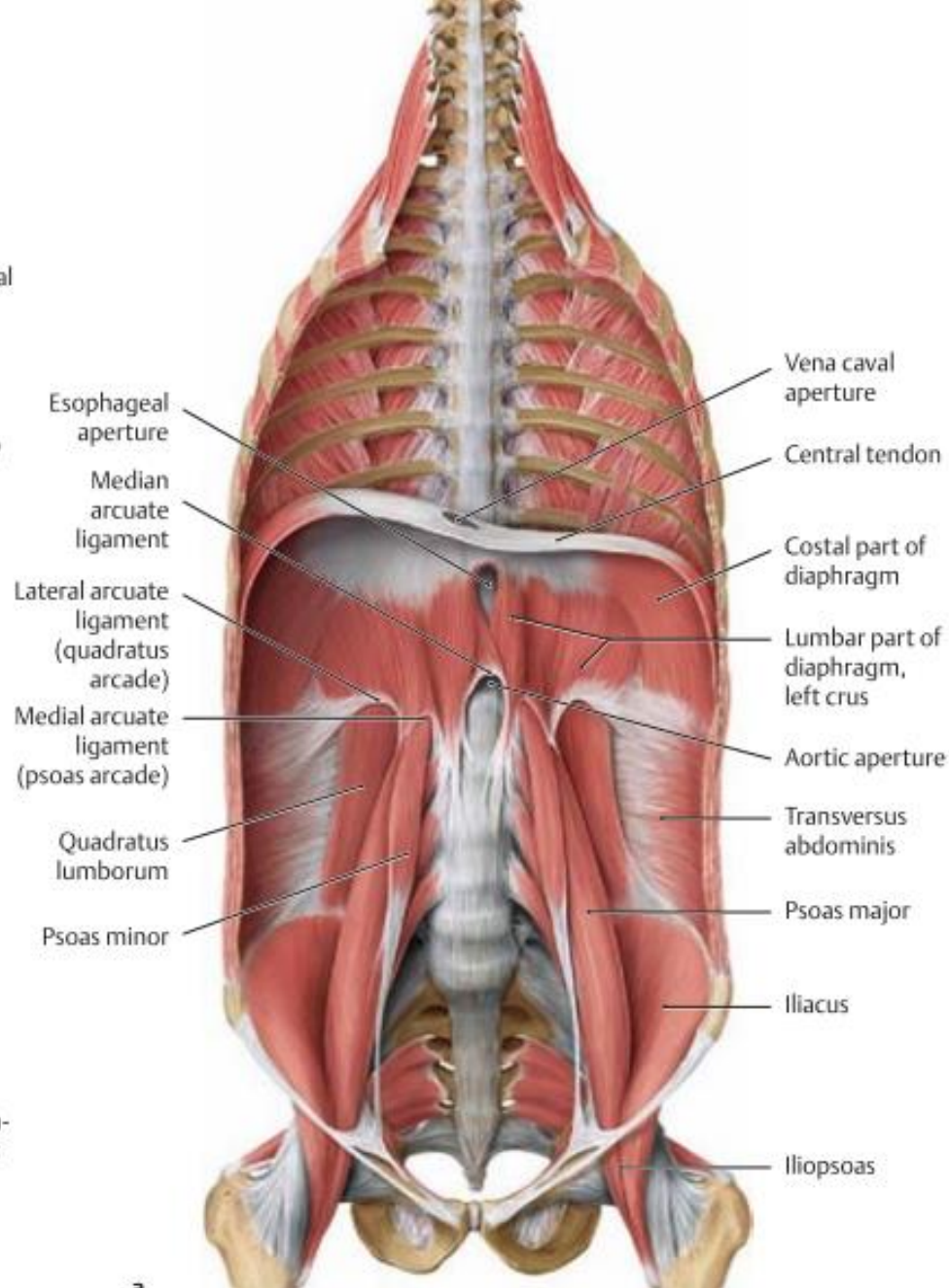


**The diaphragm, inferior view**

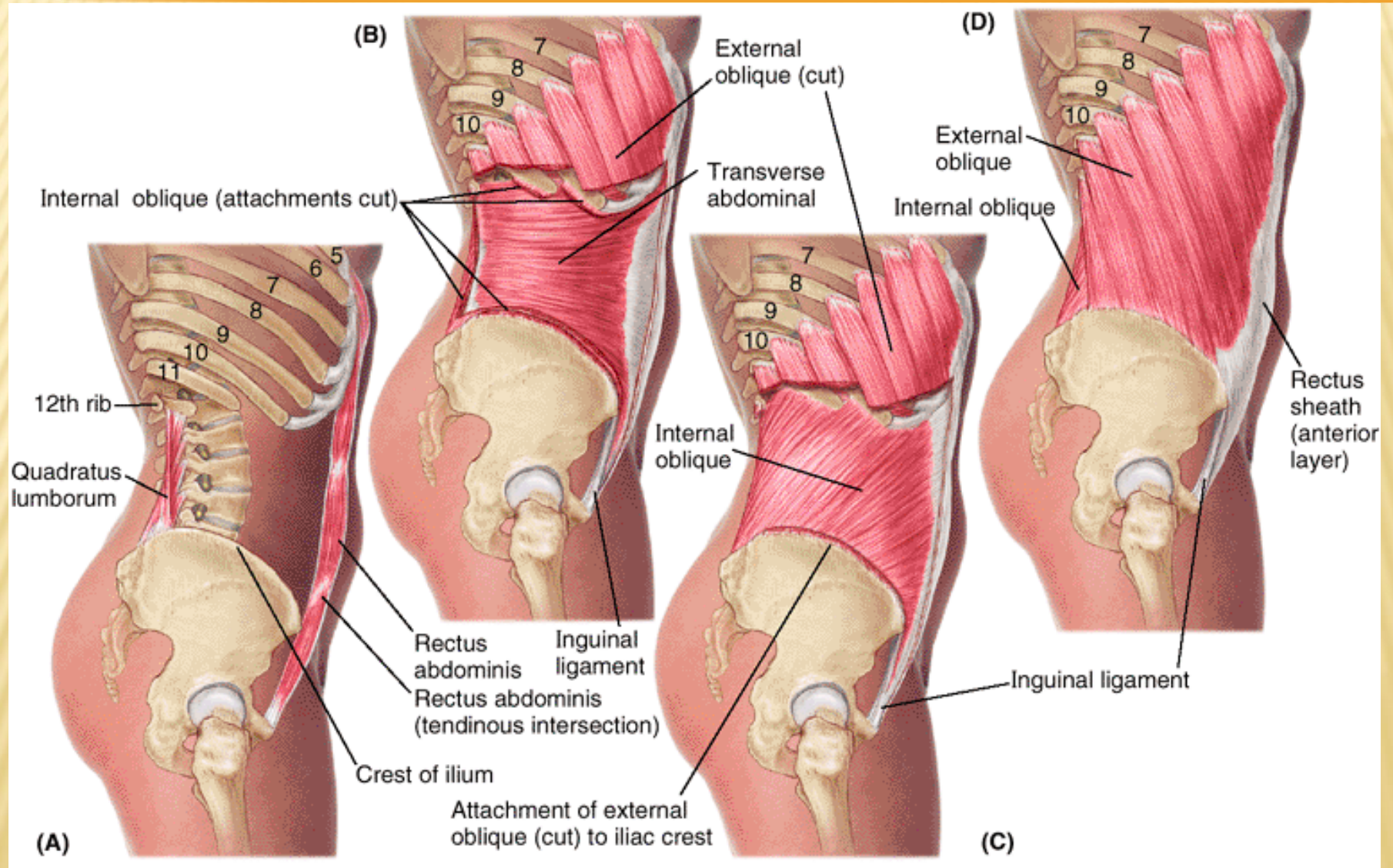




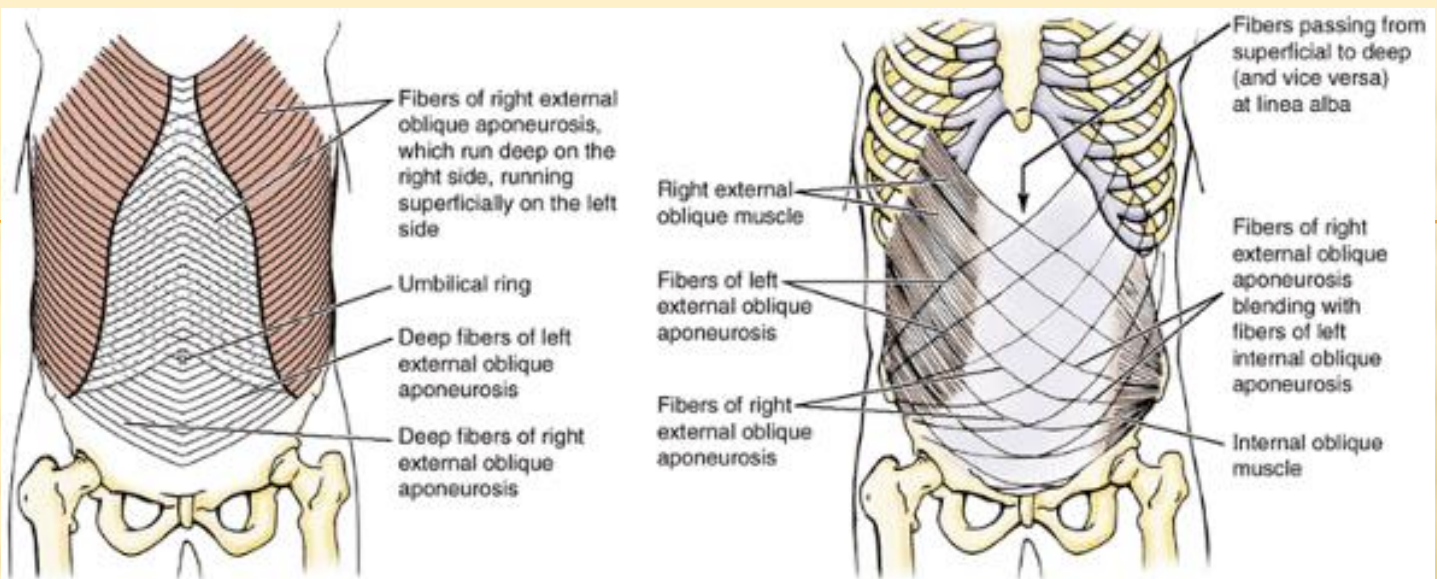
a



a



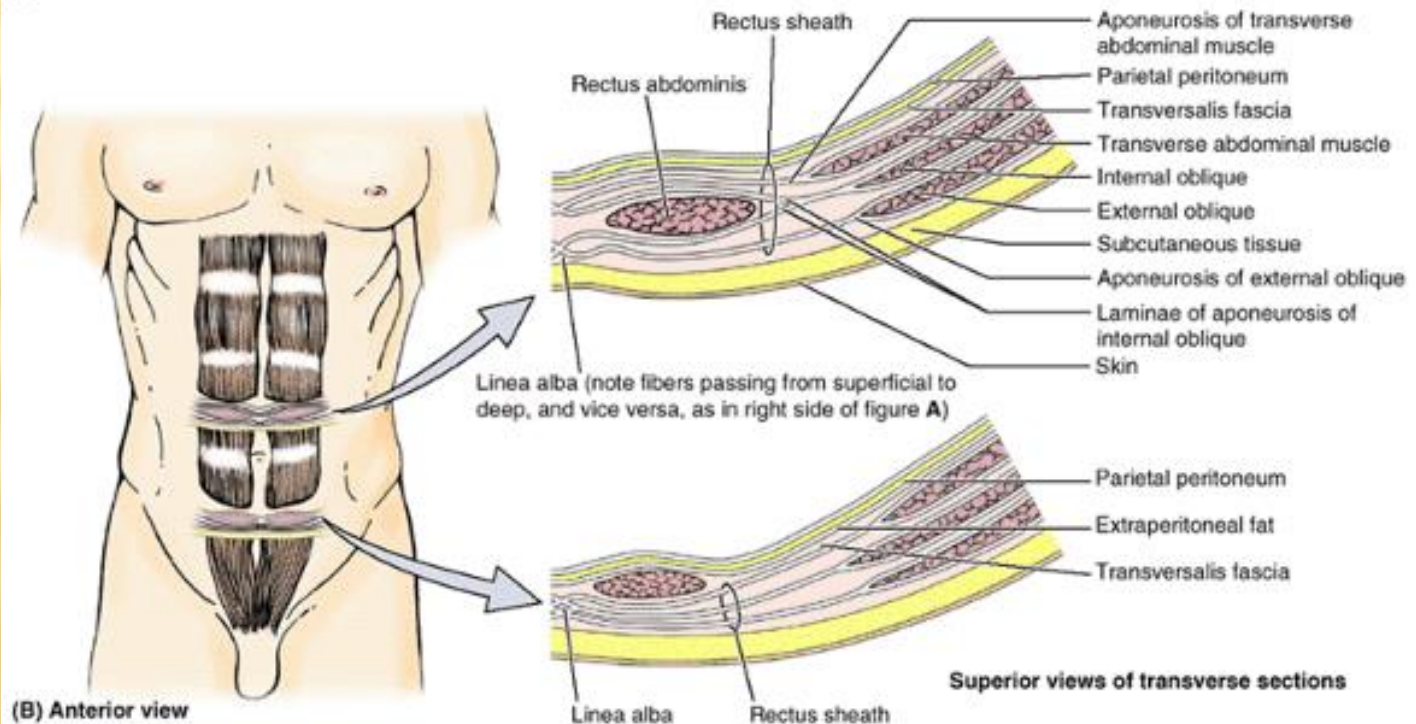




**Intramuscular** exchange of superficial and deep fibers within aponeuroses of contralateral external oblique muscles.

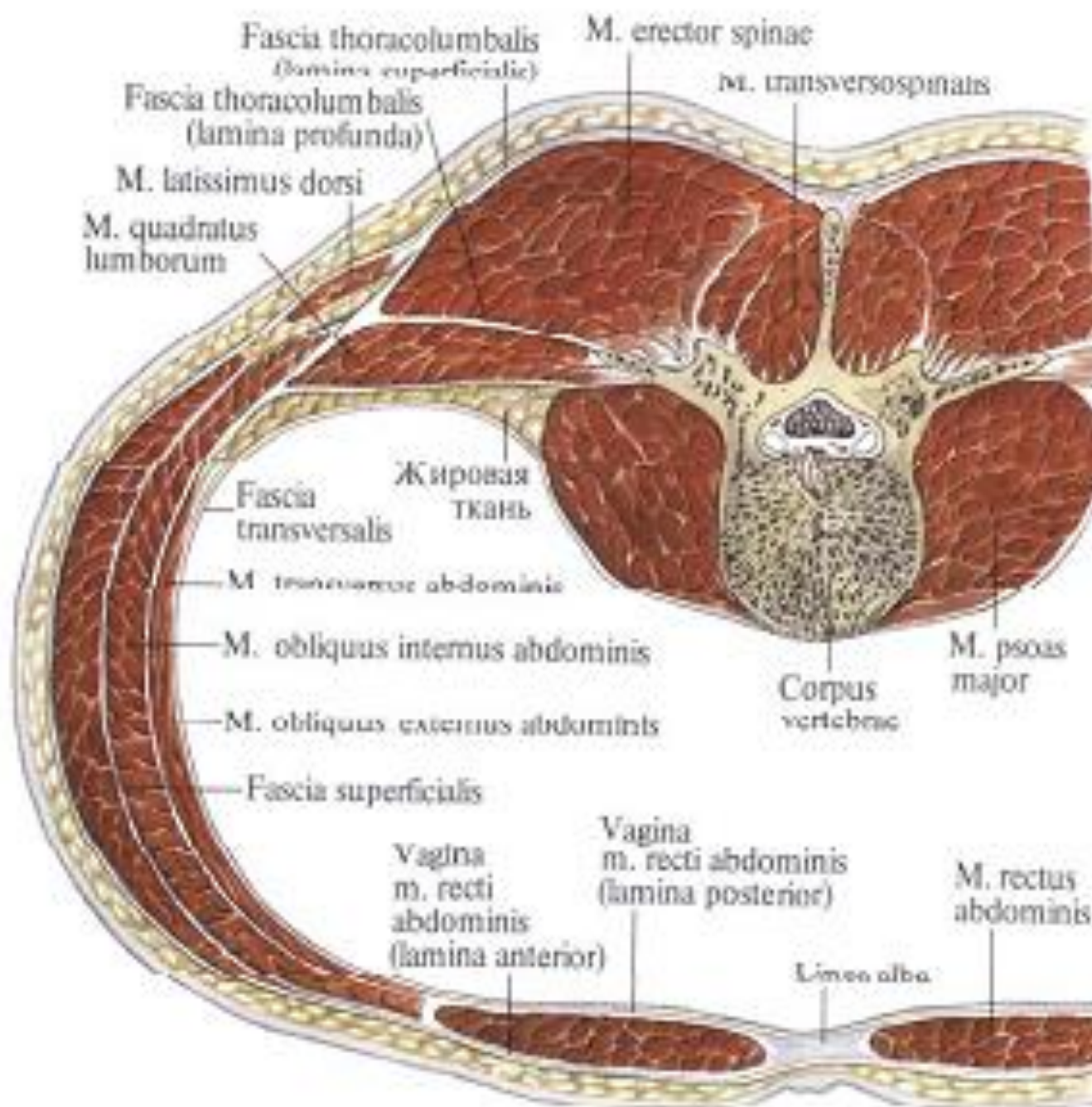
**Intermuscular** exchange of fibers between aponeuroses of contralateral external and internal oblique muscles.

**(A) Anterior views**

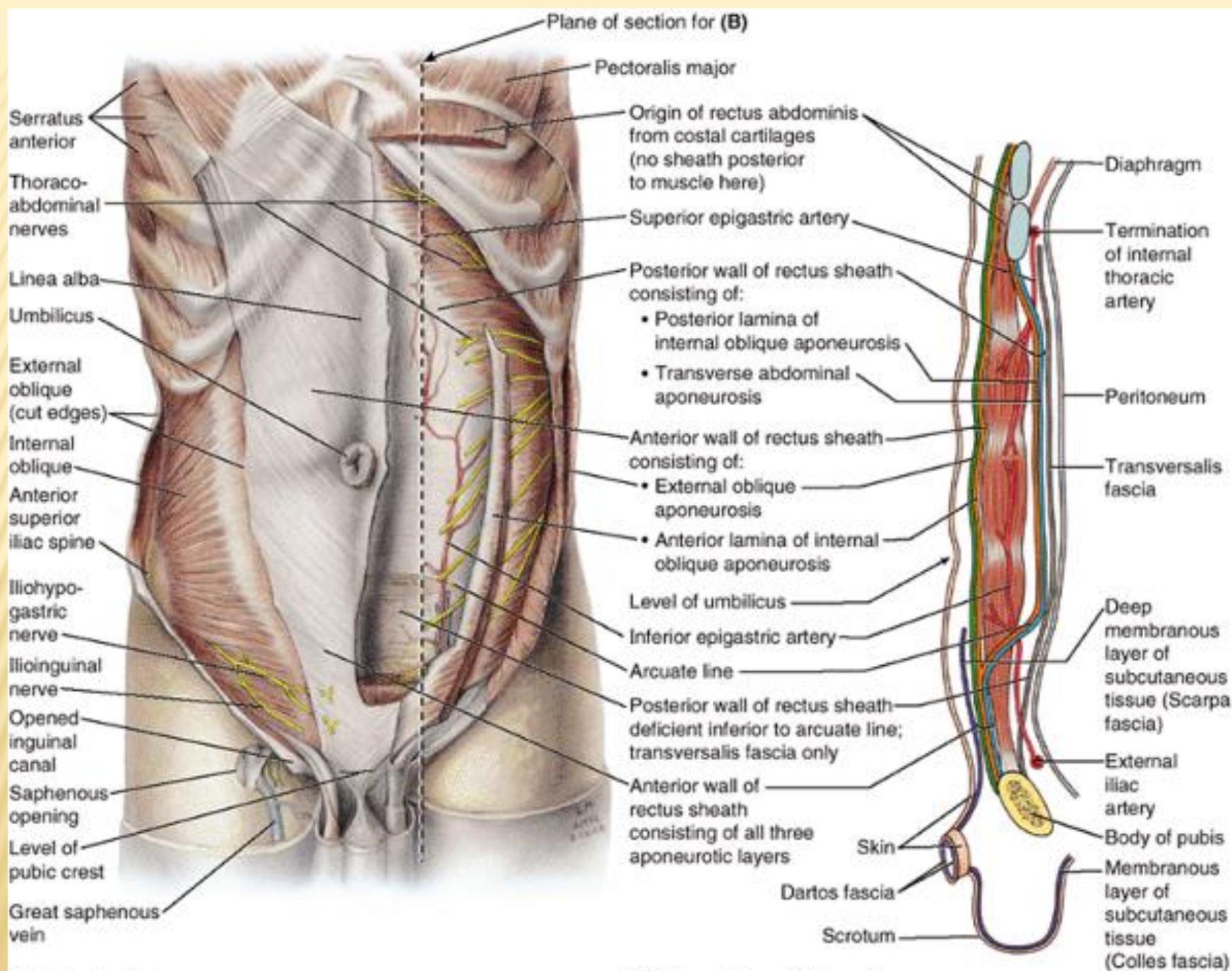


**(B) Anterior view**

**Superior views of transverse sections**

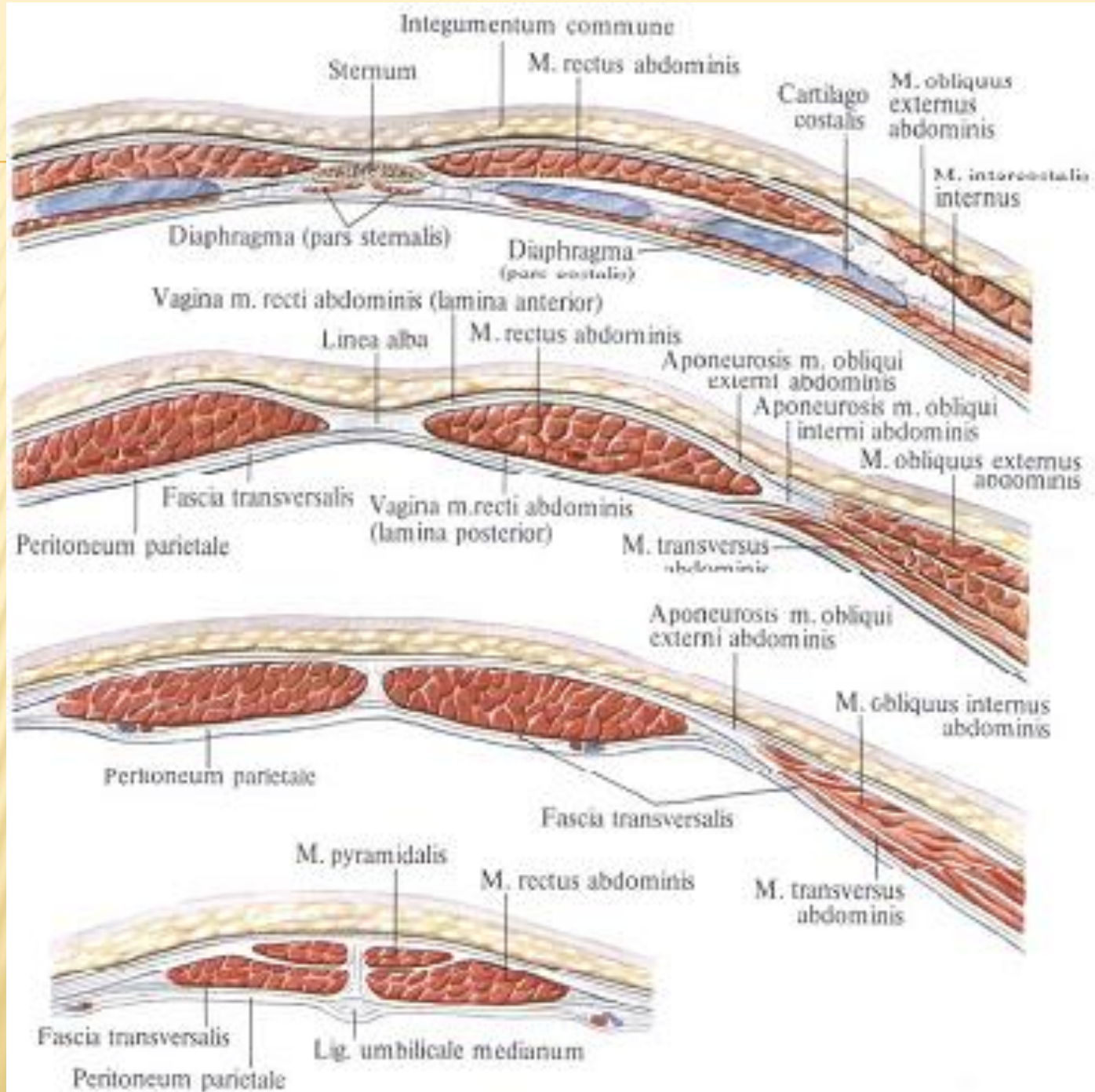




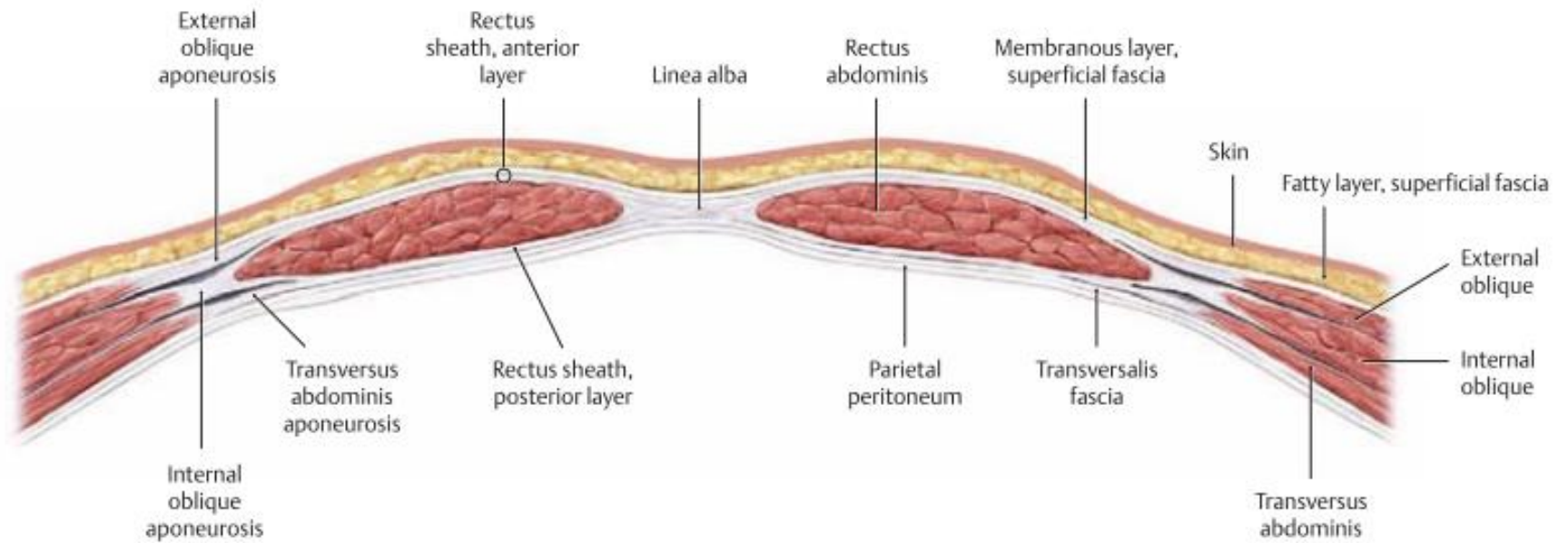


**(A) Anterior view**

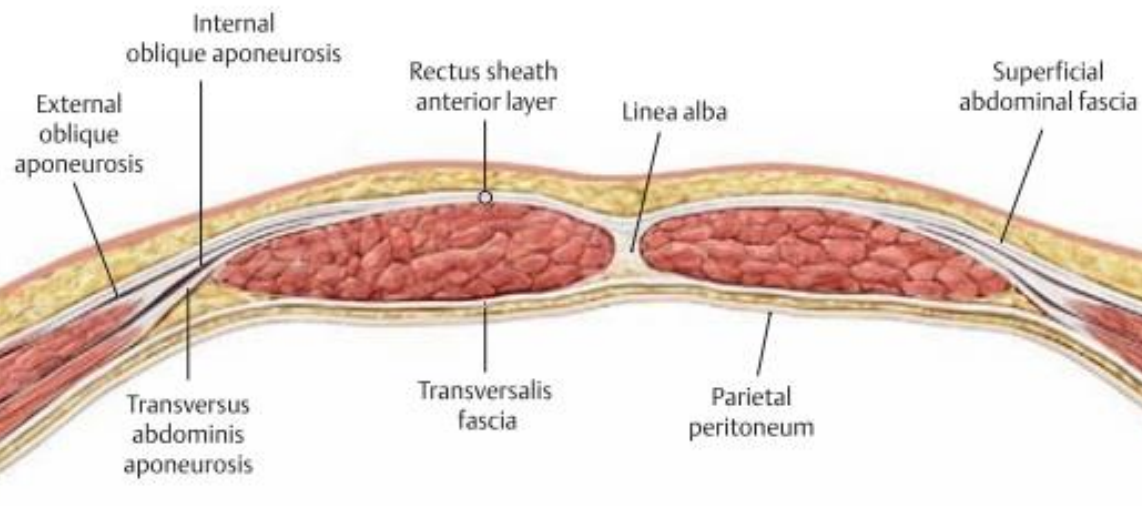
**(B) Schematic sagittal section**



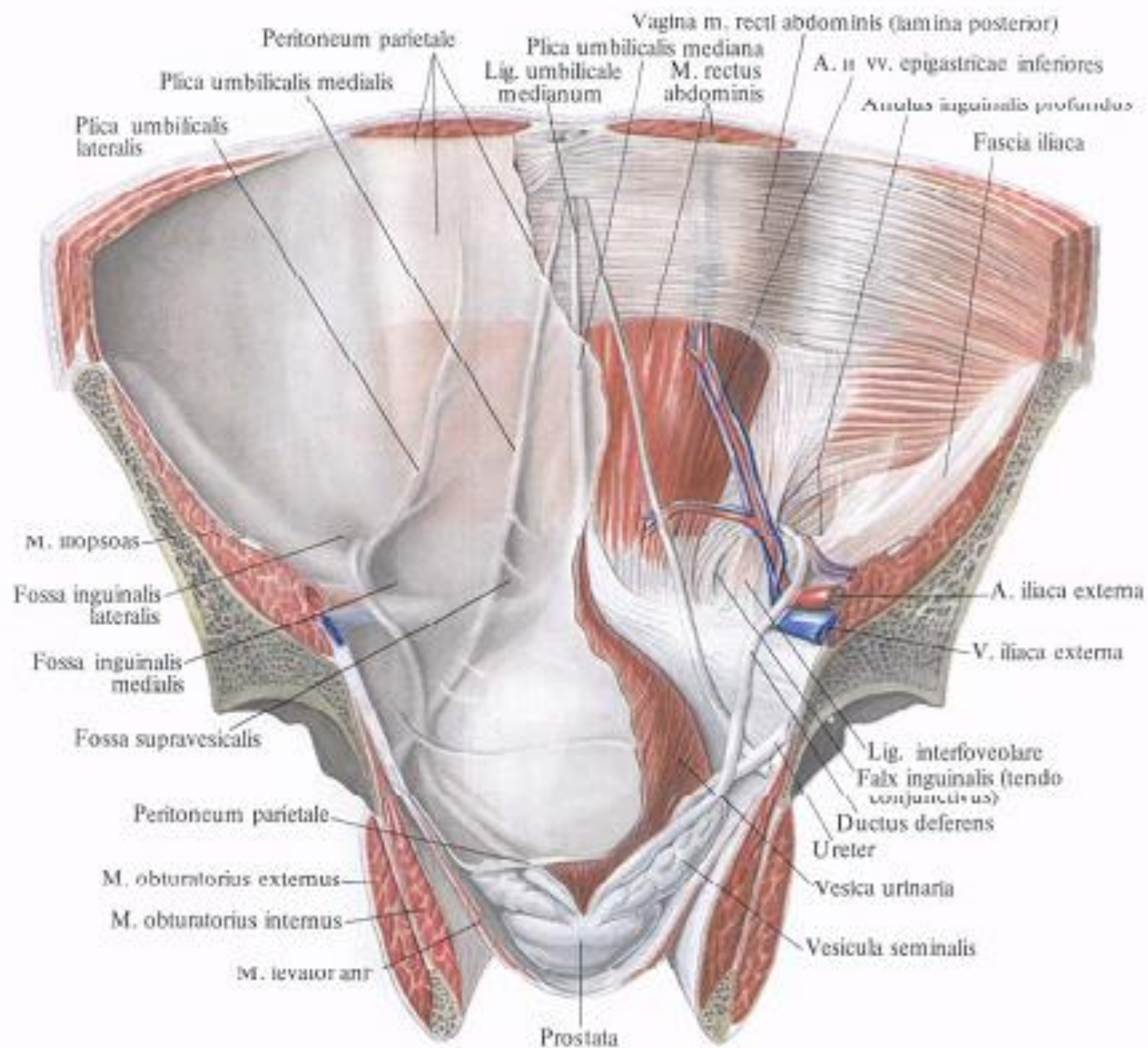




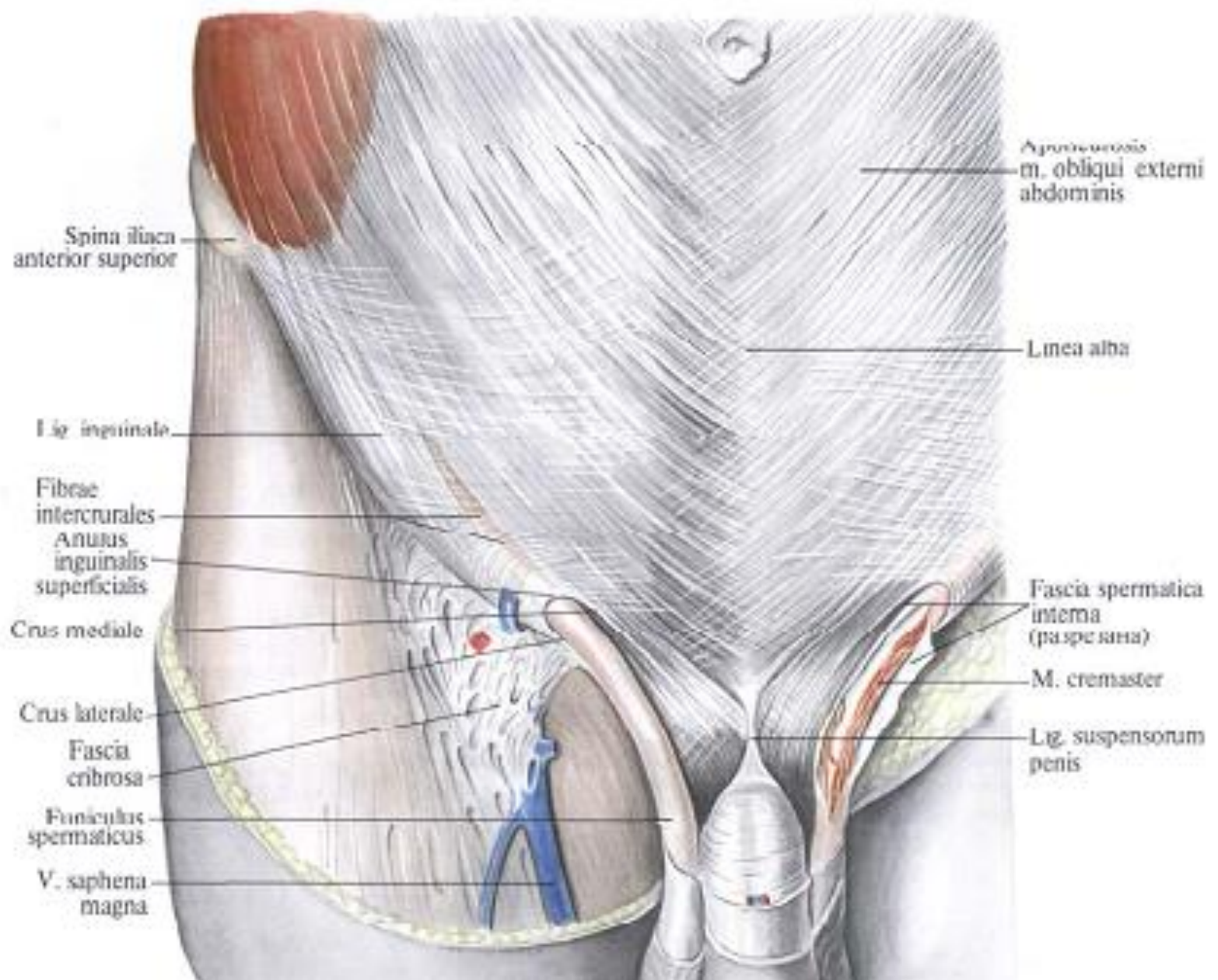
a

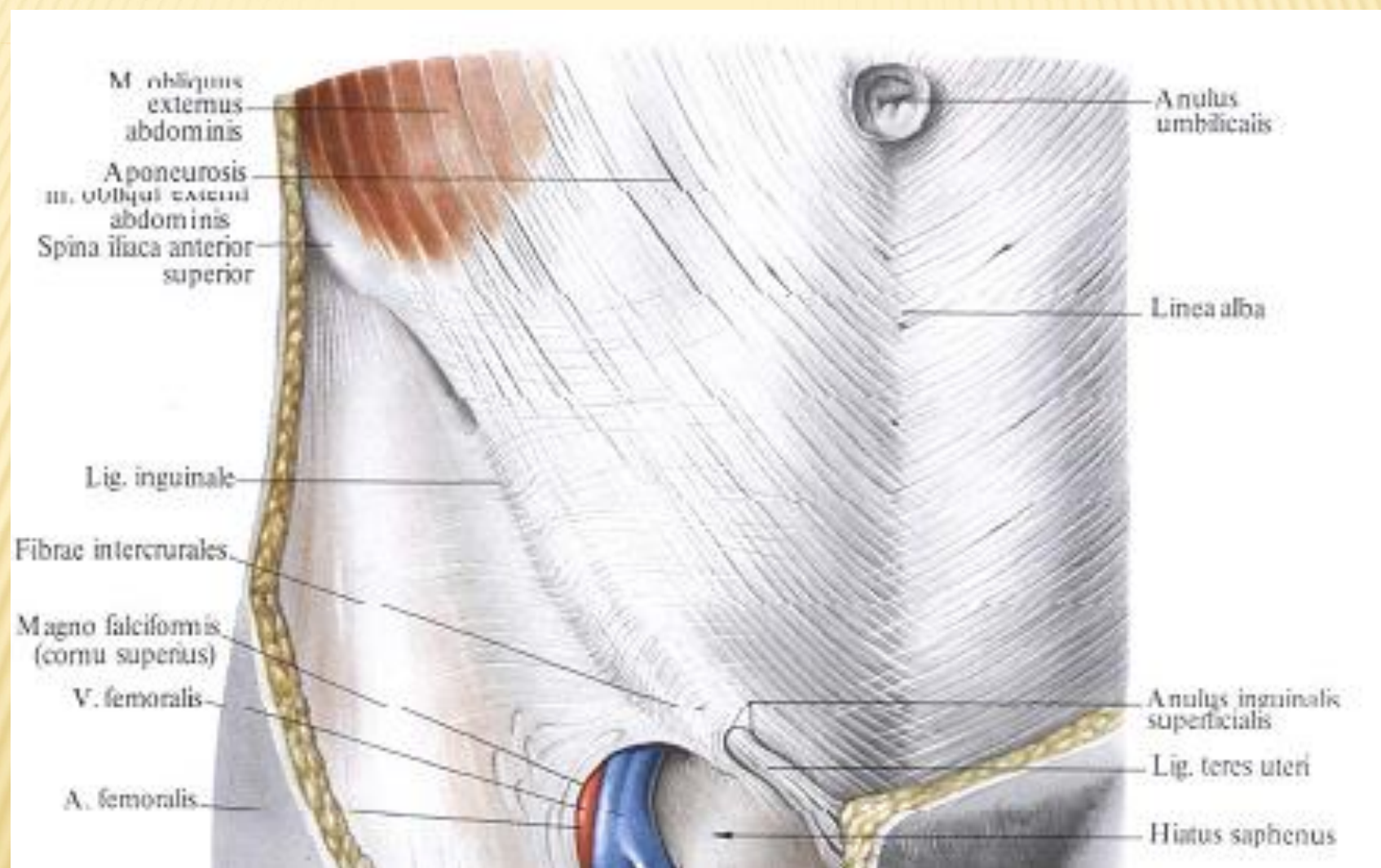


b

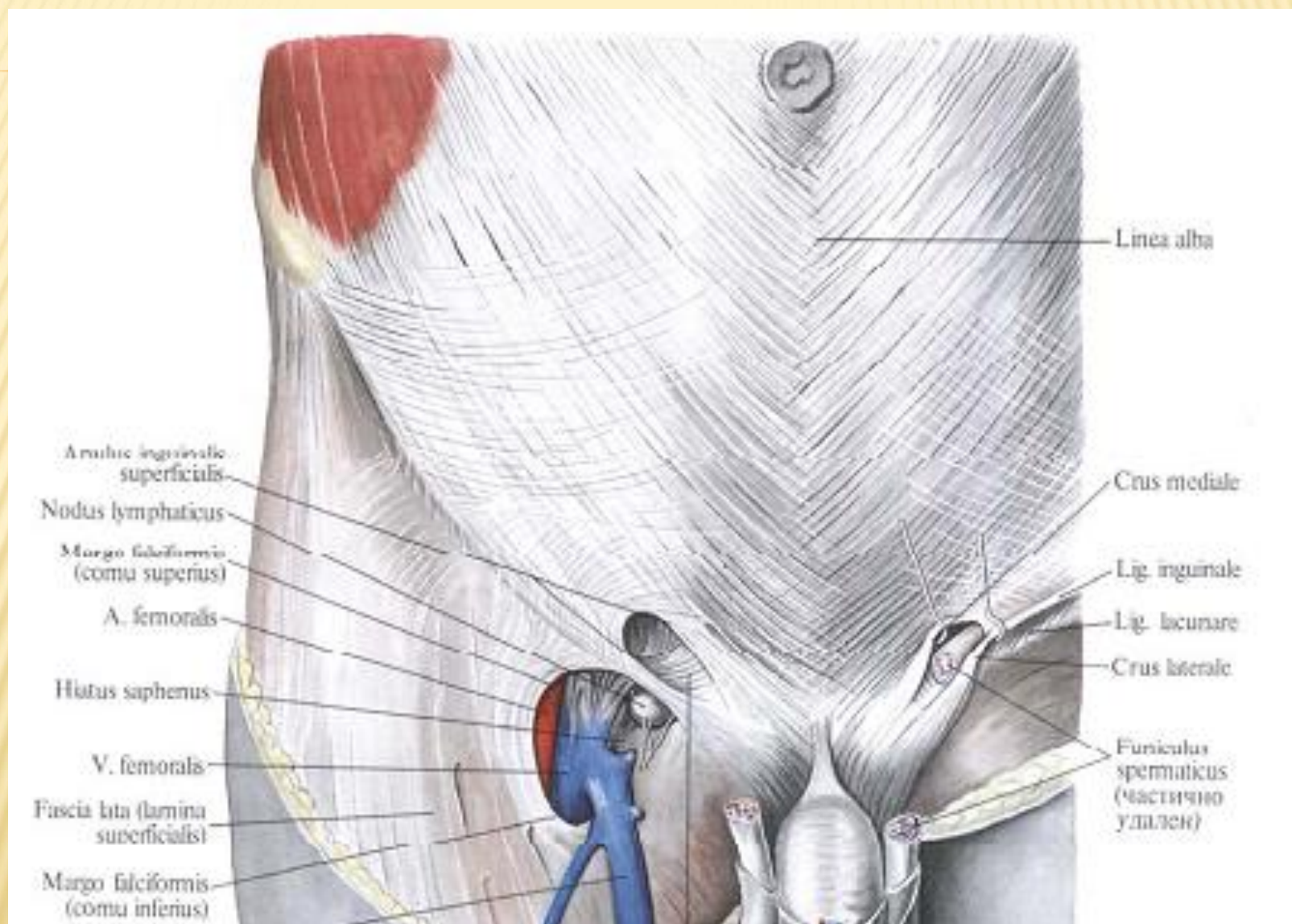


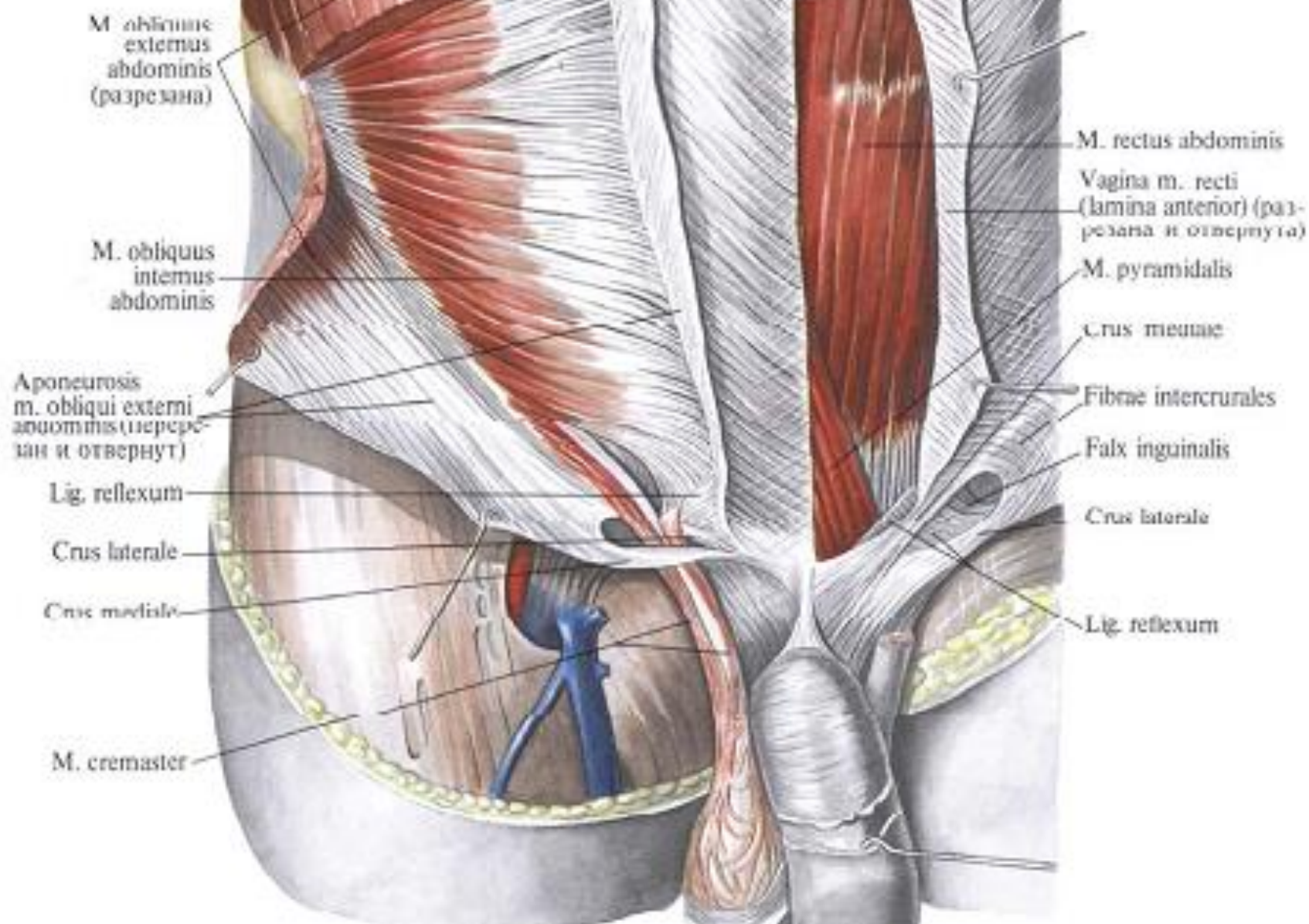




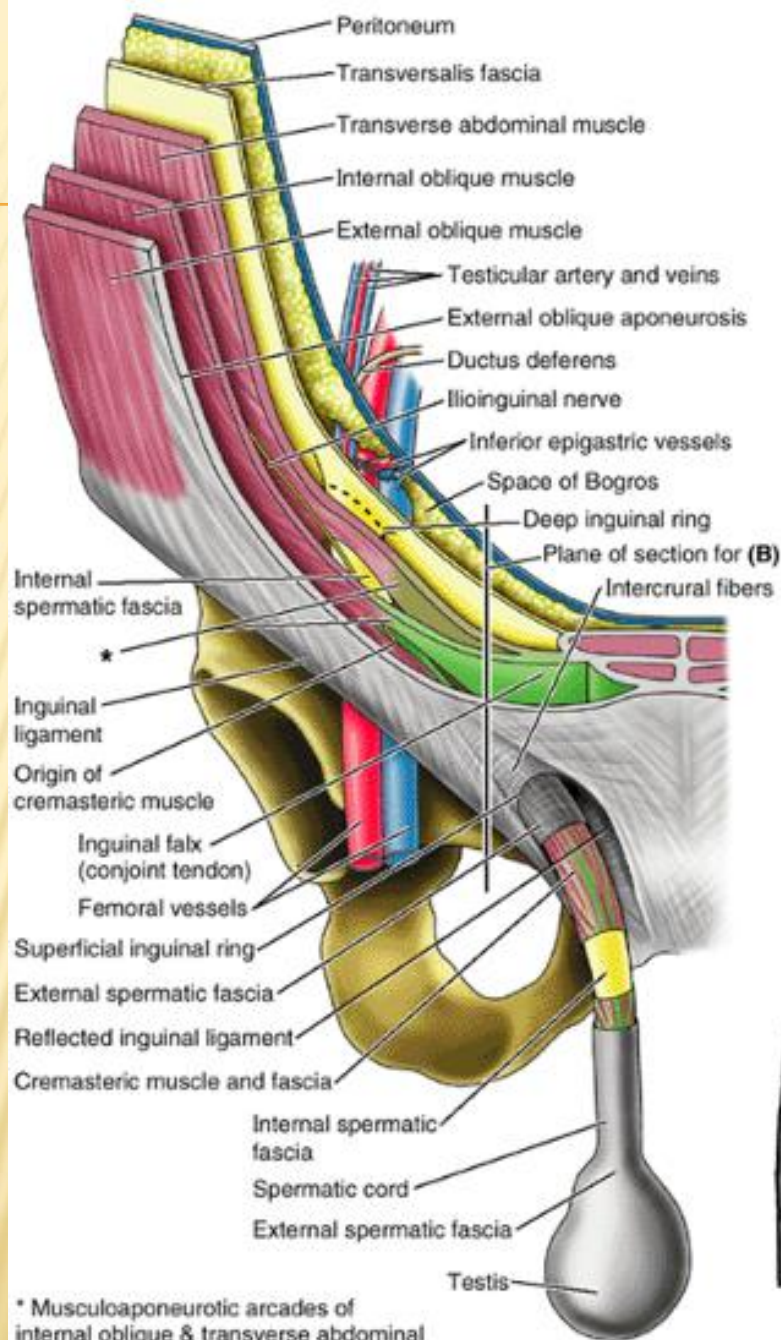




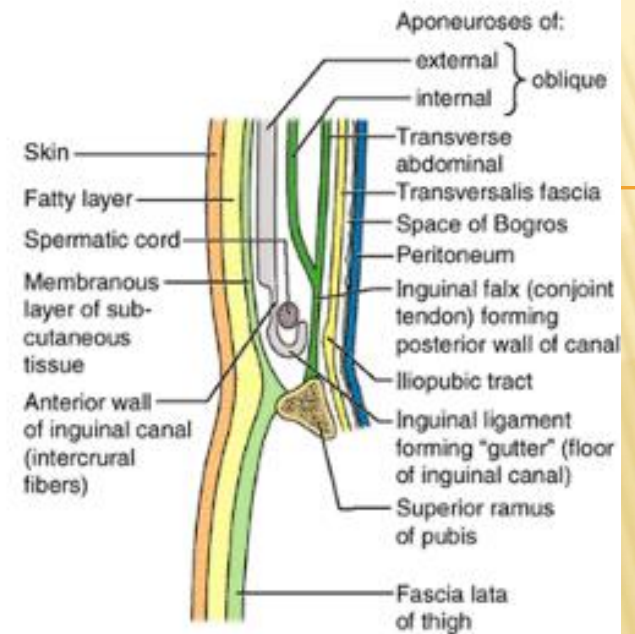




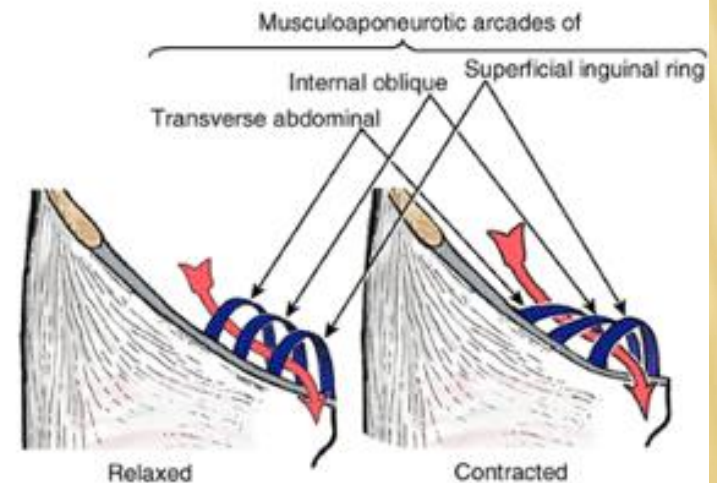




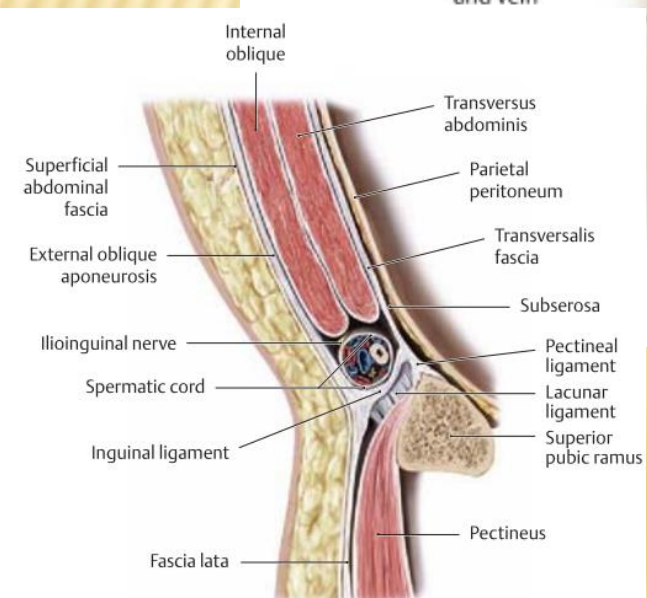
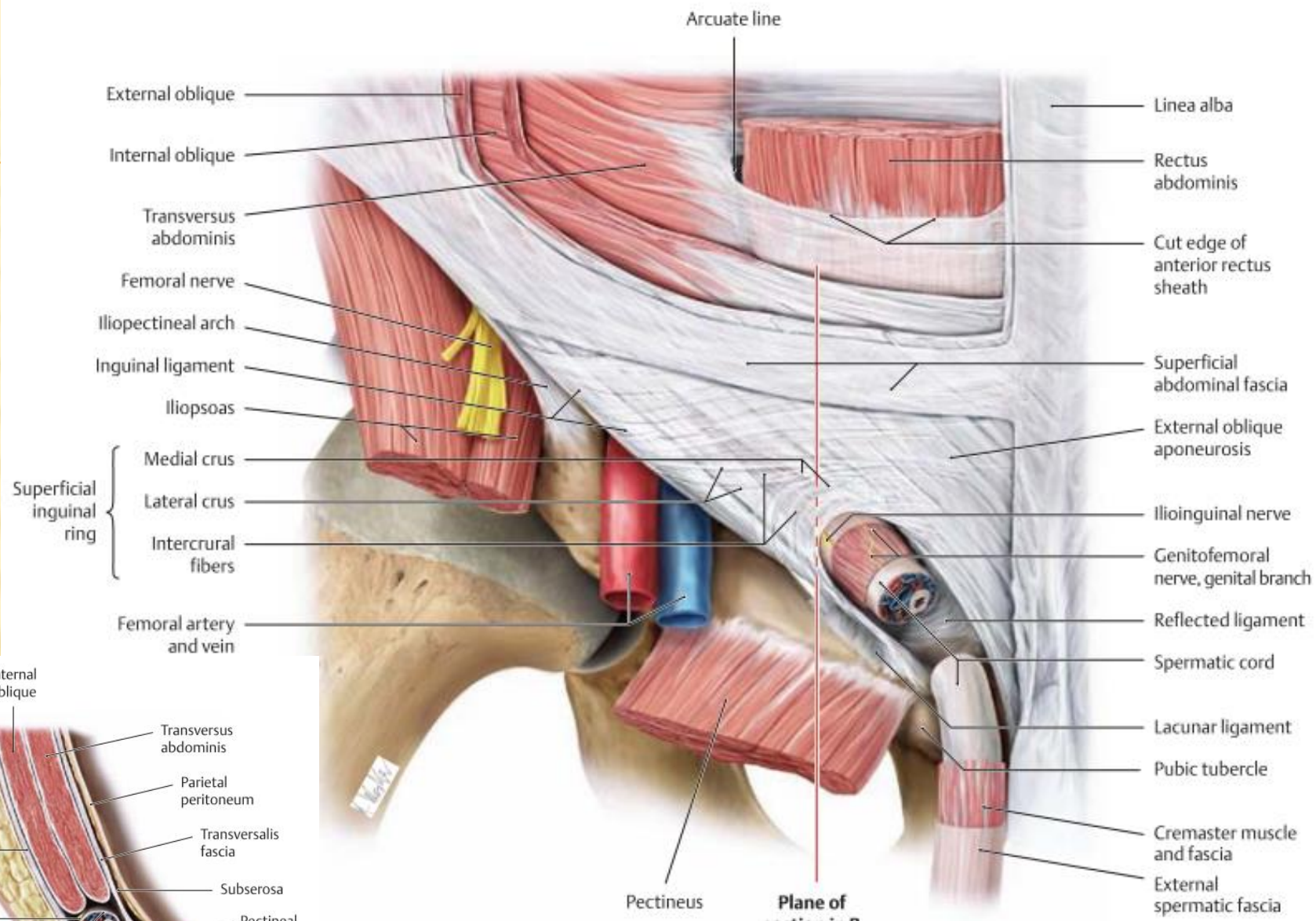
(A) Anterior view



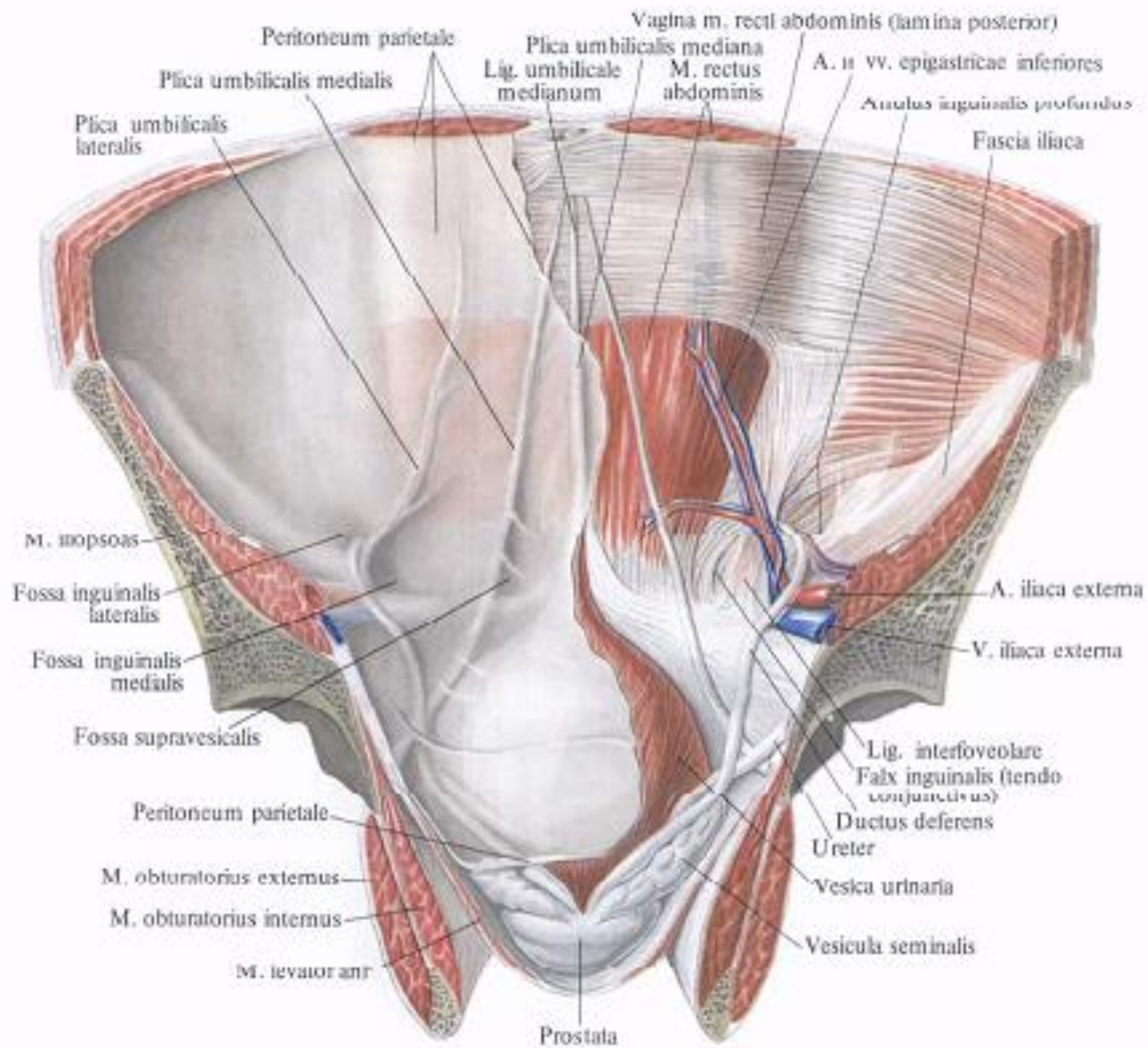
(B) Schematic sagittal section

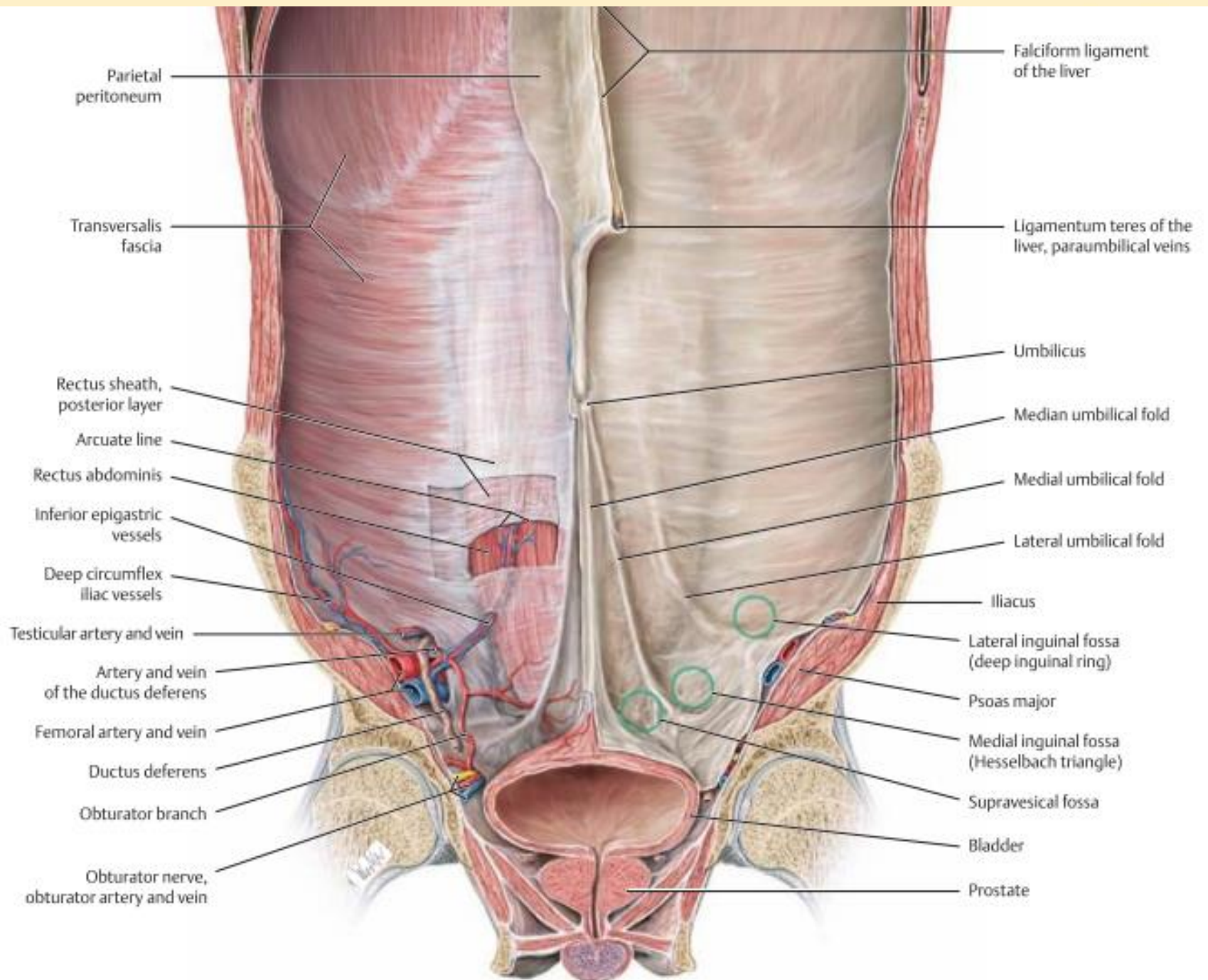


(C) Anterior view







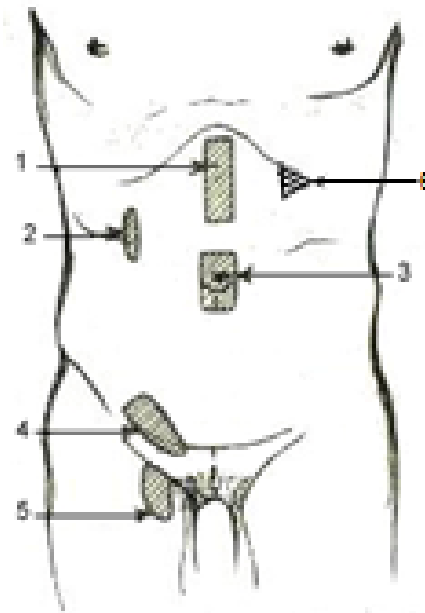




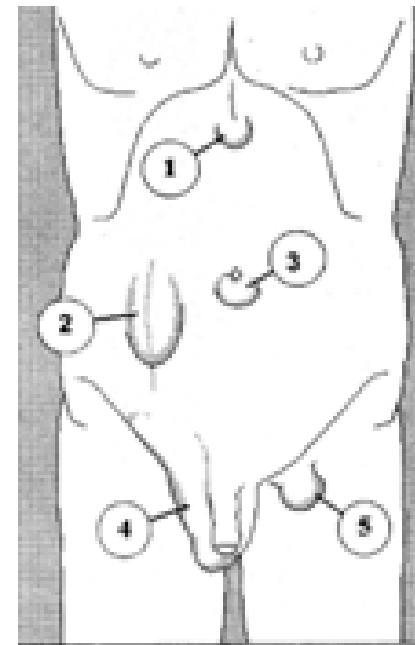
**Zonele slabe ale abdomenului (aspect ventral și dorsal) și unele tipuri de hernii**  
*(după N. Diaconescu și colab., 1979)*

**Слабые места живота (передняя и задняя поверхности) и некоторые виды грыж**  
**грыж**

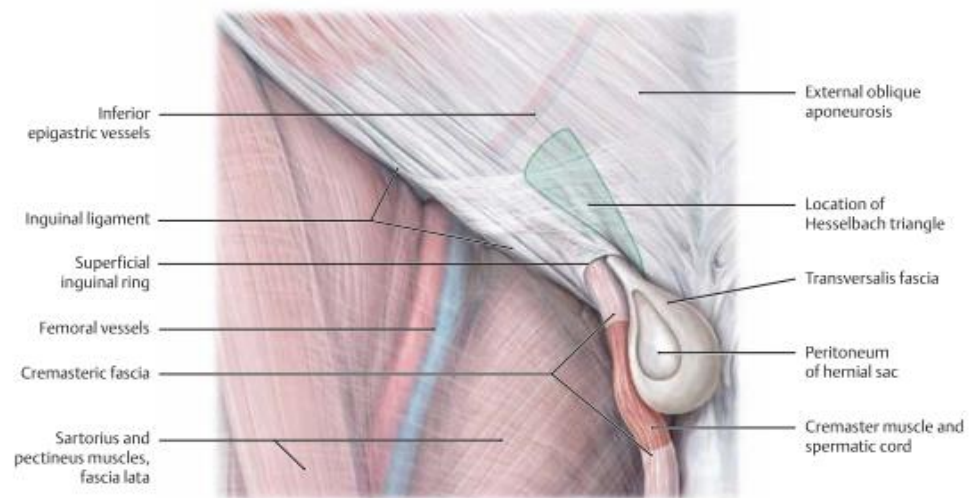
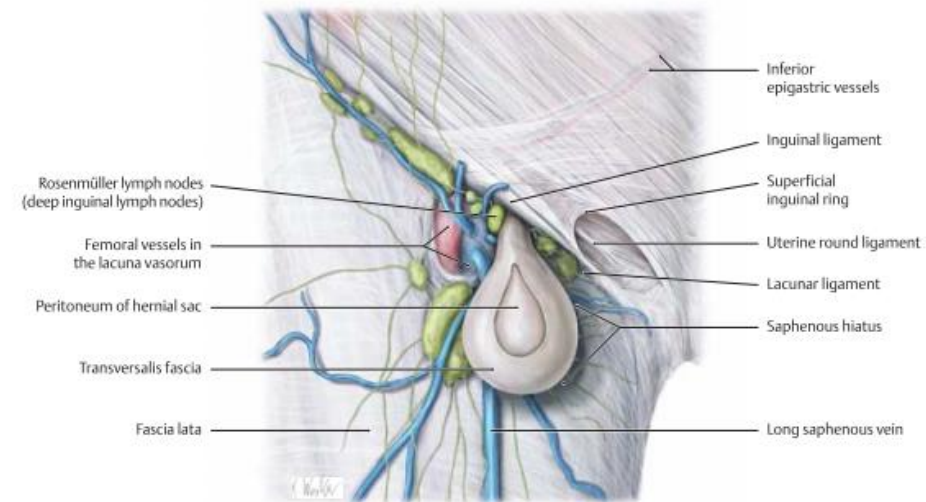
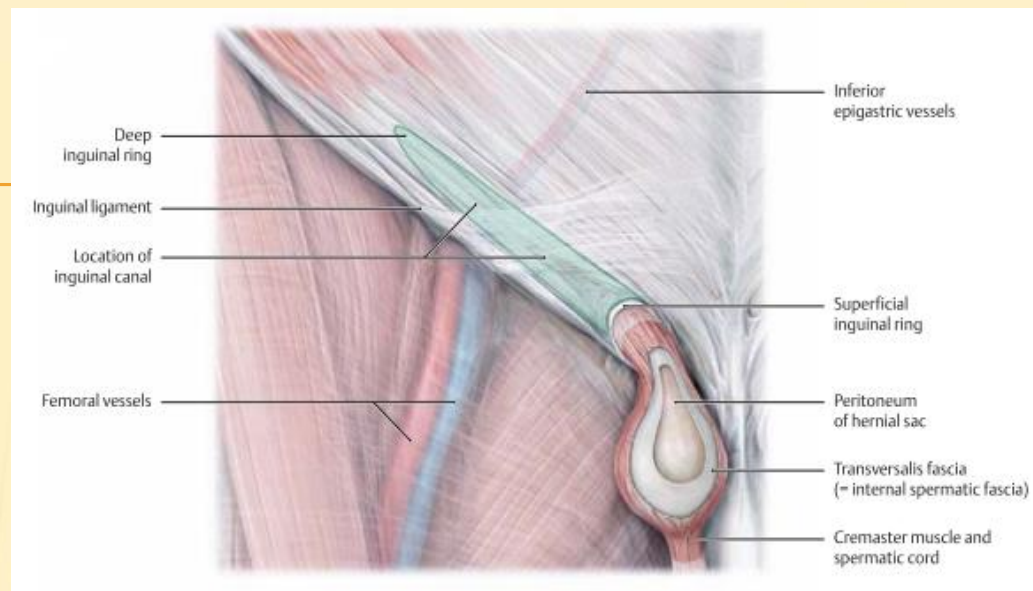
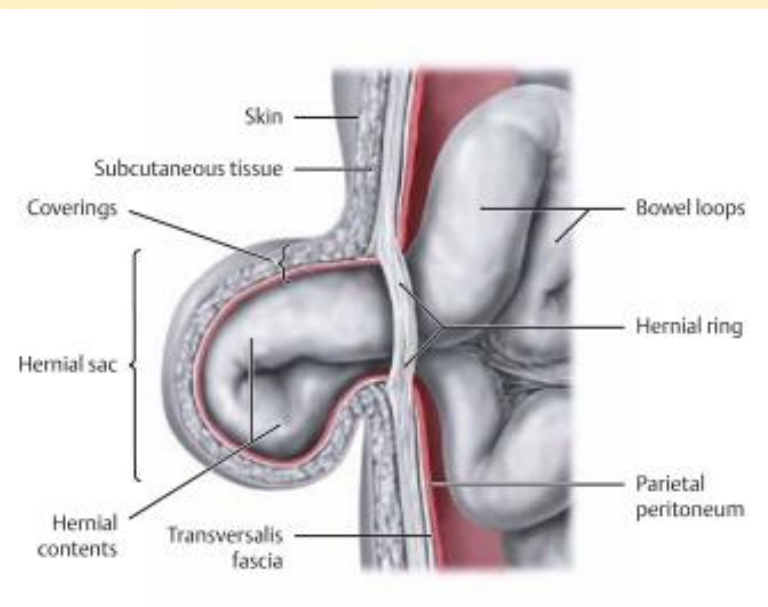
**Weak areas of the abdominal wall (ventral and dorsal aspects) and some types of hernias**



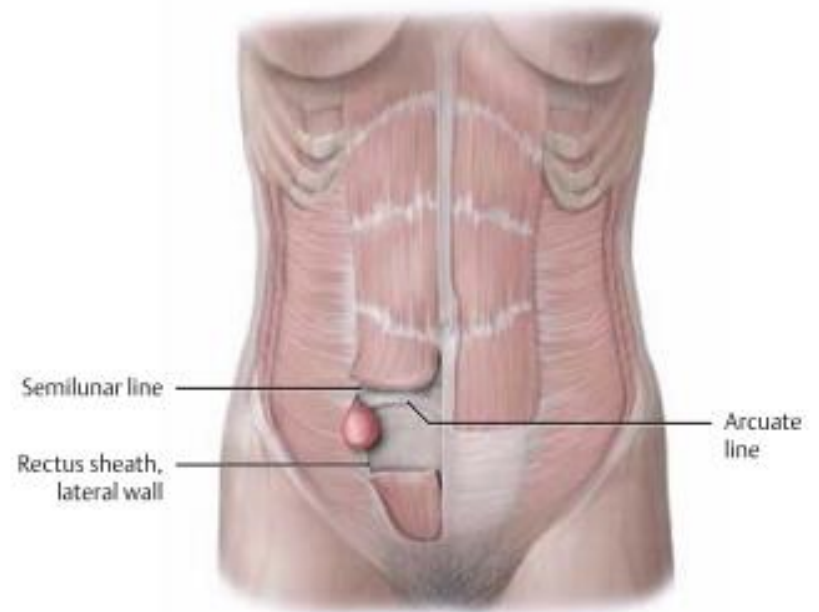
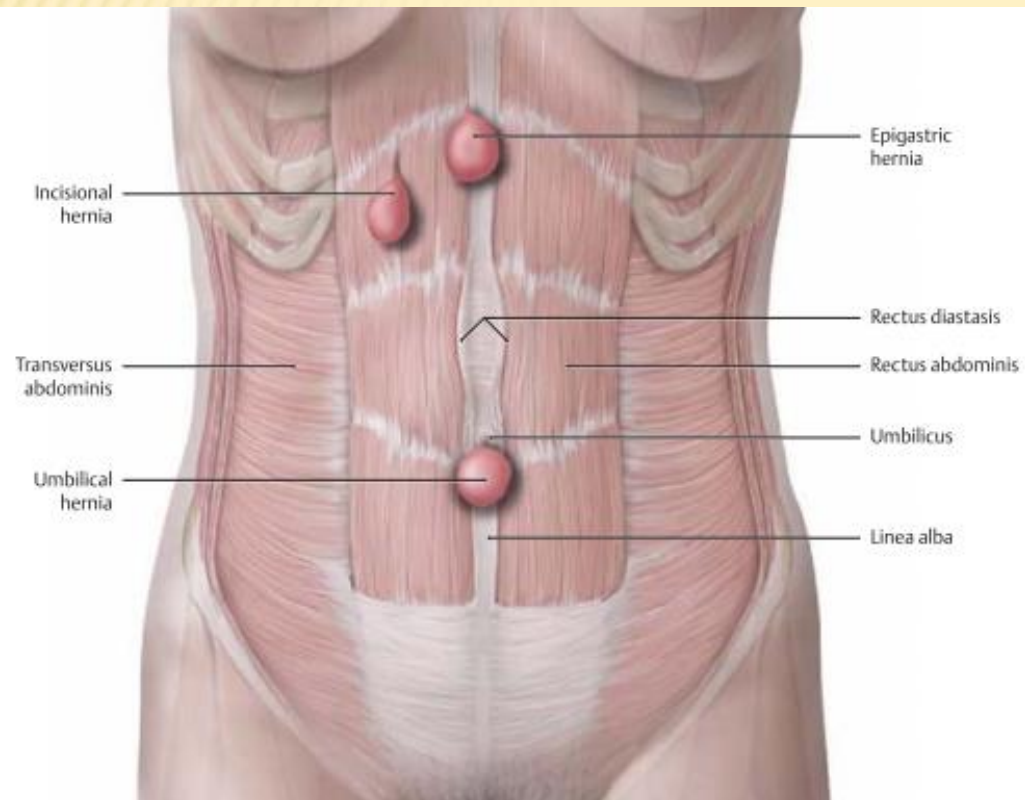
- 1 – *linea alba*;
- 2 – *linea semilunaris (Spigelius)*;
- 3 – *annulus umbilicalis*;
- 4 – *canalis inguinalis (paries posterior)*;
- 5 – *canalis femoralis (annulus femoralis)*;
- 6 – *trigonum subcostale (Валынский)*.



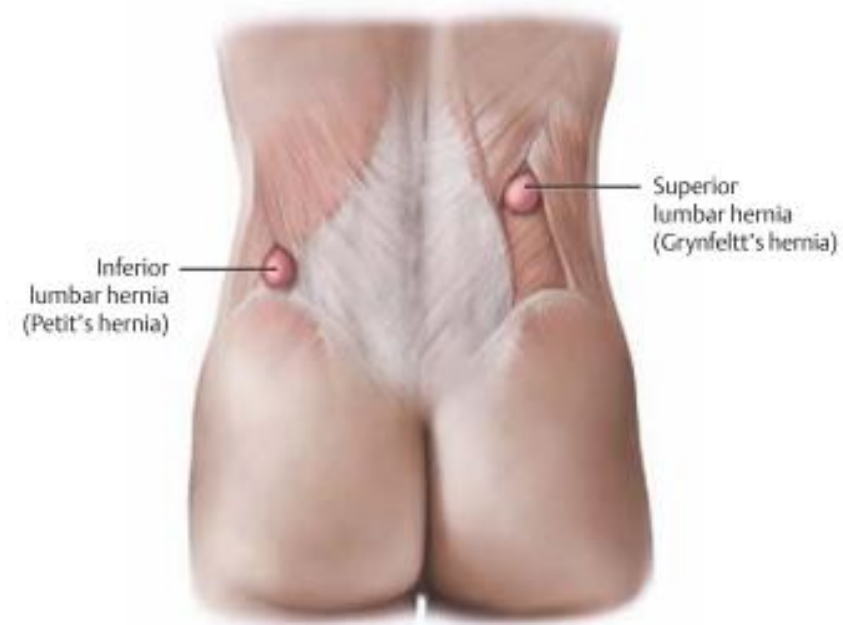- 1 – *hernia lineae albae*;
- 2 – *hernia lineae semilunaris*;
- 3 – *hernia umbilicalis*;
- 4 – *hernia inguinalis*;
- 5 – *hernia femoralis*.

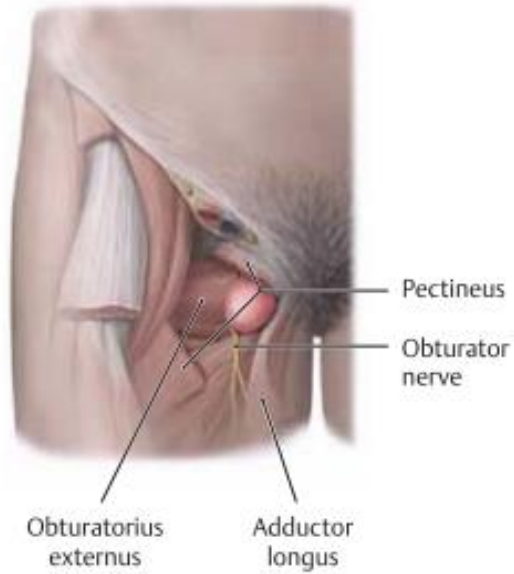




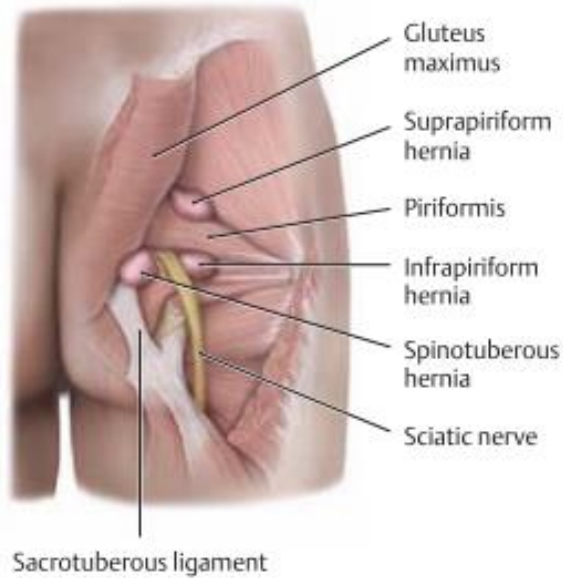

#### D Spigelian hernia

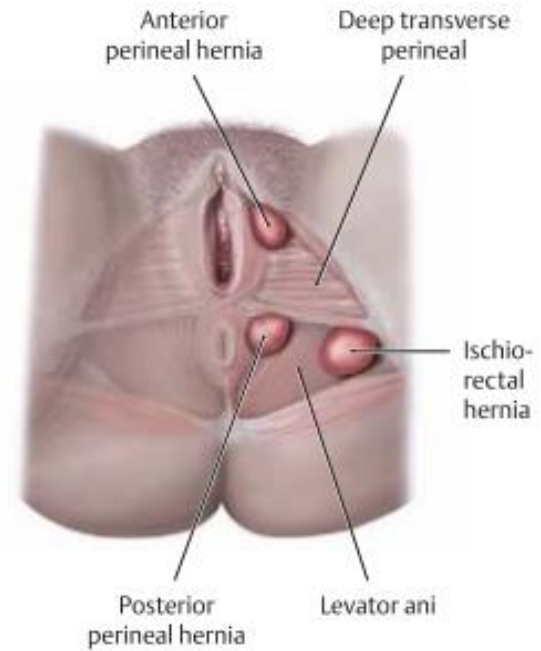




**F Obturator hernia**

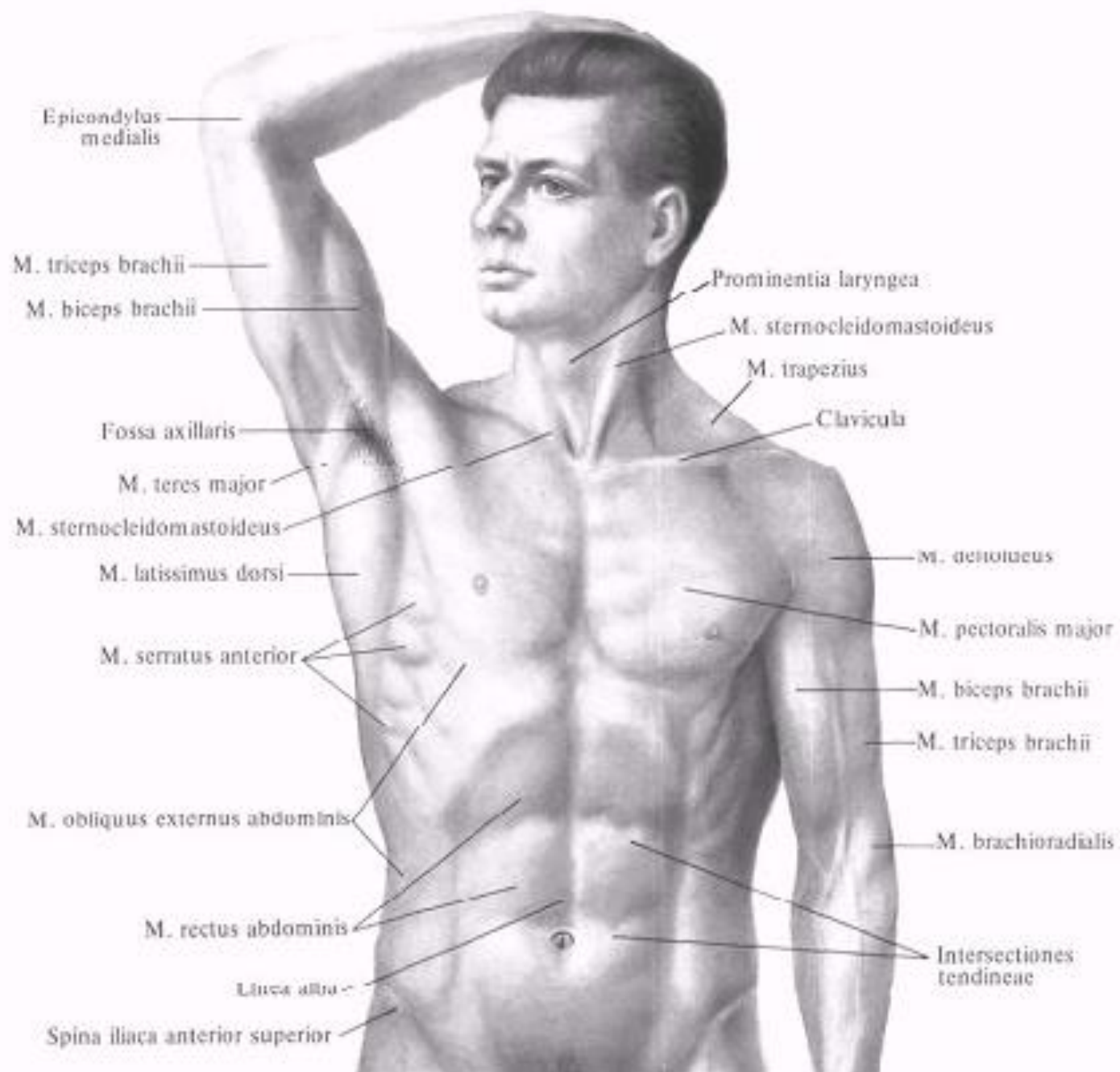


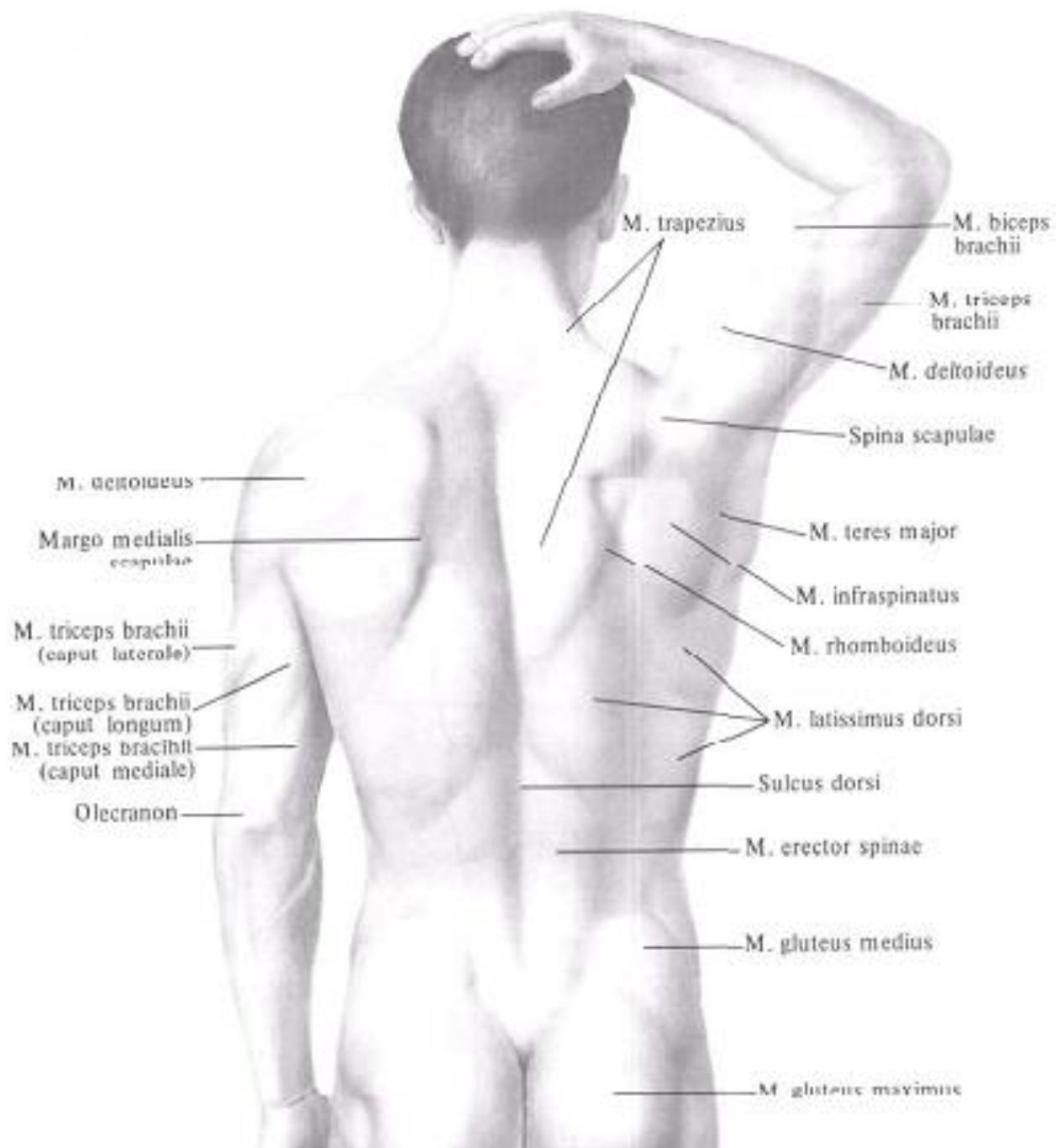
**G Sciatic hernia**



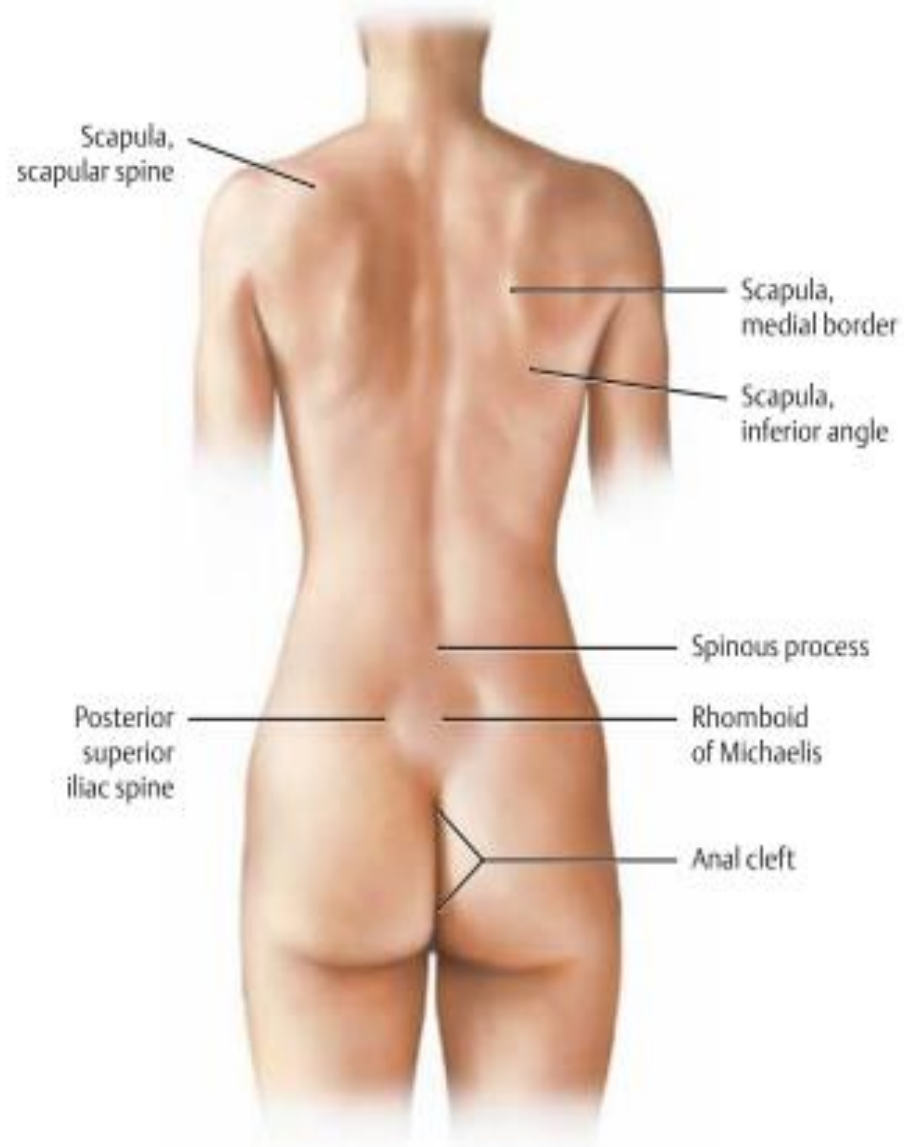
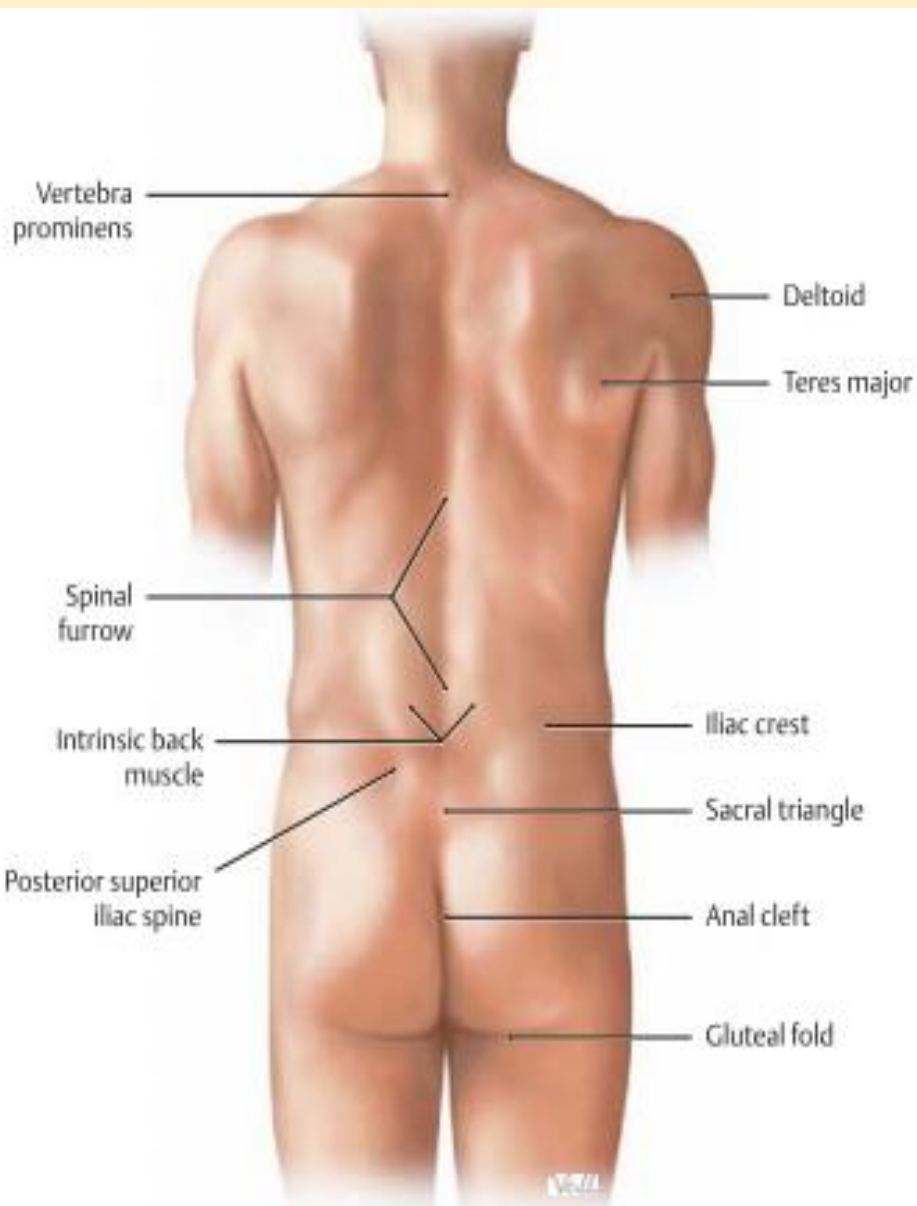
**H Perineal hernia**

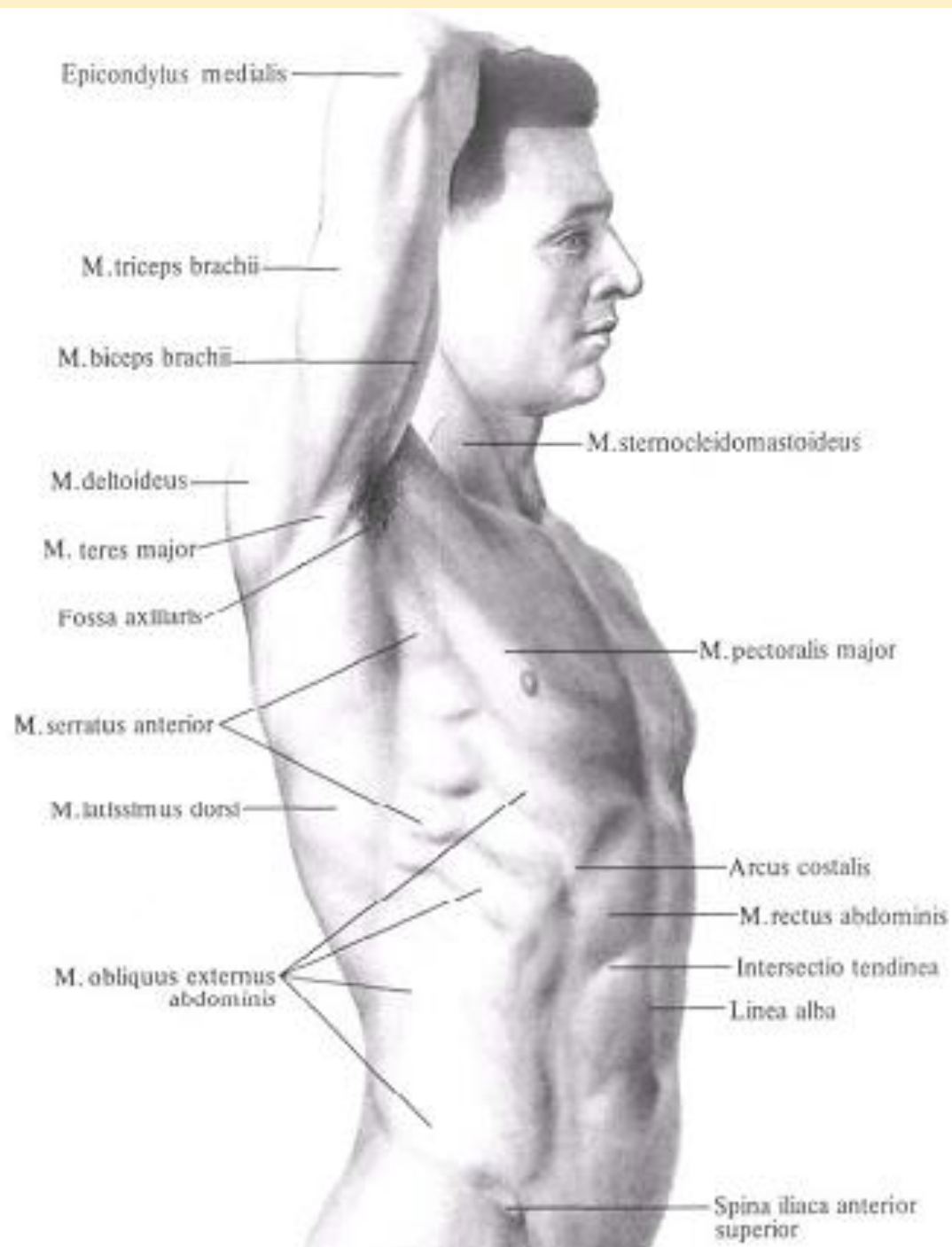




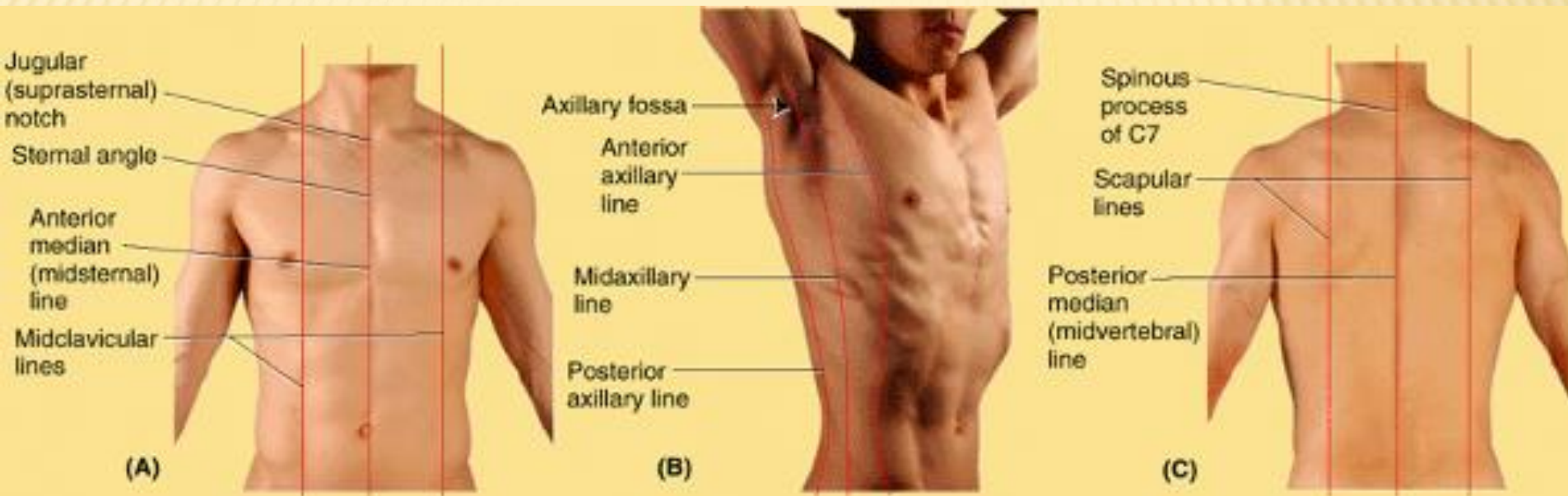


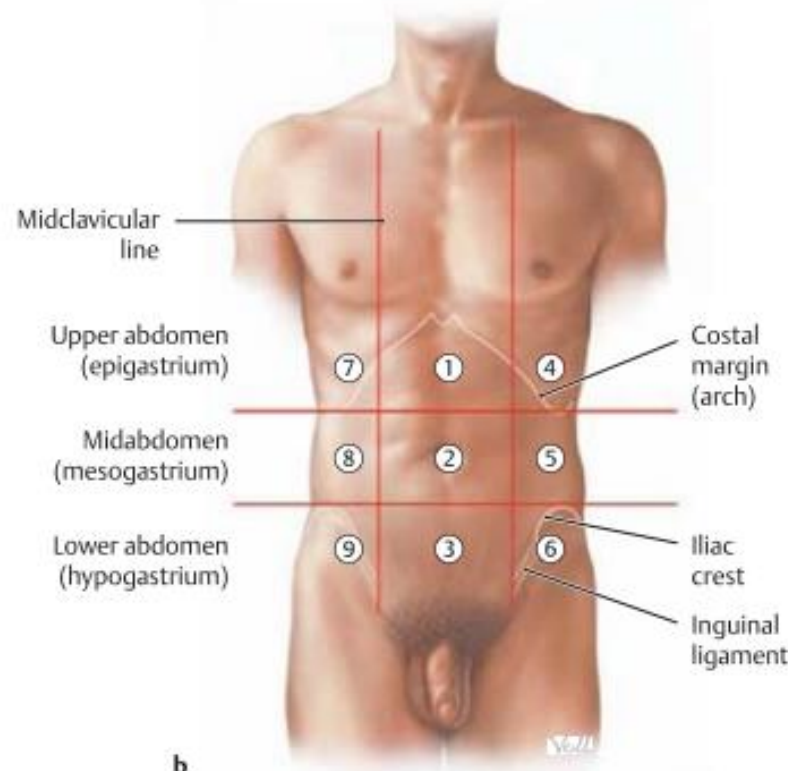
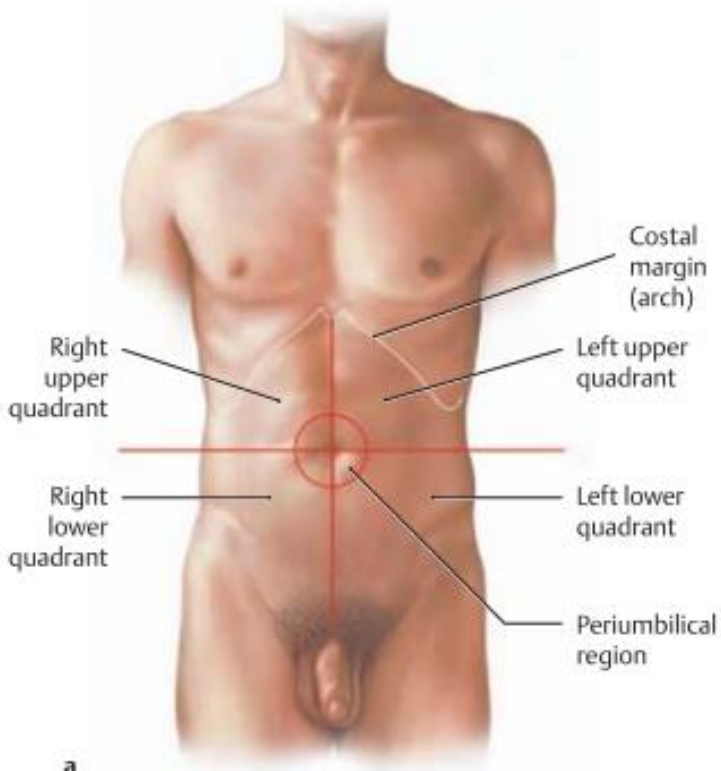






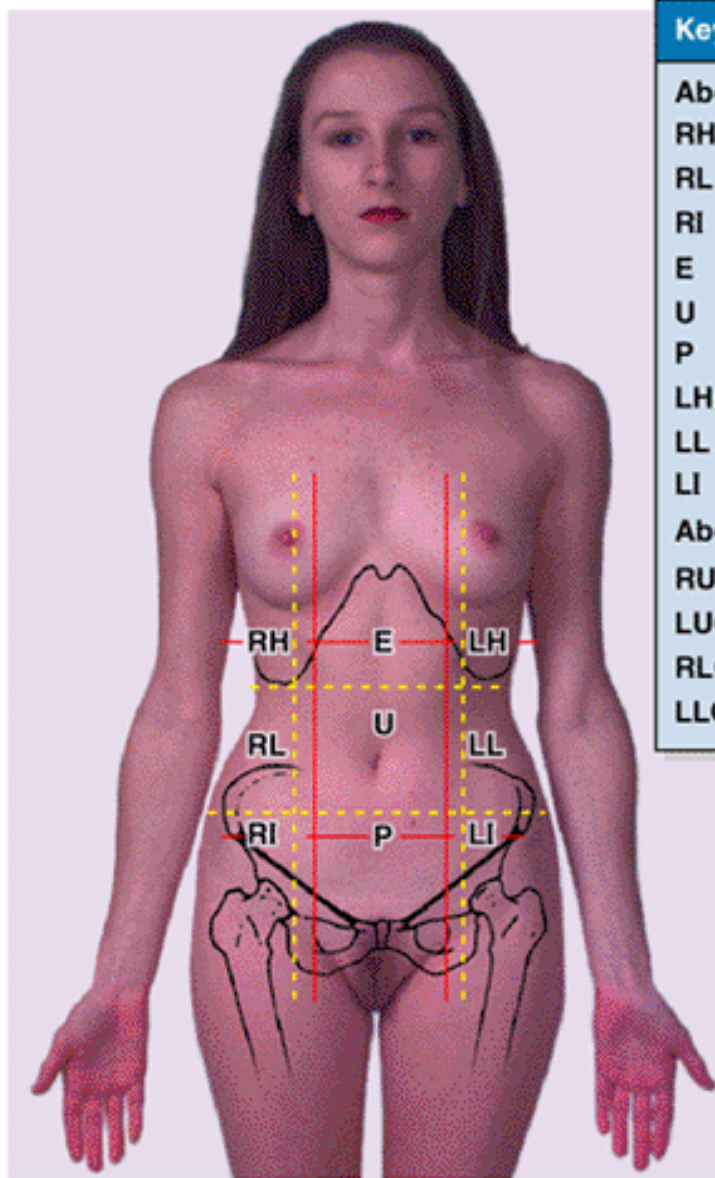






- ① Epigastric region
- ② Umbilical region
- ③ Pubic region
- ④ Left hypo-chondriac region
- ⑤ Left lumbar region
- ⑥ Left inguinal region
- ⑦ Right hypo-chondriac region
- ⑧ Right lumbar region
- ⑨ Right inguinal region





(A) Abdominal regions

### Key

#### Abdominal Regions:

- RH Right hypochondriac
- RL Right lateral (lumbar)
- RI Right inguinal (groin)
- E Epigastric
- U Umbilical
- P Pubic (hypogastric)
- LH Left hypochondriac
- LL Left lateral (lumbar)
- LI Left inguinal (groin)

#### Abdominal Quadrants:

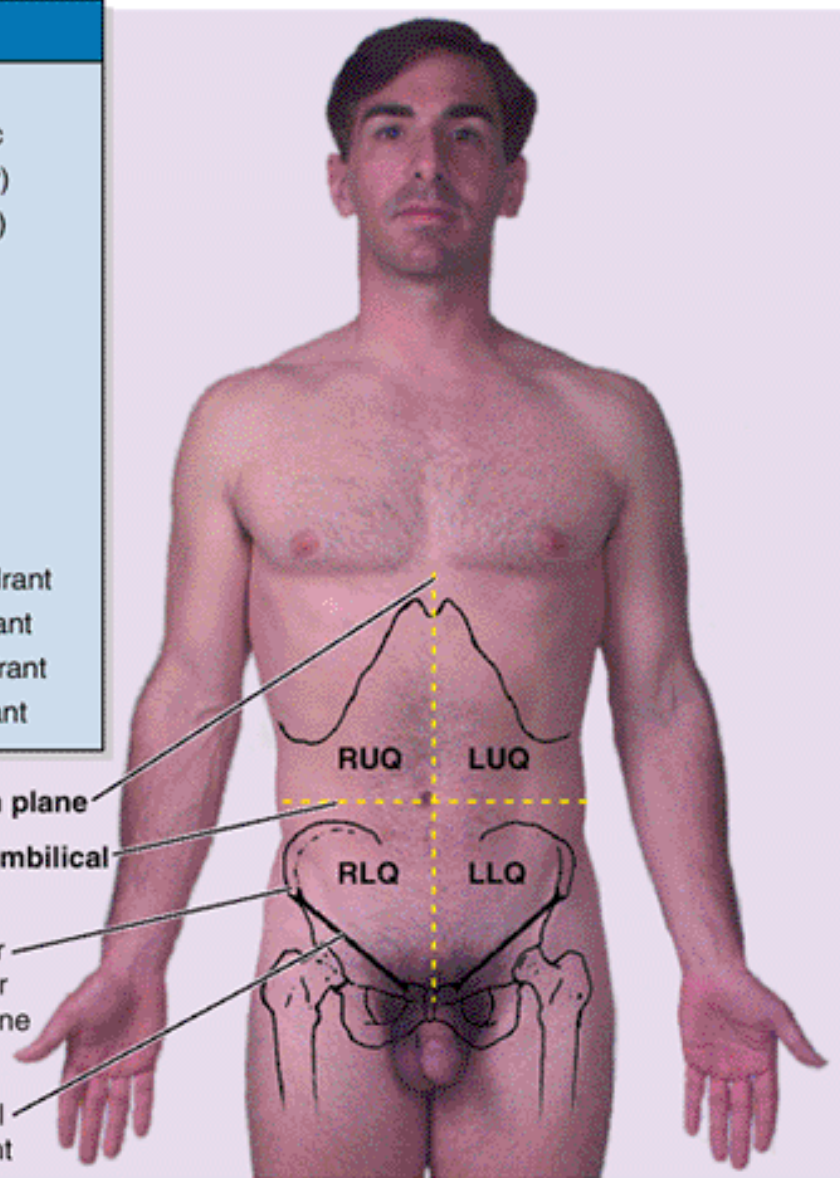
- RUQ Right upper quadrant
- LUQ Left upper quadrant
- RLQ Right lower quadrant
- LLQ Left lower quadrant

Median plane

Transumbilical plane

Anterior superior iliac spine (ASIS)

Inguinal ligament



(C) Abdominal quadrants